

Video Article

Screening of Axonal Degeneration in Carpal Tunnel Syndrome Using Ultrasonography and Nerve Conduction Studies

Xue Deng¹, Lai-Heung Phoebe Chau², Suk-Yee Chiu², Kwok-Pui Leung³, Yong Hu¹, Wing-Yuk Ip¹

¹Department of Orthopedics & Traumatology, The University of Hong Kong

²Clinical Electro-diagnostic Unit, Tung Wah Hospital

³Department of Medicine, The University of Hong Kong

Correspondence to: Wing-Yuk Ip at wyip@hku.hk

URL: <https://www.jove.com/video/58681>

DOI: [doi:10.3791/58681](https://doi.org/10.3791/58681)

Keywords: Carpal tunnel syndrome, ultrasound, nerve conduction studies, demyelination, axonal degeneration, diagnostic accuracy

Date Published: 12/19/2018

Citation: Deng, X., Chau, L.H., Chiu, S.Y., Leung, K.P., Hu, Y., Ip, W.Y. Screening of Axonal Degeneration in Carpal Tunnel Syndrome Using Ultrasonography and Nerve Conduction Studies. *J. Vis. Exp.* (), e58681, doi:10.3791/58681 (2018).

Abstract

Axonal degeneration, indicative of surgical decompression, may coexist in carpal tunnel syndrome (CTS) as the disease progresses. However, the current diagnostic and severity gradation system cannot clearly indicate its coexistence, resulting in confusion of appropriate treatment prescription. There are also constraints in conventional methods for differentiation as well. This study aims at introducing an innovative, efficient, and quick screening protocol to differentiate axonal degeneration associated with CTS, using ultrasound and nerve conduction studies (NCS). It starts by using NCS to perform orthodromic stimulation at the wrist, to obtain the sensory conduction of the median and the ulnar nerves respectively. Meanwhile, the motor conduction of the median nerve is collected by stimulating the palm, wrist, and elbow, followed by the stimulation of the ulnar nerve at the wrist, below and above the elbow. Then, an ultrasound assessment is performed, using a linear array transducer, with cross-sectional area (CSA) and perimeter (P) at the wrist and at the one-third distal forearm calipered. Ratios (R-CSA, R-P) and changes from wrist to one-third distal forearm (Δ CSA and Δ P) are calculated according to a standard format. Potential axonal degeneration coexisting in CTS will be screened according to the criteria of NCS and cut-off values of ultrasound measurements established in a previous study. In terms of its noninvasiveness, low cost, convenience, and efficiency, it is easy to apply ultrasound complementarily in clinical practice to prescreen patients with potential coexisting axonal degeneration. Nevertheless, the ultrasonographic imaging cannot directly reflect axonal degeneration. It still relies on conventional but invasive methods such as electromyography (EMG) and biopsy for confirmation if needed.

Video Link

The video component of this article can be found at <https://www.jove.com/video/58681/>

Introduction

CTS is pathologically a disorder with segmental demyelination, whereas secondary axonal degeneration, which is indicative of surgical decompression, may coexist as the disease progresses¹. However, the current diagnostic and severity gradation scale (from mild to very severe grade) for CTS cannot clearly indicate any coexistence of axonal degeneration, resulting in confusion when choosing the appropriate treatment. Conventional methods for confirming axonal degeneration, such as needle EMG and nerve biopsy, can be sensitive and accurate, but they are both restricted in the clinical practice due to their invasiveness².

To overcome these shortcomings, ultrasound has been introduced for assisting diagnosing^{3,4,5} and grading of the severity of CTS^{6,7,8}. Also, previous study successfully identified its cut-off values for discriminating axonal degeneration associated with CTS, with overall satisfactory sensitivity and specificity⁹. This study aims at introducing this efficient and noninvasive protocol to the practice in the clinical context. The rationale of this protocol is to combine the neurophysiological and structural information provided by NCS and ultrasounds to indicate the pathological progress^{1,10}. It is assumed to be more accurate to describe the pathological progress than the current severity gradation system, helping clinicians to better figure out a plan of care. Compared to other conventional neuroimaging techniques such as diffusion tensor imaging (DTI), this evidence-based approach can be more easily applied in clinical settings with lower costs¹¹.

Protocol

All the procedures have been approved by the University of Hong Kong/Hospital authorities Hong Kong West Institutional Review Board (HKU/HA HKW IRB, Ref. Number: UW17-129).

This protocol is applicable to patients who demonstrated clinical symptoms such as numbness, tingling, or pain over the median nerve-innervated area of the hand, with a positive outcome in Tinel's sign and Phalen's test. Those subjects with comorbidities, such as diabetes mellitus, cancer, rheumatoid arthritis, and other peripheral neuropathies, are not eligible for this protocol.

1. Measurement of the Nerve Conduction Studies

1. Ask the patient to wash his/her hands with warm water. Dry the hands before placing the electrodes. Keep the hand skin temperature above 32 °C.
2. Measure the conduction in the median sensory nerve (**Figure 1**).
 1. Place the recording (E1) ring electrode at the proximal interphalangeal joint while the reference electrode (E2) is attached over the distal interphalangeal joint.
 2. Place the recording electrodes at the wrist between the tendons of the flexor carpal radialis and palmaris longus (12 cm proximal to the E1 electrode) and, ideally, proximal to the distal wrist crease. Ensure that the ground electrode is between the stimulation and recording sites.
 3. Apply supramaximal stimulus 10x to the median nerve via the attached electrodes over the index finger.
 4. Collect the averaged readings of the distal sensory latency, the sensory nerve action potential (SNAP) amplitude, and the conduction velocities displayed in the NCS system.
3. Measure the conduction in the ulnar sensory nerve (**Figure 1**).
 1. Place the E1 ring electrode halfway on the proximal phalanx of the fifth digit while the E2 ring electrode should be located 4 cm distal to the E1 ring electrode.
 2. Place the recording electrodes near the tendon of the flexor carpi ulnaris (12 cm proximal to the E1 ring electrode). Ensure that the ground electrode is between the stimulation and recording sites.
 3. Apply supramaximal stimulus 10x to the ulnar nerve via attached electrodes over the fifth finger.
 4. Collect the averaged readings of the distal sensory latency, the SNAP amplitude, and the conduction velocities of the ulnar nerve displayed in the NCS system.
4. Measure the conduction in the median motor nerve (**Figure 2**).
 1. Place the recording electrode E1 in the most prominent eminence of the thenar area at the motor point of the abductor pollicis brevis (APB).
 2. Place the reference electrode E2 on the proximal phalanx of the thumb.
 3. Stimulate at the mid-palm (3 to 4 cm distal to the distal wrist crease), 6.5 cm proximal to the E1 at the wrist (between the tendons of the flexor carpi radialis and palmaris longus) and the elbow (medial aspect of the antecubital space, just lateral to the brachial artery), using an electronic stimulator.
 4. Collect the supramaximal readings of the distal motor latency, the compound motor nerve action potential (CMAP) amplitude, and the conduction velocities displayed in the NCS system.
5. Measure the conduction in the ulnar motor nerve (**Figure 3**).
 1. Place the E1 over the belly of the abductor digiti minimi while the E2 is attached to the distal phalanx of the fifth digit. The ground electrode is between the stimulation and the recording sites.
 2. Stimulate at the wrist (7 cm proximal to the E1 electrode, just lateral or medial to the flexor carpi radialis tendon), below and above the elbow (5 cm distal and proximal to the ulnar groove) (**Figure 3**).
 3. Collect the supramaximal readings of the distal motor latency, the CMAP amplitude, and the conduction velocities of the ulnar nerve displayed in the NCS system.

2. Measurements Using Ultrasound

1. Ensure that the patient is seated on a plinth facing the examiner, with their hands resting in a horizontal supination position and the fingers semi-extended (**Figure 4**).
2. Place some ultrasound gel over the probe of the transducer, the wrist site, and the distal one-third forearm (**Figure 4**).
3. Perform a transverse scan using a 14 - 13 MHz linear array transducer at the inlet of the carpal tunnel. Freeze the real-time imaging and continuously caliper the hyperechoic epineurium of the median nerve at the inlet of the carpal tunnel (**Figure 5**).
4. Scan proximally along the innervated area of the median nerve to the site of the one-third distal forearm. Freeze the real-time imaging and caliper the hyperechoic epineurium of the median nerve at the one-third distal forearm (**Figure 6**).

3. Screening of Potential Coexisting Axonal Degeneration in Carpal Tunnel Syndrome

1. Screen the possible coexisting axonal degeneration primarily based on the NCS criteria listed in **Table 1**.
NOTE: Those patients who fulfilled the criteria for associated axonal degeneration according to the NCS criteria in **Table 1** will be primarily screened for the potential coexistence of axonal degeneration.
2. Consider the ultrasound readings as complementary information for screening axonal degeneration.
NOTE: The patient will be considered associated with the coexistence of axonal degeneration should any of the measured readings of the ultrasound parameters be above the cut-off value(s).
3. Take the ultrasound readings into account when the NCS readings failed to fulfill the NCS criteria from **Table 1** (e.g., the NCS signal is absent or a conduction block or temporal dispersion occurs).
NOTE: The patient can also be considered as potentially associated with axonal degeneration should any of the measured readings of the ultrasound parameters be above the cut-off value(s). Further golden standard testing, such as EMG or biopsy, can be applied for confirmation if needed.

Representative Results

As was described in **Table 1**, associated axonal degeneration has been primarily screened out should the subject fulfill the criteria of NCS as follows: (1) the sensory conduction velocity of the median nerve is less than 42m/s and/or (2) the distal sensory latency is more than 4.6 ms or the distal motor latency is more than 3.2 ms; (3) the SNAP amplitude at the wrist is less than 10 μ V with the CMAP amplitude drop being no more than 20%. Those with temporal dispersion (a CMAP amplitude drop of >20%) and/or conduction block (a CMAP amplitude drop of >50%) will be excluded. Regarding the criteria of the NCS parameters, which include conduction velocity, distal latency, SNAP amplitude, exclusion of conduction block¹² and temporal dispersion¹³, they were all set based on previously well-established references and our laboratory practical standard.

Then, the measured readings of the ultrasound parameters will also be taken into account. The CSA is the coronal size of the nerve measured by tracing the hyperechoic epineurium, while the P is the circumference of the traced hyperechoic epineurium. R-CSA/R-P is calculated by the CSA/P measured at the carpal inlet divided by that measured in the one-third distal forearm. Δ CSA/ Δ P is the change of CSA/P from the wrist to the one-third distal forearm. The cut-off values and the sensitivity, specificity, and accuracy of the ultrasound parameters were determined by plotting receiver operative characteristics (ROC) curves, which were identified in a previous study⁹. The positive predictive value and negative predictive value are also displayed in **Table 1**. Those patients with any ultrasound parameter value(s) above the correspondent cut-off value(s) will be considered as suffering from the potential coexistence of axonal degeneration. Alternatively, the ultrasound readings can also be considered as indicators of potential axonal degeneration, should the subject not fulfill the NCS criteria in **Table 1**.

A group of 80 subjects who fulfilled the NCS criteria in **Table 1** was enrolled *via* convenience sampling to examine the effectiveness of the protocol. They were assigned to group A (demyelination only, $n_1 = 45$) and group B (associated axonal degeneration, $n_2 = 35$), based on the NCS criteria in **Table 1**. By between group comparison, significant differences were found in NCS and ultrasound measurements (**Table 2**). The results indicate this protocol can be effective in screening axonal degeneration associated with CTS.

On the other hand, another group of 46 subjects (group C), who did not fulfill the NCS criteria in **Table 1**, were enrolled with ultrasound measurements generated descriptively. Based on the ultrasound performance, the enrolled subjects were all potentially associated with coexisting axonal degeneration (**Table 2**).

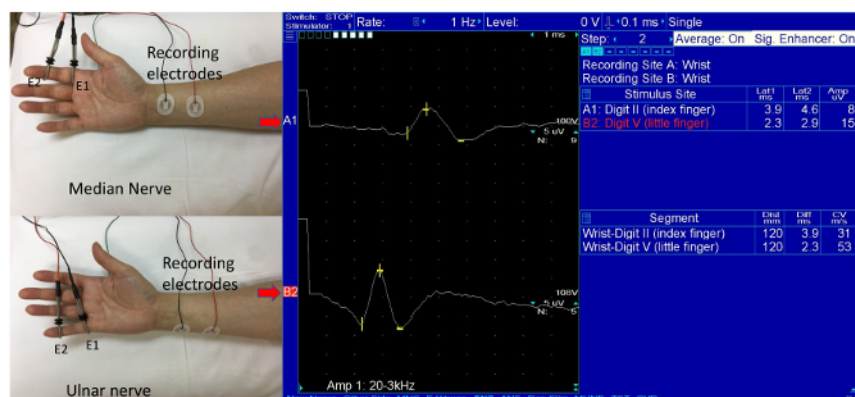


Figure 1: Measurement of the conduction in the sensory median and ulnar nerve. [Please click here to view a larger version of this figure.](#)

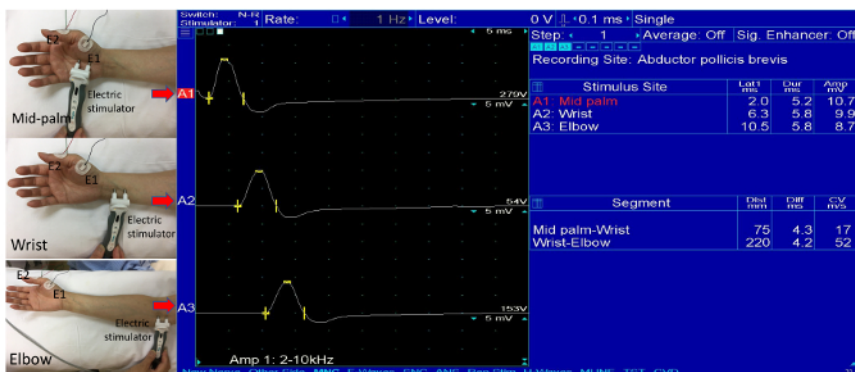

Figure 2: Measurement of the conduction in the motor median nerve. [Please click here to view a larger version of this figure.](#)

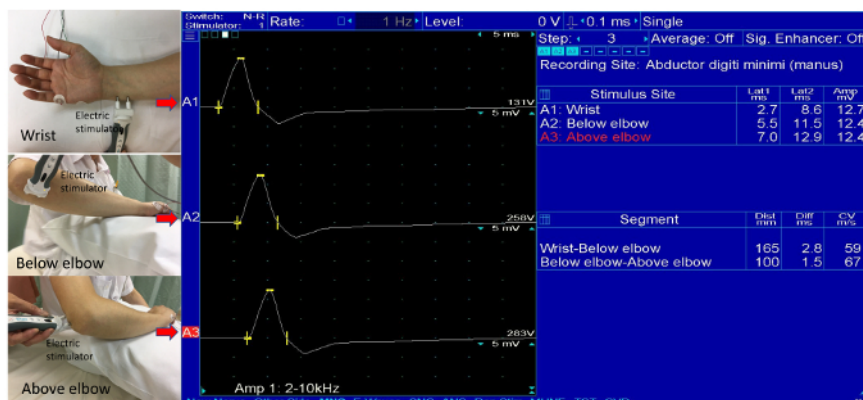


Figure 3: Measurement of the conduction in the motor ulnar nerve. [Please click here to view a larger version of this figure.](#)



Figure 4: Measurement by ultrasound. [Please click here to view a larger version of this figure.](#)

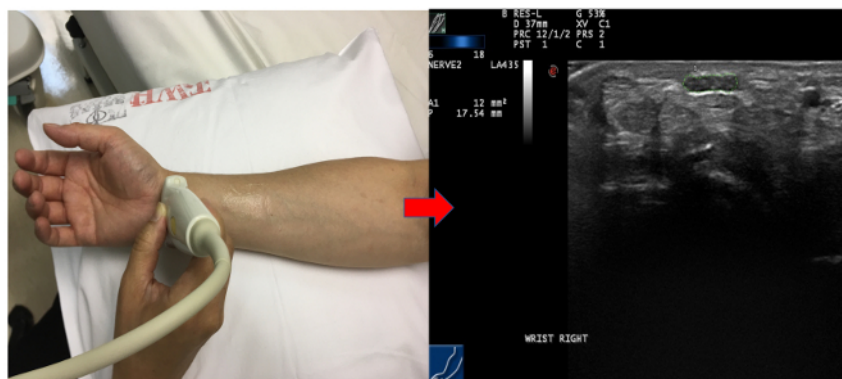


Figure 5: Measurement of the inlet of the carpal tunnel and its ultrasound imaging. [Please click here to view a larger version of this figure.](#)

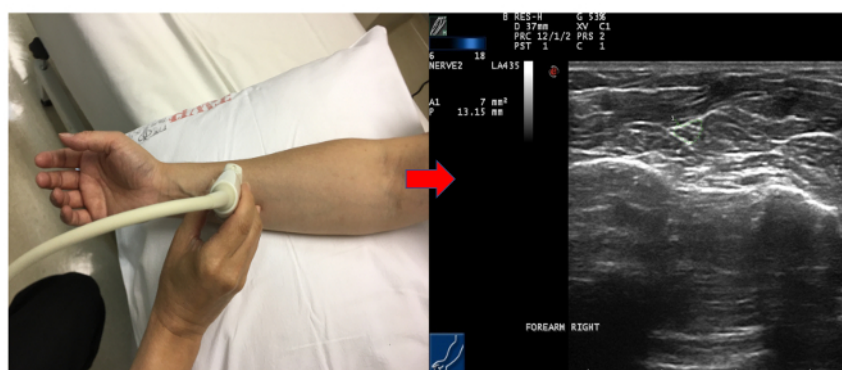


Figure 6: Measurement of the one-third distal forearm and its ultrasound imaging. [Please click here to view a larger version of this figure.](#)

Criteria for determining axonal degeneration according to measurement of nerve conduction studies						
(1) Conduction velocity of the median sensory nerve <42m/s (less than 75% of the lower limit of normal, and/or (2) Distal sensory latency > 4.6 ms or distal motor latency >3.2 ms (more than 130% of the upper limit of normal) (3) Sensory nerve action potential (SNAP) amplitude at the wrist <10 μ V with compound motor action potential (CMAP) amplitude drop \leq 20%; (4) Exclude conditions of CMAP amplitude drop >20%, which may be indicative of temporal dispersion and/or conduction block (CMAP amplitude drop >50%)						
Criteria for determining axonal degeneration according to ultrasound measurement						
	Cut-off values	Accuracy	Sensitivity (%)	Specificity (%)	Positive Predictive Value (%)	Negative Predictive Value (%)
(1) CSA(mm ²)	12	0.71	80%	48.90%	75.90%	45.10%
(2) P(mm)	16.27	0.748	88.60%	51.10%	85.20%	41.50%
(3) R-CSA	1.85	0.725	85.70%	48.90%	81.50%	43.40%
(4) R-P	1.48	0.676	80%	40%	72%	49.10%
(5) Δ CSA(mm ²)	6.98	0.758	77.10%	62.20%	77.80%	38.60%
(6) Δ P(mm)	5.77	0.717	80%	46.70%	80.60%	36.40%

Table 1: Criteria for determining axonal degeneration associated with carpal tunnel syndrome by nerve conduction studies and ultrasound. Remarks: R-CSA or R-P = CSA or P at the wrist/CSA or P at the one-third distal forearm; Δ CSA or Δ P = CSA or P at the wrist minus CSA or P at the one-third distal forearm.

	Group A(n1=45)	Group B(n2=35)	Group C(n3=46)
Demographics			
Gender#			
Female	35	31	45
Male	10	4	1
Age	58.58(8.44)	65.4(7.96)*	58.98(7.08)
Handedness			
Right	23	20	23
Left	22	15	23
Severity grade*			
Mild	20	9	29
Mild to moderate	8	0	4
Moderate	14	7	7
Moderate to severe	1	6	5
Severe	2	13	1
Nerve Conduction Studies			
Median Motor Nerve	Group A	Group B	Group C
Palmar DML	1.99(.27)	2.1(.21)	1.92(.23)
Palmar CMAP	8.46(2.51)	7.68(2.26)	8.91(2.4)
Wrist ML	4.74(1.13)	6.25(1.62)*	4.5(1.5)
Wrist CMAP	8.32(2.5)	7(2.0)#	8.12(2.72)
Wrist MCV	27.28(7.46)	20.4(6.17)*	33.32(11.15)
Median Sensory nerve	Group A	Group B	Group C
DSL	3.22(.43)	3.61(.46)*	2.82(.68)
SNAP	12.82(4.41)	6.21(2.23)*	13.77(4.93)
SCV	36.39(6.3)	33.74(4.23)	46.02(6.26)
Ultrasound Measurements			
Ultrasound parameters	Group A	Group B	Group C
CSA(mm2)	12.5(4.0)	16.54(6.81)*	14.18(3.55)
P(mm)	16.71(2.86)	19.64(4.08)*	18.31(2.5)
R-CSA	2.03(0.67)	2.79(1.01)*	2.69(.74)
R-P	1.63(.39)	1.9((0.47)*	1.84(.26)
ΔCSA(mm2)	6.17(3.76)	10.4(6.13)*	8.73(2.97)
ΔP(mm)	6.22(3.28)	9.08(4.04)*	8.25(1.99)
*<0.01;#<0.05;			
DML(ms): distal motor latency, CMAP(mV): compound motor action potential, ML(ms): Motor latency; MCV(m/s): motor conduction velocity; MCV: motor conduction velocity; DSL(ms): distal sensory latency; SNAP(μV): sensory nerve action potential; SCV(m/s): sensory conduction velocity ;W-CSA(mm2): wrist cross-sectional area, W-P (mm): wrist perimeter; R-CSA: ratio of cross sectional area of wrist over one third distal forearm, R-P: ratio of perimeter of wrist over one third distal forearm, ΔCSA (mm2): changes of cross-sectional area from wrist to one third distal forearm, ΔP (mm): changes of perimeter from wrist to one third distal forearm			

Table 2: Demographics and performance of nerve conduction studies and ultrasound measurements of the enrolled subjects.

Discussion

It is challenging to set up a universal standard for the measurement of NCS due to the influence of demographic and physical factors such as age, gender, ethnicities, and body weight, *etc.*¹⁴. Regarding SNAP amplitude, there is a difference between the orthodromic (the direction of current runs proximally toward the body) and antidromic (the direction of current runs distally away from the body) technique, as the SNAP amplitude measured by the orthodromic method is smaller than the antidromic method¹⁵. In our laboratory, orthodromic stimulation has generally

been applied clinically such that we set 10 μ V as the cut-off value of determining axonal damage. A higher SNAP amplitude is required should the antidromic technique be applied.

On the other hand, for the measurement of ultrasound, we took the inlet of the carpal tunnel and the one-third distal forearm as the bony markers for measurement. These measurement sites were consistent with previous studies, bearing a comparatively higher accuracy for diagnosing the disease^{3,4,8,16,17,18}, which may also increase the accuracy of discrimination consequently, increase the accuracy of discrimination. In addition, one of the most innovative aspects of this method is that the cut-off values of the ultrasound parameters can take a complementary role when the electric signal of NCS is absent or did not fulfill the NCS criteria for differentiation as they displayed overall satisfactory sensitivity and specificity in a previous study⁹. Compared to previous cut-off values identified for severity gradation^{8,19,20}, these cut-off values are believed to be more indicative clinically for treatment prescription as they can reflect pathological progress beyond the conventional severity grade.

Nevertheless, there are also constraints using this method. First, the specificity is inferior to the sensitivity in this protocol, as can be seen from the ultrasound findings among subjects in group C, all of which were considered with potential associated axonal degeneration based on the ultrasound cut-off readings. This can be explained as we have not yet established a concrete assessment package to confirm axonal degeneration based on various ultrasound parameters. Besides, the nature of ultrasound imaging also cannot directly display axonal degeneration. It still relies on the golden standard test to confirm axonal degeneration. Also, there is yet no universal agreement upon NCS criteria for discriminating axonal degeneration⁹. Further studies are required to examine its reliability by comparison with the golden standard test. Despite these limitations, we still propose this method as an efficient screening approach as it can quickly inform clinicians at an early stage in a noninvasive manner, thus avoiding deterioration.

Bearing overall satisfactory accuracy, sensitivity, and specificity, the combinative use of ultrasound and NCS cannot only compensate for technical pitfalls of NCS (absent signals, etc.) by providing anatomical and structural information, but also it can disclose or identify the pathological progress lying underneath. This method can be applied easily in routine clinical practice for the initial screening of the potential coexistence of axonal degeneration associated with CTS. A more refined plan of care can be attainable using this method.

Disclosures

The authors have nothing to disclose.

Acknowledgements

Mr. Xue Deng, Dr. Yong Hu, and Dr. Ip Wing-Yuk were dedicated to the concept of the study design, subject recruitment, and draft and revision of the manuscript. Ms. Lai-Heung Phoebe Chau and Ms. Suk-Yee Chiu were dedicated to subject liaison, data collection, and the manipulation of NCS. Dr. Kwok-Pui Leung was dedicated to the electrophysiological diagnosis, clinical guidance, and the manipulation of the ultrasounds.

References

- Caetano, M. R. Axonal degeneration in association with carpal tunnel syndrome. *Arquivos de Neuro-Psiquiatria*. **61** (1), 48-50 (2003).
- Werner, R. A., Andary, M. Electrodiagnostic evaluation of carpal tunnel syndrome. *Muscle Nerve*. **44** (4), 597-607 (2011).
- Duncan, I., Sullivan, P., & Lomas, F. Sonography in the diagnosis of carpal tunnel syndrome. *AJR. American journal of roentgenology*. **173** (3), 681-684 (1999).
- Miyamoto, H. *et al.* Carpal Tunnel Syndrome- Diagnosis by Means of Median Nerve Elasticity-Improved Diagnostic Accuracy of US with Sonoelastography. *Radiology*. **270** (2), 481-486 (2014).
- Azami, A. *et al.* The diagnostic value of ultrasound compared with nerve conduction velocity in carpal tunnel syndrom. *International Journal of Rheumatic Diseases*. **17**, 612-620 (2014).
- Altinok, T. *et al.* Ultrasonographic assessment of mild and moderate idiopathic carpal tunnel syndrome. *Clinical Radiology*. **59**, 916-925 (2004).
- Zhang, L. *et al.* Does the ratio of the carpal tunnel inlet and outlet cross-sectional areas in the median nerve reflect carpal tunnel syndrome severity? *Neural Regeneration Research*. **10** (7), 1172-1176 (2015).
- Klauser, A. S. *et al.* Sonographic cross-sectional area measurement in carpal tunnel syndrome patients: can delta and ratio calculations predict severity compared to nerve conduction studies? *European Radiology*. **25** (8), 2419-2427 (2015).
- Deng, X. *et al.* Exploratory use of ultrasound to determine whether demyelination following carpal tunnel syndrome co-exists with axonal degeneration. *Neural Regeneration Research*. **13** (2), 317-323 (2018).
- Moon, H. I., Kwon, H. K., Lee, A., Lee, S. K., Pyun, S. B. Sonography of Carpal Tunnel Syndrome According to Pathophysiologic Type: Conduction Block Versus Axonal Degeneration. *Journal of Ultrasound in Medicine*. **36** (5), 993-998 (2017).
- Razek, A. A. K. A., Shabana, A. A. E., El Saied, T. O., Alrefey, N. Diffusion tensor imaging of mild-moderate carpal tunnel syndrome-correlation with nerve conduction study and clinical tests. *Clinical Rheumatology*. **36** (10), 2319-2324 (2017).
- Weber, F. Conduction block and abnormal temporal dispersion--diagnostic criteria. *Electroencephalography and Clinical Neurophysiology*. **37** (5), 305-309 (1997).
- Kiernan, C. M., Mogyoros, I., Burke D. Conduction block in carpal tunnel syndrome. *Brain*. **122** (5), 933-941 (1999).
- Fong, S. Y., Goh, K. J., Shahrizaila, N., Wong, K. T., Tan, C. T. Effects of demographic and physical factors on nerve conduction study values of healthy subjects in a multi-ethnic Asian population. *Muscle Nerve*. **54** (2), 244-248 (2016).
- Valls-Sole, J., Leote, J., Pereira, P. Antidromic vs orthodromic sensory median nerve conduction studies. *Clinical Neurophysiology Practice*. **1**, 18-25 (2016).
- Wong, S. M., Griffith, J. F., Hui, A. C., Tang, A., Wong, K. S. Discriminatory sonographic criteria for the diagnosis of carpal tunnel syndrome. *Arthritis & Rheumatology*. **46** (7), 1914-1921 (2002).

17. Mondelli, M., Filippou, G., Gallo, A., Frediani, B. Diagnostic utility of ultrasonography *versus*. nerve conduction studies in mild carpal tunnel syndrome. *Arthritis & Rheumatology*. **59** (3), 357-366 (2008).
18. Wong, S. M. *et al.* Carpal tunnel syndrome: diagnostic usefulness of sonography. *Radiology*. **232** (1), 93-99 (2004).
19. Baiee, R. H., AL-Mukhtar, N. J., Al-Rubiae, S. J., Hammoodi, Z. H., Abass, F. N. Neurophysiological Findings in Patients with Carpal Tunnel Syndrome by Nerve Conduction Study in Comparing with Ultrasound study. *Journal of Natural Sciences Reserach*. **5** (16), 111-128 (2015).
20. Filius, A. *et al.* Multidimensional ultrasound imaging of the wrist: Changes of shape and displacement of the median nerve and tendons in carpal tunnel syndrome. *Journal of Orthopaedic Research*. **33** (9), 1332-1340 (2015).