

Video Article

A Case Series of Successful Abdominal Closure Utilizing a Novel Technique Combining a Mechanical Closure System with a Biologic Xenograft That Accelerates Wound Healing

Yana Puckett¹, Virginia Tran¹, Michelle Estrada¹, Shirley McReynolds¹, Catherine A. Ronaghan¹

¹Department of Surgery, Texas Tech University Health Sciences Center

Correspondence to: Yana Puckett at [yana.puckett@ttuhsc.edu](mailto: yana.puckett@ttuhsc.edu)

URL: <https://www.jove.com/video/57154>

DOI: [doi:10.3791/57154](https://doi.org/10.3791/57154)

Keywords: ABRA, abdominal wall closure, biologic xenograft, abdominal compartment syndrome, open abdomen

Date Published: 12/16/2018

Citation: Puckett, Y., Tran, V., Estrada, M., McReynolds, S., Ronaghan, C.A. A Case Series of Successful Abdominal Closure Utilizing a Novel Technique Combining a Mechanical Closure System with a Biologic Xenograft That Accelerates Wound Healing. *J. Vis. Exp.* (), e57154, doi:10.3791/57154 (2018).

Abstract

In the acute setting, once intra-abdominal injuries have been addressed, the next great hurdle is restoring a functional and intact abdominal compartment. The short and long-term consequences of living with a chronically open abdominal compartment include pulmonary, musculoskeletal, gastrointestinal, and emotional disability. The closure of catastrophic open abdominal wounds presents a challenge to the surgeon. We present a technique utilizing a mechanical abdominal closure device in conjunction with biologic xenograft in closing complex open abdominal wounds. This technique offers another option for definitive fascial closure and accelerated wound healing in this difficult patient population. The dynamic tissue system (DTS) is installed after control of original intraabdominal pathology. A porcine urinary bladder matrix is then placed in the subcutaneous space once fascial closure is achieved. Overall, primary myofascial closure was achieved in 100% of patients at a mean of 9.36 days.

Video Link

The video component of this article can be found at <https://www.jove.com/video/57154/>

Introduction

The increasing prevalence of abdominal compartment syndrome has led to an emergence of various temporary abdominal closure (TAC) techniques¹. TAC is performed to prevent evisceration, assist in the removal of unwanted intraperitoneal fluid, minimize intra-abdominal complications, and expedite the closure of the abdominal cavity². Closure of an open abdomen facilitates restoration of normal physiology in the patient³. Prolonged duration of an open abdomen results in complications such as fistula formation and an inability to close the abdomen⁴. There are several methods to achieve final closure of an open abdomen.

The simplest way to temporarily close an abdomen is by using towel clips to close the skin⁵. One of the most commonly used and studied abdominal closure techniques is negative pressure wound therapy (NPWT)⁵. For the NPWT, a nonadherent barrier to protect the intraabdominal contents is applied followed by a moisture-absorbing sponge-like material, and an outermost adhesive layer to secure the dressing in place, and a negative pressure mechanism⁶. A Bogota bag can also be used for temporary closure of an open abdomen. A Bogota bag is an empty intravenous fluid bag cut in half and sutured to the skin edges⁷. NPWT and the Bogota bag closure are two temporizing measures that facilitate delayed primary closure of the abdominal cavity⁷.

Once the abdomen is deemed ready for closure, different closure methods can be utilized. The simplest way is to apply a split-thickness graft over the omentum once it has formed healthy granulation tissue. If the wound is not contaminated, a nonabsorbable synthetic sheet may be used to bridge the fascial edges⁸. If the fascial gap is less than 14-20 cm in maximal diameter, component separation of the rectus sheath can be performed⁹.

Some abdominal closure techniques allow for gradual reapproximation of the fascial edges and eventual primary closure¹⁰. A Wittmann patch consists of two opposing Velcro sheets that are sutured to each fascial edge¹¹. The opposing sheets are then fastened together in the midline. This mechanism allows easy re-entry into the abdomen and adjustment for abdominal compartment pressures. Additionally, this can also provide midline traction on the fascial edges that can prevent retraction of the fascial edges and also facilitate primary closure of the fascia.

Alternatively, a dynamic tissue system (DTS) is available and is part of the technique described in this paper. The described DTS is composed of a silicone viscera protector that is applied over abdominal contents to prevent adhesions and adherence of viscera to the abdominal wall. Adjustable elastomers then penetrate the full abdominal wall thickness on each side and provide medial tension on the wound edges (**Figure 1**). A product composed of urinary porcine bladder extracellular matrix can be placed in the subcutaneous space once fascial closure is achieved

(**Figure 2**). Matrix placement in the subcutaneous space augments and expedites wound healing through angiogenesis, innervation, modulation of the inflammatory response, and resistance to infection¹².

In this study, we describe a novel technique of primary abdominal closure following abdominal compartment syndrome utilizing a dynamic closure system and a biologic xenograft. At our level I trauma and acute care center, abdominal compartment syndrome is a common diagnosis. Prior to utilization of this novel method, most catastrophic open abdomens were not amenable to primary closure and a skin graft was placed over the viscera or biologic mesh. Since the adoption of this method in May of 2016, we have closed 100% of open abdomens due to abdominal compartment syndrome in a high-risk patient population (average BMI 40.45, SD 9.83) (**Table 1**).

Protocol

Institutional approval was obtained. Participants and/or their surrogate medical decision maker signed consent, allowing pictures and inclusion of non-identifying patient information for educational purposes.

1. Installation of Dynamic Tissue System

1. Bring the patient to the operating room and induce general anesthesia. Drape and prepare the patient for the procedure according to hospital policy.
 1. Exclude if there is hemodynamic instability, a need for further abdominal washouts, or a concern for intra-abdominal sepsis.
2. Apply antimicrobial incise drape to the skin of the abdomen widely, covering the operating field.
3. Wash the abdomen out with at least 2 L of 40.5 °C normal saline.
4. Measure and record the myofascial gap, visceral extrusion, and length of incision in centimeters for documentation of progress on the operative note.
5. Examine the ostomy site prior to application of the device.
6. Mark the skin of the anterior abdominal wall 5 cm laterally from medial fascial edge to create an ellipse around the midline wound.
7. Use the puncture device included in the dynamic tissue system kit to puncture through the abdominal wall at the 5 cm mark, taking care not to injure the abdominal viscera. Use the "yellow fish" visceral protector included in the kit in addition to the malleable protector.
8. Place the elastomer buttons side by side on the ellipse created in step 1.6 with the "U" of the elastomer at the 5 cm ellipse demarcation around the midline wound.
9. Pull the elastomer through the abdominal wall using the puncture device.
10. Repeat the same steps on the opposite side. This time, pull the elastomer across abdominal wall over the visceral protector and connect to the elastomer button on the opposite side.
11. Loosely attach the elastomer bands to the elastomer buttons. Do not tighten elastomer bands.
12. Place elastomer adhesion stickers on the buttons.
13. Perform the osteopathic maneuver twice. This is performed with two people standing on either side of the patient. Apply bi-manual forces at the skin level, pushing towards the midline and creating circular motions synchronized with the other operator first towards the head and then creating circular motions in the opposite directions towards the feet.

2. Silicone Visceral Protector Inserted

1. Insert silicone visceral protector midline over abdominal viscera, taking care to protect any ostomies (**Figure 3**).
2. Envelop the abdominal viscera with silicone visceral protector down to each gutter of abdominal quadrants.
3. Create necessary cut outs in the visceral protector with scissors to protect the ostomies.
4. Fold the cut outs to avoid sharp edges next to the ostomy.
5. Place elastomer retainer in the midline on top of visceral protector and evenly space elastomer bands into the retainer.
6. Tighten elastomer bands.
7. Perform the osteopathic maneuver.
8. Record the myofascial gap with a ruler in centimeters (**Figure 4**).

3. Installation of Negative Pressure Wound Therapy Device

1. Make negative pressure wound therapy device sponge as thin as possible and place in the midline above the elastomer retainer (**Figure 5**).
 2. Cover with vacuum drape tape and apply the negative pressure device with continuous suction at -100 mmHg.
 3. Perform the osteopathic maneuver twice.
 4. Record myofascial gap and visceral extrusion (**Figure 6**).
- NOTE: The midline wound is left in the negative pressure wound therapy device.

4. Elastomer Adjustment

1. Bring the patient back to the operating room 48 hours after the initial installation of the DTS for elastomer adjustment.
2. Remove the negative pressure wound therapy device overlying the midline wound with scissors, taking care to leave the drapes on the skin intact.
3. Prep the abdomen widely including the elastomers in place with 4% chlorhexidine gluconate.
4. Perform osteopathic maneuvers twice. See step 1.13 for details.
5. Record the myofascial gap and the myofascial apposition (**Figure 6**).
6. Irrigate the midline wound with 2 L of 40.5 °C normal saline, taking care not to spill water on the DTS or antimicrobial incision drape.

7. Adjust elastomers by releasing the elastomer from the anchor and pulling each elastomer laterally, away from the midline.
8. Reapply the negative pressure wound therapy device.

5. Fascial Closure

1. Bring the patient back to the operating room.
2. Remove all of the elastomer buttons and elastomers.
3. Gently peel the antimicrobial incise drape off the skin, taking care not to injure the epidermis.
4. Remove the visceral protector and elastomer retainer and irrigate the abdominal cavity with 3 L of normal saline.
5. Close the fascia in an interrupted Smead-Jones fashion with No. 2 vicryl suture on a cutting needle.
6. Irrigate and dry the midline wound.
7. Apply wound matrix powder to the midline wound and evenly distribute the powder so that every surface is covered with the powder.
8. Apply two-layer wound matrix sheet on top of the powder to cover the entire surface of midline wound (**Figure 7**).
9. Bring the midline wound together with vacuum drape tape (**Figure 8**).

Representative Results

We have analyzed a total of 11 patients so far with catastrophic open abdomens. Primary myofascial closure was achieved at a mean of 9.36 days. We had 0% surgical site infections (SSI) and achieved 100% primary myofascial closure. No enteroatmospheric fistula resulted in this technique, unless present prior to this DTS and xenograft approach. Since May 2016, zero open abdomens were left open or covered with a skin graft (**Figure 9**).

The results of this study show that the use of mechanical closure device system with urinary bladder matrix achieved closure in 100% of the patients with catastrophic abdomens. The system provides dynamic, and therefore more physiologic, appositional traction from the fascial layer up to the skin using elastomers. A recent meta-analysis that included 251 studies and 13,650 patients showed that negative pressure wound therapy with continuous fascial traction (with either mesh or tension sutures) had the highest weighted rate of definitive fascial closure of 76% in 26 series^{12,13,14}. The weighted definitive fascial closure rates were 75% with the Wittman patch (8 series), 73% with the dynamic retention sutures (5 series), 54% with negative pressure wound therapy alone (106 series), 50% with loose packing (25 series), 25% with zipper (14 series), 39% with mesh (43 series), and 37% with Bogota bag (24 series)¹².

Although our institution did not close septic patients with this technique, an 18-patient study evaluating the use of the DTS system in closing open abdomen in septic patients showed successful closure in 88% of the studied patients¹⁴. The mean number of days the DTS stayed in place until closure in the aforementioned studies ranged from 10 to 48 days^{12,13,14,15}.

Our study only included 11 patients, three of whom had ostomies in place. Our technique achieved 100% closure rate with an average of 9.36 days from DTS application to fascial closure. The use of a xenograft matrix allowed closure of the cutaneous wound after fascial closure despite our study population having an average BMI of 40. The results of our study conclude that the use of the dynamic tissue system achieves excellent results in definitive closure of open abdomen.

	Mean	Standard Deviation
Age (years)	48.11	10.03
BMI (kg/m ²)	40.45	9.83
Visceral Extrusion (cm)	6.8	1.57
Incision Length (cm)	26.55	10.13
Days to Closure of Fascia	9.36	4.18
Adjustments of DTS Prior to Closure (Days)	1.82	0.98
Days Abdomen Open Before DTS Application	8	9
Myofascial Gap Before DTS Application (cm)	18	6
Myofascial gap after DTS Application (cm)	9.06	2.04

Table 1. Review of 11 patients that underwent novel dynamic tissue system closure with biologic xenograft placement to midline wound at a single trauma I center.

Reasons for Open Abdomens at Our Institution	
1.	Obstructing rectal cancer with gangrenous colon
2.	Exploratory laparotomy x2, Aortic dissection status post thoracic endovascular aortic repair, open gastrostomy, splenectomy, colectomy
3.	Severe Acute Hemorrhagic Pancreatitis with Colopancreatic Fistula
4.	Auto versus pedestrian, abdominal compartment syndrome, splenic Laceration, acetabular fracture, bladder injury with suprapubic cystostomy
5.	Incisional hernia, Crohn's disease, small bowel obstruction
6.	Enteroatmospheric fistula, skin grafted open abdomen after prostatectomy
7.	Motor vehicle crash, splenectomy, paraplegia from cervical spine Injury, small bowel obstruction, gastrojejunostomy, partial Abdominal Closure, pulmonary Embolus
8.	Abdominal compartment syndrome (due to excessive crystalloid resuscitation and delay in definitive management of massive upper gastrointestinal hemorrhage)
9.	Incisional hernia with loss of domain and obstructing jejunal adenocarcinoma
10.	Diverticulitis, attempted Hartmann's reversal, massive venous hemorrhage

Table 2: Reasons for open abdomens and abdominal compartment syndromes at our level I trauma center.

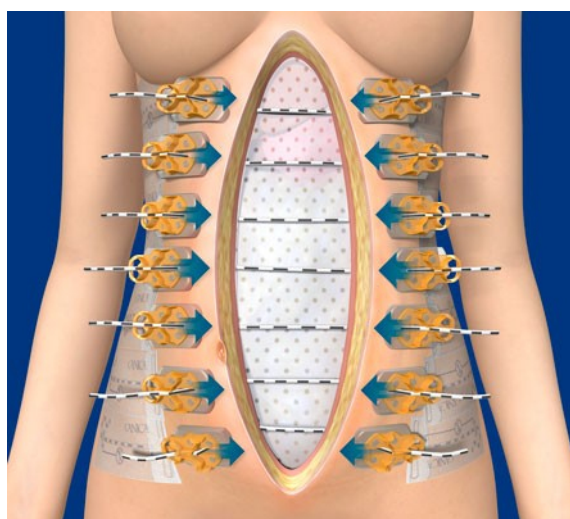


Figure 1: Dynamic Tissue System (DTS).




Figure 2: Urinary bladder extracellular matrix comes in wound sheet and wound powder. The powder and sheet are combined together to accelerate and expedite wound healing.

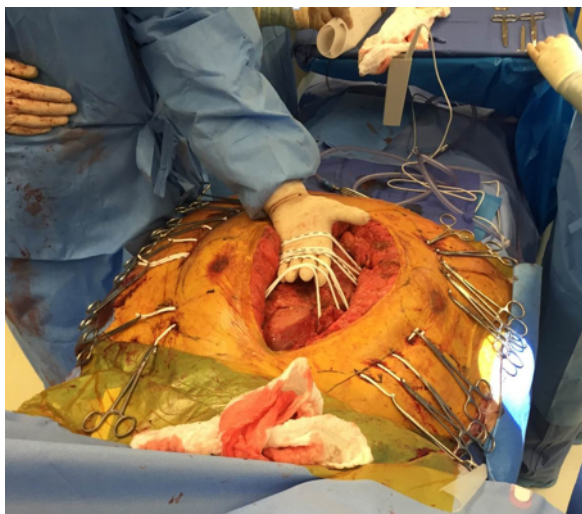

Figure 3: Abdominal visceral protector is in place, the elastomer holes have been made with puncture device, and then elastomer bands pulled through on each side. Hemostats are placed on elastomers to avoid pull through the abdominal wall. Note the abdominal wall markings of an ellipse. The elastomer bands are gathered loosely at midline ready to place an elastomer retainer.

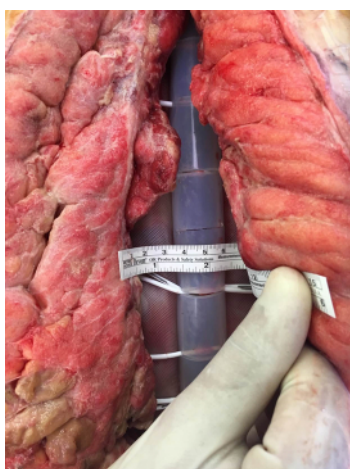


Figure 4: The elastomer retainer is placed in midline above visceral protector. Elastomer bands are then placed in the elastomer retainer. Myofascial gap is then recorded.

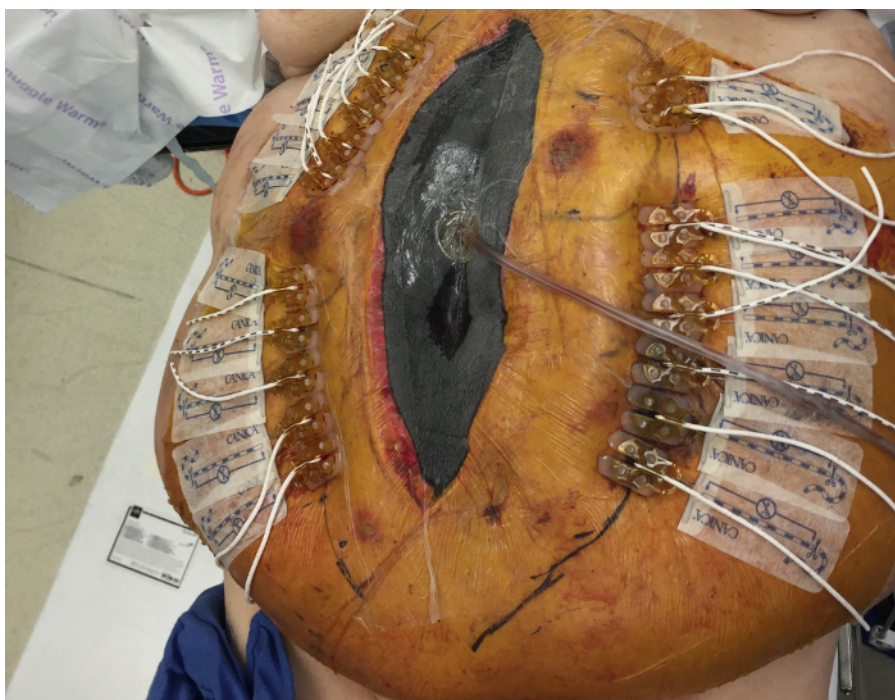


Figure 5: Negative pressure wound therapy device is applied and connected to suction. [Please click here to view a larger version of this figure.](#)

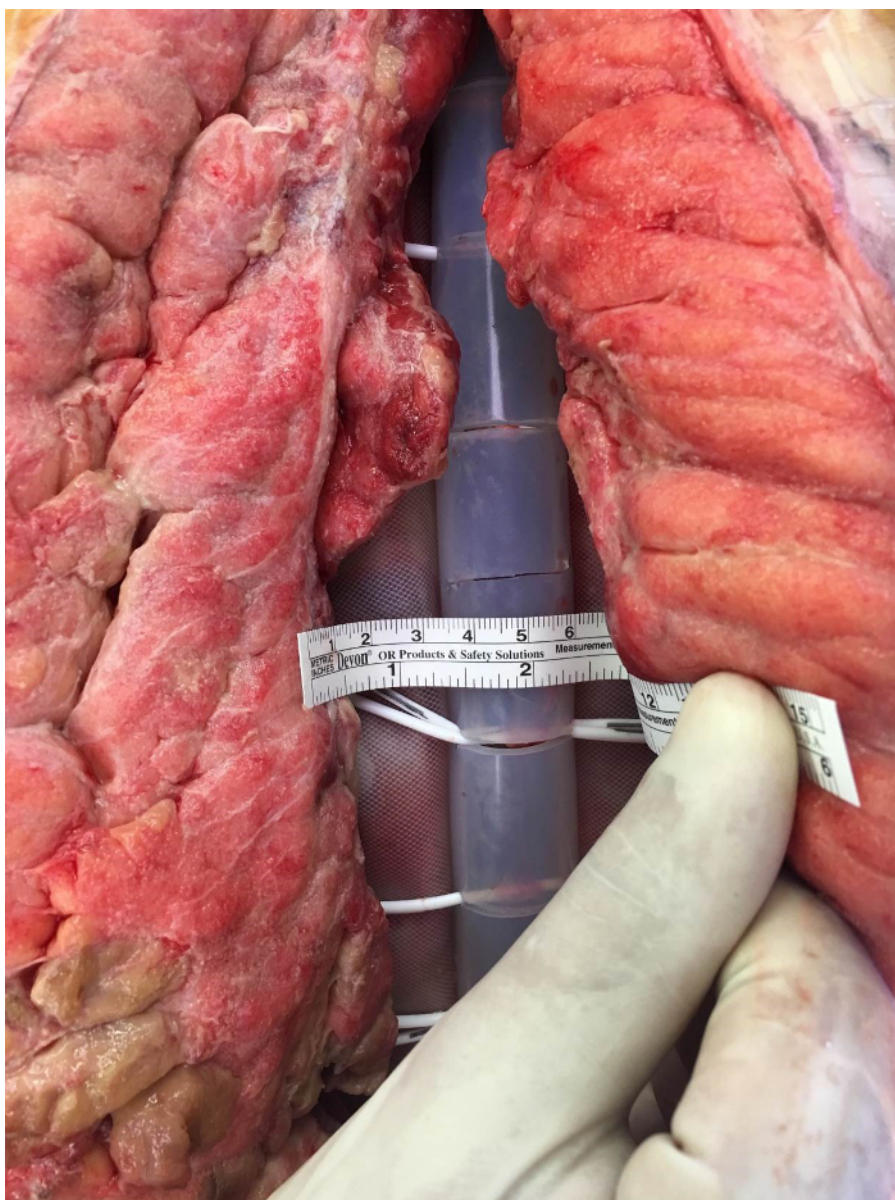


Figure 6: Elastomers are adjusted in 48 hours after initial DTS installation and myofascial gap is measured and recorded. [Please click here to view a larger version of this figure.](#)

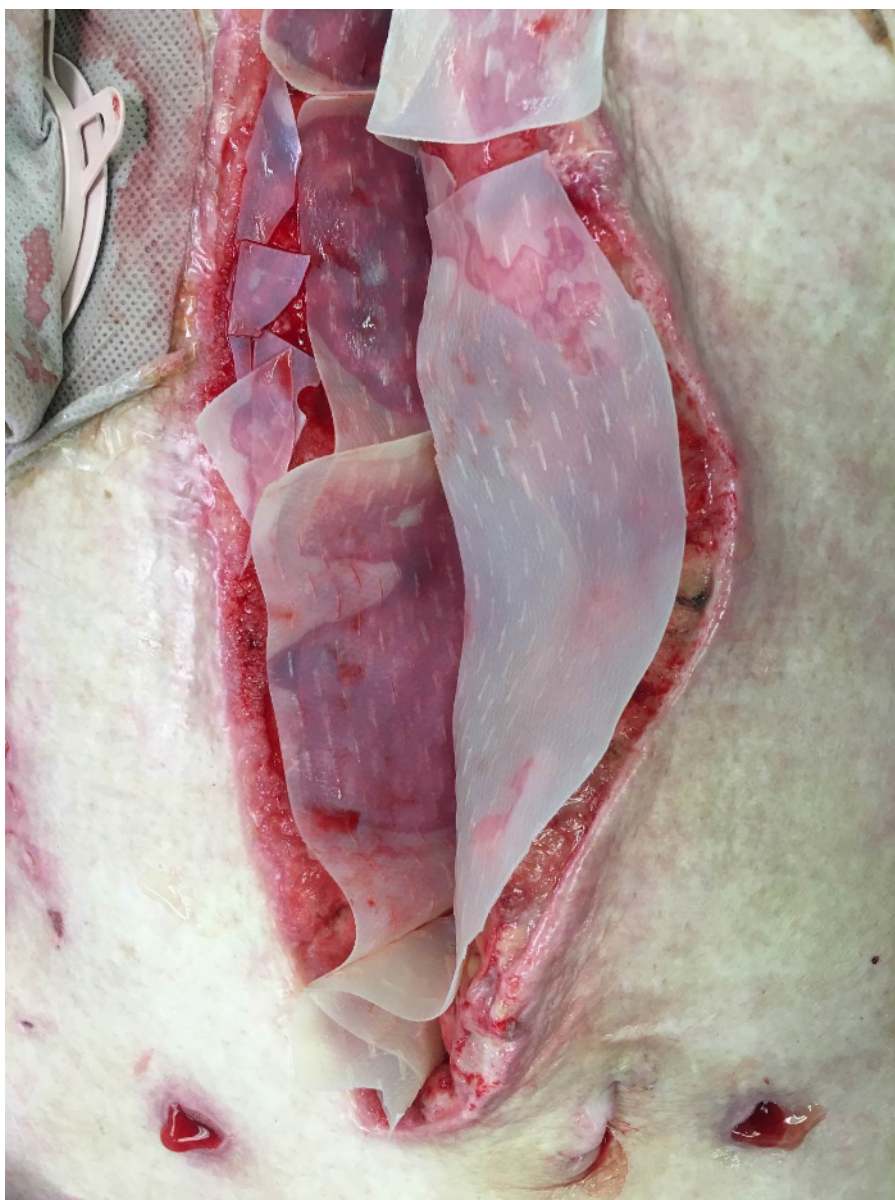


Figure 7: Fascia is closed and wound matrix powder and sheet is laid in midline. [Please click here to view a larger version of this figure.](#)

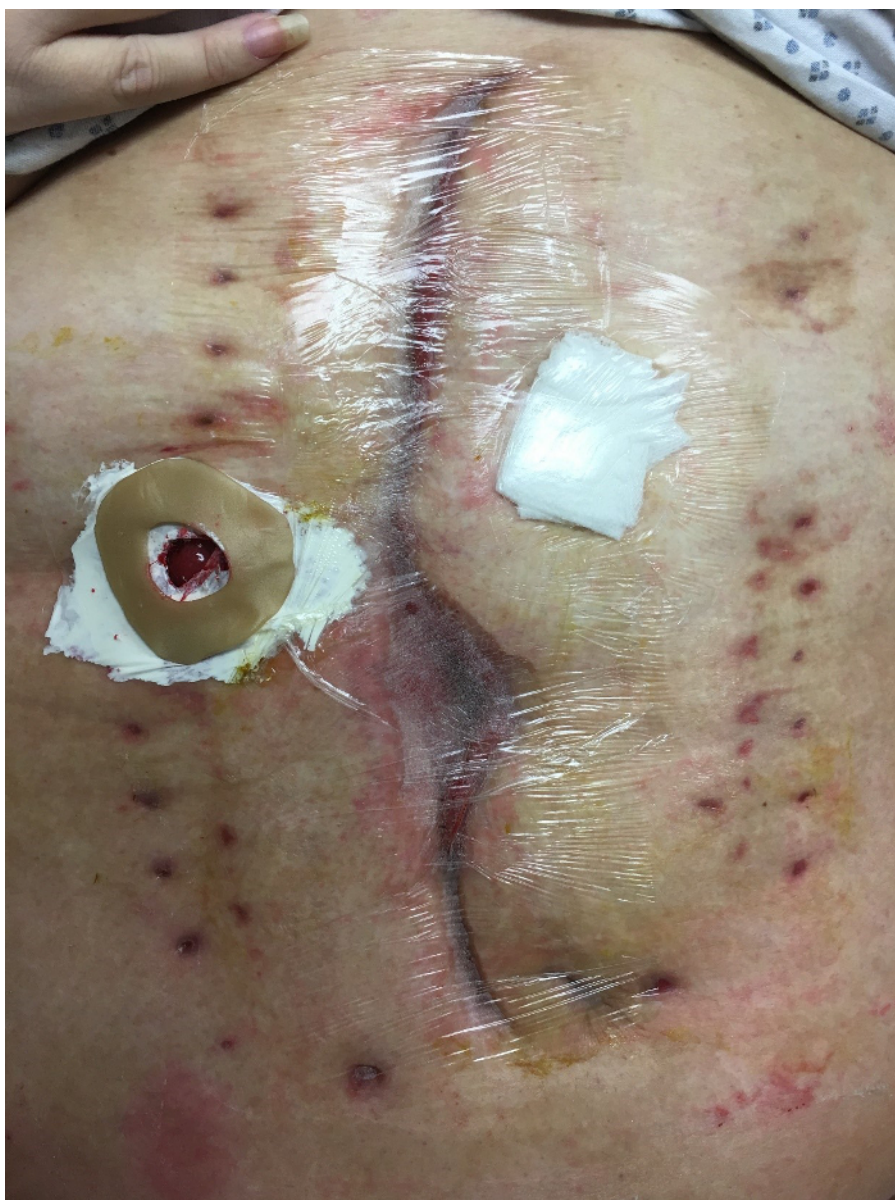

Figure 8: Midline wound is brought together with vacuum drape tape that has been cut into 2 inch strips across abdominal wall. Ostomy appliance is then applied. [Please click here to view a larger version of this figure.](#)

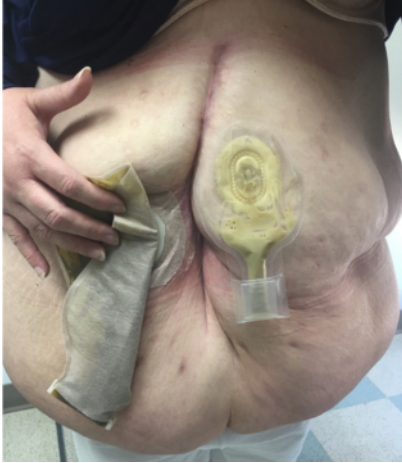

Figure 9: Same patient that survived severe necrotizing pancreatitis with abdominal compartment syndrome is shown above at her six weeks clinic follow-up appointment. Midline wound is completely healed. Fascia is intact and no hernia is palpable. Her fascia was closed after 10 days of having an open abdomen.

Discussion

The most critical step of the protocol for closing a complex abdominal wound is performing osteopathic maneuvers before elastomer placement, after elastomer placement, and before and after elastomer adjustments. In addition, we perform osteopathic maneuvers on these patients after surgery three times a day. Our approach describes the use of the osteopathic maneuver prior and after the elastomers tightening. The anecdotal observation has been that these maneuvers aid in fascial approximation. Although we did not record the fascial edges prior and after the osteopathic maneuvers, we do feel that this step is crucial. There are no studies available at the time of this paper on the benefit of osteopathic maneuvers and fascial approximation. A study using a mathematical model found that tangential and compressive forces on the skin are transmitted to the fascial layer¹⁵. This force allows approximation of the fascia.

Another critical step of the protocol is to adjust the elastomer only to twice its length and never to push the abdomen to close sooner than required. At times when abdominal closure was extremely difficult, we paralyzed patients in the intensive care unit with rocuronium and sedatives to keep intraabdominal pressure low. The average time length of paralysis was 3.4 days.

The use of incision tape is a modification of our technique that keeps the surgical site clean and free of infection. This is one of the key reasons our surgical site infection rate was 0% in a patient population at high risk of surgical site infections.

At the present moment, we have not found any limitations to the technique. One limitation that may occur is the cost of dynamic closure system (USD\$5500) and porcine urinary bladder matrix (USD\$1000 per sheet, USD\$1000 per powder bottle). In addition, frequent take backs of patients to the operating room for adjustments and prolonged time in the intensive care unit stay for paralysis add on costs. However, a cost analysis needs to be performed into the quality of life post closure. In addition, our rate of hernia is 0%. Operation on recurrence of hernia, possibility of bowel obstruction, and the return to hospital may need to be factored into cost savings of our protocol.

Future applications of this technique include closure of extremity wounds, fasciotomy wounds, and large traumatic wounds. Future studies need to include cost-analysis of this technique.

Disclosures

Dr. Catherine Ronaghan is an ACeLL cadaver lab proctor and speaker. The rest of the authors have nothing to disclose.

Acknowledgements

The authors have no acknowledgements.

References

1. Kirkpatrick, A.W., *et al.* Update from the Abdominal Compartment Society (WSACS) on intra-abdominal hypertension and abdominal compartment syndrome: past, present, and future beyond Banff 2017. *Anaesthesiology Intensive Therapy*. **49** (2), 83-87 (2017).
2. Yetisir, F., Sarer, A.E., Acar, H.Z., & Aygar, M. Delayed Closure of 61 Open Abdomen Patients Based on an Algorithm. *Indian Journal of Surgery*. **79** (1), 38-44 (2017).
3. Ribeiro Junior, M.A., *et al.* Open abdomen in gastrointestinal surgery: Which technique is the best for temporary closure during damage control? *World Journal of Gastrointestinal Surgery*. **8** (8), 590-597 (2016).
4. Karakose, O., *et al.* Bogota Bag Use in Planned Re-Laparotomies. *Medical Science Monitor*. **22**, 2900-2904 (2016).
5. Lassalle, S., Chechin, C., & de la Forge, D. A new cleansing technique for complex wounds. *Soins*. **62** (814), 12-15 (2017).

6. Strang, S.G., Van Lieshout, E.M., Van Waes, O.J., & Verhofstad, M.H. Prevalence and mortality of abdominal compartment syndrome in severely injured patients: A systematic review. *The Journal of Trauma and Acute Care Surgery*. **81** (3), 585-592 (2016).
7. Bressan, A.K., & Ball, C.G. Intra-abdominal hypertension and abdominal compartment syndrome in acute pancreatitis, hepato-pancreato-biliary operations and liver transplantation. *Anaesthesiology Intensive Therapy*. **49** (2), 159-166 (2017).
8. Muresan, M., *et al.* How much does decompressive laparotomy reduce the mortality rate in primary abdominal compartment syndrome?: A single-center prospective study on 66 patients. *Medicine (Baltimore)*. **96** (5), e6006 (2017).
9. Coccolini, F., *et al.* IROA: International Register of Open Abdomen, preliminary results. *World Journal of Emergency Surgery*. **12**, 8 (2017).
10. Lecheminant, J., & Field, C. Porcine urinary bladder matrix: a retrospective study and establishment of protocol. *Journal of Wound Care*. **21** (10), 80, 482 (2012).
11. Coccolini, F., *et al.* IROA: International Register of Open Abdomen, preliminary results. *World Journal of Emergency Surgery*. **12**, 8 (2017).
12. Muturi, A., Ndaguatha, P., Ojuka, D., & Kibet, A. Prevalence and predictors of intra-abdominal hypertension and compartment syndrome in surgical patients in critical care units at Kenyatta National Hospital. *BMC Emergency Medicine*. **17** (1), (2017).
13. Okullo, A., *et al.* The Abdominal Reapproximation Anchor Device. *Surgical Innovation*. **24** (1), 49-54 (2017).
14. Yetisir, F., Sarer, A.E., Acar, H.Z., & Aygar, M. Delayed Closure of 61 Open Abdomen Patients Based on an Algorithm. *Indian Journal of Surgery*. **79** (1), 38-44 (2017).
15. Chaudhry, H., Bukiet, B., Zhiming J., Stecco, A., & Findley T. Deformations experienced in the human skin, adipose tissue, and fascia in osteopathic manipulative medicine. *The Journal of the American Osteopathic Association*. **114** (1), 780-7 (2017).