

Science Education Collection

Cardiac Exam II: Auscultation

URL: <https://www.jove.com/science-education/10124>

Overview

Source: Suneel Dhand, MD, Attending Physician, Internal Medicine, Beth Israel Deaconess Medical Center

Proficiency in the use of a stethoscope to listen to heart sounds and the ability to differentiate between normal and abnormal heart sounds are essential skills for any physician. Correct placement of the stethoscope on the chest corresponds to the sound of cardiac valves closing. The heart has two main sounds: S1 and S2. The first heart sound (S1) occurs as the mitral and tricuspid valves (atrioventricular valves) close after blood enters the ventricles. This represents the start of systole. The second heart sound (S2) occurs when the aortic and pulmonary valves (semilunar valves) close after blood has left the ventricles to enter the systemic and pulmonary circulation systems at the end of systole. Traditionally, the sounds are known as a "lub-dub."

Auscultation of the heart is performed using both diaphragm and bell parts of the stethoscope chest piece. The diaphragm is most commonly used and is best for high-frequency sounds (such as S1 and S2) and murmurs of mitral regurgitation and aortic stenosis. The diaphragm should be pressed firmly against the chest wall. The bell best transmits low-frequency sounds (such as S3 and S4) and the murmur of mitral stenosis. The bell should be applied with a light pressure.

Procedure

1. Position the patient at 30-45 degrees.
2. Make sure the area being examined is exposed, and never auscultate through the gown.
3. Place the stethoscope in the defined anatomical landmarks (**Figure 1**). A good rule of thumb to find the second intercostal space is to locate the angle of Louis (manubriosternal joint), which is at this level. Palpate across and down with your fingers to locate the other intercostal spaces described.

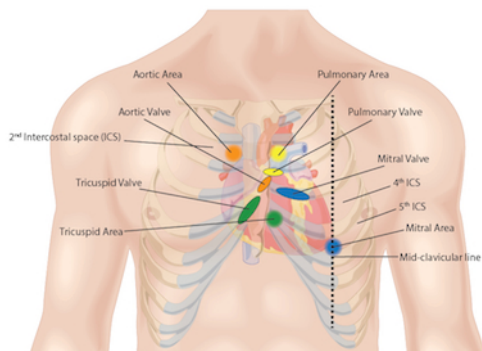


Figure 1. Auscultation surface landmarks.

1. Aortic area
 1. Place the diaphragm of the stethoscope at the 2nd intercostal space, right sternal edge. This is the anatomical landmark for the aortic valve.
 2. Listen for at least 5 sec for the second heart sound, which represents the aortic valve closing.
2. Pulmonic area
 1. Place the diaphragm of the stethoscope at the 2nd intercostal space, left sternal edge. This is the anatomical landmark for the pulmonary valve.
 2. Listen for at least 5 sec for the second heart sound, which represents the pulmonary valve closing.
3. Tricuspid area
 1. Place the diaphragm of the stethoscope at the 4th - 5th intercostal space, left sternal edge. This is the anatomical landmark for the tricuspid valve.
 2. Listen for at least 5 sec for the first heart sound, which represents the tricuspid valve closing.
4. Mitral area
 1. Place the diaphragm of the stethoscope at the 5th intercostal space, mid-clavicular line (same area as the apex beat). This is the anatomical landmark for the mitral valve.
 2. Listen for at least 5 sec for the first heart sound, which represents the mitral valve closing.

4. Other auscultation areas:

Auscultation of the lungs and major arteries also provides essential information of the function of the cardiovascular system.

1. Auscultate with the diaphragm of the stethoscope at the bases of the lungs. Listen for any crepitations or crackles, which indicate fluid in the lungs (pulmonary edema), a sign of heart failure.
2. Auscultate with the bell of the stethoscope at the carotid arteries. Frequently, a murmur that is present from the aortic valve may be heard. Also, auscultate here for a bruit (a swishing sound produced by turbulent blood flow), which is a sign of carotid artery stenosis.
3. Auscultate for abdominal bruits at the renal arteries and femoral arteries to assess for peripheral vascular disease.

Summary

Auscultation of the heart remains one of the fundamental skills for any clinician to master, and it provides vital diagnostic clues to many cardiac abnormalities. Learning the correct technique for auscultation is essential in order to distinguish the normal from the pathological. All cardiac areas must be auscultated in a structured and methodical fashion. The physical findings should be interpreted with respect to the cardiac cycle, and the intensity, duration, pitch, and timing of each sound should be noted. It is essential to memorize the anatomical landmarks where the stethoscope should be placed on the patient's chest, and always examine the patient in a quiet environment. It is important to listen for at least 5 sec, while the patient is breathing normally, to avoid one of the common mistakes made during the physical exam - not allowing adequate time to listen to the heart sounds. Physicians must be familiar with their stethoscopes and engage both the diaphragm and the bell during the heart auscultation.