


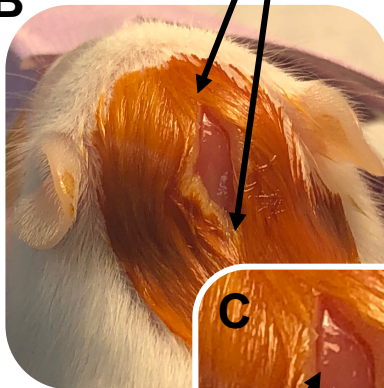
Constant delivery of isoflurane
to ensure anesthesia

A



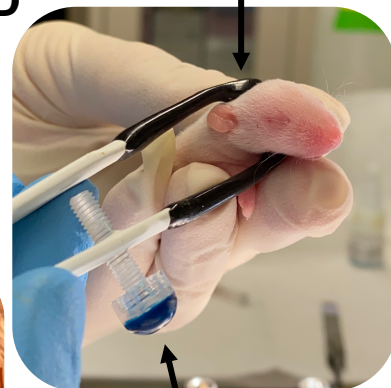Surgical incision stretches from the top
to the base of the ears

B



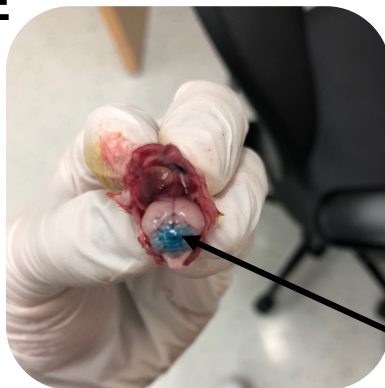
Tweezer-type electrode
right above the incision

D



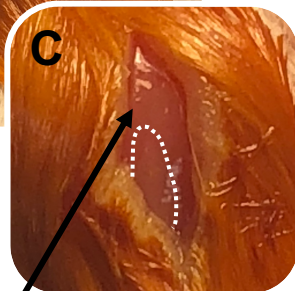
(+) end oriented
downwards

E



Injection site should be within
1 mm above white demarcation

C



Fast Green dye is localized
to the vermis