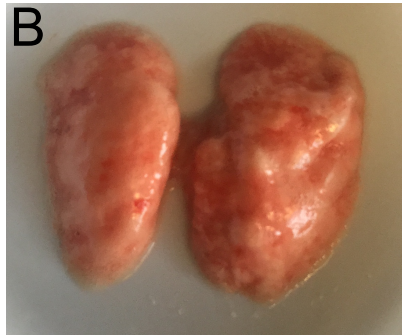
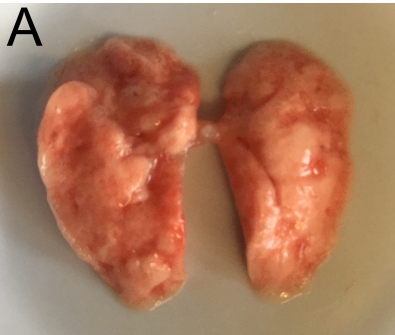


Dorsal

Ventral

Uninfected



Coomassie

