

Journal of Visualized Experiments

Facial Nerve Surgery in the Rat Model to Study Axonal Inhibition and Regeneration

--Manuscript Draft--

Article Type:	Invited Methods Article - JoVE Produced Video
Manuscript Number:	JoVE59224R2
Full Title:	Facial Nerve Surgery in the Rat Model to Study Axonal Inhibition and Regeneration
Keywords:	Facial nerve, axotomy, neuro-inhibition, nerve regeneration, GFP, rat model, animal surgery
Corresponding Author:	Syed Ahmed Ali, M.D. Michigan Medicine Ann Arbor, MI UNITED STATES
Corresponding Author's Institution:	Michigan Medicine
Corresponding Author E-Mail:	ahmedali@med.umich.edu
Order of Authors:	Syed Ahmed Ali, M.D. Aaron Stebbins John Edward Hanks Robbi A Kupfer Norman D Hogikyan Eva L. Feldman Michael J. Brenner
Additional Information:	
Question	Response
Please indicate whether this article will be Standard Access or Open Access.	Standard Access (US\$2,400)
Please indicate the city, state/province, and country where this article will be filmed . Please do not use abbreviations.	Ann Arbor, MI, USA

TITLE:

Facial Nerve Surgery in the Rat Model to Study Axonal Inhibition and Regeneration

AUTHORS & AFFILIATIONS:

S. Ahmed Ali¹, Aaron Stebbins¹, John E. Hanks¹, Robbi A. Kupfer¹, Norman. D. Hogikyan¹, Eva L. Feldman², Michael J. Brenner¹

¹Department of Otolaryngology-Head and Neck Surgery, Michigan Medicine, Ann Arbor, MI, USA

²Department of Neurology, Michigan Medicine, Ann Arbor, MI, USA

Corresponding author:

S. Ahmed Ali (ahmedali@med.umich.edu)

Email addresses of co-authors:

Aaron W. Stebbins (stebbiaa@med.umich.edu)

John E. Hanks (hanksj@med.umich.edu)

Robbi A. Kupfer (rkupfer@med.umich.edu)

Norman. D. Hogikyan (nhogikya@med.umich.edu)

Eva L. Feldman (efeldman@med.umich.edu)

Michael J. Brenner (mbren@med.umich.edu)

KEYWORDS:

Facial nerve, axotomy, neuroinhibition, nerve regeneration, GFP, rat model, animal surgery

SUMMARY:

This protocol describes a reproducible approach to facial nerve surgery in the rat model, including descriptions of various inducible patterns of injury.

ABSTRACT:

This protocol describes consistent and reproducible methods to study axonal regeneration and inhibition in a rat facial nerve injury model. The facial nerve can be manipulated along its entire length, from its intracranial segment to its extratemporal course. There are three primary types of nerve injury used for the experimental study of regenerative properties: nerve crush, transection, and nerve gap. The range of possible interventions is vast, including surgical manipulation of the nerve, delivery of neuroactive reagents or cells, and either central or end-organ manipulations. Advantages of this model for studying nerve regeneration include simplicity, reproducibility, interspecies consistency, reliable survival rates of the rat, and an increased anatomic size relative to murine models. Its limitations involve a more limited genetic manipulation versus the mouse model and the superlative regenerative capability of the rat, such that the facial nerve scientist must carefully assess time points for recovery and whether to translate results to higher animals and human studies. The rat model for facial nerve injury allows for functional, electrophysiological, and histomorphometric parameters for the interpretation and comparison of nerve regeneration. It thereby boasts tremendous potential toward furthering the understanding and treatment of the devastating consequences of facial nerve injury in human patients.

INTRODUCTION:

Cranial nerve injury in the head and neck region can be secondary to congenital, infectious, idiopathic, iatrogenic, traumatic, neurologic, oncologic, or systemic etiologies¹. Cranial nerve VII, or the facial nerve, is commonly affected. The incidence of facial nerve dysfunction can be significant, as it affects 20 to 30 per 100,000 people each year². The main motor branches of the facial nerve are the temporal, zygomatic, buccal, marginal mandibular, and cervical branches; depending on the branch involved, the consequences can include oral incompetence or drooling, corneal dryness, visual field obstruction secondary to ptosis, dysarthria, or facial asymmetry^{2,3}. Long-term morbidity includes the phenomenon of synkinesis, or involuntary movement of one facial muscle group, with attempted voluntary contraction of a distinct facial muscle group. Ocular-oral synkinesis is the most common of the aberrant regeneration as a sequela of facial nerve injury and causes functional impairment, embarrassment, diminished self-esteem, and poor quality of life³. Injury to individual branches dictates the functions that are selectively compromised.

The clinical treatment of facial nerve injury is not well standardized and is in need of further research to improve outcomes. Steroids can alleviate acute facial nerve swelling, whereas Botox is useful for temporizing synkinetic movements; but, the primary reconstructive options in the practitioner's armamentarium involve surgical intervention through nerve repair, substitution, or reanimation³⁻⁶. Depending on the type of facial nerve injury sustained, the facial nerve surgeon may utilize a number of options. For simple transection, nerve reanastomosis is useful whereas cable-graft repair is better suited for a nerve defect; for a restoration of function, the surgeon may choose either static or dynamic facial reanimation procedures. In many cases of facial nerve injury and subsequent repair, even in the hands of experienced facial nerve surgeons, the best outcome still results in persistent facial asymmetry and functional compromise⁷.

These suboptimal outcomes have spurred extensive research on facial nerve regeneration. Broad topics of interest include perfecting and innovating nerve repair techniques, determining the effect of various nerve regeneration factors, and assessing the potential of specific neural inhibitors to help combat the long-term outcome of synkinesis⁸⁻¹¹. While in vitro models can be used to assess some characteristics of pro-growth or inhibitory factors, true translational research on this subject matter is best accomplished via translatable animal models.

The decision of which animal model to utilize can be challenging, as researchers have utilized both large animals, such as sheep and small animal models, such as mice^{12,13}. While large animal models offer ideal anatomic visualization, their use requires specialized equipment and personnel not readily or easily available. Furthermore, powering a study to demonstrate effect could be highly cost-prohibitive and potentially not within the feasible scope of many scientific centers. Thus, the small animal model is most frequently utilized. The mouse model can be utilized for assessing a number of outcomes related to facial nerve surgery; however, the limited length of the nerve can restrict the scientist's ability to model certain patterns, such as large-gap injury¹⁴.

Thus, the rat murine prototype has emerged as the workhorse model through which the scientist can perform innovative surgical procedures or utilize inhibitory or pro-growth factors and assess effect across a broad range of outcome parameters. The rat facial nerve anatomy is predictably and easily approached in a reproducible fashion. Its larger scale, in comparison to the mouse model, allows for modeling of a wide range of surgical defects, ranging from simple transection to 5 mm gaps^{15,16}. This further allows for the application of complex interventions at the defect site, including the topical placement of factor, intraneural injections of factor, and the placement of isografts or bridges¹⁷⁻²³.

The docile nature of the rat, its reliable anatomy, and its propensity for effective nerve regeneration allows for the collection of many outcome measures in response to the aforementioned surgical patterns of injury²⁴. Via the rat model, the facial nerve scientist is able to assess electrophysiologic responses to injury, nerve and muscle histologic outcomes via immunohistochemistry, functional outcomes via tracking movement of the vibrissal pad and assessing eye closure, and micro- and macroscopic changes via fluorescent or confocal microscopy, among others^{11,22,23,25-29}. Thus, the following protocol will outline a surgical approach to the rat facial nerve and the injury patterns that can be induced.

PROTOCOL:

All interventions were performed in strict accordance with the National Institutes of Health (NIH) guidelines. The experimental protocol was approved by the University of Michigan's Institutional Animal Care & Use Committee (IACUC) prior to implementation. Ten-week-old adult female Sprague-Dawley rats were utilized.

1. Prior to the operative day

1.1. Ensure an appropriate stock of sterilized surgical instruments, analgesic medications, anesthetic medication, and oxygen prior to the operating day. Please see **Table of Materials** for a complete list.

2. Preoperative setup

2.1. Ensure an adequate working space, including room for at least two individuals (the surgeon and an assistant).

NOTE: There is need for a dedicated operating table, room for the anesthesia machine setup, and adequate storage space for sterilized and backup supplies.

2.2. Calibrate an operating microscope for use during the procedures. Make sure the surgeon has the ability to adjust the handles of the microscope and the zoom/focus buttons by placing a sterilized cover over the handles/buttons

NOTE: We utilized sterilized aluminum foil over the handles/buttons.

3. Anesthesia and preparation

3.1. Place the animal in the anesthesia chamber and induce general anesthesia via 1.8% isoflurane and 0.9 L/min oxygen.

3.1.1. Confirm an adequate plane of anesthesia via an assessment of spontaneous breathing and an evaluation of consciousness by assessing the animal's grimace response to a toe pinch.

3.2. Apply eye lubricant bilaterally to guard against corneal irritation or dryness.

3.3. Shave the operative site(s) with a razor or automatic clipper.

3.3.1. Establish a method for rat identification at this time, either via an ear tag or tail label/markings.

3.4. Administer a subcutaneous injection of 0.05 mg/kg buprenorphine along the animal's back for prophylaxis against postoperative pain.

4. Surgical approach and injury patterns

4.1. Transfer the animal to the operating table and continue the gas flow via a nosecone. Ensure that a warming pad is positioned underneath the animal and the sterile field to maintain its body temperature.

4.2. Place sterilized gauze (rolled up and fastened with tape) to use as a neck roll for the rat; this will provide an enhanced exposure of the surgical field. Note that the appropriate positioning of the animal is paramount for efficient nerve identification and dissection.

4.3. Prepare the animal's facial skin for the procedure. Use chlorhexidine or an iodine-based solution to scrub the surgical site 3x, alternating with 70% ethanol, to ensure disinfection.

4.4. Plan and mark the surgical incision if desired. Manipulate the ipsilateral ear in an anterior-posterior direction to determine the natural folding of the postauricular skin.

4.5. Fashion a 4–5 mm incision in the postauricular crease using sharp iris scissors or a number 15 blade. This can be expanded later in the procedure as necessary.

4.6. Bluntly dissect through the immediate subcutaneous fascia and place a micro-Weitlaner retractor to enhance exposure. Note that there may be small caliber blood vessels in this area; these are best avoided by retracting superiorly or inferiorly via the Weitlaner retractor.

4.7. Identify the anterior digastric muscle as it travels in an inferior-to-superior direction toward its insertion along the skull base.

4.7.1. Spread gently through the muscle belly along its insertion point to reveal the tendon of the anterior digastric belly. Note that the tendon appears as a filmy white process emanating from the muscle with a solid insertion onto the skull base.

4.8. After identification of the anterior digastric muscle and its tendon, adjust the Weitlaner retractor to further retract the muscle belly. Note that the subsequently exposed region is the three-dimensional space where the main trunk of the facial nerve lies.

NOTE: This region is bounded superiorly and medially by the skull base, laterally by the anterior digastric muscle, posteromedially by the ear canal, and inferiorly by the structures of the neck, including the superficial temporal artery.

4.9. After adequate exposure, identify the main trunk of the facial nerve as it travels inferiorly from underneath the tendon of the digastric muscle, where it exits the stylomastoid foramen from the skull base. Note that the nerve appears as a pearly white cord, encased in the animal's parotid-masseteric fascia. Practice caution when further exposing the nerve, for the following reasons.

4.9.1. Avoid aggressive dissection, or perpendicular spreads, to guard against stretch-mediated neuropraxia injury.

4.9.2. Avoid aggressive posteriorly and medially directed dissection to guard against violating the thin tissues overlying the ear canal as this could introduce middle ear flora into the surgical field.

4.9.3. Avoid damaging the superficial temporal artery through broad medially and inferiorly directed dissection. Note that an injury will be identified by brisk, pulsatile bleeding.

4.9.3.1. If the artery is injured, apply prompt pressure with a cotton-tipped applicator or sterile gauze via forceps. Hemostatic agents or liquid fibrin sealant can be placed in near proximity. Keep in mind that the animal may require a subcutaneous injection of 0.9% sterile saline for fluid stabilization.

4.10. Trace the main trunk distally by dissecting along the nerve in an inferior direction, distally from the exit of the stylomastoid foramen.

4.10.1. Extend the original incision to allow for a full exposure of the nerve and its branches. Take care to avoid a disruption of the parotid gland as this could result in postoperative sialoceles.

4.11. Induce the desired injury patterns as follows.

4.11.1. For a crush injury, use smooth-surfaced jeweler's forceps to firmly grasp the nerve and compress it⁹. Apply constant and reproducible pressure to the nerve for a period of 30 s to ensure an appropriate crush injury.

4.11.2. For a simple transection, grasp the fascia overlying the nerve, or the immediate epineurium, with fine-toothed forceps, and use sharp microscissors to cleanly transect the nerve at the desired point with a single cut. Take care to avoid excess traction on the nerve with the forceps.

4.11.3. For a nerve gap model, create the desired nerve gap using a similar method to the simple transection injury. Use the sterilized shaft of a cotton-tipped applicator—cut to the desired nerve gap length—intraoperatively to ensure similarity of injury pattern between animals.

5. Wound closure

5.1. Irrigate the wound with sterile saline and dry it with sterile gauze.

5.2. Approximate the skin edges in a simple, subcuticular fashion with absorbable sutures, or use skin glue or wound clips, which are also acceptable for wound closure. Place a buried stitch by taking a deep-to-superficial bite of one skin edge and then a subsequent superficial-to-deep bite of the opposite skin edge.

6. Postoperative recovery

6.1. Administer a subcutaneous injection of nonsteroidal anti-inflammatory analgesic (such as 0.5 mg/kg carprofen) for postoperative pain control. Place the injection along the animal's back.

6.2. Cease the administration of the anesthetic agent and allow the animal to inhale oxygen for an additional 1 min.

6.3. Place the animal in a warmed (via a heat lamp), aseptic cage devoid of bedding material to avoid accidental ingestion. Note that the animal will typically demonstrate signs of recovery within 1–2 min and can appear disoriented, with a delayed recovery of hind-leg function.

6.4. Return the animals to their cages in the appropriate housing unit and administer postoperative analgesics on postoperative day #1 to ensure continued prophylaxis against pain.

6.5. Monitor the animals 2x per day to evaluate for signs of malnourishment, corneal irritation, or surgical site infection, and maintain appropriate surgical logs.

6.5.1. Administer 0.9% sterile saline in a subcutaneous fashion if there is significant weight loss.

6.5.2. Apply lubricating eye ointment daily until the animal's blink reflex is re-established.

REPRESENTATIVE RESULTS:

Following the initial surgical procedure, there are two main types of outcome measures: serial measurements in the live animal and measurements that require sacrificing the animal. Examples of serial measurements include electrophysiological assays, such as a compound muscle action

potential measurement³⁰, assessments of facial muscle movement via laser-assisted or videography means⁹, or even repetitive live imaging of regrowth of the facial nerve in fluorescent transgenic animals^{31,32}. **Figure 1** illustrates live imaging of the main trunk of the facial nerve in an adult transgenic *Thy1-GFP* rat. A crush injury has been performed on the marginal mandibular branch, approximately 2–3 mm distal to the branch point of the first pes. Utilizing MetaMorph imaging software, we were able to quantify the fluorescent intensity at any point along the course of the facial nerve. In particular, it is possible to quantify fluorescence proximal and distal to an injury site, thereby serially assessing for the return of fluorescence as a marker for nerve regeneration. **Figure 2** illustrates the gradual return of fluorescence (measured as a ratio of distal fluorescence to proximal fluorescence across a simple transection site) at the 1, 2, 3, and 4 week time-points in the *Thy1-GFP* rat.

Histomorphometric analysis of the nerve proper or muscle requires sacrificing the animal after a predetermined length of time to demonstrate the desired effect across groups. **Figure 3** demonstrates cross-sectional images of the marginal mandibular division. This technique requires careful tissue handling, storage, preparation, sectioning, and staining to allow for a histomorphometric analysis across various groups. If appropriately performed, this technique allows for the quantification of the axonal diameter, amount of debris, nerve fiber, percentage of nerve, and density measurements.

FIGURE AND TABLE LEGENDS:

Figure 1: Facial nerve anatomy demonstrated in the *Thy1-GFP* rat 1 week after a crush injury at the marginal mandibular nerve. The site of the crush injury is demonstrated by the white arrow. Sections of the nerve are labeled as MT (main trunk), B (buccal), and MM (marginal mandibular) branches. The scale bar represents 1.5 mm.

Figure 2: Quantification of return of fluorescence as a ratio of the fluorescent intensity of the site immediately distal to the transection injury over the intensity of the site proximal to the transection injury. Four animals were studied, and a crush injury was modeled. The graph is plotted as mean proportion \pm standard error of the mean.

Figure 3: Axial cross-section of the marginal mandibular branch of the rat facial nerve following staining with toluidine blue. The scale bar represents 100 μ m.

DISCUSSION:

The rat facial nerve injury model has emerged as the most versatile system for the evaluation of neurotrophic factors due to its surgical accessibility, branching pattern, and physiological significance^{27,29,33–36}. The combination of video demonstration and application of transgenic animal data opens new possibilities for the scientific study of nerve regenerative phenomena. This model allows the systematic and detailed characterization of neural response to trauma, neurotrophic influences, immunomodulatory influences, and other aspects of the microenvironment. Although the primary objective of clinical facial nerve study relates to the recovery of motoneuron function, the model can also be used to better understand events at the

neuromuscular junction, nuances of axonal transport, and the interplay of axonal–glial influences^{27,36–44}. Mechanistic study using facial nerve has paradoxically led to important insights relating to central inflammation and neurodegenerative diseases, such as Alzheimer’s disease and Parkinson’s disease^{45–47}. There, the medical implications of work conducted in this model have notable implications for better understanding and eventually improving clinical care for patients afflicted with both peripheral and central nervous system disorders affecting both supporting cells and neuronal tissues.

There is an initial learning curve with performing facial nerve surgery in the rat model. While it is not necessary for the scientist to be surgically trained, they should be comfortable working underneath an operating microscope and utilizing binocular vision. The scientist should further be comfortable working with their nondominant hand, as adjusting the retraction with the Weitlaner retractor in the contralateral hand can significantly improve visualization. This is particularly true for identifying the main trunk of the facial nerve, as it is possible for the novice surgeon to lose landmarks and become disoriented in the three-dimensional space where the nerve exits the skull base. However, once experience is gained and the surgeon is consistently able to identify the tendon of the digastric muscle, then the procedures are quite straightforward. Where the procedure—a simple transection of the nerve—could take as long as 30 min when the scientist is initially learning, in the hands of an experienced surgeon, it can be as expedient as 5 min from incision to wound closure. With an experienced assistant managing the preparation and the anesthesia of the animals—as well as restocking supplies as needed—it is feasible to operate on several animals in a single sitting. If complex intraoperative maneuvers are performed, such as a stereotaxic intraneural injection, then the time required will increase.

This group has experience working with the adult Lewis and Sprague-Dawley rats and the adult *Thy1-GFP* rat. These models have demonstrated impressive resilience, both intraoperatively and postoperatively. It would be prudent to allow time for the acclimation of the animal (typically 1 week) if ordered from a separate facility as mandated by the NIH Guide for Care and Use of Laboratory Animals, as operating too soon after a transfer could result in excessive stress and poor postoperative health. With unilateral facial nerve injury, the rat does not demonstrate untoward signs of malnourishment or corneal irritation postoperatively. Furthermore, they tolerate repetitive periods of anesthesia quite well⁴⁸, as previous protocols have demanded serial electrophysiological analyses of the return of whisker function until eventual sacrifice. Although the operators should attempt to maintain intraoperative sterility to the best of their abilities, we have not noted postoperative infections with any of the operated animals. On occasion, the animal will attempt to scratch at their incision site; however, it typically returns to baseline status with regrowth of hair within 1–2 weeks postoperatively. If the parotid gland is injured or inadvertently removed, then sialoceles will result, which may necessitate repeat anesthesia for drainage.

Modifications can be made to the location of injury, type of injury, or intervention performed. Injury can be induced at any point along the course of the facial nerve, from intracranial facial nerve transection to injury to the main trunk or any of its peripheral branches⁴⁹. The broad patterns of injury include crush injury, simple transection with or without repair, and gap-defect

with or without repair or bridge¹¹. The range of possible interventions is exhaustive. Briefly, intervention can be undertaken at the level of the nerve proper¹⁷, at the site of the injury²³, or at the muscular end-organ⁵⁰. The list of possible outcome parameters is equally lengthy. Workhorse histomorphometric parameters include axial-based quantification of nerve count, nerve density, and percentage of nerve, among others. Additional measures include histologic analyses of longitudinal sections to illustrate the extent of regeneration and neuromuscular junction quantification to demonstrate the reinnervation of target facial musculature⁵¹. Novel methods of assessing outcomes continue to be developed²². For example, Hadlock et al. have demonstrated a complex method for assessing the contracture of independent facial zones via scent- or puff-induced reactions; this has potential for the assessment and eventual treatment of troublesome synkinetic regeneration¹¹.

As with any animal model, there are limitations in translating the results to human patients. The mouse and rat models both exhibit the superior regenerative potential inherent in the rodent nervous system; this property allows the rodent to demonstrate regenerative results that could not possibly be achieved in humans and higher animals²⁴. Therefore, the facial nerve scientist must carefully select appropriate time-points for the evaluation of nerve regeneration and recovery; if a prolonged time-point is selected, the narrow window of opportunity where experimental groups may reliably demonstrate the effect from their unique intervention may be missed²⁴.

ACKNOWLEDGMENTS:

S.A.A. is funded by the American Academy of Facial Plastic and Reconstructive Surgery Leslie Bernstein Grants Program.

DISCLOSURES:

The authors have nothing to disclose.

REFERENCES:

1. Chan, J. Y. K., Byrne, P. J. Management of facial paralysis in the 21st century. *Facial Plastic Surgery*. **27** (4), 346-357, doi:10.1055/s-0031-1283053 (2011).
2. Razfar, A., Lee, M. K., Massry, G. G., Azizzadeh, B. Facial Paralysis Reconstruction. *Otolaryngologic Clinics of North America*. **49** (2), 459-473, doi:10.1016/j.otc.2015.12.002 (2016).
3. Couch, S. M., Chundury, R. V., Holds, J. B. Subjective and objective outcome measures in the treatment of facial nerve synkinesis with onabotulinumtoxinA (Botox). *Ophthalmic Plastic and Reconstructive Surgery*. **30** (3), 246-250, doi:10.1097/IOP.0000000000000086 (2014).
4. Wei, L. A., Diels, J., Lucarelli, M. J. Treating buccinator with botulinum toxin in patients with facial synkinesis: A previously overlooked target. *Ophthalmic Plastic and Reconstructive Surgery*. **32** (2), 138-141, doi:10.1097/IOP.0000000000000449 (2016).
5. Cooper, L., Lui, M., Nduka, C. Botulinum toxin treatment for facial palsy: A systematic review. *Journal of Plastic, Reconstructive and Aesthetic Surgery*. **70** (6), 833-841, doi:10.1016/j.bjps.2017.01.009 (2017).
6. Choi, K. H. et al. Botulinum toxin injection of both sides of the face to treat post-paralytic facial synkinesis. *Journal of Plastic, Reconstructive and Aesthetic Surgery*. **66** (8), 1058-1063,

doi:10.1016/j.bjps.2013.04.012 (2013).

7. Yang, X. N. et al. Peripheral nerve repair with epimysium conduit. *Biomaterials*. **34** (22), 5606-5616, doi:10.1016/j.biomaterials.2013.04.018 (2013).

8. Banks, C. A. et al. Long-term functional recovery after facial nerve transection and repair in the rat. *Journal of Reconstructive Microsurgery*. **31** (3), 210-216, doi:10.1055/s-0034-1395940 (2015).

9. Hadlock, T. A., Kowaleski, J., Lo, D., MacKinnon, S. E., Heaton, J. T. Rodent facial nerve recovery after selected lesions and repair techniques. *Plastic and Reconstructive Surgery*. **125** (1), 99-109, doi:10.1097/PRS.0b013e3181c2a5ea (2010).

10. Hadlock, T. et al. The effect of electrical and mechanical stimulation on the regenerating rodent facial nerve. *Laryngoscope*. **120** (6), 1094-1102, doi:10.1002/lary.20903 (2009).

11. Hadlock, T. et al. Functional assessments of the rodent facial nerve: A synkinesis model. *Laryngoscope*. **118** (10), 1744-1749, doi:10.1097/MLG.0b013e31817f5255 (2008).

12. Diogo, C. C. et al. The use of sheep as a model for studying peripheral nerve regeneration following nerve injury: review of the literature. *Neurological Research*. **39** (10), 926-939, doi:10.1080/01616412.2017.1331873 (2017).

13. Wanner, R. et al. Functional and Molecular Characterization of a Novel Traumatic Peripheral Nerve–Muscle Injury Model. *NeuroMolecular Medicine*. **19** (2-3), 357-374, doi:10.1007/s12017-017-8450-1 (2017).

14. Olmstead, D. N. et al. Facial nerve axotomy in mice: A model to study motoneuron response to injury. *Journal of Visualized Experiments*. (96), e52382, doi:10.3791/52382 (2015).

15. Maeda, T., Hori, S., Sasaki, S., Maruo, S. Effects of tension at the site of coaptation on recovery of sciatic nerve function after neurorrhaphy: Evaluation by walking-track measurement, electrophysiology, histomorphometry, and electron probe X-ray microanalysis. *Microsurgery*. **19** (4), 200-207, doi:10.1002/(SICI)1098-2752(1999)19:4<200::AID-MICR7>3.0.CO;2-Y (1999).

16. Zhang, F., Inserra, M., Richards, L., Terris, D. J., Lineaweaver, W. C. Quantification of nerve tension after nerve repair: Correlations with nerve defects and nerve regeneration. *Journal of Reconstructive Microsurgery*. **17** (6), 445-451, doi:10.1055/s-2001-16360 (2001).

17. Macfarlane, B. V., Wright, A., Benson, H. A. E. Reversible blockade of retrograde axonal transport in the rat sciatic nerve by vincristine. *Journal of Pharmacy and Pharmacology*. **49** (1), 97-101, doi:10.1111/j.2042-7158.1997.tb06759.x (1997).

18. Stromberg, B. V., Vlastou, C., Earle, A. S. Effect of nerve graft polarity on nerve regeneration and function. *Journal of Hand Surgery*. **4** (5), 444-445, doi:10.1016/S0363-5023(79)80039-8 (1979).

19. Sotereanos, D. G. et al. Reversing nerve-graft polarity in a rat model: The effect on function. *Journal of Reconstructive Microsurgery*. **8** (4), 303-307, doi:10.1055/s-2007-1006712 (1992).

20. Whitlock, E. L. et al. Ropivacaine-induced peripheral nerve injection injury in the rodent model. *Anesthesia and Analgesia*. **111** (1), 214-220, doi:10.1213/ANE.0b013e3181de574e (2010).

21. Lloyd, B. M. et al. Use of motor nerve material in peripheral nerve repair with conduits. *Microsurgery*. **27** (2), 138-145, doi:10.1002/micr.20318 (2007).

22. Kawamura, D. H. et al. Regeneration through nerve isografts is independent of nerve geometry. *Journal of Reconstructive Microsurgery*. **21** (4), 243-249, doi:10.1055/s-2005-871751 (2005).

23. Brenner, M. J. et al. Repair of motor nerve gaps with sensory nerve inhibits regeneration in

rats. *Laryngoscope*. **116** (9), 1685-1692, doi:10.1097/01.mlg.0000229469.31749.91 (2006).

24. Brenner, M. J. et al. Role of timing in assessment of nerve regeneration. *Microsurgery*. **28** (4), 265-272, doi:10.1002/micr.20483 (2008).

25. Heaton, J. T. et al. A system for studying facial nerve function in rats through simultaneous bilateral monitoring of eyelid and whisker movements. *Journal of Neuroscience Methods*. **171** (2), 197-206, doi:10.1016/j.jneumeth.2008.02.023 (2008).

26. Magill, C. K., Moore, A. M., Borschel, G. H., Mackinnon, S. E. A new model for facial nerve research: The novel transgenic Thy1-GFP rat. *Archives of Facial Plastic Surgery*. **12** (5), 315-320, doi:10.1001/archfacial.2010.71 (2010).

27. Guntinas-Lichius, O. et al. Factors limiting motor recovery after facial nerve transection in the rat: Combined structural and functional analyses. *European Journal of Neuroscience*. **21** (2), 391-402, doi:10.1111/j.1460-9568.2005.03877.x (2005).

28. Skouras, E. et al. Manual stimulation, but not acute electrical stimulation prior to reconstructive surgery, improves functional recovery after facial nerve injury in rats. *Restorative Neurology and Neuroscience*. **27** (3), 237-251, doi:10.3233/RNN-2009-0474 (2009).

29. Bischoff, A. et al. Manual stimulation of the orbicularis oculi muscle improves eyelid closure after facial nerve injury in adult rats. *Muscle and Nerve*. **39** (2), 197-205, doi:10.1002/mus.21126 (2009).

30. Schulz, A., Walther, C., Morrison, H., Bauer, R. In vivo electrophysiological measurements on mouse sciatic nerves. *Journal of Visualized Experiments*. (86), e51181, doi:10.3791/51181 (2014).

31. Placheta, E. et al. Macroscopic in vivo imaging of facial nerve regeneration in Thy1-GFP rats. *JAMA Facial Plastic Surgery*. **17** (1), 8-15, doi:10.1001/jamafacial.2014.617 (2015).

32. Moore, A. M. et al. A transgenic rat expressing green fluorescent protein (GFP) in peripheral nerves provides a new hindlimb model for the study of nerve injury and regeneration. *Journal of Neuroscience Methods*. **204** (1), 19-27, doi:10.1016/j.jneumeth.2011.10.011 (2012).

33. Grosheva, M. et al. Early and continued manual stimulation is required for long-term recovery after facial nerve injury. *Muscle and Nerve*. **57** (1), 100-106, doi:10.1002/mus.25613 (2018).

34. Grosheva, M. et al. Comparison of trophic factors' expression between paralyzed and recovering muscles after facial nerve injury. A quantitative analysis in time course. *Experimental Neurology*. **279**, 137-148, doi:10.1016/j.expneurol.2016.02.020 (2016).

35. Grosheva, M. et al. Local stabilization of microtubule assembly improves recovery of facial nerve function after repair. *Experimental Neurology*. **209** (1), 131-144, doi:10.1016/j.expneurol.2007.09.016 (2008).

36. Angelov, D. N. et al. Mechanical stimulation of paralyzed vibrissal muscles following facial nerve injury in adult rat promotes full recovery of whisking. *Neurobiology of Disease*. **26** (1), 229-242, doi:10.1016/j.nbd.2006.12.016 (2007).

37. Tomov, T. L. et al. An example of neural plasticity evoked by putative behavioral demand and early use of vibrissal hairs after facial nerve transection. *Experimental Neurology*. **178** (2), 207-218, doi:10.1006/exnr.2002.8040 (2002).

38. Streppel, M. et al. Focal application of neutralizing antibodies to soluble neurotrophic factors reduces collateral axonal branching after peripheral nerve lesion. *European Journal of Neuroscience*. **15** (8), 1327-1342, doi:10.1046/j.1460-9568.2002.01971.x (2002).

39. Peeva, G. P. et al. Improved outcome of facial nerve repair in rats is associated with enhanced regenerative response of motoneurons and augmented neocortical plasticity. *European Journal*

485 of *Neuroscience*. **24** (8), 2152-2162, doi:10.1111/j.1460-9568.2006.05091.x (2006).

486 40. Pavlov, S. P. et al. Manually-stimulated recovery of motor function after facial nerve injury

487 requires intact sensory input. *Experimental Neurology*. **211** (1), 292-300,

488 doi:10.1016/j.expneurol.2008.02.019 (2008).

489 41. Guntinas-Lichius, O. et al. Transplantation of olfactory ensheathing cells stimulates the

490 collateral sprouting from axotomized adult rat facial motoneurons. *Experimental Neurology*. **172**

491 (1), 70-80, doi:10.1006/exnr.2001.7774 (2001).

492 42. Guntinas-Lichius, O., Angelov, D. N., Stennert, E., Neiss, W. F. Delayed hypoglossal-facial nerve

493 suture after predegeneration of the peripheral facial nerve stump improves the innervation of

494 mimetic musculature by hypoglossal motoneurons. *Journal of Comparative Neurology*. **387** (2),

495 234-242, doi:10.1002/(SICI)1096-9861(19971020)387:2<234::AID-CNE5>3.0.CO;2-1 (1997).

496 43. Sinis, N. et al. Electrical stimulation of paralyzed vibrissal muscles reduces endplate

497 reinnervation and does not promote motor recovery after facial nerve repair in rats. *Annals of*

498 *Anatomy*. **191** (4), 356-370, doi:10.1016/j.aanat.2009.03.004 (2009).

499 44. Kiryakova, S. et al. Recovery of whisking function promoted by manual stimulation of the

500 vibrissal muscles after facial nerve injury requires insulin-like growth factor 1 (IGF-1).

501 *Experimental Neurology*. **222** (2), 226-234, doi:10.1016/j.expneurol.2009.12.031 (2010).

502 45. Banati, R. B. et al. Early and rapid de novo synthesis of Alzheimer β A4-Amyloid precursor

503 protein (APP) in activated microglia. *Glia*. **9** (3), 199-210, doi:10.1002/glia.440090305 (1993).

504 46. Blinzinger, K., Kreutzberg, G. Displacement of synaptic terminals from regenerating

505 motoneurons by microglial cells. *Zeitschrift für Zellforschung und Mikroskopische Anatomie*. **85**

506 (2), 145-157, doi:10.1007/BF00325030 (1968).

507 47. Rieske, E. et al. Microglia and microglia-derived brain macrophages in culture: generation

508 from axotomized rat facial nuclei, identification and characterization in vitro. *Brain Research*. **492**

509 (1-2), 1-14, doi:10.1016/0006-8993(89)90883-4 (1989).

510 48. Matsumoto, K. et al. Peripheral nerve regeneration across an 80-mm gap bridged by a

511 polyglycolic acid (PGA)-collagen tube filled with laminin-coated collagen fibers: A histological and

512 electrophysiological evaluation of regenerated nerves. *Brain Research*. **868** (2), 315-328,

513 doi:10.1016/S0006-8993(00)02207-1 (2000).

514 49. Mattsson, P., Janson, A. M., Aldskogius, H., Svensson, M. Nimodipine promotes regeneration

515 and functional recovery after intracranial facial nerve crush. *Journal of Comparative Neurology*.

516 **437** (1), 106-117, doi:10.1002/cne.1273 (2001).

517 50. Yian, C. H., Paniello, R. C., Gershon Spector, J. Inhibition of motor nerve regeneration in a

518 rabbit facial nerve model. *Laryngoscope*. **111** (5), 786-791 (2001).

519 51. Angelov, D. N. et al. Nimodipine accelerates axonal sprouting after surgical repair of rat facial

520 nerve. *Journal of Neuroscience*. **16** (3), 1041-1048 (1996).

Figure 1

[Click here to access/download;Figure;Figure 1 12_3_18 copy.tif](#)

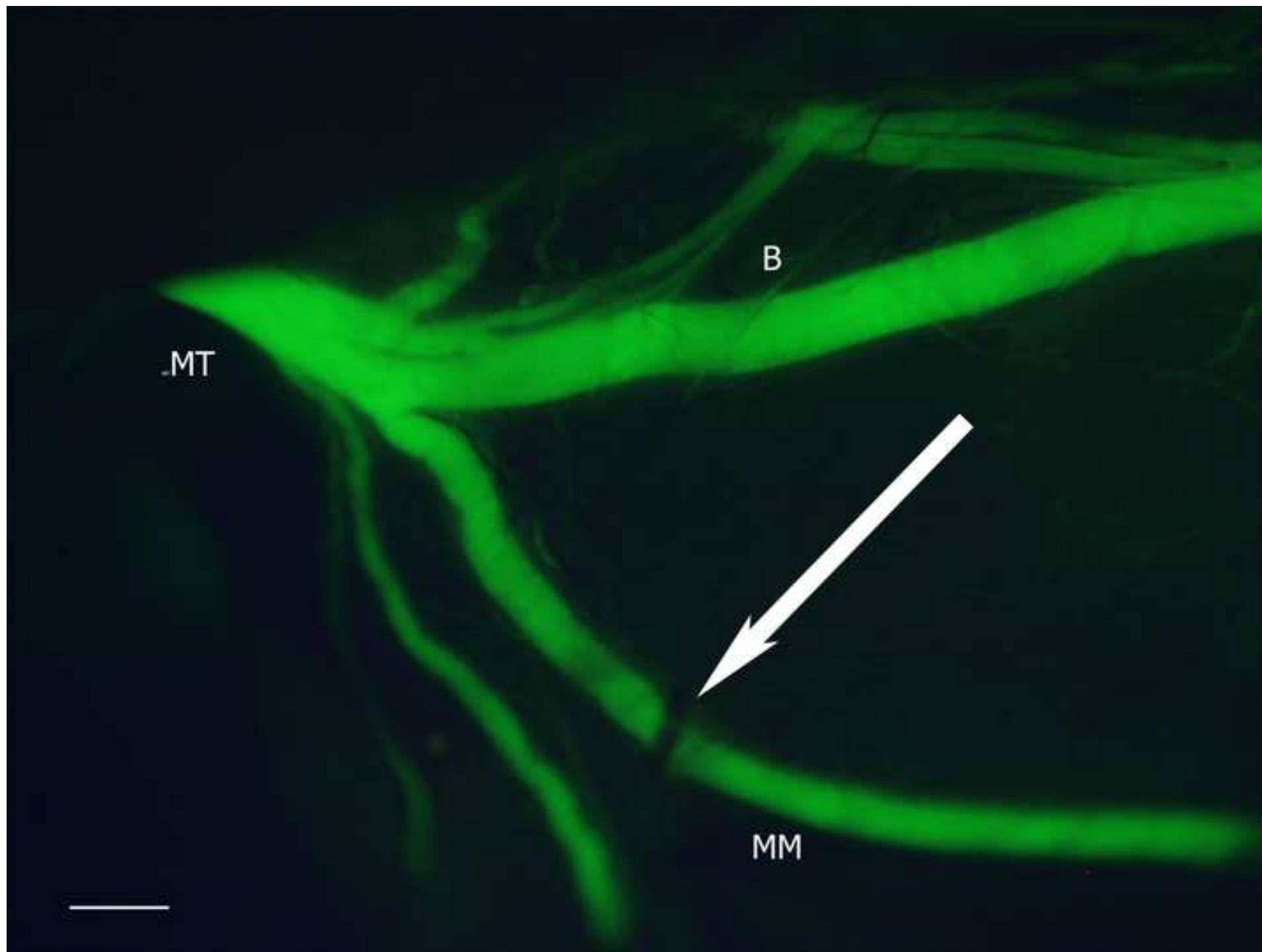
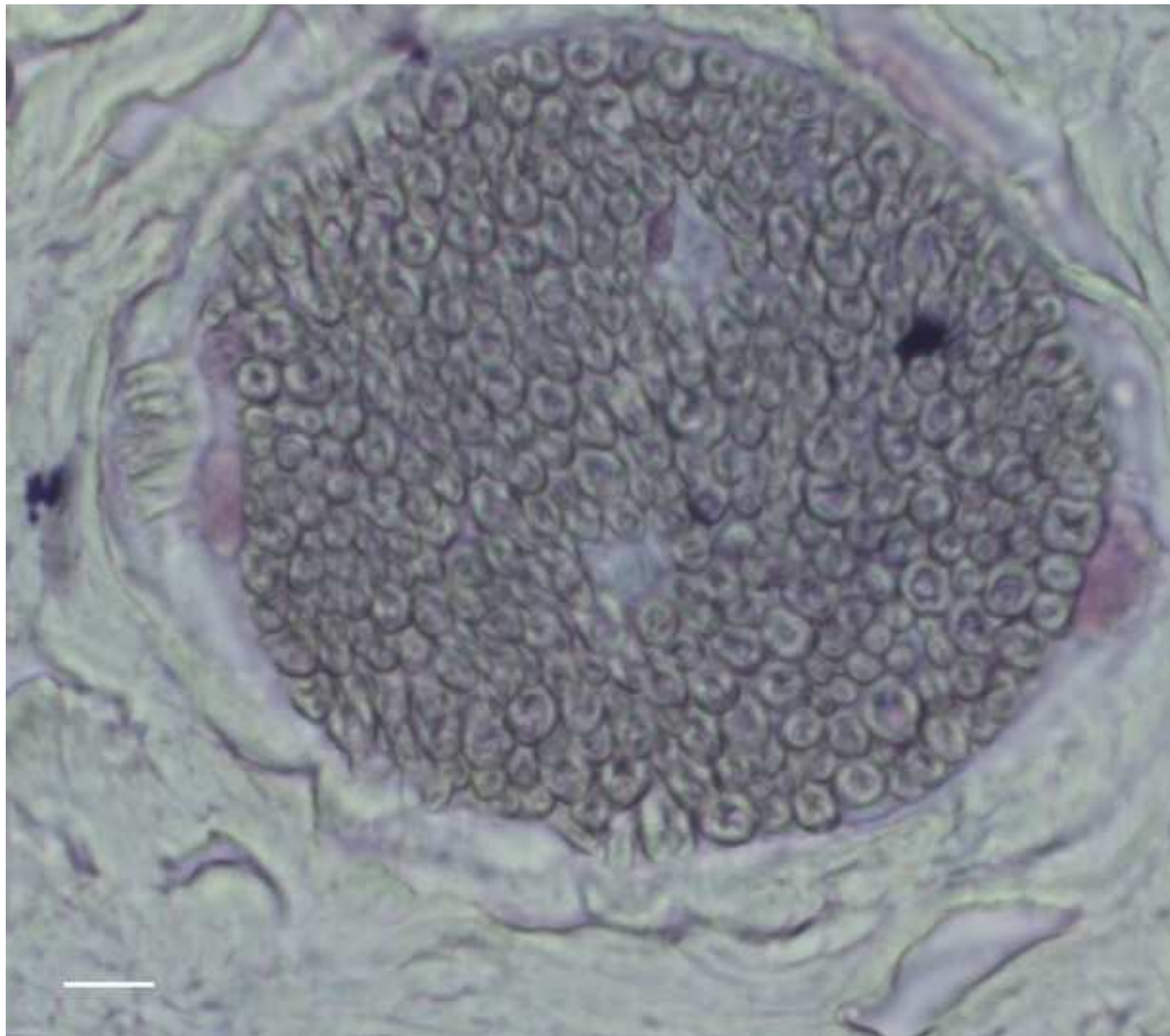
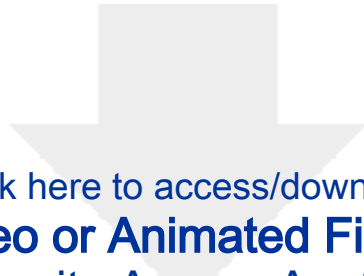


Figure 3

[Click here to access/download;Figure;Figure 3 12_3_18 copy.tif](#)





[Click here to access/download](#)

Video or Animated Figure

Figure 2. Intensity Across Axotomy Site.emf



Name of Material/ Equipment	Company	Catalog Number	Comments/Description
1.8% isoflurane	VetOne	13985-030-40	
11-0 nylon microsutures	AROSuture	TK-117038	
4-0 monocryl suture	VWR	75982-084	
Buprenorphine SR	ZooPharm	MIF 900-006	
Carprofen	Sigma-Aldrich	MFCD00079028	
Chlorhexidine	VWR	IC19135805	
Jeweler forceps	VWR	21909-458	
Micro Weitlaner retractor	VWR	82030-146	
Micro-scissors	VWR	100492-348	
Mini tenotomy scissors	VWR	89023-522	
Number 15 scalpel blade	VWR	102097-834	
Operating microscope	Leica		
Petrolatum eye gel	Pharmaderm	B002LUWBEK	
Sterile water	VWR	89125-834	
Tissue adhesive	Vetbond, 3M	NC9259532	
Water conductor pad	Aqua Relief System	ARS2000B	

ARTICLE AND VIDEO LICENSE AGREEMENT

Title of Article	Facial Nerve Surgery in the Rat Model: Methods to Study Nerve Inhibition and Regeneration
Author(s):	S. Ahmed Ali, M.D., Aaron Stebbins, B.S., John E. Hanks, M.D., Robbi A. Kupfer, M.D., Norman D. Hogikyan, M.D., Eva L. Feldman, M.D., Michael J. Brenner, M.D.

Item 1: The Author elects to have the Materials be made available (as described at <http://www.jove.com/publish>) via:

☒ Standard Access

☐ Open Access

Item 2: Please select one of the following items:

☒ The Author is **NOT** a United States government employee.

☐ The Author is a United States government employee and the Materials were prepared in the course of his or her duties as a United States government employee.

☐ The Author is a United States government employee but the Materials were NOT prepared in the course of his or her duties as a United States government employee.

ARTICLE AND VIDEO LICENSE AGREEMENT

1. **Defined Terms.** As used in this Article and Video License Agreement, the following terms shall have the following meanings: **"Agreement"** means this Article and Video License Agreement; **"Article"** means the article specified on the last page of this Agreement, including any associated materials such as texts, figures, tables, artwork, abstracts, or summaries contained therein; **"Author"** means the author who is a signatory to this Agreement; **"Collective Work"** means a work, such as a periodical issue, anthology or encyclopedia, in which the Materials in their entirety in unmodified form, along with a number of other contributions, constituting separate and independent works in themselves, are assembled into a collective whole; **"CRC License"** means the Creative Commons Attribution-Non Commercial-No Derivs 3.0 Unported Agreement, the terms and conditions of which can be found at: <http://creativecommons.org/licenses/by-nc-nd/3.0/legalcode>; **"Derivative Work"** means a work based upon the Materials or upon the Materials and other pre-existing works, such as a translation, musical arrangement, dramatization, fictionalization, motion picture version, sound recording, art reproduction, abridgment, condensation, or any other form in which the Materials may be recast, transformed, or adapted; **"Institution"** means the institution, listed on the last page of this Agreement, by which the Author was employed at the time of the creation of the Materials; **"JoVE"** means MyJoVE Corporation, a Massachusetts corporation and the publisher of The Journal of Visualized Experiments; **"Materials"** means the Article and / or the Video; **"Parties"** means the Author and JoVE; **"Video"** means any video(s) made by the Author, alone or in conjunction with any other parties, or by JoVE or its affiliates or agents, individually or in collaboration with the Author or any other parties, incorporating all or any portion

of the Article, and in which the Author may or may not appear.

2. **Background.** The Author, who is the author of the Article, in order to ensure the dissemination and protection of the Article, desires to have the JoVE publish the Article and create and transmit videos based on the Article. In furtherance of such goals, the Parties desire to memorialize in this Agreement the respective rights of each Party in and to the Article and the Video.

3. **Grant of Rights in Article.** In consideration of JoVE agreeing to publish the Article, the Author hereby grants to JoVE, subject to **Sections 4** and **7** below, the exclusive, royalty-free, perpetual (for the full term of copyright in the Article, including any extensions thereto) license (a) to publish, reproduce, distribute, display and store the Article in all forms, formats and media whether now known or hereafter developed (including without limitation in print, digital and electronic form) throughout the world, (b) to translate the Article into other languages, create adaptations, summaries or extracts of the Article or other Derivative Works (including, without limitation, the Video) or Collective Works based on all or any portion of the Article and exercise all of the rights set forth in (a) above in such translations, adaptations, summaries, extracts, Derivative Works or Collective Works and (c) to license others to do any or all of the above. The foregoing rights may be exercised in all media and formats, whether now known or hereafter devised, and include the right to make such modifications as are technically necessary to exercise the rights in other media and formats. If the "Open Access" box has been checked in **Item 1** above, JoVE and the Author hereby grant to the public all such rights in the Article as provided in, but subject to all limitations and requirements set forth in, the CRC License.

ARTICLE AND VIDEO LICENSE AGREEMENT

4. **Retention of Rights in Article.** Notwithstanding the exclusive license granted to JoVE in **Section 3** above, the Author shall, with respect to the Article, retain the non-exclusive right to use all or part of the Article for the non-commercial purpose of giving lectures, presentations or teaching classes, and to post a copy of the Article on the Institution's website or the Author's personal website, in each case provided that a link to the Article on the JoVE website is provided and notice of JoVE's copyright in the Article is included. All non-copyright intellectual property rights in and to the Article, such as patent rights, shall remain with the Author.

5. **Grant of Rights in Video – Standard Access.** This **Section 5** applies if the "Standard Access" box has been checked in **Item 1** above or if no box has been checked in **Item 1** above. In consideration of JoVE agreeing to produce, display or otherwise assist with the Video, the Author hereby acknowledges and agrees that, Subject to **Section 7** below, JoVE is and shall be the sole and exclusive owner of all rights of any nature, including, without limitation, all copyrights, in and to the Video. To the extent that, by law, the Author is deemed, now or at any time in the future, to have any rights of any nature in or to the Video, the Author hereby disclaims all such rights and transfers all such rights to JoVE.

6. **Grant of Rights in Video – Open Access.** This **Section 6** applies only if the "Open Access" box has been checked in **Item 1** above. In consideration of JoVE agreeing to produce, display or otherwise assist with the Video, the Author hereby grants to JoVE, subject to **Section 7** below, the exclusive, royalty-free, perpetual (for the full term of copyright in the Article, including any extensions thereto) license (a) to publish, reproduce, distribute, display and store the Video in all forms, formats and media whether now known or hereafter developed (including without limitation in print, digital and electronic form) throughout the world, (b) to translate the Video into other languages, create adaptations, summaries or extracts of the Video or other Derivative Works or Collective Works based on all or any portion of the Video and exercise all of the rights set forth in (a) above in such translations, adaptations, summaries, extracts, Derivative Works or Collective Works and (c) to license others to do any or all of the above. The foregoing rights may be exercised in all media and formats, whether now known or hereafter devised, and include the right to make such modifications as are technically necessary to exercise the rights in other media and formats. For any Video to which this **Section 6** is applicable, JoVE and the Author hereby grant to the public all such rights in the Video as provided in, but subject to all limitations and requirements set forth in, the CRC License.

7. **Government Employees.** If the Author is a United States government employee and the Article was prepared in the course of his or her duties as a United States government employee, as indicated in **Item 2** above, and any of the licenses or grants granted by the Author hereunder exceed the scope of the 17 U.S.C. 403, then the rights granted hereunder shall be limited to the maximum

rights permitted under such statute. In such case, all provisions contained herein that are not in conflict with such statute shall remain in full force and effect, and all provisions contained herein that do so conflict shall be deemed to be amended so as to provide to JoVE the maximum rights permissible within such statute.

8. **Protection of the Work.** The Author(s) authorize JoVE to take steps in the Author(s) name and on their behalf if JoVE believes some third party could be infringing or might infringe the copyright of either the Author's Article and/or Video.

9. **Likeness, Privacy, Personality.** The Author hereby grants JoVE the right to use the Author's name, voice, likeness, picture, photograph, image, biography and performance in any way, commercial or otherwise, in connection with the Materials and the sale, promotion and distribution thereof. The Author hereby waives any and all rights he or she may have, relating to his or her appearance in the Video or otherwise relating to the Materials, under all applicable privacy, likeness, personality or similar laws.

10. **Author Warranties.** The Author represents and warrants that the Article is original, that it has not been published, that the copyright interest is owned by the Author (or, if more than one author is listed at the beginning of this Agreement, by such authors collectively) and has not been assigned, licensed, or otherwise transferred to any other party. The Author represents and warrants that the author(s) listed at the top of this Agreement are the only authors of the Materials. If more than one author is listed at the top of this Agreement and if any such author has not entered into a separate Article and Video License Agreement with JoVE relating to the Materials, the Author represents and warrants that the Author has been authorized by each of the other such authors to execute this Agreement on his or her behalf and to bind him or her with respect to the terms of this Agreement as if each of them had been a party hereto as an Author. The Author warrants that the use, reproduction, distribution, public or private performance or display, and/or modification of all or any portion of the Materials does not and will not violate, infringe and/or misappropriate the patent, trademark, intellectual property or other rights of any third party. The Author represents and warrants that it has and will continue to comply with all government, institutional and other regulations, including, without limitation all institutional, laboratory, hospital, ethical, human and animal treatment, privacy, and all other rules, regulations, laws, procedures or guidelines, applicable to the Materials, and that all research involving human and animal subjects has been approved by the Author's relevant institutional review board.

11. **JoVE Discretion.** If the Author requests the assistance of JoVE in producing the Video in the Author's facility, the Author shall ensure that the presence of JoVE employees, agents or independent contractors is in accordance with the relevant regulations of the Author's institution. If more than one author is listed at the beginning of this Agreement, JoVE may, in its sole

ARTICLE AND VIDEO LICENSE AGREEMENT

discretion, elect not take any action with respect to the Article until such time as it has received complete, executed Article and Video License Agreements from each such author. JoVE reserves the right, in its absolute and sole discretion and without giving any reason therefore, to accept or decline any work submitted to JoVE. JoVE and its employees, agents and independent contractors shall have full, unfettered access to the facilities of the Author or of the Author's institution as necessary to make the Video, whether actually published or not. JoVE has sole discretion as to the method of making and publishing the Materials, including, without limitation, to all decisions regarding editing, lighting, filming, timing of publication, if any, length, quality, content and the like.

12. **Indemnification.** The Author agrees to indemnify JoVE and/or its successors and assigns from and against any and all claims, costs, and expenses, including attorney's fees, arising out of any breach of any warranty or other representations contained herein. The Author further agrees to indemnify and hold harmless JoVE from and against any and all claims, costs, and expenses, including attorney's fees, resulting from the breach by the Author of any representation or warranty contained herein or from allegations or instances of violation of intellectual property rights, damage to the Author's or the Author's institution's facilities, fraud, libel, defamation, research, equipment, experiments, property damage, personal injury, violations of institutional, laboratory, hospital, ethical, human and animal treatment, privacy or other rules, regulations, laws, procedures or guidelines, liabilities and other losses or damages related in any way to the submission of work to JoVE, making of videos by JoVE, or publication in JoVE or elsewhere by JoVE. The Author shall be responsible for, and shall hold JoVE harmless from, damages caused by lack of sterilization, lack of cleanliness or by contamination due to


the making of a video by JoVE its employees, agents or independent contractors. All sterilization, cleanliness or decontamination procedures shall be solely the responsibility of the Author and shall be undertaken at the Author's expense. All indemnifications provided herein shall include JoVE's attorney's fees and costs related to said losses or damages. Such indemnification and holding harmless shall include such losses or damages incurred by, or in connection with, acts or omissions of JoVE, its employees, agents or independent contractors.

13. **Fees.** To cover the cost incurred for publication, JoVE must receive payment before production and publication the Materials. Payment is due in 21 days of invoice. Should the Materials not be published due to an editorial or production decision, these funds will be returned to the Author. Withdrawal by the Author of any submitted Materials after final peer review approval will result in a US\$1,200 fee to cover pre-production expenses incurred by JoVE. If payment is not received by the completion of filming, production and publication of the Materials will be suspended until payment is received.

14. **Transfer, Governing Law.** This Agreement may be assigned by JoVE and shall inure to the benefits of any of JoVE's successors and assignees. This Agreement shall be governed and construed by the internal laws of the Commonwealth of Massachusetts without giving effect to any conflict of law provision thereunder. This Agreement may be executed in counterparts, each of which shall be deemed an original, but all of which together shall be deemed to be one and the same agreement. A signed copy of this Agreement delivered by facsimile, e-mail or other means of electronic transmission shall be deemed to have the same legal effect as delivery of an original signed copy of this Agreement.

A signed copy of this document must be sent with all new submissions. Only one Agreement is required per submission.

CORRESPONDING AUTHOR

Name:	S. Ahmed Ali, M.D.	
Department:	Otolaryngology - Head & Neck Surgery	
Institution:	Michigan Medicine	
Title:	Resident Physician	
Signature:		Date: 10/8/2018

Please submit a **signed** and **dated** copy of this license by one of the following three methods:

1. Upload an electronic version on the JoVE submission site
2. Fax the document to +1.866.381.2236
3. Mail the document to JoVE / Attn: JoVE Editorial / 1 Alewife Center #200 / Cambridge, MA 02140

December 5th, 2018

Dear Editor,

Thank you for your continued consideration of this manuscript entitled “Facial Nerve Surgery in the Rat Model: Methods to Study Axonal Inhibition and Regeneration” for publication in the Journal of Visualized Experiments. We greatly appreciate the editorial and reviewer feedback. We have performed revisions to address all of the following reviewer comments:

Editorial Office

1. Please take this opportunity to thoroughly proofread the manuscript to ensure that there are no spelling or grammar issues.

The manuscript has been proofread for spelling and grammar issues.

2. Step 4.11.1: Please ensure that all text is written in the imperative tense.

The step has been updated to be in the imperative tense, as such on lines 222-225:

4.11.1. Crush injury: use smooth-surfaced jeweler’s forceps to firmly grasp the nerve and compress it. Apply constant and reproducible pressure to the nerve for a period of 30-seconds to ensure appropriate crush injury.

3. 4.8.1-4.8.4: Please write these steps in complete sentences and in the imperative tense.

The steps have been consolidated and now read in the imperative sense:

4.8.1. Note that this region is bounded superiorly and medially by the skull base, laterally by the anterior digastric muscle, postero-medially by the ear canal, and inferiorly by the structures of the neck, including the superficial temporal artery.

4. Step 6.1.1 is missing.

Step 6.1.2 has been amended to be 6.1.1.

5. Figure 2: Please define the error bars in Figure Legend.]

The error bars have been defined as such on line 303:

“... as mean proportion \pm standard error of the mean.”

We attest that this manuscript has not been published elsewhere, accepted for publication elsewhere, or under review for publication elsewhere. All authors listed have contributed sufficiently to the project to be included as authors. To the best of our knowledge, no conflict of interest, financial or other, exists.

Sincerely,

S. Ahmed Ali, MD
Department of Otolaryngology Head & Neck Surgery
University of Michigan Health System
1500 East Hospital Drive
Ann Arbor, MI 48109, United States of America
ahmedali@med.umich.edu

Michael J. Brenner, MD
Department of Otolaryngology - Head & Neck Surgery
University of Michigan Health System
1500 East Hospital Drive
Ann Arbor, MI 48109, United States of America
pthoff@med.umich.edu