

Journal of Visualized Experiments

Cardiac Magnetic Resonance for the Evaluation of Suspected Cardiac Thrombus: Conventional and Emerging Techniques --Manuscript Draft--

Article Type:	Invited Methods Article - JoVE Produced Video
Manuscript Number:	JoVE58808R3
Full Title:	Cardiac Magnetic Resonance for the Evaluation of Suspected Cardiac Thrombus: Conventional and Emerging Techniques
Keywords:	cardiac magnetic resonance; cardiac magnetic resonance; thrombus; thrombus; T1 mapping; T1 mapping; Magnetic resonance imaging; Magnetic resonance imaging; cardiac mass; cardiac mass; Tumor; Tumor
Corresponding Author:	Daniel Jeong H Lee Moffitt Cancer Center and Research Institute Tampa, UNITED STATES
Corresponding Author's Institution:	H Lee Moffitt Cancer Center and Research Institute
Corresponding Author E-Mail:	Daniel.Jeong@moffitt.org
Order of Authors:	Elizabeth M Johnson Kenneth Gage Sebastian Feuerlein Daniel Jeong
Additional Information:	
Question	Response
Please indicate whether this article will be Standard Access or Open Access.	Standard Access (US\$2,400)
Please indicate the city, state/province, and country where this article will be filmed . Please do not use abbreviations.	Tampa, Florida, USA

TITLE:

Cardiac Magnetic Resonance for the Evaluation of Suspected Cardiac Thrombus: Conventional and Emerging Techniques

AUTHORS AND AFFILIATIONS:

Elizabeth M. Johnson¹, Kenneth L. Gage², Sebastian Feuerlein², Daniel Jeong²

¹Department of Radiology, University of South Florida, Tampa, FL, USA

²Department of Diagnostic Imaging, H. Lee Moffitt Cancer Center and Research Institute, Tampa, FL, USA

Corresponding Author:

Daniel Jeong (Daniel.Jeong@moffitt.org)

Email Addresses of Co-authors:

Elizabeth M. Johnson (emjohnson2@health.usf.edu)

Kenneth L. Gage (kenneth.gage@moffitt.org)

Sebastian Feuerlein (sebastian.feuerlein@moffitt.org)

KEYWORDS:

Cardiac magnetic resonance, screening, cardiac mass, cardiac thrombus, first pass perfusion, late gadolinium enhancement, T1 mapping, tissue characterization, post processing

SUMMARY:

The goal of this article is to describe how cardiac magnetic resonance can be used for the evaluation and diagnosis of a suspected cardiac thrombus. The method presented will describe data acquisition as well as the pre-procedure and post-procedure protocol.

ABSTRACT:

We present the conventional cardiac magnetic resonance (CMR) protocol for evaluating a suspected thrombus and highlight emerging techniques. The appearance of a mass on certain magnetic resonance (MR) sequences can help differentiate a thrombus from competing diagnoses such as a tumor. T1 and T2 signal characteristics of a thrombus are related to the evolution of hemoglobin properties. A thrombus typically does not enhance following contrast administration, which also helps differentiation from a tumor. We also highlight the emerging role of T1 mapping in the evaluation of a thrombus, which can add another level of support in diagnosis. Prior to any CMR exam, patient screening and interviews are critical to ensure safety and to optimize patient comfort. Effective communication during the exam between the technologist and the patient promotes proper breath holding technique and higher quality images. Volumetric post processing and structured reporting are helpful to ensure that the radiologist answers the ordering services' question and communicates these results effectively. Optimal pre-MR safety evaluation, CMR exam execution, and post exam processing and reporting allow for delivery of high quality radiological service in the evaluation of a suspected cardiac thrombus.

INTRODUCTION:

Cardiac magnetic resonance (CMR) imaging is an important diagnostic modality for the evaluation of cardiovascular function and pathology. Technological advances allow for reduced acquisition time, improved spatial and temporal resolution, as well as higher quality tissue characterization. These advances are particularly useful in the evaluation of cardiac masses.

Echocardiography remains the first line imaging modality for the initial evaluation of cardiac masses, specifically with respect to mass location, morphology, and physiologic impact. However, echocardiography is limited by poor tissue characterization, a restricted field of view, and operator dependent image quality. Cardiac computed tomography (CT) is often utilized as a second-line imaging modality for assessing cardiac masses. Advantages of cardiac CT over other modalities include excellent spatial resolution and a superior ability in detecting calcifications. The main disadvantage of cardiac CT is patient exposure to ionizing radiation. Additional limitations include decreased temporal resolution and soft tissue contrast resolution. CMR is emerging as a valuable tool in the characterization of cardiac masses detected on echocardiography or CT. Compared to CT, CMR does not expose patients to ionizing radiation. In addition, CMR can be useful in treatment and surgical planning^{1,2}.

A thrombus is the most common cardiac mass. The most common locations for cardiac thrombi are the left atrium and left atrial appendage, especially in the setting of atrial fibrillation or a dysfunctional left ventricle^{1,3}. The diagnosis of thrombus is important for the prevention of embolic events as well as establishing the need for anticoagulation. CMR can aide in determining the acuity of a thrombus. Acute thrombus typically demonstrates intermediate T1- and T2-weighted signal intensity relative to the myocardium due to high amounts of oxygenated hemoglobin. Increased methemoglobin content in the subacute thrombus results in lower T1-weighted signal intensity and intermediate or increased T2-weighted signal intensity. With a chronic thrombus, methemoglobin and water are replaced with fibrous tissue leading to decreased T1- and T2-weighted signal intensity¹⁻³.

The avascular composition gives a cardiac thrombus intrinsic tissue characteristics that can be exploited by contrast enhanced CMR, to aide in the differentiation of a thrombus from other cardiac tumors⁴. An organized thrombus does not enhance while true cardiac lesions enhance on post contrast imaging due to the presence of intratumoral vascularity³. Arterial perfusion imaging allows real time assessment of vascularity within a mass and is critical to differentiate a thrombus from a tumor. Perfusion within a mass can also be useful in the delineation of a bland thrombus from a tumor thrombus. Cine imaging provides advantages over other modalities that can be subject to motion artifact, and the temporal resolution provided by real time gated perfusion imaging increases sensitivity in detecting enhancement⁵.

T1 mapping is a MR technique that allows pre-contrast native T1 relaxation times and post-contrast extracellular volume calculation to detect pathologic alterations in tissue. By adding a quantitative dimension to CMR, T1 mapping can help differentiate various disease processes from the normal myocardium. An emerging application is the characterization of cardiac

masses and delineation of masses from cardiac thrombi. Previous studies performed on a 1.5 T Aera XQ scanner have reported native T1 relaxation times of a recent thrombus (911 ± 177 ms) and a chronic thrombus (1169 ± 107 ms)⁶. Other pertinent native T1 relaxation times include lipoma (278 ± 29 ms), calcifications (621 ± 218 ms), melanoma (736 ms), and normal myocardium (950 ± 21 ms). This data suggests that T1 mapping can add quantitative information to a non-contrast exam which in the setting of contraindication to IV gadolinium could be extremely useful^{6,7}.

Contrast-enhanced CMR has been well validated for the detection of a left ventricular thrombus. It has been shown to provide the highest sensitivity and specificity (88% and 99%, respectively) for detection of a left ventricular thrombus compared to transthoracic (23% and 96%, respectively) and transesophageal (40% and 96%, respectively) echocardiography⁸. Currently, there are no large-scale studies validating the utility of CMR for assessing a thrombus in other chambers of the heart³.

Despite the many advantages of CMR over other imaging modalities for evaluating cardiac masses, there are also limitations. CMR, like cardiac CT, relies on electrocardiographic gating. This can cause artifact and image degradation in patients with significant arrhythmias. Image quality can also be degraded when scanning patients who have difficulty complying with breath hold requirements. However, faster acquisition times and respiratory gating techniques allow for quality images during free breathing. The presence of certain implanted devices is a contraindication for CMR and poses as a major disadvantage, although the number of MR compatible implantable devices is increasing^{1,2}.

In summary, specific CMR sequences can be utilized to develop a dedicated MR imaging protocol for the evaluation of a suspected cardiac thrombus. The method presented here will provide instructions for the acquisition of CMR data for evaluation of a suspected thrombus. Pre-procedure screening, sequence selection, troubleshooting, post-processing, volumetric analysis, and report generation will be discussed.

PROTOCOL:

The following protocol follows the departmental clinical guidelines and is adherent to the institution's human research ethics guidelines.

1. Prepare for MRI data acquisition

1.1. Conduct a safety screening.

1.1.1. Evaluate for renal impairment⁸.

1.1.1.1. Avoid gadolinium contrast in patients with stage 4 or 5 chronic kidney disease (estimated glomerular filtration rate <30 mL/min/1.71 m²) not on chronic dialysis, patients with

end-stage renal disease on chronic dialysis, and patients with known or suspected acute kidney injury due to concerns for NSF.

1.1.2. Determine necessity for sedation⁹.

NOTE: Moderate sedation or general anesthesia allows completion of the examination for patients suffering from anxiety or claustrophobia or pediatric patients.

1.1.2.1. Administer a lorazepam tablet up to 1 mg orally prior to scanning for patients with claustrophobia. Driving or machinery operation after medication administration is contraindicated.

1.1.3. Evaluate for implanted devices⁹.

1.1.3.1. Perform a careful review of the patient's history and safety to identify implanted devices that may be hazardous in the CMR environment or create image artifact.

1.1.3.2. Determine MR compatibility of patient implanted devices. Each case is reviewed for risks and benefits. The proper personnel are required to be present during the examination if CMR is to be performed in patients with non-MR safe devices.

1.1.3.3. Obtain radiographs to assist with screening, particularly orbit radiographs when there is possible history of metal fragments within the eye. Perform posterior-anterior radiographs with eyes up, eyes down, and a lateral view.

1.2. Provide patient instructions.

1.2.1. Deliver breathing instructions¹⁰.

1.2.1.1. Perform breath holding at end expiration as reproducibility is higher compared to inspiratory breath holds. For CMR, use the typical breath hold command: "breathe in, breathe out, stop breathing".

1.2.1.2. Provide patient with headphones connected to the technologist microphone so commands can be efficiently conveyed.

1.2.1.3. Perform free-breathing protocol when patient is unable to hold-breath for the exam due to sedation or medical condition. Free breathing protocols increase the number of averages (excitations) up to 4 and allow adequate free breathing image acquisition. Free breathing protocols can be selected from typical scanner exam libraries.

1.3. Setup physiological monitoring¹⁰.

1.3.1. Place electrocardiogram (ECG) leads in optimal positions on the left chest, and confirm adequate ECG signal.

1.4. Position the patient on the MRI scanner.

1.4.1. Ensure an appropriate surface coil size is chosen to maximize the signal-to-noise ratio over the heart. Often a dedicated cardiac coil is selected for optimal performance. Signal to noise correlates directly with image quality and is visually evident during scanning

1.4.2. Reduce field of view to maintain adequate spatial resolution. FOV is changed in the scanner settings directly and is dependent on patient size

2. Acquire the MRI data [cardiac MR without and with IV contrast limited] focused scan to evaluated potential cardiac thrombus

NOTE: Basic scan sequences are often loaded by the MRI technologist from scan libraries that are present on each MRI scanner. Standard cardiac scan prescription and orientations are also considered routine operating tasks for MRI technologists.

2.1. Obtain the Scout T1-weighted fast spin-echo including the trans-axial localizing stack⁴.

NOTE: This constitutes the first scan for each MRI exam and allows further sequences to be prescribed using spatial localization.

2.2. Obtain the Bright-blood, cine SSFP gradient-echo – axial stack with full heart coverage. This sequence offers the most consistent mass delineation and correlation with other radiology studies.

2.2.1. Obtain short axis, 2 chamber, 3 chamber, and 4-chamber planes as needed depending on clinical indications. Scan plane prescriptions are discussed in detail in Boegart¹¹.

NOTE: These acquisitions are non-dependent on flow effects which allow for short TR, improve temporal resolution, and permit determination of mobility of a thrombus. SSFP provides high SNR and CNR due to intrinsic contrast properties between myocardium and blood pool.

2.3. Perform the tissue characterization module^{1-3,11-12}.

2.3.1. Obtain the black-blood triple inversion recovery.

NOTE: This provides excellent contrast resolution for determining the size and the extent of the mass. It is useful for characterizing myocardial edema associated with mass or cystic component of mass and in detecting fat within the mass.

2.3.1.1. Obtain the black-blood double inversion recovery if there is a benefit of a bright fat signal. This is run as a separate sequence available in most CMR scanner sequence libraries where blood pool and myocardium signal are nulled while fat remains bright.

2.4. Perform the first-pass arterial perfusion module^{1-3,11-12}.

2.4.1. Obtain T1-weighted fat-saturated volumetric contrast-enhanced images; the axial plane is often most universal for mass visualization.

2.4.1.1. Begin imaging during contrast administration of 0.05 – 0.1 mmol/kg injected at 3-4 mL/s.

2.4.1.2. Image until the contrast passes through the LV myocardium (40-50 heart beats).

NOTE: A vascular tumor enhances during perfusion sequences while a thrombus does not enhance.

2.5. Perform the post gadolinium delayed viability module^{1-3,11-12}.

2.5.1. Obtain phase sensitive inversion recovery (PSIR), (~10 min post injection) 6-8 mm slices with inversion time set to null thrombus, to differentiate the thrombus from the tumor or delineate the thrombus surrounding or associated with the tumor.

2.5.1.1. Set the scan “time to inversion” (TI time) which changes in real time based on gadolinium kinetics and is typically set at 200– 450 ms at 1.5 T; 300-550 ms at 3 T. Set a new TI time into the scanner for each PSIR sequence run, which is usually higher than the previous time based on gadolinium kinetics.

NOTE: Serial imaging can be performed to distinguish hypo-perfused tumor necrotic core from thrombus. This is performed by repeating the PSIR sequence at multiple time points to evaluate gadolinium kinetics with the region of concern.

2.6. Consider obtaining emerging sequences¹³⁻¹⁹.

2.6.1. Obtain native T1 mapping (multiple protocols available).

NOTE: For example, use a single shot inversion recovery readout with a 5(3)3 scheme: inversion followed by 5 acquisition heartbeats, 3 recovery heartbeats, an additional inversion followed by 3 heartbeats.

2.6.2. Obtain post contrast T1 mapping (extracellular volume fraction).

NOTE: Post contrast Extracellular volume (ECV) represents a gadolinium-based measurement of the size of the extracellular space which primarily reflects interstitial disease. ECV is calculated

by comparing the changes in relaxivity of myocardium and blood pool prior to and following the administration of the IV contrast agent. Serum hematocrit is necessary to calculate ECV.

2.6.3. Obtain T2 mapping.

NOTE: T2 mapping can be derived from bright-blood T2 prepped SSFP sequence. Accurate application of T2 mapping requires a reference range for normal T2w signal; however, large interpatient variability of myocardial T2 signal can affect interpretation of results.

2.6.4. Obtain a cardiac triggered 3D spoiled gradient echo acquisition named 3D-QALAS (3D quantification).

NOTE: This sequence uses an interleaved look-locker acquisition sequence with T2-preparation and has been shown to be a feasible option for myocardial T1 and T2 mapping in a single breath hold.

3. Analysis of the MRI data

3.1. Perform post-processing^{2,20}.

3.1.1. Use an FDA-approved software for processing data either as part of the MRI system or on a separate workstation.

NOTE: Post-processing is performed or supervised by the cardiac MRI physician and appropriately documented in the report.

3.2. Assess ventricular chambers.

3.2.1. Perform visual analysis of global and segmental function and wall motion. Look for any wall motion abnormalities in all obtained planes.

3.2.2. Perform quantitative analysis of ventricular volumes and wall thicknesses. Ensure there is no abnormal thickening (>13 mm) or thinning of the left ventricular myocardium, which could suggest underlying pathology.

3.3. Evaluate T2-weighted imaging.

3.3.1. Visually analyze to detect or exclude regions of increased myocardial signal intensity indicating edema. For cardiac thrombus evaluation, the thrombus can have increased T2w signal intensity in the subacute time period and low T2w signal intensity in the chronic time period.

3.3.2. Perform semi-quantitative analysis of T2 signal intensity ratios, if needed. Using Picture Archiving and Communication Software (PACS), draw an ROI over a portion of the LV

myocardium and compare the LV T2 signal to skeletal muscle ROI signal. This can be useful in ruling out myocarditis.

3.4. Evaluate perfusion imaging.

3.4.1. Perform visual analysis to identify regions of relative hypoperfusion. In cardiac thrombus evaluation, the mass in question is carefully analyzed for any internal post contrast increased signal, which would suggest against thrombus and signify the presence of vascular tumor.

3.5. Evaluate late gadolinium enhancement (LGE) imaging within myocardium and any suspected masses.

3.5.1. Perform visual analysis to assess for the presence and the pattern of LGE. No solid regions of internal LGE are expected within a thrombus. However, a thin linear component of LGE can be seen along the outer margin of thrombus.

3.5.2. Perform visual analysis of location and extent of LGE.

3.5.3. Perform quantitative analysis with T1 mapping. Post processing software is used. Motion corrected sequences are used for analysis. Draw a region of interest over the mass of interest and over the myocardial regions of concern and record the pertinent T1 relaxation times.

NOTE: This is potentially helpful in distinguishing a thrombus from a tumor by providing quantitative assessment of pre-contrast T1 relaxation times.

3.6. Generate the report²⁰⁻²¹.

3.6.1. Include general study information.

3.6.1.1. Document the study site, scanner information including the manufacturer and the model, the field strength, and the software platform.

3.6.1.2. Document patient demographics.

3.6.1.3. Document the patient ID, gender, and date of birth.

3.6.1.4. Document the referring physician and service.

3.6.2. Include study performance information.

3.6.2.1. Document the date and time of examination, the personnel involved, the indication for examination, and the list of sequences used.

- 350 3.6.2.2. Document the patient history and risk factors.
351
- 352 3.6.2.3. Document the height, the weight, the heart rate, and the electrocardiogram
353 interpretation.
354
- 355 3.6.2.4. Document the contrast agent administered, the route, and the dose.
356
- 357 3.6.2.5. Document the amount, the type, the route, and the dose of sedation, if
358 applicable.
359
- 360 3.6.3. Report the cardiovascular imaging features.
361
- 362 3.6.3.1. Describe the cardiac size and function based on qualitative and quantitative
363 assessment.
364
- 365 3.6.3.1.1. Report the cardiac mass and describe the location, the anatomic relationships,
366 the 3-dimensional size, and the morphology.
367
- 368 3.6.3.1.2. Report the mass T1- and T2-weighted signal characteristics of the mass.
369 Classically, a thrombus will have low T1 and T2 signals. However, the T2w signal can vary with
370 the age of blood products.
371
- 372 3.6.3.1.3. Report the first pass perfusion pattern of the mass. The thrombus should have
373 no internal perfusion.
374
- 375 3.6.3.1.4. Report the late gadolinium enhancement pattern of the mass. Thrombus
376 generally has no internal LGE but may have thin linear LGE signal around the periphery.
377
- 378 3.6.3.1.5. Report the mass motion on cine imaging and its effect on myocardial
379 contractility.
380
- 381 3.6.3.1.6. Provide concluding statements synthesizing the findings into a comprehensive
382 impression
383

384 **REPRESENTATIVE RESULTS:**

385 The CMR protocol designed for the evaluation and diagnosis of cardiac thrombus encompasses
386 patient screening and preparation, data acquisition utilizing specific sequences, data post-
387 processing, and report generation. Specific signal characteristics on given sequences can infer
388 with high accuracy the diagnosis of a cardiac thrombus and differentiate these from the
389 competing diagnosis of a cardiac tumor. **Table 1** highlights the conventional and emerging CMR
390 sequences that are commonly used to evaluate for cardiac thrombus.
391

392 A cardiac thrombus has a low SSFP signal with absent internal perfusion and absent delayed
393 enhancement (**Figure 1 and Figure 3**). The T2 signal on dark blood imaging can vary depending

on the age of the blood products within the thrombus. In subacute thrombi, mildly increased T2w signal can be encountered (**Figure 3B**); whereas in chronic thrombus, low T2w signal is expected. Alterations in native T1 signal are also expected with chronic thrombus having elevated T1 relaxation times (**Figure 1D,E** and **Figure 3F**).

Pazos-Lopez et al. showed that CMR can differentiate a thrombus from other cardiac tumors with excellent accuracy²². Cardiac thrombi were smaller, more homogenous, and less mobile than tumors²². Higher or isointense signals compared to normal myocardium on T2w, first pass perfusion, and LGE sequences were more common in tumors vs. thrombi (85% vs. 42%, 70% vs. 4%, and 71% vs. 5%), respectively²².

FIGURE AND TABLE LEGENDS:

Figure 1: A 71-year-old male with history of prostate cancer and a left ventricular mass seen on CT. CMR demonstrates an intraluminal LV mass compatible with thrombus within an LV apical aneurysm with associated chronic LV infarct (A) Axial SSFP demonstrates LV apical wall thinning with an aneurysmal configuration at the apex. There is a low signal intraluminal structure within the LV apex. **(B)** Axial first pass arterial perfusion image: There is no perfusion within the LV apical structure. **(C)** 3 chamber LGE image: no LGE within the LV apex mass. LGE within the apical wall is >50% wall thickness compatible with previous infarct. **(D)** Color native T1 map demonstrates native T1 relaxation time within the LV apex mass of 1105 ms suggesting chronic bland thrombus. **(E)** Enlarged color native T1 map at LV apex: There is a thinned LV apex wall with the blue-green ROI T1 relaxation time measuring 1268 ms which is compatible with a prior infarct.

Figure 2: A 70-year-old male with hepatocellular carcinoma metastatic to the IVC and right atrium. This right atrial intraluminal metastasis is shown to provide comparison to intraluminal thrombus in other figures (A) Axial SSFP: A cavoatrial junction mass demonstrates low signal. **(B)** T2 dark blood: The high T2 signal within the mass (arrow) is nearly iso-intense to nearby hepatic tumors seen on the same image. **(C)** Axial Native T1 map color image (Siemens myomaps, Erlangen, Germany): the mass (arrow) demonstrates a native T1 relaxation time of 724 ms. **(D)** Coronal MRA: the mass is contiguous with adjacent hepatic tumor extending through the IVC into the right atrium (arrow).

Figure 3: A 61-year-old male with metastatic urothelial carcinoma with a right ventricular mass seen on CT which is compatible with thrombus on CMR. (A) Axial SSFP: A low signal mass near the RV apex is noted. **(B)** Axial T2 dark blood: there is isointense to mildly hyperintense T2 signal within the mass related to the presence of subacute blood products. **(C)** Axial dynamic arterial perfusion: no perfusion is seen within RV mass. **(D)** Axial post contrast CT: there is no enhancement within the RV mass. **(E)** Axial LGE: the non-enhancing RV mass is compatible with thrombus. **(F)** Grayscale pre-contrast native T1 Map demonstrates an elevated T1 relaxation time within the mass of 1094ms, which is compatible with thrombus.

DISCUSSION:

With the increasing quality and frequency of diagnostic imaging, it is not uncommon to discover incidental cardiac masses when performing imaging for unrelated indications. Patients with cardiac masses are often asymptomatic, and if present, symptoms are typically nonspecific.

The diagnosis of cardiac thrombus is important not only for differentiating thrombus from benign or malignant cardiac tumors, but also for determining the need for anticoagulation and prevention of embolic events¹. In patients with a suspected cardiac thrombus, the option for a single imaging modality with a specific protocol can provide for accurate and efficient diagnosis.

The protocol described includes specific CMR sequences designed for optimal localization and characterization of a suspected cardiac thrombus. For structural and functional evaluation, cine SSFP images are acquired in two-chamber, three-chamber, four-chamber, and short-axis views. SSFP imaging provides high spatial resolution and is not dependent on flow effects. This allows for a short time to repetition (TR), which improves temporal resolution. This is particularly useful for patients with breath-holding difficulty, and it aids in assessing for any mobility of a suspected thrombus. SSFP also provides a high signal to noise ratio (SNR) and contrast to noise ratio (CNR) due to intrinsic contrast properties between the myocardium and blood pool. For tissue characterization, black blood T1-weighted and T2-weighted double and triple inversion recovery FSE images are acquired with and without fat saturation. The T1-weighted images provide excellent contrast resolution for determining size and extent of the thrombus, as well as providing information on the presence or absence of recent hemorrhage or melanin due to T1 shortening. T1-weighted images also serve as a basis for comparison to post-contrast images. The fat-saturated images are useful for determining the presence of fat in a cardiac mass. The T2-weighted images are useful for characterizing myocardial edema associated with a mass, or to assess for a cystic component. Post gadolinium enhancement images are acquired during the injection of contrast (first pass perfusion) and repeated at approximately 10 minutes post-injection (LGE). The perfusion images are useful for distinguishing vascular tumor from a thrombus. For LGE, a phase-sensitive inversion recovery sequence is utilized, and the inversion time is set to null thrombus. This aids in differentiating a thrombus from a tumor. If there is a known tumor, this aids in delineating a thrombus surrounding or associated with a tumor¹⁻⁴.

We also highlight the emerging role of T1 mapping in the evaluation of thrombus which can add another level of support in diagnosis. T1 mapping is potentially helpful in distinguishing a thrombus from a tumor by providing quantitative assessment of pre-contrast T1 relaxation times. T1 mapping can also potentially differentiate between an acute and a chronic thrombus. More recent (<1 week) thrombi have been shown to have shorter T1 values compared to older (>1 month) thrombi⁶. Additionally, T1 mapping in addition to T2 mapping have shown to be useful for differentiating masses such as cardiac myxomas from myocardium²³.

Multiple imaging modalities can be employed to comprehensively evaluate cardiac masses, each possessing strengths and weaknesses. CMR is emerging as the imaging modality of choice for evaluating cardiac masses. CMR allows for the qualitative and quantitative assessment of cardiac anatomy, function, perfusion, and tissue characteristics in a single examination. Unlike CT, CMR does not expose patients to ionizing radiation. In contrast to echocardiography which

suffers from poor tissue characterization and limited field of view, CMR offers superior tissue characterization, high spatial and temporal resolution, multiplanar imaging capabilities, and a larger field of view¹⁻³.

Prior to any CMR exam, patient screening and interviews are critical to ensure safety and to optimize patient comfort. Effective communication during the exam, between the technologist and the patient, promotes proper breath holding technique and high quality images. Volumetric post processing and structured reporting are helpful to ensure the radiologist answers the ordering services' question and communicates these results effectively. Optimal safety screening evaluation, CMR exam execution, exam post-processing, and reporting allow for delivery of high quality radiological service in the evaluation of suspected cardiac thrombus.

ACKNOWLEDGMENTS:

The authors acknowledge support from the Department of Diagnostic Imaging at the H. Lee Moffitt Cancer Center and Research Institute.

DISCLOSURES:

The authors have nothing to disclose.

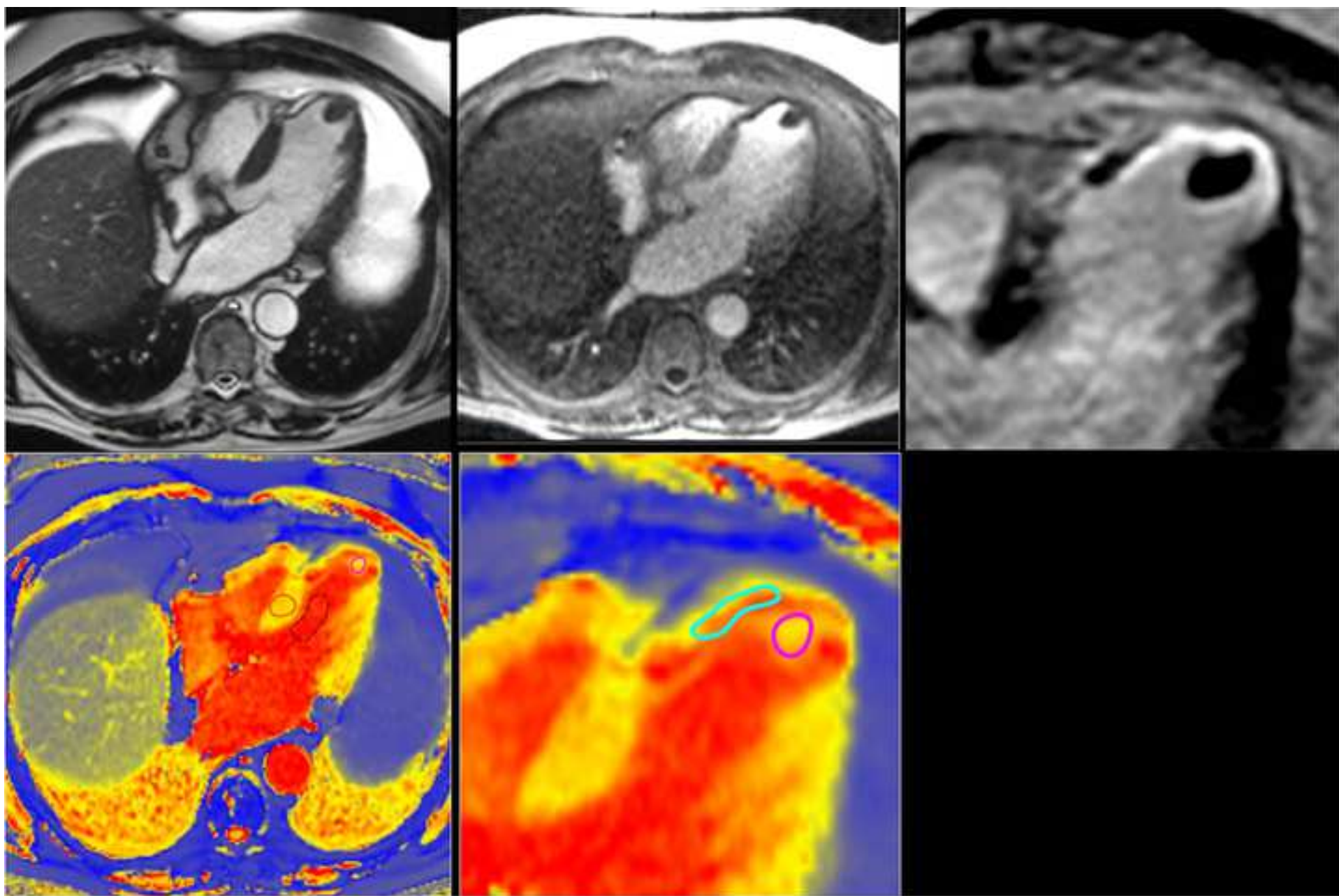
REFERENCES:


1. Lichtenberger, J.P., Dulberger, A.R., Gonzales, P.E., Bueno, J., Carter, B.W. MR imaging of cardiac masses. *Topics in Magnetic Resonance Imaging*. **27** (2), 103-111 (2018).
2. Motwani, M. et al. MR imaging of cardiac tumors and masses: a review of methods and clinical applications. *Radiology*. **268** (1), 26-43 (2013).
3. Jeong, D., Patel, A., Francois, C.J., Gage, K.L., Fradley, M.G. Cardiac magnetic resonance imaging in oncology. *Cancer Control*. **24** (2), 147-160 (2017).
4. Goyal, P., Weinsaft, J.W. Cardiovascular magnetic resonance imaging for assessment of cardiac thrombus. *Methodist DeBakey Cardiovascular Journal*. **9** (3), 132-136 (2013).
5. Jeong, D., Gage, K.L., Berman, C.G., Montilla-Soler, J.L. Cardiac magnetic resonance for evaluating catheter related FDG avidity. *Case Reports in Radiology*. 1-4 (2016).
6. Caspar, T. et al. Magnetic resonance evaluation of cardiac thrombi and masses by T1 and T2 mapping: an observational study. *International Journal of Cardiovascular Imaging*. **33** (4), 551-559 (2017).
7. Ferreira, V.M. et al. Non-contrast T1-mapping detects acute myocardial edema with high diagnostic accuracy: a comparison to T2-weighted cardiovascular magnetic resonance. *Journal of Cardiovascular Magnetic Resonance*. **14** (42), (2012).
8. Srichai, M.B. et al. Clinical, imaging, and pathological characteristics of left ventricular thrombus: a comparison of contrast-enhanced magnetic resonance imaging, transthoracic echocardiography, and transesophageal echocardiography with surgical or pathological validation. *American Heart Journal*. **152** (1), 75-84 (2006).
9. American College of Radiology. ACR committee on drugs and contrast media. Available at: https://www.acr.org/-/media/ACR/Files/Clinical-Resources/Contrast_Media.pdf. Accessed July 17, 2018. 1-127. Version 10.3 (2018).

10. American College of Radiology. ACR-NASCI-SPR practice parameter for the performance and interpretation of cardiac magnetic resonance imaging (MRI). Available at: <https://www.acr.org/-/media/ACR/Files/Practice-Parameters/MR-Cardiac.pdf>. Accessed July 17, 2018. (Resolution 5). 1-12. Revised (2016).
11. Bogaert, J., Dymarkowski, S., Taylor, A.M. Clinical cardiac MRI. Springer, Berlin Heidelberg New York (2005).
12. Kramer, C.M., Barkhausen, J., Flamm, S.D., Kim, R.J., Nagel, E. Standardized cardiovascular magnetic resonance (CMR) protocols 2013 update. *Journal of Cardiovascular Magnetic Resonance*. **15** (91), 1-10 (2013).
13. Fratz, S. et al. Guidelines and protocols for cardiovascular magnetic resonance in children and adults with congenital heart disease: SCMR expert consensus group on congenital heart disease. *Journal of Cardiovascular Magnetic Resonance*. **15** (51), 1-26 (2013).
14. Al-Wakeel-Marquard, N. et al. Cardiac T1 mapping in congenital heart disease: bolus vs. infusion protocols for measurements of myocardial extracellular volume fraction. *International Journal of Cardiovascular Imaging*. **33** (12), 1961-1968 (2017).
15. Messroghli, D.R. et al. Modified Look-Locker inversion recovery (MOLLI) for high resolution T1 mapping of the heart. *Magnetic Resonance Medicine*. **52** (1), 141–6 (2004).
16. Messroghli, D.R. et al. Clinical recommendations for cardiovascular magnetic resonance mapping of T1, T2, T2* and extracellular volume: A consensus statement by the Society for Cardiovascular Magnetic Resonance (SCMR) endorsed by the European Association for Cardiovascular Imaging (EACVI). *Journal of Cardiovascular Magnetic Resonance*. **19** (1), 75 (2017).
17. Foltz, W.D., Al-Kwif, O., Sussman, M.S., Stainsby, J.A., Wright, G.A. Optimized spiral imaging for measurement of myocardial T2 relaxation. *Magnetic Resonance Medicine*. **49** (6), 1089–97 (2003).
18. Kvernby, S. et al. Simultaneous three-dimensional myocardial T1 and T2 mapping in one breath hold with 3D-QALAS. *Journal of Cardiovascular Magnetic Resonance*. **20** (16), 102 (2014).
19. Kvernby, S. et al. Clinical feasibility of 3D-QALAS – single breath-hold 3D myocardial T1 and T2-mapping. *Magnetic Resonance Imaging*. **38**, 13-20 (2017).
20. Schulz-Menger, J. et al. Standardized image interpretation and post processing in cardiovascular magnetic resonance: Society for cardiovascular magnetic resonance (SCMR) Board of Trustees task force on standardized post processing. *Journal of Cardiovascular Magnetic Resonance*. **15** (35), 1-19 (2013).
21. Hundley, W.G. et al. Society for cardiovascular magnetic resonance guidelines for reporting cardiovascular magnetic resonance examinations. *Journal of Cardiovascular Magnetic Resonance*. **11** (5), 1-11 (2009).
22. Pazos-Lopez, P. et al. Value of CMR for the differential diagnosis of cardiac masses. *Journal of the American College of Cardiology: Cardiovascular Imaging*. **7** (9), 896-905 (2014).
23. Kubler, D. et al. T1 and T2 mapping for tissue characterization of cardiac myxoma. *International Journal of Cardiology*. **169** (1), e17-20 (2013).



Figure 1

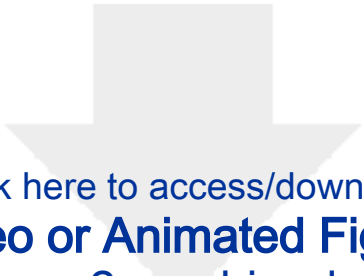
[Click here to access/download;Figure;Figure 1 combined.jpg](#)







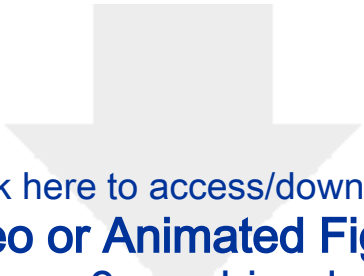
Click here to access/download
Video or Animated Figure
Figure 1 combined.svg





Click here to access/download
Video or Animated Figure
Figure 2 combined.svg





Click here to access/download
Video or Animated Figure
Figure 3 combined.svg





Table 1: CMR sequences for thrombus evaluation

Conventional CMR Sequences	Indications	Comments
Cine SSFP	Bright blood structure and function evaluation	Mass delineation and mobility evaluation. Axial plane is often helpful to correlate with previous radiological imaging.
T2w - Triple IR	Saturated blood, fat, and myocardium	Helpful to distinguish thrombus from avidly T2w hyperintense masses such as myxomas.
1 st pass arterial perfusion	Mass characterization, ischemia evaluation	Thrombus will have no perfusion while vascular masses will perfuse
Delayed Viability	Myocardial ischemia/disease characterization	Thrombus may have subtle delayed rim enhancement but no internal enhancement
Emerging CMR sequences		
T1 Mapping (pre contrast native T1 and post contrast extracellular volume)	Quantification of T1 relaxation times within myocardium and masses.	T1 values are dependent on field strength and scanner/prescription.
T2 Mapping	Quantification of T2 relaxation times. Myocardial and mass characterization.	T2 signal is sensitive to mild stressors such as viral illness. Large inter-patient T2w signal variability limiting widespread utility

CMR – cardiac magnetic resonance; SSFP – steady state free precession; T2w – T2 weighted; IR – inversion recovery;

Name of Material/ Equipment	Company
MRI Scanner	Siemens Healthcare
Post processing software	Medis
Scanner processing software	Siemens Healthcare

Location	Catalog Number
Erlangen, Germany	Magnetom Aera 1.5 Tesla
The Netherlands	Qmass software
Erlangen, Germany	Myomaps

Comments/Description

MRI scanner that will be used for the demonstration

post processing software for ventricular volumetric and T1 mapping analysis

Scanner sequence package and post processing software



1 Alewife Center #200
Cambridge, MA 02140
tel. 617.945.9051
www.jove.com

ARTICLE AND VIDEO LICENSE AGREEMENT

Title of Article:	Cardiac Magnetic Resonance for the diagnosis of thrombus: conventional and emerging imaging techniques
Author(s):	Elizabeth M. Johnson, Kenneth Gage, Sebastian Feuerlein, Daniel Jeong

Item 1: The Author elects to have the Materials be made available (as described at <http://www.jove.com/publish>) via:

☒ Standard Access

☐ Open Access

Item 2: Please select one of the following items:

☒ The Author is **NOT** a United States government employee.

☐ The Author is a United States government employee and the Materials were prepared in the course of his or her duties as a United States government employee.

☐ The Author is a United States government employee but the Materials were NOT prepared in the course of his or her duties as a United States government employee.

ARTICLE AND VIDEO LICENSE AGREEMENT

1. **Defined Terms.** As used in this Article and Video License Agreement, the following terms shall have the following meanings: **"Agreement"** means this Article and Video License Agreement; **"Article"** means the article specified on the last page of this Agreement, including any associated materials such as texts, figures, tables, artwork, abstracts, or summaries contained therein; **"Author"** means the author who is a signatory to this Agreement; **"Collective Work"** means a work, such as a periodical issue, anthology or encyclopedia, in which the Materials in their entirety in unmodified form, along with a number of other contributions, constituting separate and independent works in themselves, are assembled into a collective whole; **"CRC License"** means the Creative Commons Attribution-Non Commercial-No Derivs 3.0 Unported Agreement, the terms and conditions of which can be found at: <http://creativecommons.org/licenses/by-nc-nd/3.0/legalcode>; **"Derivative Work"** means a work based upon the Materials or upon the Materials and other pre-existing works, such as a translation, musical arrangement, dramatization, fictionalization, motion picture version, sound recording, art reproduction, abridgment, condensation, or any other form in which the Materials may be recast, transformed, or adapted; **"Institution"** means the institution, listed on the last page of this Agreement, by which the Author was employed at the time of the creation of the Materials; **"JoVE"** means MyJoVE Corporation, a Massachusetts corporation and the publisher of The Journal of Visualized Experiments; **"Materials"** means the Article and / or the Video; **"Parties"** means the Author and JoVE; **"Video"** means any video(s) made by the Author, alone or in conjunction with any other parties, or by JoVE or its affiliates or agents, individually or in collaboration with the Author or any other parties, incorporating all or any portion

of the Article, and in which the Author may or may not appear.

2. **Background.** The Author, who is the author of the Article, in order to ensure the dissemination and protection of the Article, desires to have the JoVE publish the Article and create and transmit videos based on the Article. In furtherance of such goals, the Parties desire to memorialize in this Agreement the respective rights of each Party in and to the Article and the Video.

3. **Grant of Rights in Article.** In consideration of JoVE agreeing to publish the Article, the Author hereby grants to JoVE, subject to **Sections 4** and **7** below, the exclusive, royalty-free, perpetual (for the full term of copyright in the Article, including any extensions thereto) license (a) to publish, reproduce, distribute, display and store the Article in all forms, formats and media whether now known or hereafter developed (including without limitation in print, digital and electronic form) throughout the world, (b) to translate the Article into other languages, create adaptations, summaries or extracts of the Article or other Derivative Works (including, without limitation, the Video) or Collective Works based on all or any portion of the Article and exercise all of the rights set forth in (a) above in such translations, adaptations, summaries, extracts, Derivative Works or Collective Works and (c) to license others to do any or all of the above. The foregoing rights may be exercised in all media and formats, whether now known or hereafter devised, and include the right to make such modifications as are technically necessary to exercise the rights in other media and formats. If the "Open Access" box has been checked in **Item 1** above, JoVE and the Author hereby grant to the public all such rights in the Article as provided in, but subject to all limitations and requirements set forth in, the CRC License.

ARTICLE AND VIDEO LICENSE AGREEMENT

4. **Retention of Rights in Article.** Notwithstanding the exclusive license granted to JoVE in **Section 3** above, the Author shall, with respect to the Article, retain the non-exclusive right to use all or part of the Article for the non-commercial purpose of giving lectures, presentations or teaching classes, and to post a copy of the Article on the Institution's website or the Author's personal website, in each case provided that a link to the Article on the JoVE website is provided and notice of JoVE's copyright in the Article is included. All non-copyright intellectual property rights in and to the Article, such as patent rights, shall remain with the Author.

5. **Grant of Rights in Video – Standard Access.** This **Section 5** applies if the "Standard Access" box has been checked in **Item 1** above or if no box has been checked in **Item 1** above. In consideration of JoVE agreeing to produce, display or otherwise assist with the Video, the Author hereby acknowledges and agrees that, Subject to **Section 7** below, JoVE is and shall be the sole and exclusive owner of all rights of any nature, including, without limitation, all copyrights, in and to the Video. To the extent that, by law, the Author is deemed, now or at any time in the future, to have any rights of any nature in or to the Video, the Author hereby disclaims all such rights and transfers all such rights to JoVE.

6. **Grant of Rights in Video – Open Access.** This **Section 6** applies only if the "Open Access" box has been checked in **Item 1** above. In consideration of JoVE agreeing to produce, display or otherwise assist with the Video, the Author hereby grants to JoVE, subject to **Section 7** below, the exclusive, royalty-free, perpetual (for the full term of copyright in the Article, including any extensions thereto) license (a) to publish, reproduce, distribute, display and store the Video in all forms, formats and media whether now known or hereafter developed (including without limitation in print, digital and electronic form) throughout the world, (b) to translate the Video into other languages, create adaptations, summaries or extracts of the Video or other Derivative Works or Collective Works based on all or any portion of the Video and exercise all of the rights set forth in (a) above in such translations, adaptations, summaries, extracts, Derivative Works or Collective Works and (c) to license others to do any or all of the above. The foregoing rights may be exercised in all media and formats, whether now known or hereafter devised, and include the right to make such modifications as are technically necessary to exercise the rights in other media and formats. For any Video to which this **Section 6** is applicable, JoVE and the Author hereby grant to the public all such rights in the Video as provided in, but subject to all limitations and requirements set forth in, the CRC License.

7. **Government Employees.** If the Author is a United States government employee and the Article was prepared in the course of his or her duties as a United States government employee, as indicated in **Item 2** above, and any of the licenses or grants granted by the Author hereunder exceed the scope of the 17 U.S.C. 403, then the rights granted hereunder shall be limited to the maximum

rights permitted under such statute. In such case, all provisions contained herein that are not in conflict with such statute shall remain in full force and effect, and all provisions contained herein that do so conflict shall be deemed to be amended so as to provide to JoVE the maximum rights permissible within such statute.

8. **Protection of the Work.** The Author(s) authorize JoVE to take steps in the Author(s) name and on their behalf if JoVE believes some third party could be infringing or might infringe the copyright of either the Author's Article and/or Video.

9. **Likeness, Privacy, Personality.** The Author hereby grants JoVE the right to use the Author's name, voice, likeness, picture, photograph, image, biography and performance in any way, commercial or otherwise, in connection with the Materials and the sale, promotion and distribution thereof. The Author hereby waives any and all rights he or she may have, relating to his or her appearance in the Video or otherwise relating to the Materials, under all applicable privacy, likeness, personality or similar laws.

10. **Author Warranties.** The Author represents and warrants that the Article is original, that it has not been published, that the copyright interest is owned by the Author (or, if more than one author is listed at the beginning of this Agreement, by such authors collectively) and has not been assigned, licensed, or otherwise transferred to any other party. The Author represents and warrants that the author(s) listed at the top of this Agreement are the only authors of the Materials. If more than one author is listed at the top of this Agreement and if any such author has not entered into a separate Article and Video License Agreement with JoVE relating to the Materials, the Author represents and warrants that the Author has been authorized by each of the other such authors to execute this Agreement on his or her behalf and to bind him or her with respect to the terms of this Agreement as if each of them had been a party hereto as an Author. The Author warrants that the use, reproduction, distribution, public or private performance or display, and/or modification of all or any portion of the Materials does not and will not violate, infringe and/or misappropriate the patent, trademark, intellectual property or other rights of any third party. The Author represents and warrants that it has and will continue to comply with all government, institutional and other regulations, including, without limitation all institutional, laboratory, hospital, ethical, human and animal treatment, privacy, and all other rules, regulations, laws, procedures or guidelines, applicable to the Materials, and that all research involving human and animal subjects has been approved by the Author's relevant institutional review board.

11. **JoVE Discretion.** If the Author requests the assistance of JoVE in producing the Video in the Author's facility, the Author shall ensure that the presence of JoVE employees, agents or independent contractors is in accordance with the relevant regulations of the Author's institution. If more than one author is listed at the beginning of this Agreement, JoVE may, in its sole

ARTICLE AND VIDEO LICENSE AGREEMENT

discretion, elect not take any action with respect to the Article until such time as it has received complete, executed Article and Video License Agreements from each such author. JoVE reserves the right, in its absolute and sole discretion and without giving any reason therefore, to accept or decline any work submitted to JoVE. JoVE and its employees, agents and independent contractors shall have full, unfettered access to the facilities of the Author or of the Author's institution as necessary to make the Video, whether actually published or not. JoVE has sole discretion as to the method of making and publishing the Materials, including, without limitation, to all decisions regarding editing, lighting, filming, timing of publication, if any, length, quality, content and the like.

12. **Indemnification.** The Author agrees to indemnify JoVE and/or its successors and assigns from and against any and all claims, costs, and expenses, including attorney's fees, arising out of any breach of any warranty or other representations contained herein. The Author further agrees to indemnify and hold harmless JoVE from and against any and all claims, costs, and expenses, including attorney's fees, resulting from the breach by the Author of any representation or warranty contained herein or from allegations or instances of violation of intellectual property rights, damage to the Author's or the Author's institution's facilities, fraud, libel, defamation, research, equipment, experiments, property damage, personal injury, violations of institutional, laboratory, hospital, ethical, human and animal treatment, privacy or other rules, regulations, laws, procedures or guidelines, liabilities and other losses or damages related in any way to the submission of work to JoVE, making of videos by JoVE, or publication in JoVE or elsewhere by JoVE. The Author shall be responsible for, and shall hold JoVE harmless from, damages caused by lack of sterilization, lack of cleanliness or by contamination due to


the making of a video by JoVE its employees, agents or independent contractors. All sterilization, cleanliness or decontamination procedures shall be solely the responsibility of the Author and shall be undertaken at the Author's expense. All indemnifications provided herein shall include JoVE's attorney's fees and costs related to said losses or damages. Such indemnification and holding harmless shall include such losses or damages incurred by, or in connection with, acts or omissions of JoVE, its employees, agents or independent contractors.

13. **Fees.** To cover the cost incurred for publication, JoVE must receive payment before production and publication the Materials. Payment is due in 21 days of invoice. Should the Materials not be published due to an editorial or production decision, these funds will be returned to the Author. Withdrawal by the Author of any submitted Materials after final peer review approval will result in a US\$1,200 fee to cover pre-production expenses incurred by JoVE. If payment is not received by the completion of filming, production and publication of the Materials will be suspended until payment is received.

14. **Transfer, Governing Law.** This Agreement may be assigned by JoVE and shall inure to the benefits of any of JoVE's successors and assignees. This Agreement shall be governed and construed by the internal laws of the Commonwealth of Massachusetts without giving effect to any conflict of law provision thereunder. This Agreement may be executed in counterparts, each of which shall be deemed an original, but all of which together shall be deemed to be one and the same agreement. A signed copy of this Agreement delivered by facsimile, e-mail or other means of electronic transmission shall be deemed to have the same legal effect as delivery of an original signed copy of this Agreement.

A signed copy of this document must be sent with all new submissions. Only one Agreement is required per submission.

CORRESPONDING AUTHOR

Name:	Daniel Jeong		
Department:	Diagnostic Imaging and Interventional Radiology		
Institution:	H. Lee Moffitt Cancer Center and Research Institute		
Title:	Assistant Member and Assistant Professor		
Signature:		Date:	7/17/2018

Please submit a **signed** and **dated** copy of this license by one of the following three methods:

1. Upload an electronic version on the JoVE submission site
2. Fax the document to +1.866.381.2236
3. Mail the document to JoVE / Attn: JoVE Editorial / 1 Alewife Center #200 / Cambridge, MA 02140

Dear Editors:

Thank you again for your consideration of our manuscript for your journal

We highly appreciate the suggestions from the editors regarding the changes to improve the writing and we have implemented all suggested changes. We have also employed two additional expert editors to carefully review the manuscript for any additional grammatical improvements. I have assembled the corrections from the copy editors into the marked version provided by JoVE which are visualized in blue font.

In addition to the JoVE editor changes which were implemented, additional changes from our copy editors are noted in the following lines:

55, 66, 71, 76, 90, 207-208, 235, 263, 266, 271, 331-332, 335, 373, 380, 383, 394, 405, 412, 414, 417-418, 421-422, 424-431, 433-434, 437-438, 440, 457, 463-464, 468, 483, 489-490, 492, 494, 497.

Additionally, minor changes to the references section were made to assure compliance with JoVE formatting.

We hope that you will find the changes acceptable and we appreciate your time and effort with the review process.

Sincerely,

Daniel Jeong