

Journal of Visualized Experiments

Screening of Axonal Degeneration in Carpal Tunnel Syndrome Using Ultrasonography and Nerve Conduction Studies --Manuscript Draft--

Article Type:	Invited Methods Article - JoVE Produced Video
Manuscript Number:	JoVE58681R2
Full Title:	Screening of Axonal Degeneration in Carpal Tunnel Syndrome Using Ultrasonography and Nerve Conduction Studies
Keywords:	carpal tunnel syndrome; nerve conduction studies; ultrasonography; axonal degeneration; demyelination; peripheral nerve compression injuries
Corresponding Author:	Xue DENG, Msc University of Hong Kong Pokfulam, Hong Kong HONG KONG
Corresponding Author's Institution:	University of Hong Kong
Corresponding Author E-Mail:	dannytang023@gmail.com
Order of Authors:	Xue DENG, Msc Lai-Heung Phoebe Chau Suk-Yee Chiu Kwok-Pui Leung Yong Hu Wing-Yuk Ip
Additional Information:	
Question	Response
Please indicate whether this article will be Standard Access or Open Access.	Standard Access (US\$2,400)
Please indicate the city, state/province, and country where this article will be filmed . Please do not use abbreviations.	Block C, 9/F, Clinical Electrodiagnostic Unit, 12 Po Yan Street, Sheung Wan, Hong Kong

TITLE:

Screening of Axonal Degeneration in Carpal Tunnel Syndrome Using Ultrasonography and Nerve Conduction Studies

AUTHORS AND AFFILIATIONS:

Xue Deng¹, Lai-Heung Phoebe Chau², Suk-Yee Chiu², Kwok-Pui Leung³, Yong Hu¹, Wing-Yuk Ip¹

¹Department of Orthopedics & Traumatology, The University of Hong Kong, Hong Kong Special Administrative Region, China

²Clinical Electro-diagnostic Unit, Tung Wah Hospital, Hong Kong Special Administrative Region, China

³Department of Medicine, The University of Hong Kong, Hong Kong Special Administrative Region, China

Corresponding Author:

Wing-Yuk Ip (wyip@hku.hk)

Tel: (852) 2255 4581

Email Addresses of Co-authors:

Xue Deng (danny023@connect.hku.hk)

Lai-Heung Phoebe Chau (3bchau@gmail.com)

Suk-Yee Chiu (csy673@ha.org.hk)

Kwok-Pui Leung (kpleungb@hku.hk)

Yong Hu (yhud@hku.hk)

KEYWORDS:

Carpal tunnel syndrome; ultrasound; nerve conduction studies; demyelination; axonal degeneration; diagnostic accuracy

SUMMARY:

Here we present a protocol using nerve conduction studies and ultrasound to screen potential axonal degeneration associated with carpal tunnel syndrome. The criteria for differentiation are established. Compared to conventional approaches, this method is noninvasive, convenient, and efficient, with an overall satisfactory accuracy, sensitivity, and specificity.

ABSTRACT:

Axonal degeneration, indicative of surgical decompression, may coexist in carpal tunnel syndrome (CTS) as the disease progresses. However, the current diagnostic and severity gradation system cannot clearly indicate its coexistence, resulting in a confusion of appropriate treatment prescriptions. There are also constraints in conventional methods for the differentiation as well. This study aims at introducing an innovative, efficient, and quick screening protocol to differentiate axonal degeneration associated with CTS, using ultrasound and nerve conduction studies (NCS). It starts by using NCS to perform orthodromic stimulation at the wrist, to obtain the sensory evoked potential of the median and the ulnar nerves respectively.

Meanwhile, the motor-evoked potential of the median nerve is collected by stimulating the palm, wrist, and elbow, followed by the stimulation of the ulnar nerve at the wrist and below and above the elbow. Then, an ultrasound assessment is performed, using a linear array transducer, by calculating the cross-sectional area (CSA) and perimeter (P) at the wrist and at the one-third distal forearm. Ratios (R-CSA, R-P) and changes from wrist to one-third distal forearm (Δ CSA and Δ P) are calculated according to a standard format. Potential axonal degeneration coexisting in CTS will be screened according to the criteria of NCS and cut-off values of ultrasound measurements established in a previous study. In terms of its noninvasiveness, low cost, convenience, and efficiency, it is easy to apply ultrasound complementarily in clinical practice to prescreen patients with potential coexisting axonal degeneration. Nevertheless, the ultrasonographic imaging cannot directly reflect axonal degeneration. It still relies on conventional but invasive methods, such as electromyography (EMG) and biopsy, for confirmation.

INTRODUCTION:

CTS is, pathologically, a disorder with segmental demyelination, whereas secondary axonal degeneration, which is indicative of surgical decompression, may coexist as the disease progresses¹. However, the current diagnostic and severity gradation scale (from mild to very severe grade) for CTS cannot clearly indicate any coexistence of axonal degeneration, resulting in confusion when choosing the appropriate treatment. Conventional methods for confirming axonal degeneration, such as needle EMG and nerve biopsy, can be sensitive and accurate, but they are both restricted in the clinical practice due to their invasiveness².

To overcome these shortcomings, ultrasound has been introduced for assisting in the diagnosing³⁻⁵ and grading of the severity of CTS⁶⁻⁸. Also, previous study successfully identified its cut-off values for discriminating axonal degeneration associated with CTS, with overall satisfactory sensitivity and specificity⁹. This study aims at introducing this efficient and noninvasive protocol to the practice in the clinical context. The rationale of this protocol is to combine the neurophysiological and structural information provided by NCS and ultrasounds, respectively, to indicate the pathological progress^{1,10}. It is assumed to be more accurate to describe the pathological progress than the current severity gradation system, helping clinicians to better figure out a plan of care. Compared to other conventional neuroimaging techniques, such as diffusion tensor imaging (DTI), this evidence-based approach can also be more easily applied in clinical settings, with lower costs¹¹.

PROTOCOL:

All the procedures have been approved by the University of Hong Kong/Hospital authorities Hong Kong West Institutional Review Board (HKU/HA HKW IRB, Ref. Number: UW17-129).

This protocol is applicable to patients who demonstrated clinical symptoms such as numbness, tingling, or pain over the median nerve-innervated area of the hand, with a positive outcome in Tinel's sign and Phalen's test. Those subjects with comorbidities, such as diabetes mellitus, cancer, rheumatoid arthritis, and other peripheral neuropathies, are not eligible for this protocol.

1. Measurement of the Nerve Conduction Studies

1.1. Ask the patient to wash his/her hands with warm water. Dry the hands before placing the electrodes. Keep the hand skin temperature above 32 °C.

1.2. Measure the conduction in the median sensory nerve (**Figure 1**).

1.2.1. Place the recording (E1) ring electrode at the proximal interphalangeal joint while the reference electrode (E2) is attached over the distal interphalangeal joint.

1.2.2. Place the recording electrodes at the wrist between the tendons of the flexor carpal radialis and palmaris longus (12 cm proximal to the E1 electrode) and, ideally, proximal to the distal wrist crease. Ensure that the ground electrode is between the stimulation and recording sites.

1.2.3. Apply supramaximal stimulus 10x to the median nerve *via* the attached electrodes over the index finger.

1.2.4. Collect the averaged readings of the distal sensory latency, the sensory nerve action potential (SNAP) amplitude, and the conduction velocities displayed in the NCS system.

1.3. Measure the conduction in the ulnar sensory nerve (**Figure 1**).

1.3.1. Place the E1 ring electrode halfway on the proximal phalanx of the fifth digit while the E2 ring electrode should be located 4 cm distal to the E1 ring electrode.

1.3.2. Place the recording electrodes near the tendon of the flexor carpi ulnaris (12 cm proximal to the E1 ring electrode). Ensure that the ground electrode is between the stimulation and recording sites.

1.3.3. Apply supramaximal stimulus 10x to the ulnar nerve *via* attached electrodes over the fifth finger.

1.3.4. Collect the averaged readings of the distal sensory latency, the SNAP amplitude, and the conduction velocities of the ulnar nerve displayed in the NCS system.

1.4. Measure the conduction in the median motor nerve (**Figure 2**).

1.4.1. Place the recording electrode E1 in the most prominent eminence of the thenar area at the motor point of the abductor pollicis brevis (APB).

1.4.2. Place the reference electrode E2 on the proximal phalanx of the thumb.

1.4.3. Stimulate at the mid-palm (3 to 4 cm distal to the distal wrist crease), 6.5 cm proximal to the E1 at the wrist (between the tendons of the flexor carpi radialis and palmaris longus) and the elbow (medial aspect of the antecubital space, just lateral to the brachial artery), using an

electronic stimulator.

1.4.4. Collect the supramaximal readings of the distal motor latency, the compound motor nerve action potential (CMAP) amplitude, and the conduction velocities displayed in the NCS system.

1.5. Measure the conduction in the ulnar motor nerve (Figure 3).

1.5.1. Place the E1 over the belly of the abductor digiti minimi while the E2 is attached to the distal phalanx of the fifth digit. The ground electrode is between the stimulation and the recording sites.

1.5.2. Stimulate at the wrist (7 cm proximal to the E1 electrode, just lateral or medial to the flexor carpi radialis tendon), below and above the elbow (5 cm distal and proximal to the ulnar groove) (Figure 3).

1.5.3. Collect the supramaximal readings of the distal motor latency, the CMAP amplitude, and the conduction velocities of the ulnar nerve displayed in the NCS system.

2. Measurements Using Ultrasound

2.1. Ensure that the patient is seated on a plinth facing the examiner, with their hands resting in a horizontal supination position and the fingers semi-extended (Figure 4).

2.2. Place some ultrasound gel over the probe of the transducer, the wrist site, and the distal one-third forearm (Figure 4).

2.3. Perform a transverse scan using a 14 - 13 MHz linear array transducer at the inlet of the carpal tunnel. Freeze the real-time imaging and continuously caliper the hyperechoic epineurium of the median nerve at the inlet of the carpal tunnel (Figure 5).

2.4. Scan proximally along the innervated area of the median nerve to the site of the one-third distal forearm. Freeze the real-time imaging and caliper the hyperechoic epineurium of the median nerve at the one-third distal forearm (Figure 6).

3. Screening of Potential Coexisting Axonal Degeneration in Carpal Tunnel Syndrome

3.1. Screen the possible coexisting axonal degeneration primarily based on the NCS criteria listed in Table 1.

NOTE: Those patients who fulfilled the criteria for associated axonal degeneration according to the NCS criteria in Table 1 will be primarily screened for the potential coexistence of axonal degeneration.

3.2. Consider the ultrasound readings as complementary information for screening axonal

degeneration.

NOTE: The patient will be considered associated with the coexistence of axonal degeneration should any of the measured readings of the ultrasound parameters be above the cut-off value(s).

3.3. Take the ultrasound readings into account when the NCS readings failed to fulfill the NCS criteria from **Table 1** (e.g., the NCS signal is absent or a conduction block or temporal dispersion occurs).

NOTE: The patient can also be considered as potentially associated with axonal degeneration should any of the measured readings of the ultrasound parameters be above the cut-off value(s). Further golden standard testing, such as EMG or biopsy, can be applied for confirmation if needed.

REPRESENTATIVE RESULTS:

As was described in **Table 1**, associated axonal degeneration will be primarily screened out should the subject fulfill the criteria of NCS as follows: (1) the sensory conduction velocity of the median nerve is less than 42m/s and/or (2) the distal sensory latency is more than 4.6 ms or the distal motor latency is more than 3.2 ms; (3) the SNAP amplitude at the wrist is less than 10 μ V with the CMAP amplitude drop being no more than 20%. Those with temporal dispersion (a CMAP amplitude drop of >20%) and/or conduction block (a CMAP amplitude drop of >50%) will be excluded. Regarding the criteria of the NCS parameters, which include conduction velocity, distal latency, SNAP amplitude, exclusion of conduction block¹², and temporal dispersion¹³, they were all set based on previously well-established references and our laboratory practical standard.

Then, the measured readings of the ultrasound parameters will also be taken into account. The CSA is the coronal size of the nerve measured by tracing the hyperechoic epineurium, while the P is the circumference of the traced hyperechoic epineurium. R-CSA/R-P is calculated by the CSA/P measured at the carpal inlet divided by that measured in the one-third distal forearm. Δ CSA/ Δ P is the change of CSA/P from the wrist to the one-third distal forearm. The cut-off values and the sensitivity, specificity, and accuracy of the ultrasound parameters were determined by plotting receiver operative characteristics (ROC) curves, which were identified in a previous study⁹. The positive predictive value and negative predictive value are also displayed in **Table 1**. Those patients with any ultrasound parameter value(s) above the correspondent cut-off value(s) will be considered as suffering from the potential coexistence of axonal degeneration. Alternatively, the ultrasound readings can also be considered as indicators of potential axonal degeneration, should the subject not fulfill the NCS criteria in **Table 1**.

A group of 80 subjects who fulfilled the NCS criteria in **Table 1** was enrolled *via* convenience sampling to examine the effectiveness of the protocol. They were assigned to group A (demyelination only, $n_1 = 45$) and group B (associated axonal degeneration, $n_2 = 35$), based on the NCS criteria in **Table 1**. When comparing group A and B, significant differences were found in NCS and ultrasound measurements (**Table 2**). The results indicate this protocol can be effective in screening axonal degeneration associated with CTS.

On the other hand, another group of 46 subjects (group C), who did not fulfill the NCS criteria in **Table 1**, were enrolled with ultrasound measurements generated descriptively. Based on the ultrasound performance, the enrolled subjects were all potentially associated with coexisting axonal degeneration (**Table 2**).

FIGURE AND TABLE LEGENDS:

Figure 1: Measurement of the sensory-evoked potential of the median and ulnar nerve.

Figure 2: Measurement of the motor-evoked potential of the median nerve.

Figure 3: Measurement of the motor-evoked potential of the ulnar nerve.

Figure 4: Measurement by ultrasound.

Figure 5: Measurement of the inlet of the carpal tunnel and its ultrasound imaging.

Figure 6: Measurement of the one-third distal forearm and its ultrasound imaging.

Table 1: Criteria for determining axonal degeneration associated with carpal tunnel syndrome by nerve conduction studies and ultrasound. Remarks: R-CSA or R-P = CSA or P at the wrist/CSA or P at the one-third distal forearm; Δ CSA or Δ P = CSA or P at the wrist minus CSA or P at the one-third distal forearm.

Table 2: Demographics and performance of nerve conduction studies and ultrasound measurements of the enrolled subjects.

DISCUSSION:

It is challenging to set up a universal standard for the measurement of NCS due to the influence of demographic and physical factors such as age, gender, ethnicities, and body weight, *etc.*¹⁴. Regarding SNAP amplitude, note that there is a difference between the orthodromic (the direction of current runs proximally toward the body) and antidromic (the direction of current runs distally away from the body) technique, as the SNAP amplitude measured by the orthodromic method is smaller than the antidromic method¹⁵. In our laboratory, orthodromic stimulation has generally been applied clinically such that we set 10 μ V as the cut-off value of determining axonal damage. A higher SNAP amplitude is required should the antidromic technique be applied.

On the other hand, for the measurement of ultrasounds, we took the inlet of the carpal tunnel and the one-third distal forearm as the bony markers for measurement. These measurement sites were consistent with previous studies, bearing a comparatively higher accuracy for diagnosing the disease^{3,4,8,16-18}, which may also, consequently, increase the accuracy of discrimination. In addition, one of the most innovative aspects of this method is that the cut-off values of the ultrasound parameters can take a complementary role when the electric signal of

NCS is absent or did not fulfill the NCS criteria for differentiation as they displayed overall satisfactory sensitivity and specificity in a previous study⁹. Compared to previous cut-off values identified for severity gradation^{8,19,20}, these cut-off values are believed to be more indicative clinically for treatment prescription as they can reflect pathological progress beyond the conventional severity grade.

Nevertheless, there are also constraints using this method. First, the specificity is inferior to the sensitivity in this protocol, as can be seen from the ultrasound findings among subjects in group C, all of which were considered with potential associated axonal degeneration based on the ultrasound cut-off readings. This can be explained as, at the current stage, we have not yet established a concrete assessment package to confirm axonal degeneration based on various ultrasound measurements. Besides, the nature of ultrasound imaging also cannot directly display axonal degeneration. It still relies on the golden standard test to confirm axonal degeneration. Also, there is yet no universal agreement upon NCS criteria for discriminating axonal degeneration⁹. Further studies are required to examine its reliability by comparison with the golden standard test. Despite these limitations, we still propose this method as an efficient screening approach as it can quickly inform clinicians at an early stage in a noninvasive manner, thus avoiding deterioration.

Bearing overall satisfactory accuracy, sensitivity, and specificity, the combinative use of ultrasound and NCS cannot only compensate for technical pitfalls of NCS (absent signals, *etc.*) by providing anatomical and structural information, but it can also disclose or identify the pathological progress lying underneath, besides diagnosing the disease and grading the severity. This method can be applied easily in routine clinical practice for the initial screening of the potential coexistence of axonal degeneration associated with CTS. A more refined plan of care can be attainable using this method.

ACKNOWLEDGMENTS:

Mr. Xue Deng, Dr. Yong Hu, and Dr. Ip Wing-Yuk were dedicated to the concept of the study design, subject recruitment, and draft and revision of the manuscript. Ms. Lai-Heung Phoebe Chau and Ms. Suk-Yee Chiu were dedicated to subject liaison, data collection, and the manipulation of NCS. Dr. Kwok-Pui Leung was dedicated to the electrophysiological diagnosis, clinical guidance, and the manipulation of the ultrasounds.

DISCLOSURES:

The authors have nothing to disclose.

REFERENCES:

1. Caetano, M. R. Axonal degeneration in association with carpal tunnel syndrome. *Arquivos de Neuro-Psiquiatria*. **61** (1), 48-50 (2003).
2. Werner, R. A., Andary, M. Electrodiagnostic evaluation of carpal tunnel syndrome. *Muscle Nerve*. **44** (4), 597-607 (2011).
3. Duncan, I., Sullivan, P. & Lomas, F. Sonography in the diagnosis of carpal tunnel syndrome. *AJR. American journal of roentgenology*. **173** (3), 681-684 (1999).

4. Miyamoto, H. *et al.* Carpal Tunnel Syndrome- Diagnosis by Means of Median Nerve Elasticity—Improved Diagnostic Accuracy of US with Sonoelastography. *Radiology*. **270** (2), 481-486 (2014).
5. Azami, A. *et al.* The diagnostic value of ultrasound compared with nerve conduction velocity in carpal tunnel syndrom. *International Journal of Rheumatic Diseases*. **17**, 612-620 (2014).
6. Altinok, T. *et al.* Ultrasonographic assessment of mild and moderate idiopathic carpal tunnel syndrome. *Clinical Radiology*. **59**, 916-925 (2004).
7. Zhang, L. *et al.* Does the ratio of the carpal tunnel inlet and outlet cross-sectional areas in the median nerve reflect carpal tunnel syndrome severity? *Neural Regeneration Research*. **10** (7), 1172-1176 (2015).
8. Klauser, A. S. *et al.* Sonographic cross-sectional area measurement in carpal tunnel syndrome patients: can delta and ratio calculations predict severity compared to nerve conduction studies? *European Radiology*. **25** (8), 2419-2427 (2015).
9. Deng, X. *et al.* Exploratory use of ultrasound to determine whether demyelination following carpal tunnel syndrome co-exists with axonal degeneration. *Neural Regeneration Research*. **13** (2), 317-323 (2018).
10. Moon, H. I., Kwon, H. K., Lee, A., Lee, S. K., Pyun, S. B. Sonography of Carpal Tunnel Syndrome According to Pathophysiologic Type: Conduction Block Versus Axonal Degeneration. *Journal of Ultrasound in Medicine*. **36** (5), 993-998 (2017).
11. Razek, A. A. K. A., Shabana, A. A. E., El Saied, T. O., Alrefey, N. Diffusion tensor imaging of mild-moderate carpal tunnel syndrome- correlation with nerve conduction study and clinical tests. *Clinical Rheumatology*. **36** (10), 2319-2324 (2017).
12. Weber, F. Conduction block and abnormal temporal dispersion--diagnostic criteria. *Electroencephalography and Clinical Neurophysiology*. **37** (5), 305-309 (1997).
13. Kiernan, C. M., Mogyoros, I., Burke D. Conduction block in carpal tunnel syndrome. *Brain*. **122** (5), 933-941 (1999).
14. Fong, S. Y., Goh, K. J., Shahrizaila, N., Wong, K. T., Tan, C. T. Effects of demographic and physical factors on nerve conduction study values of healthy subjects in a multi-ethnic Asian population. *Muscle Nerve*. **54** (2), 244-248 (2016).
15. Valls-Sole, J., Leote, J., Pereira, P. Antidromic vs orthodromic sensory median nerve conduction studies. *Clinical Neurophysiology Practice*. **1**, 18-25 (2016).
16. Wong, S. M., Griffith, J. F., Hui, A. C., Tang, A., Wong, K. S. Discriminatory sonographic criteria for the diagnosis of carpal tunnel syndrome. *Arthritis & Rheumatology*. **46** (7), 1914-1921 (2002).
17. Mondelli, M., Filippou, G., Gallo, A., Frediani, B. Diagnostic utility of ultrasonography versus nerve conduction studies in mild carpal tunnel syndrome. *Arthritis & Rheumatology*. **59** (3), 357-366 (2008).
18. Wong, S. M. *et al.* Carpal tunnel syndrome: diagnostic usefulness of sonography. *Radiology*. **232** (1), 93-99 (2004).
19. Baiee, R. H., AL-Mukhtar, N. J., Al-Rubiae, S. J., Hammoodi, Z. H., Abass, F. N. Neurophysiological Findings in Patients with Carpal Tunnel Syndrome by Nerve Conduction Study in Comparing with Ultrasound study. *Journal of Natural Sciences Reserach*. **5** (16), 111-128 (2015).
20. Filius, A. *et al.* Multidimensional ultrasound imaging of the wrist: Changes of shape and displacement of the median nerve and tendons in carpal tunnel syndrome. *Journal of Orthopaedic Research*. **33** (9), 1332-1340 (2015).

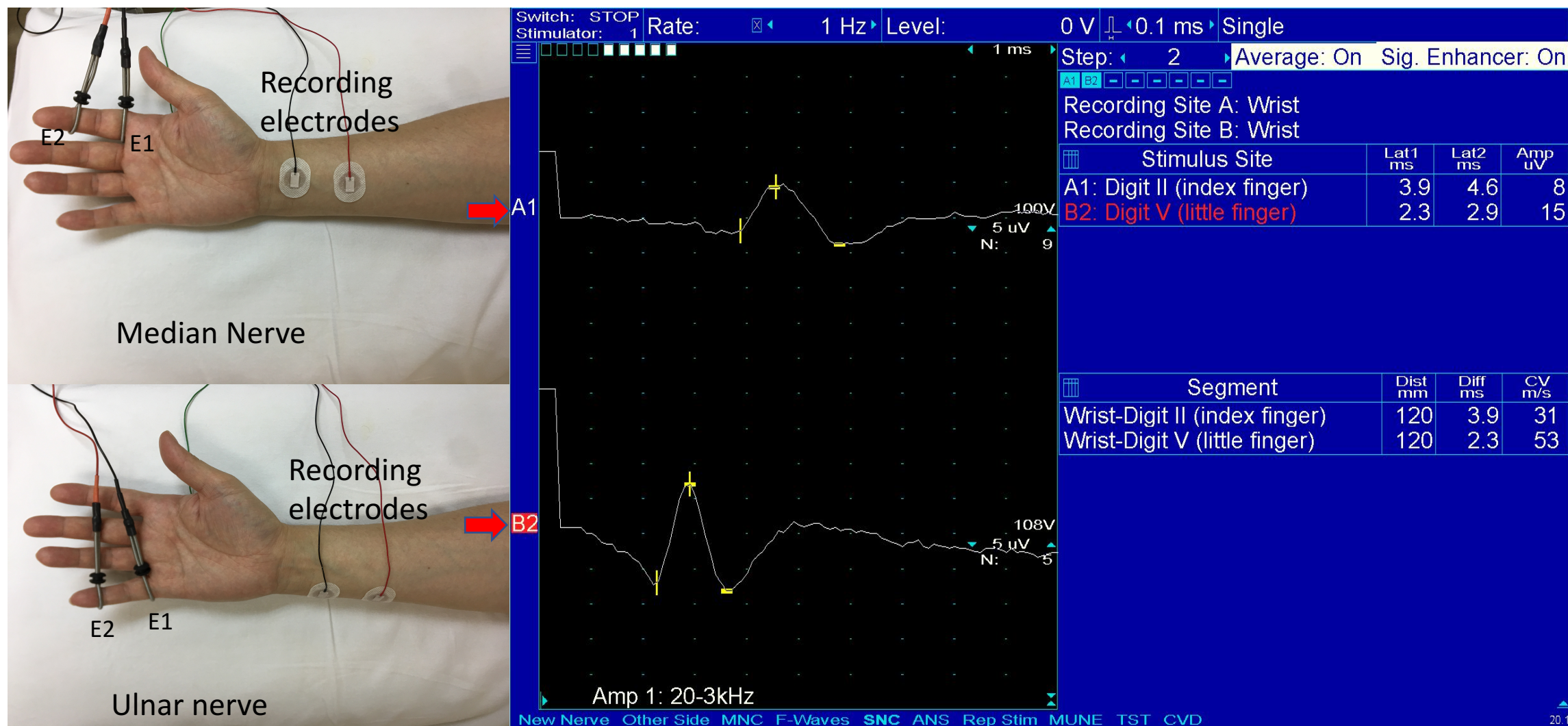


Figure 1. Measurement of the sensory evoked potential of median and ulnar nerve

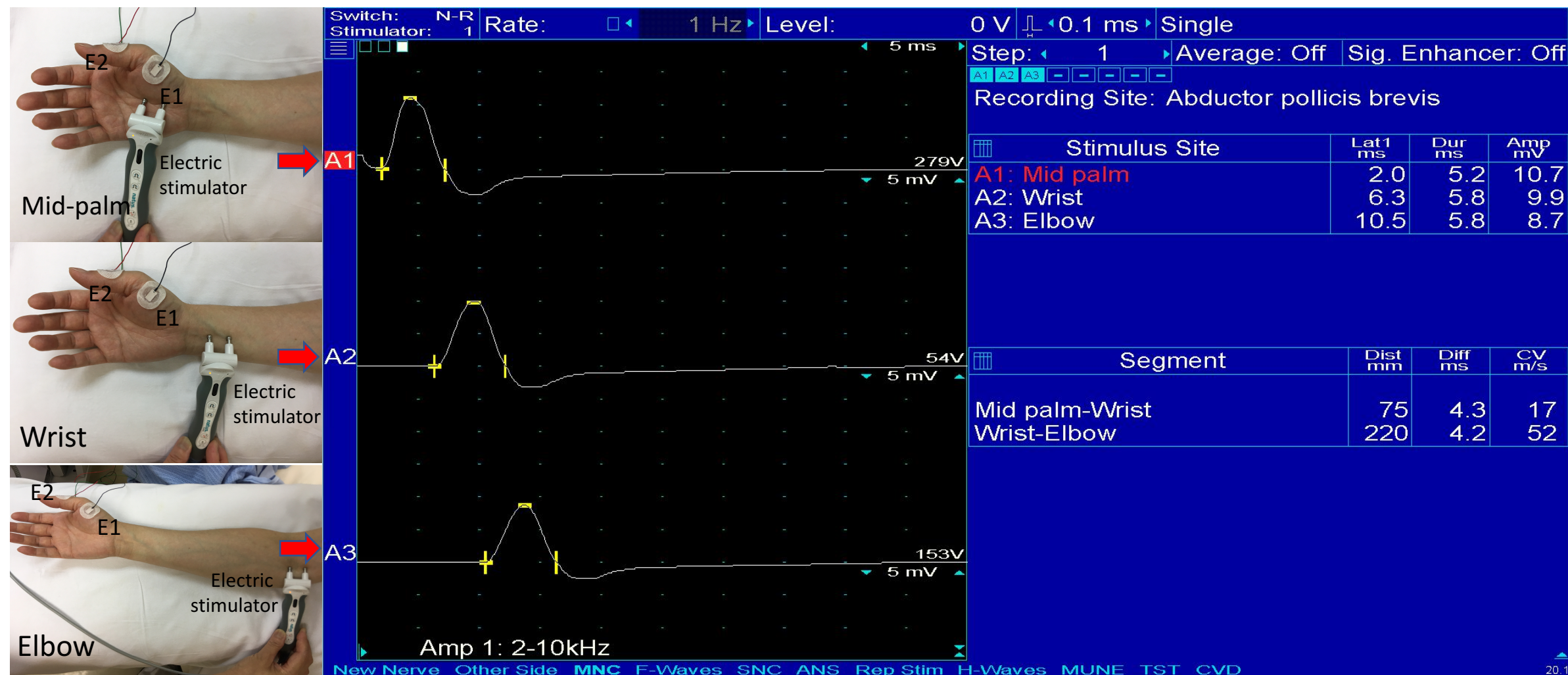

Figure 2. Measurement of the motor evoked potential of median nerve

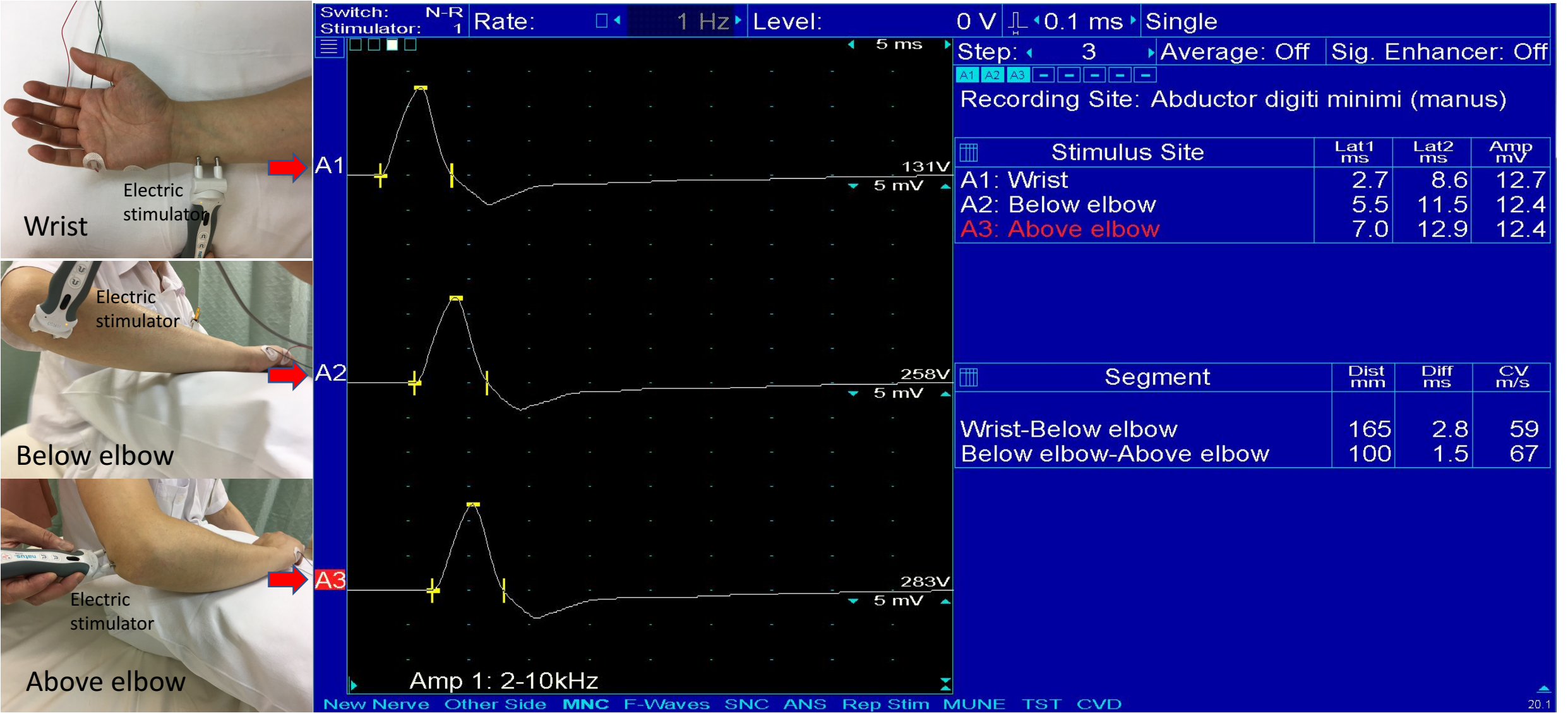

Figure 3. Measurement of the motor evoked potential of ulnar nerve

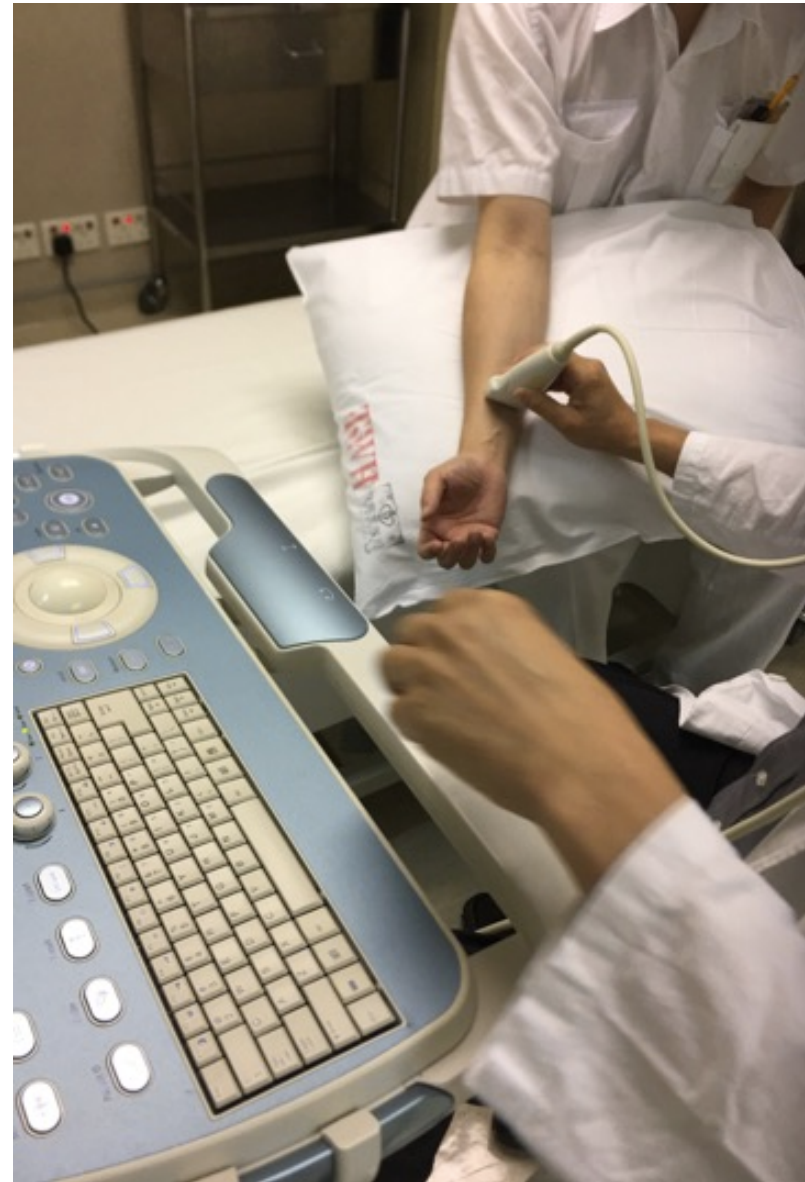

Figure 4. Measurement by ultrasound

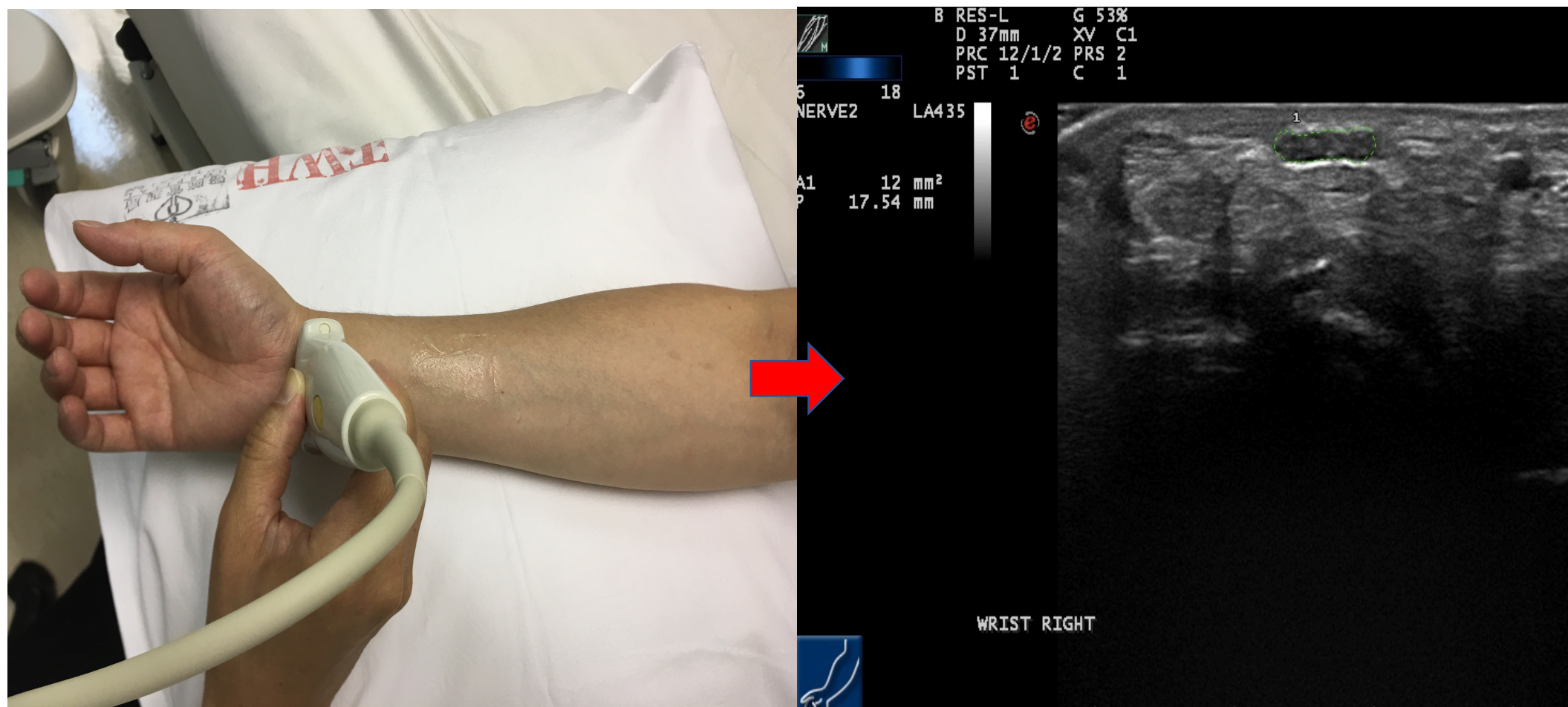


Figure 5. Measurement of the inlet of carpal tunnel and its ultrasound imaging

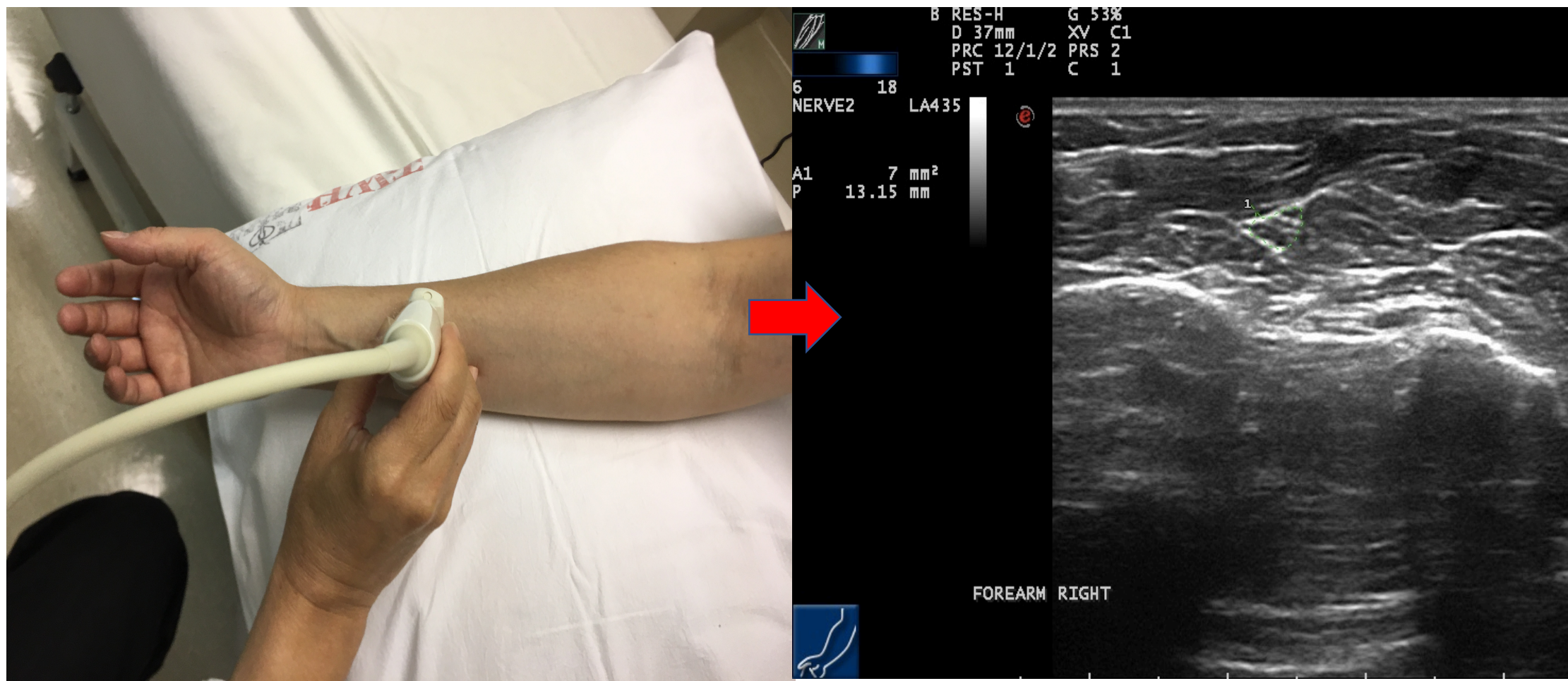


Figure 6. Measurement of the distal one-third forearm and its ultrasound imaging

Table 1. Criteria for determining axonal degeneration associated in carpal tunnel syndrome conduction studies and ultrasound. (Remarks: R-CSA or R-P= CSA or P at wrist/CSA or P at d forearm; Δ CSA or Δ P= CSA or P at wrist – CSA or P at distal one third forearm)

Criteria for determining axonal degeneration according to measurement of nerve condu					
(1) Conduction velocity of the median sensory nerve <42m/s (less than 75% of the lower limit and/or					
(2) Distal sensory latency > 4.6 ms or distal motor latency >3.2 ms (more than 130% of the up normal)					
(3) Sensory nerve action potential (SNAP) amplitude at the wrist <10 μ V with compound moti potential (CMAP) amplitude drop \leq 20%;					
(4) Exclude conditions of CMAP amplitude drop >20%, which may be indicative of temporal d conduction block (CMAP amplitude drop >50%)					
Criteria for determining axonal degeneration according to ultrasound measurer					
	Cut-off values	Accuracy	Sensitivity (%)	Specificity (%)	Positive Predictative Value (%)
(1) CSA(mm ²)	12	0.71	80%	48.90%	75.90%
(2) P(mm)	16.27	0.748	88.60%	51.10%	85.20%
(3) R-CSA	1.85	0.725	85.70%	48.90%	81.50%
(4) R-P	1.48	0.676	80%	40%	72%
(5) Δ CSA(mm ²)	6.98	0.758	77.10%	62.20%	77.80%
(6) Δ P(mm)	5.77	0.717	80%	46.70%	80.60%

by nerve
distal one third

action studies
of normal,
upper limit of
or action
dispersion and/or
nent
Negative Predictive Value (%)
45.10%
41.50%
43.40%
49.10%
38.60%
36.40%

Table 2. Demographics, performance of nerve conduction studies and ultrasound

Group A(n1=45)	
Gender#	
Female	35
Male	10
Age	58.58(8.44)
Handedness	
Right	23
Left	22
Severity grade*	
Mild	20
Mild to moderate	8
Moderate	14
Moderate to severe	1
Severe	2
Median Motor Nerve	
Group A	
Palmar DML	1.99(.27)
Palmar CMAP	8.46(2.51)
Wrist ML	4.74(1.13)
Wrist CMAP	8.32(2.5)
Wrist MCV	27.28(7.46)
Median Sensory nerve	
Group A	
DSL	3.22(.43)
SNAP	12.82(4.41)
SCV	36.39(6.3)
Ultrasound Measurements	
Group A	
CSA(mm2)	12.5(4.0)
P(mm)	16.71(2.86)
R-CSA	2.03(0.67)
R-P	1.63(.39)
Δ CSA(mm2)	6.17(3.76)
Δ P(mm)	6.22(3.28)

* <0.01 ;# <0.05 ;

DML(ms): distal motor latency, CMAP(mV): compound motor action potential, ML(

measurement of the enrolled subjects


Group B(n2=35)
Demographics
31
4
65.4(7.96)*
20
15
9
0
7
6
13
Nerve Conduction Studies
Group B
2.1(.21)
7.68(2.26)
6.25(1.62)*
7(2.0)#
20.4(6.17)*
Group B
3.61(.46)*
6.21(2.23)*
33.74(4.23)
Group B
16.54(6.81)*
19.64(4.08)*
2.79(1.01)*
1.9((0.47)*
10.4(6.13)*
9.08(4.04)*

(ms): Motor latency; MCV(m/s): motor conduction velocity; MCV: motor cc

Group C(n3=46)
45
1
58.98(7.08)
23
23
29
4
7
5
1
Group C
1.92(.23)
8.91(2.4)
4.5(1.5)
8.12(2.72)
33.32(11.15)
Group C
2.82(.68)
13.77(4.93)
46.02(6.26)
Group C
14.18(3.55)
18.31(2.5)
2.69(.74)
1.84(.26)
8.73(2.97)
8.25(1.99)

nduction velocity; DSL(ms): distal sensory latency;

Name of Material/ Equipment	Company	Catalog Number
Nicolet Viking EDX	Nicolet	RY111820G
MyLab Twice	ESAOTE	101620000



Research Center 4070B
Cambridge, MA 02142
Tel: 617.495.9051
www.jove.com

ARTICLE AND VIDEO LICENSE AGREEMENT

Title of Article:	Combat the use of nerve conduction studies and ultrasonography to differentiate axonal degeneration associated with carpal tunnel syndrome
Author(s):	Xue Deng, Lu-Heng Phoebe Chao, Suh-Yee Chin, Kwok-Pui Leung, Yang Hu, Wing-Yan Ip

Item 1 The Author elects to have the Materials be made available (as described at <http://www.jove.com/publish>) via:

☒ Standard Access

☐ Open Access

Item 2 Please select one of the following items:

☒ The Author is **NOT** a United States government employee.

☐ The Author is a United States government employee and the Materials were prepared in the course of his or her duties as a United States government employee.

☐ The Author is a United States government employee but the Materials were NOT prepared in the course of his or her duties as a United States government employee.

ARTICLE AND VIDEO LICENSE AGREEMENT

1. **Defined Terms.** As used in this Article and Video License Agreement, the following terms shall have the following meanings: **"Agreement"** means this Article and Video License Agreement; **"Article"** means the article specified on the last page of this Agreement, including any associated materials such as texts, figures, tables, artwork, abstracts, or summaries contained therein; **"Author"** means the author who is a signatory to this Agreement; **"Collective Work"** means a work, such as a periodical issue, anthology or encyclopedia, in which the Materials in their entirety in unmodified form, along with a number of other contributions, constituting separate and independent works in themselves, are assembled into a collective whole; **"CRC License"** means the Creative Commons Attribution-Non Commercial-No Derivs 3.0 Unported Agreement, the terms and conditions of which can be found at: <http://creativecommons.org/licenses/by-nc-nd/3.0/legalcode>; **"Derivative Work"** means a work based upon the Materials or upon the Materials and other pre-existing works, such as a translation, musical arrangement, dramatization, fictionalization, motion picture version, sound recording, art reproduction, abridgment, condensation, or any other form in which the Materials may be recast, transformed, or adapted; **"Institution"** means the institution, listed on the last page of this Agreement, by which the Author was employed at the time of the creation of the Materials; **"JoVE"** means MyJoVE Corporation, a Massachusetts corporation and the publisher of The Journal of Visualized Experiments; **"Materials"** means the Article and / or the Video; **"Parties"** means the Author and JoVE; **"Video"** means any video(s) made by the Author, alone or in conjunction with any other parties, or by JoVE or its affiliates or agents, individually or in collaboration with the Author or any other parties, incorporating all or any portion

of the Article, and in which the Author may or may not appear.

2. **Background.** The Author, who is the author of the Article, in order to ensure the dissemination and protection of the Article, desires to have the JoVE publish the Article and create and transmit videos based on the Article. In furtherance of such goals, the Parties desire to memorialize in this Agreement the respective rights of each Party in and to the Article and the Video.

3. **Grant of Rights in Article.** In consideration of JoVE agreeing to publish the Article, the Author hereby grants to JoVE, subject to **Sections 4 and 7** below, the exclusive, royalty-free, perpetual (for the full term of copyright in the Article, including any extensions thereto) license (a) to publish, reproduce, distribute, display and store the Article in all forms, formats and media whether now known or hereafter developed (including without limitation in print, digital and electronic form) throughout the world, (b) to translate the Article into other languages, create adaptations, summaries or extracts of the Article or other Derivative Works (including, without limitation, the Video) or Collective Works based on all or any portion of the Article and exercise all of the rights set forth in (a) above in such translations, adaptations, summaries, extracts, Derivative Works or Collective Works and (c) to license others to do any or all of the above. The foregoing rights may be exercised in all media and formats, whether now known or hereafter devised, and include the right to make such modifications as are technically necessary to exercise the rights in other media and formats. If the "Open Access" box has been checked in **Item 1** above, JoVE and the Author hereby grant to the public all such rights in the Article as provided in, but subject to all limitations and requirements set forth in, the CRC License.

612542.6 For questions, please contact us at submissions@jove.com or +1.617.945.9051.

6. **Retention of Rights in Article.** Notwithstanding the exclusive license granted to JoVE in **Section 3** above, the Author shall, with respect to the Article, retain the non-exclusive right to use all or part of the Article for the non-commercial purpose of giving lectures, presentations or teaching classes, and to post a copy of the Article on the institution's website or the Author's personal website, in each case provided that a link to the Article on the JoVE website is provided and notice of JoVE's copyright in the Article is included. All non-copyright intellectual property rights in and to the Article, such as patent rights, shall remain with the Author.

5. **Grant of Rights in Video – Standard Access.** This **Section 5** applies if the "Standard Access" box has been checked in **Item 1** above or if no box has been checked in **Item 1** above. In consideration of JoVE agreeing to produce, display or otherwise assist with the Video, the Author hereby acknowledges and agrees that, Subject to **Section 7** below, JoVE is and shall be the sole and exclusive owner of all rights of any nature, including, without limitation, all copyrights, in and to the Video. To the extent that, by law, the Author is deemed, now or at any time in the future, to have any rights of any nature in or to the Video, the Author hereby disclaims all such rights and transfers all such rights to JoVE.

6. **Grant of Rights in Video – Open Access.** This **Section 6** applies only if the "Open Access" box has been checked in **Item 1** above. In consideration of JoVE agreeing to produce, display or otherwise assist with the Video, the Author hereby grants to JoVE, subject to **Section 7** below, the exclusive, royalty-free, perpetual (for the full term of copyright in the Article, including any extensions thereto) license (a) to publish, reproduce, distribute, display and store the Video in all forms, formats and media whether now known or hereafter developed (including without limitation in print, digital and electronic form) throughout the world, (b) to translate the Video into other languages, create adaptations, summaries or extracts of the Video or other Derivative Works or Collective Works based on all or any portion of the Video and exercise all of the rights set forth in (a) above in such translations, adaptations, summaries, extracts, Derivative Works or Collective Works and (c) to license others to do any or all of the above. The foregoing rights may be exercised in all media and formats, whether now known or hereafter devised, and include the right to make such modifications as are technically necessary to exercise the rights in other media and formats. For any Video to which this **Section 6** is applicable, JoVE and the Author hereby grant to the public all such rights in the Video as provided in, but subject to all limitations and requirements set forth in, the CRC License.

7. **Government Employees.** If the Author is a United States government employee and the Article was prepared in the course of his or her duties as a United States government employee, as indicated in **Item 2** above, and any of the licenses or grants granted by the Author hereunder exceed the scope of the 17 U.S.C. 403, then the rights granted hereunder shall be limited to the maximum

rights permitted under such statute. In such case, all provisions contained herein that are not in conflict with such statute shall remain in full force and effect, and all provisions contained herein that do so conflict shall be deemed to be amended so as to provide to JoVE the maximum rights permissible within such statute.

8. **Protection of the Work.** The Author(s) authorize JoVE to take steps in the Author(s) name and on their behalf if JoVE believes some third party could be infringing or might infringe the copyright of either the Author's Article and/or Video.

9. **Likeness, Privacy, Personality.** The Author hereby grants JoVE the right to use the Author's name, voice, likeness, picture, photograph, image, biography and performance in any way, commercial or otherwise, in connection with the Materials and the sale, promotion and distribution thereof. The Author hereby waives any and all rights he or she may have, relating to his or her appearance in the Video or otherwise relating to the Materials, under all applicable privacy, likeness, personality or similar laws.

10. **Author Warranties.** The Author represents and warrants that the Article is original, that it has not been published, that the copyright interest is owned by the Author (or, if more than one author is listed at the beginning of this Agreement, by such authors collectively) and has not been assigned, licensed, or otherwise transferred to any other party. The Author represents and warrants that the author(s) listed at the top of this Agreement are the only authors of the Materials. If more than one author is listed at the top of this Agreement and if any such author has not entered into a separate Article and Video License Agreement with JoVE relating to the Materials, the Author represents and warrants that the Author has been authorized by each of the other such authors to execute this Agreement on his or her behalf and to bind him or her with respect to the terms of this Agreement as if each of them had been a party hereto as an Author. The Author warrants that the use, reproduction, distribution, public or private performance or display, and/or modification of all or any portion of the Materials does not and will not violate, infringe and/or misappropriate the patent, trademark, intellectual property or other rights of any third party. The Author represents and warrants that it has and will continue to comply with all government, institutional and other regulations, including, without limitation all institutional, laboratory, hospital, ethical, human and animal treatment, privacy, and all other rules, regulations, laws, procedures or guidelines, applicable to the Materials, and that all research involving human and animal subjects has been approved by the Author's relevant institutional review board.

11. **JoVE Discretion.** If the Author requests the assistance of JoVE in producing the Video in the Author's facility, the Author shall ensure that the presence of JoVE employees, agents or independent contractors is in accordance with the relevant regulations of the Author's institution. If more than one author is listed at the beginning of this Agreement, JoVE may, in its sole

ARTICLE AND VIDEO LICENSE AGREEMENT

discretion, shall not take any action with respect to the Article until such time as it has received complete, executed Article and Video License Agreements from each such author. JoVE reserves the right, in its absolute and sole discretion and without giving any reason therefore, to accept or decline any work submitted to JoVE. JoVE and its employees, agents and independent contractors shall have full, unfettered access to the facilities of the Author or of the Author's institution as necessary to make the Video, whether actually published or not. JoVE has sole discretion as to the method of making and publishing the Materials, including, without limitation, to all decisions regarding editing, lighting, filming, timing of publication, if any, length, quality, content and the like.

12. **Indemnification.** The Author agrees to indemnify JoVE and/or its successors and assigns from and against any and all claims, costs, and expenses, including attorney's fees, arising out of any breach of any warranty or other representations contained herein. The Author further agrees to indemnify and hold harmless JoVE from and against any and all claims, costs, and expenses, including attorney's fees, resulting from the breach by the Author of any representation or warranty contained herein or from allegations or instances of violation of intellectual property rights, damage to the Author's or the Author's institution's facilities, fraud, libel, defamation, research, equipment, experiments, property damage, personal injury, violations of institutional, laboratory, hospital, ethical, human and animal treatment, privacy or other rules, regulations, laws, procedures or guidelines, liabilities and other losses or damages related in any way to the submission of work to JoVE, making of videos by JoVE, or publication in JoVE or elsewhere by JoVE. The Author shall be responsible for, and shall hold JoVE harmless from, damages caused by lack of sterilization, lack of cleanliness or by contamination due to

the making of a video by JoVE its employees, agents or independent contractors. All sterilization, cleanliness or decontamination procedures shall be solely the responsibility of the Author and shall be undertaken at the Author's expense. All indemnifications provided herein shall include JoVE's attorney's fees and costs related to said losses or damages. Such indemnification and holding harmless shall include such losses or damages incurred by, or in connection with, acts or omissions of JoVE, its employees, agents or independent contractors.

13. **Fees.** To cover the cost incurred for publication, JoVE must receive payment before production and publication the Materials. Payment is due in 21 days of invoice. Should the Materials not be published due to an editorial or production decision, these funds will be returned to the Author. Withdrawal by the Author of any submitted Materials after final peer review approval will result in a US\$1,200 fee to cover pre-production expenses incurred by JoVE. If payment is not received by the completion of filming, production and publication of the Materials will be suspended until payment is received.

14. **Transfer, Governing Law.** This Agreement may be assigned by JoVE and shall inure to the benefits of any of JoVE's successors and assignees. This Agreement shall be governed and construed by the internal laws of the Commonwealth of Massachusetts without giving effect to any conflict of law provision thereunder. This Agreement may be executed in counterparts, each of which shall be deemed an original, but all of which together shall be deemed to be one and the same agreement. A signed copy of this Agreement delivered by facsimile, e-mail or other means of electronic transmission shall be deemed to have the same legal effect as delivery of an original signed copy of this Agreement.

A signed copy of this document must be sent with all new submissions. Only one Agreement is required per submission.

CORRESPONDING AUTHOR

Name:

Dr. Ip Wing Yuk

Department:

— Dept. of O&T

Institution:

The University of Hong Kong

Title:

Associate Professor

Signature:

[Handwritten Signature]

Date:

Jun 27th, 2018

Please submit a **signed** and **dated** copy of this license by one of the following three methods:

1. Upload an electronic version on the JoVE submission site
2. Fax the document to +1.866.381.2236
3. Mail the document to JoVE / Attn: JoVE Editorial / 1 Alewife Center #200 / Cambridge, MA 02140

Reviewer Comments	Rebuttal
1. The editor has formatted the manuscript as per the journal's style. Please retain the same.	done
2. Please address all the specific comments marked in the manuscript.	Done
3. I have changed the title to make it crisper. Please check.	Checked
4. Please clearly bring out the reason for differentiating axonal degeneration in carpal tunnel syndrome.	Done
5. Please add more details to your protocol steps. Please ensure you answer the “how” question, i.e., how is the step performed? Alternatively, add references to published material specifying how to perform the protocol action.	Done
6. Please describe all abbreviations before first-time use.	Revised
7. Figures: Please upload each figure individually to the editorial manager account.	Revised
8. Figure legend: Please provide a short description of what is being observed and all relevant symbols.	Revised
9. Representative result: Please include some controls to show the clear difference between the carpal tunnel syndrome with and without axonal degradation.	Included
10. Representative result: Please include some study on few patients with statistics to show that this protocol can clearly differentiate CTS with and without axonal degradation.	Included
11. Table 1: Table 1 is missing in this revision. Also, Table 1 has details on criteria used and is not a representative result for the technique mentioned in the paper.	Revised

<p>12. Please revise the table of the essential supplies, reagents, and equipment. The table should include the name, company, and catalog number of all relevant materials in separate columns in an xls/xlsx file.</p>	<p>revised</p>
--	----------------