

Journal of Visualized Experiments

Bovine Mammary Gland Biopsy Techniques

--Manuscript Draft--

Article Type:	Methods Article - Author Produced Video
Manuscript Number:	JoVE58602R2
Full Title:	Bovine Mammary Gland Biopsy Techniques
Keywords:	Cattle; lactation; bovine mammary gland; core biopsy; needle biopsy; tissue collection; udder
Corresponding Author:	Veridiana Lourenco Daley, Ph.D. University of Kentucky Blacksburg, Virginia UNITED STATES
Corresponding Author's Institution:	University of Kentucky
Corresponding Author E-Mail:	veridi7@vt.edu;veridianalsouza@gmail.com
Order of Authors:	Veridiana L. Daley, Ph.D. Charles Dye Sophie H. Bogers R. Michael Akers Francisco C. Rodriguez John P. Cant John Doelman Peter Yoder Karan Kumar Dane Webster Mark D. Hanigan
Additional Information:	
Question	Response
Please indicate whether this article will be Standard Access or Open Access.	Open Access (US\$3000)

TITLE:

Bovine Mammary Gland Biopsy Techniques

AUTHORS AND AFFILIATIONS:

Veridiana L. Daley^{1,4}, Charles Dye², Sophie H. Bogers³, R. Michael Akers⁴, Francisco C. Rodriguez³, John P. Cant⁵, John Doelman⁵, Peter Yoder⁴, Karan Kumar², Dane Webster⁶, Mark D. Hanigan⁴

¹National Animal Nutrition Program, a National Research Support Project (NRSP-9), Department of Animal and Food Sciences, University of Kentucky, Lexington, KY, USA

²School of Performing Arts, Virginia Tech, Blacksburg, VA, USA

³Department of Large Animal Clinical Sciences, The Virginia–Maryland College of Veterinary Medicine, Virginia Tech, Blacksburg, VA, USA

⁴Department of Dairy Science, Virginia Tech, Blacksburg, VA, USA

⁵Department of Animal Biosciences, University of Guelph, Ontario, Canada

⁶School of Visual Arts, Virginia Tech, Blacksburg, VA, USA

Corresponding Author:

Veridiana L. Daley

veridi7@vt.edu

Email Addresses of Co-authors:

Veridiana L. Daley (veridi7@vt.edu)

Charles Dye (cdye@vt.edu)

Sophie H. Bogers (sophie@vt.edu)

R. Michael Akers (rma@vt.edu)

Francisco C. Rodriguez (frod@vt.edu)

John P. Cant (jcant@uoguelph.ca)

John Doelman (john.doelman@trouwnutrition.com)

Peter Yoder (yoder70@vt.edu)

Karan Kumar (kkumar8@vt.edu)

Dane Webster (webster@vt.edu)

Mark D. Hanigan (mhanigan@vt.edu)

KEYWORDS:

Cattle, lactation, bovine mammary gland, core biopsy, needle biopsy, tissue collection, udder

SUMMARY:

This article presents a bovine mammary gland biopsy using core and needle biopsy tools. Harvested tissue can be used for cell culture or to assess mammary physiology and metabolism including gene expression, protein expression, protein modifications, immunohistochemistry, and metabolite concentrations.

ABSTRACT:

Bovine mammary gland biopsies allow researchers to collect tissue samples to study cell biology including gene expression, histological analysis, signaling pathways, and protein translation. This article describes two techniques for biopsy of the bovine mammary gland (MG). Three healthy Holstein dairy cows were the subjects. Before biopsies, cows were milked and subsequently restrained in a cattle chute. An analgesic (flunixin meglumine, 1.1 to 2.2 mg/kg of body weight) was administered via jugular intravenous [IV] injection 15-20 min prior to biopsy. For standing sedation, xylazine hydrochloride (0.01-0.05 mg/kg of body weight) was injected via the coccygeal vessels 5-10 min before the procedure. Once adequately sedated, the biopsy site was aseptically prepared and locally anaesthetized with 6 mL of 2% lidocaine hydrochloride via subcutaneous injection. Using aseptic technique, a 2 to 3 cm vertical incision was made using a number 10 scalpel. Core and needle biopsy tools were used. The core biopsy tool was attached to a cordless drill and inserted into the MG tissue through the incision using a clock-wise drill action. The needle biopsy tool was manually inserted into the incision site. Immediately after the procedure, an assistant applied pressure on the incision site for 20 to 25 min using a sterile towel to achieve hemostasis. Stainless steel surgical staples were used to oppose the skin incision. The staples were removed 10 days post-procedure. The main advantages of core and needle biopsies is that both approaches are minimally invasive procedures that can be safely performed in healthy cows. Milk yield following the biopsy was unaffected. These procedures require a short recovery time and result in fewer risks of complications. Specific limitations may include bleeding after the biopsy and infection on the biopsy site. Applications of these techniques include tissue collection for clinical diagnosis and research purposes, such as primary cell culture.

INTRODUCTION:

A biopsy is a procedure to harvest a core section of tissue from subjects for medical or research purposes. It is a minimally invasive and widely used technique to collect tissue as an alternative to euthanasia¹ to allow analysis of tissue responses to treatment or other factors of interest. Samples of bovine mammary gland (MG) tissues are essential for dairy research to study gene and protein expression, histology, the organization of cellular organelles, signaling pathways, and metabolic processes in response to changes in management or the environment. Additionally, MG tissue is needed to diagnose and research certain infectious diseases, such as bovine mastitis caused by bacterial infections².

The udder of cattle contains four separate glands and each gland contains an independent milk secretory system collectively called parenchyma. The alveoli, ducts, and connective tissue are present in the mammary parenchyma. The alveoli are microscopic spherical hollow structures that are composed of epithelial cells in the internal surface (luminal) and specialized myoepithelial cells on the external surface (basal). The alveoli are responsible for synthesis and secretion of milk. The fibrous connective tissue present in the parenchyma can separate a group of alveoli from other groups of alveoli, and each group is called a lobule³. Several factors can affect the development and function of the MG including animal physiology, nutrition, management, genetics, and the environment⁴. Mastitis also is a critical factor that negatively affects MG function and milk quality⁵. The toxins released by mastitic pathogens can cause damage to the alveoli and induce necrosis resulting in biochemical and histological changes in

the MG tissue⁶. Thus, the histology and metabolic processes of each alveoli or lobule in the MG may be significantly different from others. As such, biopsies that are representative samples of the entire mammary gland are desirable. Small biopsies may only capture a single lobule or individual alveolus, limiting the resulting scientific or diagnostic information. For research purposes, it is necessary to be aware that a mammary biopsy provides a 'snapshot' of tissue characteristics but a biopsy cannot adequately characterize total mammary function in the absence of estimates of total mammary gland mass.

Several biopsy tools have been developed over the last 30 years for human use. Currently, adaptations of those instruments are available for use with animals. For dairy cattle, samples of MG tissue have been obtained using different techniques including surgical excision (blunt dissection)⁷, biopsy needles^{1,8}, and core biopsy instruments^{9,10}. Thus, MG biopsy techniques in lactating dairy cows have transitioned from procedures using recumbent sedation with surgical dissection using electrocautery hemostasis in 1992⁷ to collection of core biopsies under standing sedation⁹⁻¹². Surgical biopsy is an invasive method, which can be expensive and have a higher incidence of complications such as hematoma, wound problems, and tumor spread¹³. Currently, core biopsy and needle biopsy (also known as a tru-cut biopsy) have been widely adopted as alternatives to surgical biopsy. The advantages of core and needle biopsies compared to surgical biopsy include: the procedure is minimally invasive; major complications are rare; general anesthesia is not required; the procedure is relatively rapid; the recovery time is short; there is minimal negative effects on udder health, and only short-term effects on milk yield and composition⁸⁻¹⁰; and the cost is less than surgical biopsy¹³.

One core biopsy procedure described in 1996 used a sterile, stainless steel cannula with a removable retractable blade to remove a representative amount of tissue from the bovine MG without general anesthesia⁹⁻¹². During the procedure, the instrument was attached to a cordless drill to create a low speed, rotational motion which cleanly cut a tissue core as the tool was advanced into the tissue. The benefit was a larger tissue sample (70 mm x 4 mm in diameter, about 0.75 to 1 g)⁹. A recent study¹⁰ showed that the biopsy procedure described by V. C. Farr et al.⁹ can be used to perform repeated MG tissue collections without negative impact on performance and udder health of lactating dairy cows. Most recently, a study¹⁴ was carried out in dairy cows to evaluate repeated biopsies of the MG using a larger trocar (31 cm long, outer diameter of 9.5 mm, inner diameter of 8 mm) with vacuum applied to an internal stainless steel cannula to collect the biopsy. This method used sedation (xylazine) and local anesthesia (2% lidocaine hydrochloride).

The needle biopsy is another technique to collect mammary tissue. Several studies have adopted this technique. One study¹ used sedation (detomidine) and local anesthetic (1% lidocaine) in the procedure. After the biopsy, the cows received a prophylactic antibiotic treatment. The mammary gland was manually massaged before and after the milking. Blood in the milk was observed for up to 84 h after the biopsy. The amount and composition of the milk were affected for a short period of time. Recently, a study used a biopsy needle to perform repeated MG biopsies in dairy cows⁸. Sedation (1% acepromazine, intramuscular) and local anesthesia (2% lidocaine hydrochloride, subcutaneous) were administered to the animals. The

animals did not receive intramammary drugs or antibiotics before or after the procedure, and there were no signs of infection at the biopsy site during the post-surgical period. In this study, repeated bovine MG biopsies using a needle had a minor negative impact on milk production and udder health of dairy cows. In general, the needle biopsy seems to be a less invasive method than the core biopsy instrument. However, as noted previously, it is essential for the biopsy technique to harvest a representative sample of the MG tissue. The limitation of a needle biopsy is that a small amount of bovine MG tissue is obtained (about 20 to 25 mg)^{8,15}.

Almost all of the studies used a combination of α -2 agonist sedation and local anesthetic⁸⁻¹⁰, whether the biopsy was via a needle or a larger core. In the bovine MG, most nerve endings are associated with the skin. Innervation to the parenchymal tissue is largely via stretch receptors with sparse Type A nerve fibers to detect sharp surgical pain. As a result, physiological mechanisms of pain due to surgical manipulation of the MG is via skin and subcutaneous tissues³ and not deep tissues such as parenchymal tissue. Therefore, for biopsy procedures, it is only necessary to locally anesthetize the skin and subcutaneous tissues, as infiltration of local anesthetic into the deeper tissues does not significantly reduce surgical pain. After an appropriate preparation of the biopsy area, animal discomfort is, primarily, associated with restraint.

Collection of larger core samples may increase hematoma formation and increase the risk of infection within the MG parenchyma. Therefore, peri-operative protocols often include administration of parenteral antibiotics⁷, although that is not universal⁸. Achieving hemostasis is also an important factor for reducing cow morbidity. In the aforementioned study using a large core biopsy instrument¹⁴, manual pressure was applied to the biopsy site and a cow bra was used to apply ice to the wounds for at least 2 h following the procedure. Despite the large amount of tissue harvested, only slight reductions in feed intake and milk yield were observed, and the procedure was repeated every three weeks without negative effects on cow health.

Researchers performing MG biopsy in dairy cows need to consider the diagnostic or analytical quality of the resulting biopsy, ease of technique, and cow morbidity. Accurate and pre-planned surgical techniques are imperative to achieve these goals. To date, MG biopsy studies have focused on describing biopsy outcomes, as opposed to describing the biopsy technique itself, and descriptions for lactating dairy cows lack sufficient detail to allow replication. Thus, the objective of this work was to describe both needle biopsy and larger core biopsy techniques in sufficient detail to allow safe and humane replication of MG biopsy of cattle.

PROTOCOL:

All methods described were approved by the Virginia Tech Institutional Animal Care and Use Committee (IACUC).

1. Personnel

1.1. Have at least two assistants with surgical and cow-handling experience.

1.2. Train all assistants at least three times, if possible using cadaveric material, prior to performing procedures associated with this protocol on live animals.

NOTE: Training should be conducted by an instructor that has been previously trained and performed the technique.

1.3. Have a large animal veterinarian on-hand for drug administration and in the event that emergency treatment becomes necessary during the procedure. Emergencies that may occur during this procedure include but are not limited to: hemorrhage, α -2 agonist overdose and pulmonary edema, regurgitation and aspiration of food material, pain, and patient resistance requiring further sedation.

2. Preparation of the surgical instruments, supplies, and facility

2.1. Inventory and purchase all equipment and supplies (see **Table of Materials**).

2.2. Clean and autoclave surgical drapes, biopsy instruments, scalpel holders, surgical towels, and forceps.

2.3. Have a properly sized squeeze chute and head gate to restrain the cows.

2.4. Establish a work space with a table near the squeeze chute.

2.5. Ensure that the work area is clean and has limited cow through-traffic.

2.6. Organize equipment and supplies in the work space for easy access.

2.7. Have proper lighting inside of the work space.

3. Preparation of the animals

3.1. One day before the scheduled biopsy, wash and scrub the animal, particularly the udder to remove manure and soiled material.

3.2. Follow procedures for safe and humane restraint of cattle.

3.3. In advance of the biopsy and again at the time of the biopsy, assess the health, physical condition and behavior of the animal.

NOTE: A minimum examination includes temperature, pulse, and respiratory rates as well as examination for dermatitis over the proposed surgical site or other areas of bacterial infection. Collect milk samples from each quarter and check for mastitis.

220 3.4. Use only healthy cows.

222 3.5. Completely milk the cow.

224 3.6. Move the animal into the squeeze chute, ideally within 2 h of milking to minimize milk
225 presence in the glands.

227 3.7. Restrain the animal with a head gate.

229 4. Analgesia and sedation

231 4.1. Place a rope halter on the head of the cow to prevent backward and forward movement.

233 4.2. Pull the animal's head to one side, and tie the rope to the squeeze chute using a quick release
234 knot to hold the head in place.

236 4.3. Clean the area of injection with a 70% isopropyl alcohol swab and administer flunixin
237 meglumine (1.1 to 2.2 mg/kg of body weight) intravenously via the jugular vein 15-20 min prior
238 to biopsy.

240 NOTE: In some protocols, nonsteroidal anti-inflammatory drugs are administered after the biopsy
241 if anti-inflammatory drugs will not affect research results.

243 4.3.1. Locate the jugular vein.

245 4.3.2. Raise the jugular vein by application of pressure at the base of the jugular groove.

247 4.3.3. Check to make sure that there are no bubbles in the syringe.

249 4.3.4. Insert the needle into the raised jugular vein, and draw 0.5 mL of blood into the syringe
250 twice and mix with the contents. If no blood shows in the syringe, relocate the needle. If the
251 needle is resident in the vein, inject the contents.

253 4.3.5. Gently remove the needle.

255 4.3.6. Apply gauze with gentle pressure to the injection site to prevent bleeding.

257 4.4. Administer xylazine hydrochloride intravenously (0.01 to 0.05 mg/kg of body weight) in the
258 coccygeal vessel approximately 5-10 min prior to biopsy to allow sufficient time for establishment
259 of sedation.

261 **Caution: Check the animal for signs of pulmonary edema. Clinical signs of pulmonary edema**
262 **include respiratory distress, severe dyspnea, breathing difficulties, cough, frothy sputum, and**

blue tongue. If signs of pulmonary edema are observed, it is recommended to use tolazine (2 to 4 mg/kg of body weight) to reverse the xylazine effects.

4.4.1. Raise the tail and clean the area of injection with a 70% isopropyl alcohol swab.

4.4.2. Check to make sure that there are no bubbles in the syringe.

4.4.3. Insert the needle into the tail vessel, draw 0.2 mL of blood into the syringe and mix with the contents to ensure the needle is resident in the vessel. If the needle is resident in the vessel, inject the syringe contents.

4.4.4. Gently remove the needle.

4.4.5. Apply gauze with gentle pressure to the injection site.

5. Preparation of the biopsy site

5.1. Have an assistant tie up the tail for the procedure.

5.2. Select the biopsy site on the udder (typically in an upper area to minimize collection of connective tissue and to avoid penetration into the gland cistern, **Figure 1**), and remove any soiled material or manure from the selected biopsy site.

[Place Figure 1 here]

5.3. Observe and palpate the skin with special attention to identify any large subcutaneous blood vessels in order to avoid these vessels during the biopsy.

5.4. Clip the hair from a 15 cm x 15 cm area around the biopsy site.

5.5. Prepare the biopsy area with povidone-iodine (0.75% available iodine) or chlorhexidine gluconate scrub. Alternate with 70% isopropyl alcohol at least three times to remove all visible and invisible debris. Apply the aseptic scrub solution and isopropyl alcohol in a circular motion using inside-out approach. Ensure that the antiseptic scrub solution remains in contact with the skin for at least 5 min.

5.6. Use a butterfly infusion set with an 18 G needle to deposit 6 mL of 2% lidocaine hydrochloride subcutaneously at the incision site to create a line-block. Do not penetrate into the deeper tissues.

NOTE: Dosage of lidocaine varies between 3 and 8 mL.

5.7. Allow the local anesthetic to diffuse for 3 to 5 min. Perform another repetition of scrub solution and alcohol prior to incision. While waiting, prepare the biopsy instruments.

6. Biopsy procedure

6.1. Use aseptic techniques when handling the biopsy tools and for the incision.

6.2. Wash hands to remove all visible contamination and apply sterile surgical gloves.

6.3. Arrange the surgical instruments in a sterile area in order of use. Have a number 10 scalpel, sterile gauze, an assembled biopsy instrument, and a sterile towel for hemostasis.

NOTE: Follow Procedure 1 to perform a Core biopsy or Procedure 2 to perform a Needle biopsy.

6.4. Core Biopsy Instrument (Farr et al.⁹)

6.4.1. Assemble the core biopsy instrument using sterile gloves (**Figure 2**).

[Place Figure 2 here]

6.4.1.1. Place the 7 sterile pieces on a sterile drape (**Figure 2A**).

6.4.1.2. Insert the blade (piece 1) into the docking system on piece 2 (**Figure 2B**).

CAUTION: Do not place fingers directly in the blade line.

6.4.1.3. Insert piece 3 on top of piece 2 (**Figure 2C**) ensuring that the docking station will align.

NOTE: Observe a docking system in the interior wall of piece 4 (**Figure 2D**).

6.4.1.4. Engage the final edge of the blade (piece 1) into the docking system of piece 4 (**Figure 2D**).

6.4.1.5. Push forward piece 4 and observe if piece 4 is next to piece 3 (**Figure 2E**).

6.4.1.6. Insert piece 5 on the device (blade + piece 2) (**Figure 2F**).

6.4.1.7. Ensure that the docking station is aligned (**Figure 2G**).

6.4.1.8. Insert piece 6 into the top of piece 2 (opposite side of the blade) (**Figure 2H**).

6.4.1.9. Ensure that the docking station is aligned (**Figure 2H**).

6.4.1.10. Insert the locking screw (piece 7) into the docking station (**Figure 2I**).

6.4.1.11. Push forward piece 3 (black) to cover the locking screw.

CAUTION: Do not place fingers on the blade exit.

6.4.1.12. Activate the tool pushing forward piece 4 and observe the blade outside of the tool.

6.4.1.13. Pull piece 4 back to retract the blade into the tool (ready to use).

NOTE: The blade should be activated only when the tool has penetrated the desired distance inside the tissue to be biopsied.

6.4.2. Ensure that the cow is sufficiently sedated and the biopsy site is sufficiently anesthetized. Pinch the skin to ensure no reaction.

6.4.3. Make a 2 to 3 cm vertical incision through the skin and subcutaneous tissues from proximal to distal using a number 10 scalpel.

6.4.4. Attach the biopsy instrument to a cordless drill using sterile technique.

6.4.5. Place the drill against the biopsy tool and check if the tool is firmly attached to the drill.

6.4.6. Ensure adequate restraint by having an individual elevate the tail during all procedure.

6.4.7. Turn on the drill using clockwise rotation and a low speed.

NOTE: The drill is not sterile, and the operator does not remain sterile when using the drill.

6.4.8. Advance the entire biopsy tool (around 7.5 cm) into the udder through the incision while the drill is rotating the tool.

6.4.9. Turn off the drill and manually extend piece 4 of the tool.

6.4.10. Turn on the drill using clockwise rotation and low speed.

6.4.11. Remove the instrument containing the tissue core from the udder.

6.4.12. Apply strong pressure immediately to the wound using a sterile towel for at least 20 min.

NOTE: Have an assistant perform this using their fist to ensure adequate pressure is applied.

6.4.13. Remove the tissue from biopsy tool using tweezers.

6.4.14. Keep the sample in 1x phosphate buffered saline and evaluate the amount of tissue.

6.4.15. Take the cow's vital signs every 10 min after the biopsy for at least 30 min.

6.4.16. Check for bleeding after 20 min of pressure on the biopsy site. If there are drips of blood continue to apply pressure for an additional 5-10 min.

6.4.17. Close the incisions using stainless steel staples at 5 mm intervals after all bleeding has stopped. Use between 5 and 8 staples.

6.4.18. Apply an aerosol bandage to the biopsy area.

6.4.19. Observe the animal for 50 min after the procedure.

6.5. Needle Biopsy Instrument

6.5.1. Follow the manufacturer's instructions for the device.

6.5.2. Remove the biopsy needle from the package using sterile techniques.

6.5.3. Discard the needle if any damage is observed.

6.5.4. Attach the needle to the device.

6.5.5. Close the cover and cock the device.

6.5.6. Ensure that the cow is sufficiently sedated and the biopsy site is sufficiently anesthetized. Pinch the skin to ensure no reaction.

6.5.7. Make a 1 to 2 cm vertical incision through the skin and subcutaneous tissues from proximal to distal using a number 10 scalpel.

NOTE: The incision for the biopsy needle instrument can be smaller (1-2 cm) than that for the core biopsy instrument.

6.5.8. Insert the biopsy needle into the incision site (around 10 to 13 cm from skin).

6.5.9. Activate the biopsy needle device to collect the tissue.

6.5.10. Remove the needle from the udder.

6.5.11. Apply immediate, strong pressure to the wound using a sterile towel for at least 20 min.

6.5.12. Remove the tissue from the biopsy needle using tweezers.

6.5.13. Keep the sample in 1x phosphate buffered saline and evaluate the amount of tissue.

6.5.14. Take vital signs every 10 min after the biopsy for at least 30 min.

6.5.15. Check for bleeding after 20 min of pressure on the biopsy site.

6.5.16. Close the incisions using stainless steel staples after all bleeding has stopped.

6.5.17. Apply an aerosol bandage to the biopsy area.

6.5.18. Observe the animal for 50 min after the procedure.

7. Post-biopsy animal care

7.1. Document all drugs administered to animals.

NOTE: Milk was discarded during a period of 36 h after the procedure; meat withdrawal was 4 d. Withdrawal periods for milk and meat may vary depending on the country or jurisdiction and the drugs used. Please check local rules and regulations.

7.2. Check for the presence of blood in the milk for 7 to 10 d after the biopsy.

7.3. Hand strip blood clots from the biopsied quarter at subsequent milkings and ensure that complete milk removal occurs.

NOTE: Presence of blood clots from the biopsied quarter for 1-3 milkings following the procedure is expected. Blood in the milk may be observed for 1 to 6 d after the biopsy.

7.4. Observe milk yield, and if possible, the individual daily feed intake until surgical staples have been removed.

7.5. Monitor the animal twice a day for body temperature, respiration and heart rates, and demeanor until surgical staples have been removed.

7.6. Check the biopsy site twice daily for swelling, tenderness, and any signs of drainage until the surgical staples have been removed. If these are observed, consult a veterinarian.

NOTE: Keep the biopsy site clean and reapply the aerosol bandage every one to three days as needed.

7.7. Remove the staples from the incision site 10 to 14 d after the biopsy, depending on the healing rate.

7.8. Consult a veterinarian if any signs of local or systemic infection are observed.

REPRESENTATIVE RESULTS:

In the present protocol, the core biopsy technique produced tissue sample of 200 to 600 mg while the needle biopsy produced samples of 10 to 30 mg per biopsy. The animals were observed twice a day for 10 d after the procedure. No complications occurred during the procedure or in the post-operative period, with vital parameters of the cows remaining within normal limits (average respiratory rate = 31.4 ± 7.04 (SD) breaths per min, average heart rate = 75.9 ± 8.9 beats per min, and average rectal temperature = 38.2 ± 0.68 °C, **Figure 3**).

Following manual pressure on the biopsy area to achieve hemostasis (about 25 min), the open wound showed minimal bleeding (**Figure 4**). The cows were fed the same diet ad libitum, and the animals were kept in the same housing facility during the post-operative period. The animals did not show signs of infection at the biopsy site; there was no pain, bleeding, swelling, drainage, or elevated temperature (**Figure 5**). The wound healed within 8 to 10 d of the biopsy (**Figure 5C**).

One animal developed minor skin irritation due to wound rubbing on day 8 after the procedure. This cow was treated by cleaning the biopsy site using povidone-iodine solution and 70% isopropyl alcohol. The stainless steel staples were removed to allow drainage and povidone iodine ointment (1%) was applied twice a day on the biopsy site for 2 to 3 d. The skin irritation disappeared 2 d after applying povidone-iodine ointment and the wound healed with no further complications.

Blood clots were removed by hand stripping of milk from the biopsied quarter prior to machine milking. In the present protocol, the presence of blood clots in the milk was observed for up to three milkings (about 36 h) after the biopsy. Blood contamination of milk was observed for up to 48 h after the biopsy. There were no visual differences observed between core and needle biopsies relative to the amount of blood in the milk. The animals did not show a significant decrease in milk yield after the procedure (**Figure 6**). Average milk composition was 4.37% fat, 3.34% protein, and 4.64% lactose. The average milk somatic cell count (SCC) was less than 200,000 cells per mL.

The MG tissue obtained can be used for different research purposes such as primary cell cultures (**Figure 7**).

FIGURE AND TABLE LEGENDS:

Figure 1. Image of the bovine udder illustrating the biopsy site.

Figure 2. Schematic representation of assembly and setup of the core biopsy tool described by V. C. Farr, et al. ⁹ Scale bar is 1 cm.

Figure 3. Evaluation of animal health indicators after the bovine mammary gland biopsy.

Figure 4. Biopsy site appearance after manual pressure was applied to the biopsy area to achieve hemostasis.

Figure 5. Biopsy site photographs. (A) Biopsy site 3 d after the procedure. (B) Biopsy site 6 d after the procedure. (C) Biopsy site 10 d after the procedure illustrating that the wound was adequately healed.

Figure 6. Daily milk production before and after the bovine mammary gland biopsy (n = 3 cows). A linear model estimated that 10 days before the biopsy the animals produced 23.35 kg of milk per day. The milk yield did not change significantly ($P > 0.05$) from 10 days before to 10 days after the biopsy although a slight increase in milk yield was observed (increase of 0.0005 kg/d of milk for each day from 10 days before the biopsy). Three animals were used in this protocol; one animal was biopsied twice (Animal 1: core biopsy on the left side of the udder and needle biopsy on the right side of the udder) and two animals were biopsied once (Animal 2 and 3: only on the right side of the udder using the core or needle procedure).

Figure 7. Representative images of primary bovine mammary epithelial cells culture. Scale bar is 100 μm .

DISCUSSION:

Core and needle biopsy methods were described in this protocol^{9,16}. A detailed evaluation of the animal health and incidence of mastitis¹⁴ before the biopsy is required for both procedures. For research purposes, performing the technique in animals with obvious signs of inflammation or infectious diseases should be avoided. This will reduce the risk of complications during and after a biopsy. All biopsy instruments and devices should be clean, disinfected, and sterilized to avoid contamination of the biopsy site. Before the procedure, it is necessary to minimize surgical site infections (SSI). In general, SSI is associated with animal morbidity, lost performance, and higher production costs in dairy cows. Studies previously reported methods to prevent SSI due to biopsy including clipping the hair around the incision site, washing the biopsy area to remove contamination^{9,14}, and using antiseptic agents (70% alcohol, iodine surgical scrub⁹, 2% chlorhexidine acetate solution¹⁴, 10% povidone-iodine⁸) for skin preparation. In some studies, administration of antibiotics was adopted during⁷ or immediately after the biopsy⁹; however, antibiotic prophylaxis was not used in the present work, and no infections of the biopsy site were observed. To prevent contamination of the biopsy wound, the tail should be secured to prevent contact with the biopsy site until the aerosol bandage has been applied. In this protocol, staples are removed about 10 to 14 d after the biopsy.

Prior to a core biopsy, it is important to properly set up the tool and attach it to the drill; choose a slow rotation speed, select the forward rotation, and do not use the reverse mode of the drill. During the procedure, it is important to use digital pressure on both sides of the incision to keep the skin edges apart and have a long enough incision to allow tool entry without contacting the skin or connective tissue. If this procedure is not done, a drag on the incision edges during rotation of the core biopsy instrument may occur and cause additional skin tissue trauma which will increase the risk of infection and may delay wound healing. The present biopsy procedures described in this protocol were performed by a board-certified large animal surgeon. The procedures were performed successfully (**Figure 5**). Both techniques are relatively easy and fast to perform as compared to the surgical excision procedure.

Bleeding from the biopsy site are common after MG biopsy in dairy cows^{8-10,14}. In the present protocol, bleeding observed was minimal (**Figure 4**), which may be due to application of adequate (strong) pressure on the wound immediately after the procedure. Strong pressure for at least 20 min is required, and it may be required for more than 30 min in some cases. If moderate to severe bleeding is observed after application of pressure to the biopsy site, it is recommended to continue pressure, and immediately contact a veterinarian.

As hemostasis is an important factor for reducing cow morbidity, one study packed hemostatic pads into the biopsy site to control bleeding⁹. However, use of hemostatic pads in such a manner has a high potential risk for microbiological contamination in the dairy farm environment. Another study¹⁴ applied manual pressure to the biopsy site between repeated biopsies and after biopsy and skin closure, and applied ice to the site for at least 2 h following the biopsy. In the present protocol, strong pressure applied to the biopsy site for 20 to 25 min was adequate to control bleeding.

A successful biopsy technique should result in minimum blood in the milk which persists for a short period of time after the procedure. To avoid an interruption of milk secretion during milk letdown and mastitis infections, intramammary blood clots should be removed by hand stripping from the biopsied quarter^{10,14}. In the present protocol, blood was observed in the milk up to 48 h after the biopsy. However, in a study that used a larger number of animals, blood in the milk was observed in the majority of cows for less than 6 days. Few animals showed blood in the milk after 6 days⁸. For this reason, daily observation of milk appearance is necessary for 6 d after the procedure. Animals did not exhibit any signs of mastitis infection when a large tissue sample was obtained¹⁴. However, previous research which performed repeated biopsies on the same animal using a needle found that mastitis infection incidence was approximately 12% following the procedure⁸. In the present protocol, neither animal had visual signs of clinical mastitis infection after the procedure. There is also a slight chance that the incision site may become infected after the biopsy.

Tolazoline hydrochloride, a drug that reverses the effects of sedation, should be available in the event of an overdose from xylazine. An excessive dose of xylazine may cause pulmonary edema. Clinical signs of pulmonary edema include respiratory distress, severe dyspnea, breathing difficulties, cough, and frothy sputum. If signs of pulmonary edema are observed, it is recommended to use tolazine (2 to 4 mg/kg of body weight) to reverse the xylazine effects.

The present protocol describes the technique to perform both a needle biopsy and core biopsy. In general, the advantage of a core biopsy as compared to needle biopsy is the larger tissue sample (0.75 to 1 g)⁹ with minimum negative effect on udder health. The needle biopsy is a less invasive method than the core biopsy instrument. However, multiple biopsy attempts to obtain a larger amount of tissue using a needle biopsy procedure may increase the risk of major bleeding after the procedure, as well as blood clots in the milk. Both techniques caused minimal cow morbidity and were easily achieved with minimal training of surgical personnel. A short-term change in daily milk yield (8 to 10 % decrease) and its composition⁹ and feed intake

reduction¹⁴ is expected after the core and needle biopsies, respectively. Limitations of the needle biopsy procedure are the small volume of tissue removed with the needle. The instrument needs to be activated only when the needle is within the tissue to be biopsied and multiple attempts often are necessary to obtain adequate amounts of tissue, which increases the risk of blood in the milk and mastitis after the procedure. Limitations of the core biopsy include a higher risk of bleeding after the procedure if a large amount of tissue (>200 mg) is obtained. In addition, the biopsy tool is more difficult to assemble requiring adequate training before use.

ACKNOWLEDGMENTS:

This research was supported by the National Animal Nutrition Program and Virginia Tech. The technical assistance of Ms. Tara Pilonero, Dr. Julie Settlege, and Dr. Izabelle Teixeira are gratefully acknowledged.

DISCLOSURES:

The authors have nothing to disclose.

REFERENCES:

- 1 Khatun, M., Sorensen, P., Ingvarsen, K. L., Bjerring, M., Rontved, C. M. Effects of combined liver and udder biopsying on the acute phase response of dairy cows with experimentally induced E. coli mastitis. *Animal*. **7** (10), 1721-1730, (2013).
- 2 Buitenhuis, B., Rontved, C. M., Edwards, S. M., Ingvarsen, K. L., Sorensen, P. In depth analysis of genes and pathways of the mammary gland involved in the pathogenesis of bovine Escherichia coli-mastitis. *BMC Genomics*. **12** 130, (2011).
- 3 Nickerson, S. C., Akers, R. M. Mammary Gland | Anatomy. In: *Fuquay JW, Fox PF and McSweeney PLH (eds.), Encyclopedia of Dairy Sciences, Second Edition. San Diego: Academic Press.* **3** 328–337, (2011).
- 4 Akers, R. M. A 100-Year Review: Mammary development and lactation. *Journal of Dairy Science*. **100** (12), 10332-10352, (2017).
- 5 Ruegg, P. L. A 100-Year Review: Mastitis detection, management, and prevention1. *Journal of Dairy Science*. **100** (12), 10381-10397, (2017).
- 6 Zhao, X., Lacasse, P. Mammary tissue damage during bovine mastitis: Causes and control. *Journal of Animal Science*. **86** (13), 57-65, (2008).
- 7 Knight, C. H., Hillerton, J. E., Teverson, R. M., Winter, A. Biopsy of the bovine mammary gland. *British Veterinary Journal*. **148** (2), 129-132, (1992).
- 8 Lima, J. A. et al. Effects of bovine mammary gland biopsy and increased milking frequency on post-procedure udder health, histology, and milk yield. *Animal*. **10** (5), 838-846, (2016).
- 9 Farr, V. C. et al. An improved method for the routine biopsy of bovine mammary tissue. *Journal of Dairy Science*. **79** (4), 543-549, (1996).
- 10 Weng, X. et al. Short communication: Repeated mammary tissue collections during lactation do not alter subsequent milk yield or composition. *Journal of Dairy Science*. **100** (10), 8422-8425, (2017).
- 11 Peterson, D. G., Matitashvili, E. A., Bauman, D. E. Diet-induced milk fat depression in dairy cows results in increased trans-10, cis-12 CLA in milk fat and coordinate suppression of

659 mRNA abundance for mammary enzymes involved in milk fat synthesis. *Journal of*
660 *Nutrition*. **133** (10), 3098-3102, (2003).

661 12 Baumgard, L. H., Matitashvili, E., Corl, B. A., Dwyer, D. A., Bauman, D. E. trans-10, cis-12
662 conjugated linoleic acid decreases lipogenic rates and expression of genes involved in milk
663 lipid synthesis in dairy cows. *Journal of Dairy Science*. **85** (9), 2155-2163, (2002).

664 13 Kasraeian, S., Allison, D. C., Ahlmann, E. R., Fedenko, A. N., Menendez, L. R. A comparison
665 of fine-needle aspiration, core biopsy, and surgical biopsy in the diagnosis of extremity
666 soft tissue masses. *Clinical Orthopaedics and Related Research*. **468** (11), 2992-3002,
667 (2010).


668 14 de Lima, L. S. et al. A new technique for repeated biopsies of the mammary gland in dairy
669 cows allotted to Latin-square design studies. *Canadian Journal of Veterinary Research-*
670 *Revue Canadienne De Recherche Veterinaire*. **80** (3), 225-229, (2016).

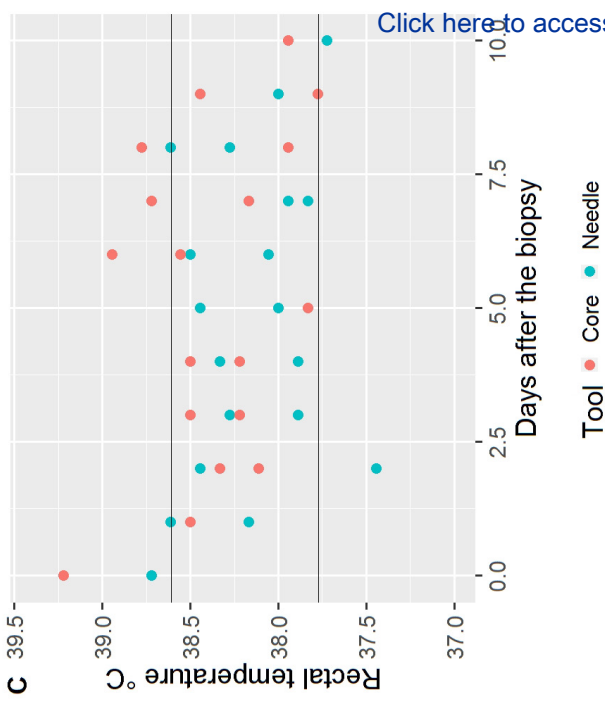
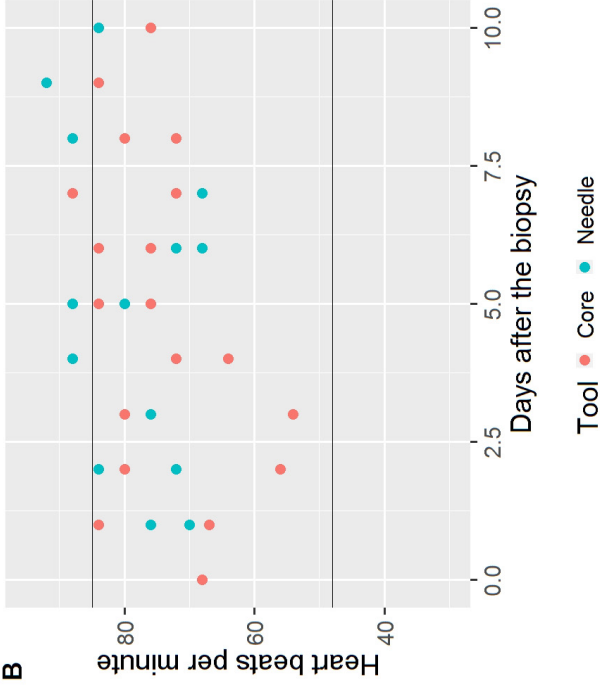
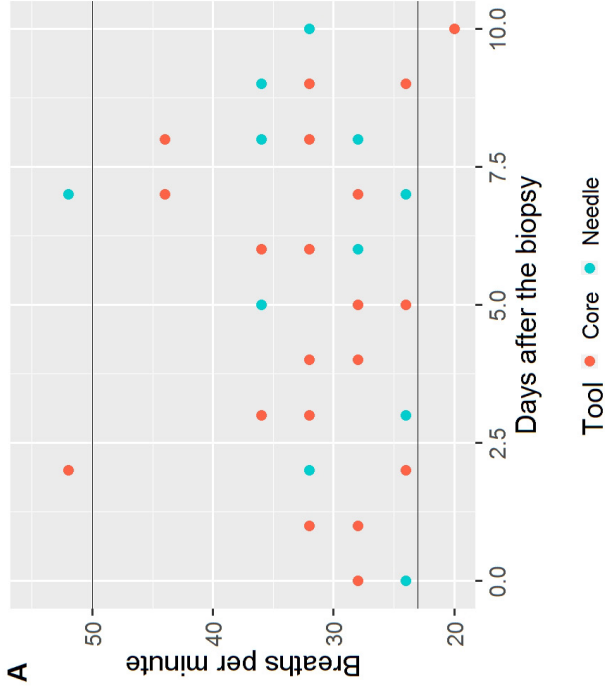
671 15 Ollier, S. et al. Whole intact rapeseeds or sunflower oil in high-forage or high-concentrate
672 diets affects milk yield, milk composition, and mammary gene expression profile in goats.
673 *Journal of Dairy Science*. **92** (11), 5544-5560, (2009).

674 16 Soberon, F. et al. Effects of increased milking frequency on metabolism and mammary
675 cell proliferation in Holstein dairy cows. *Journal of Dairy Science*. **93** (2), 565-573, (2010).
676

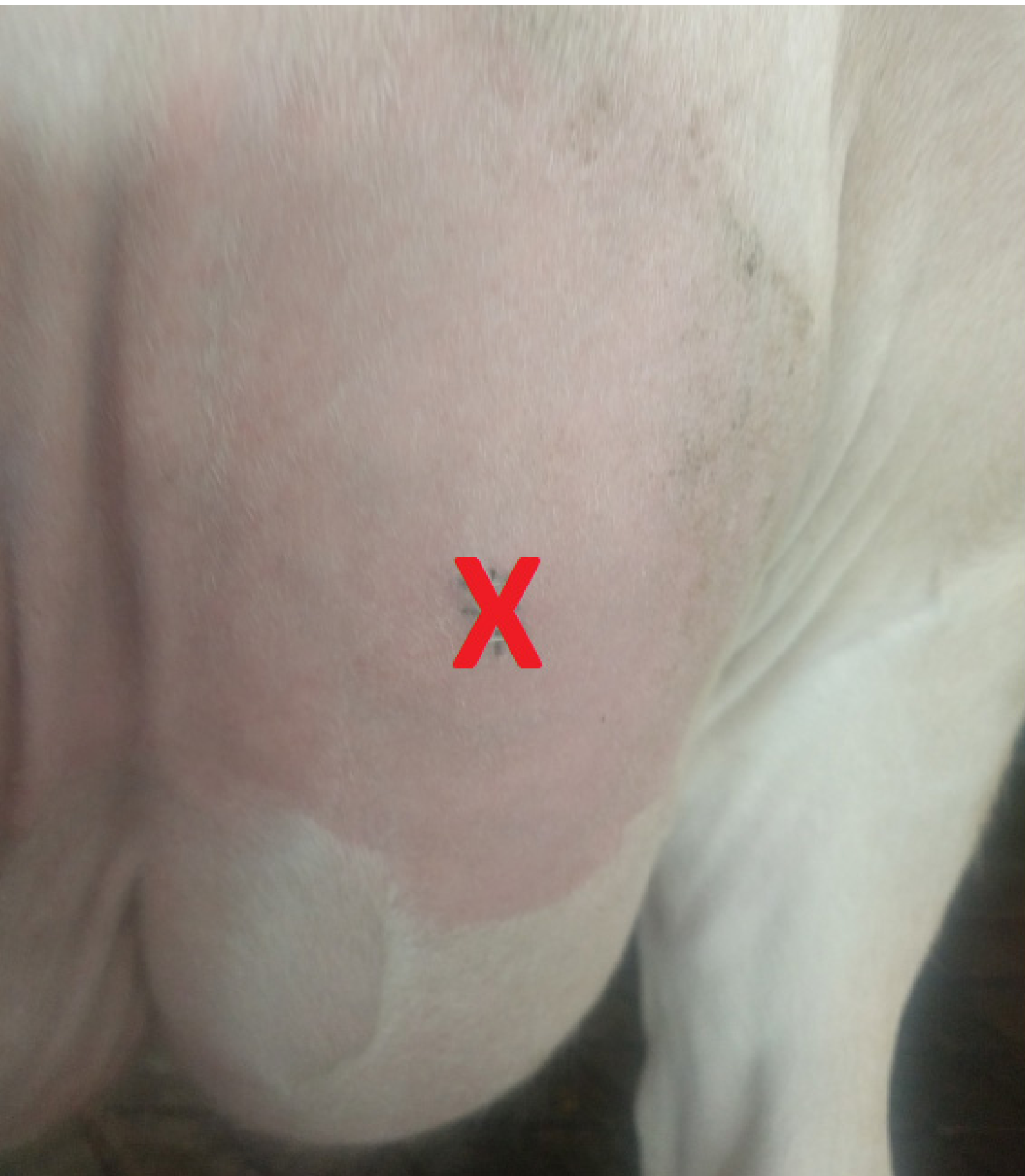

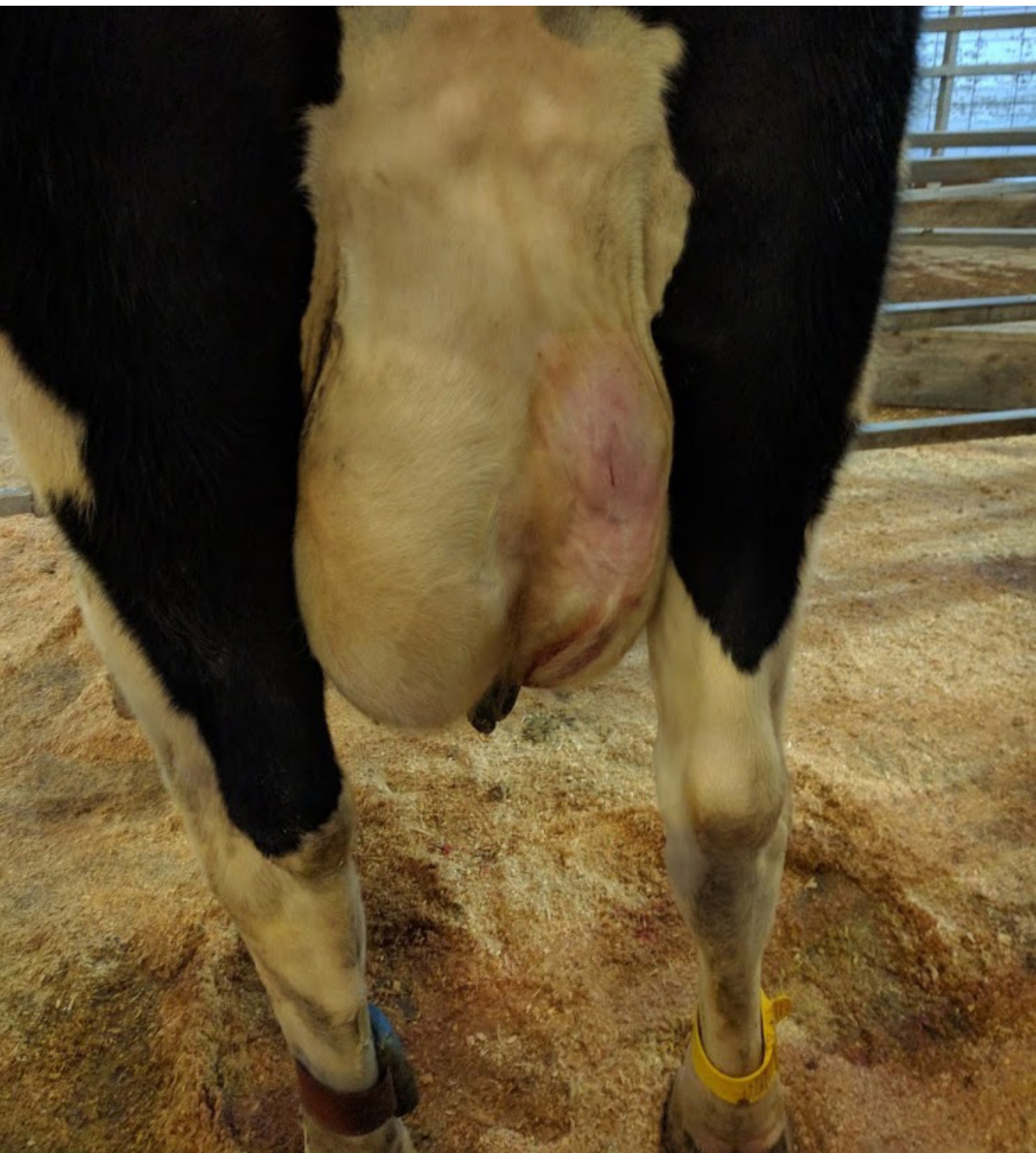Figure 2





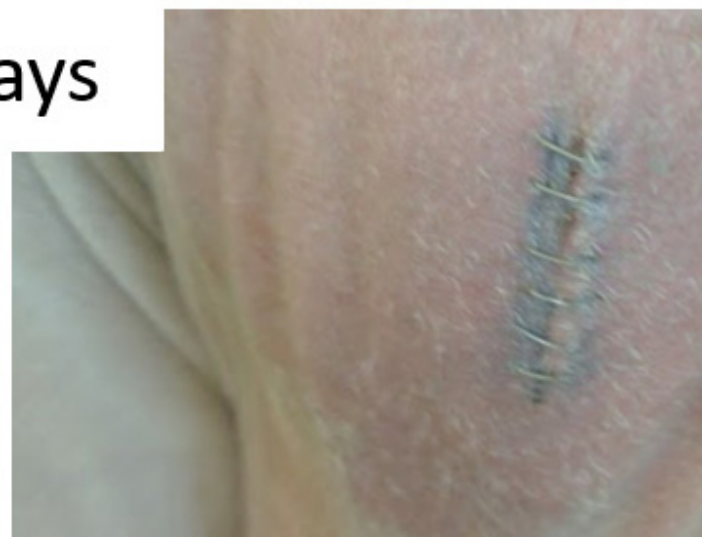
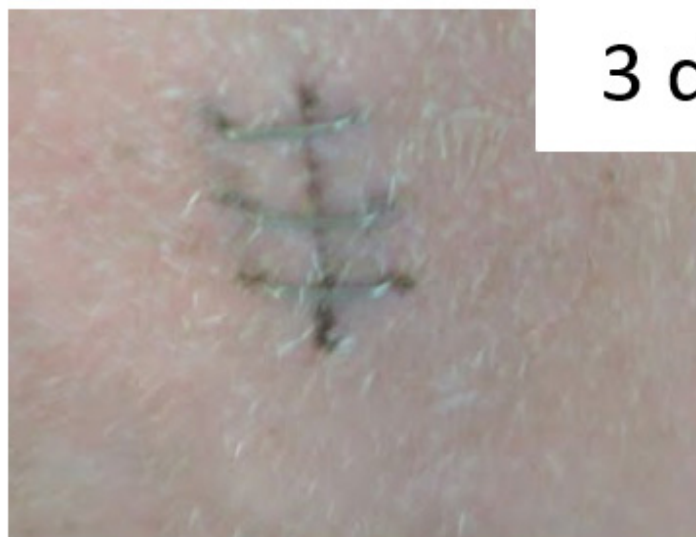
Needle biopsy

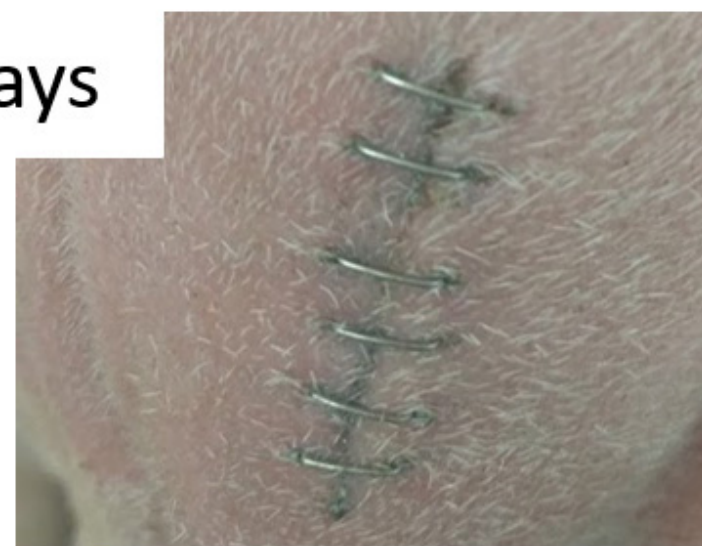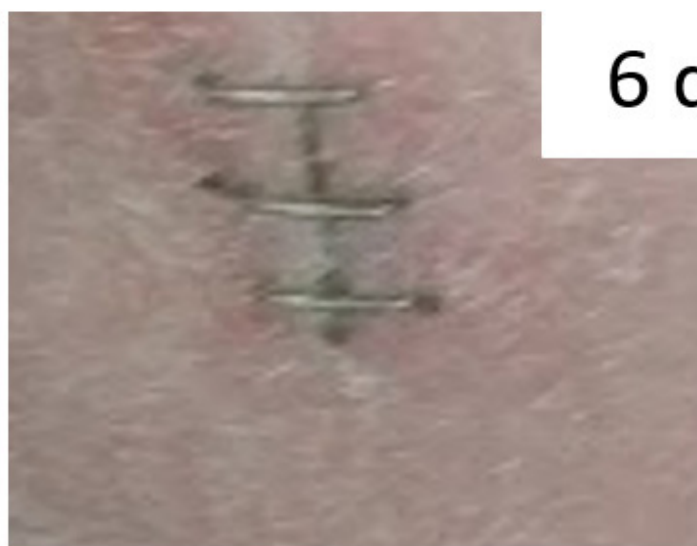Core biopsy

A

3 days

**B**

6 days

**C**

10 days

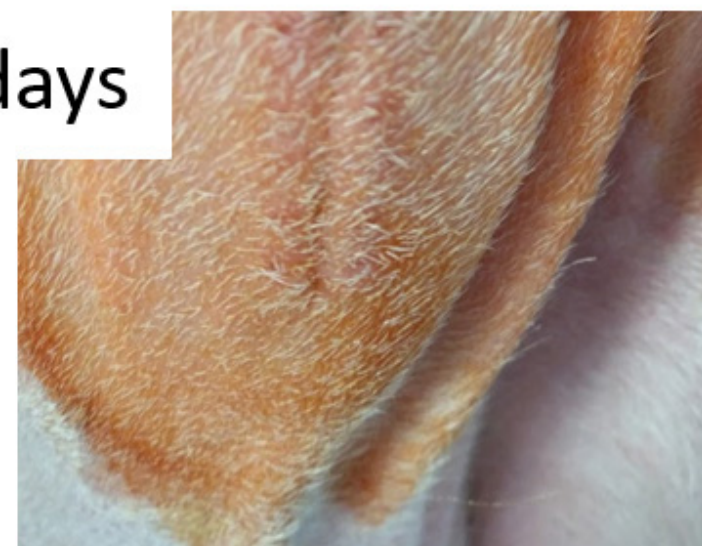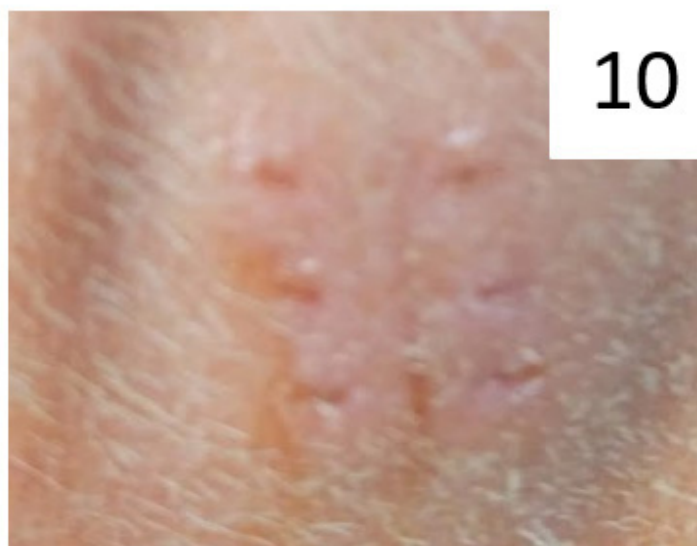


Figure 7

[Click here to access/download;Figure;Figure 7. Revised.eps](#)

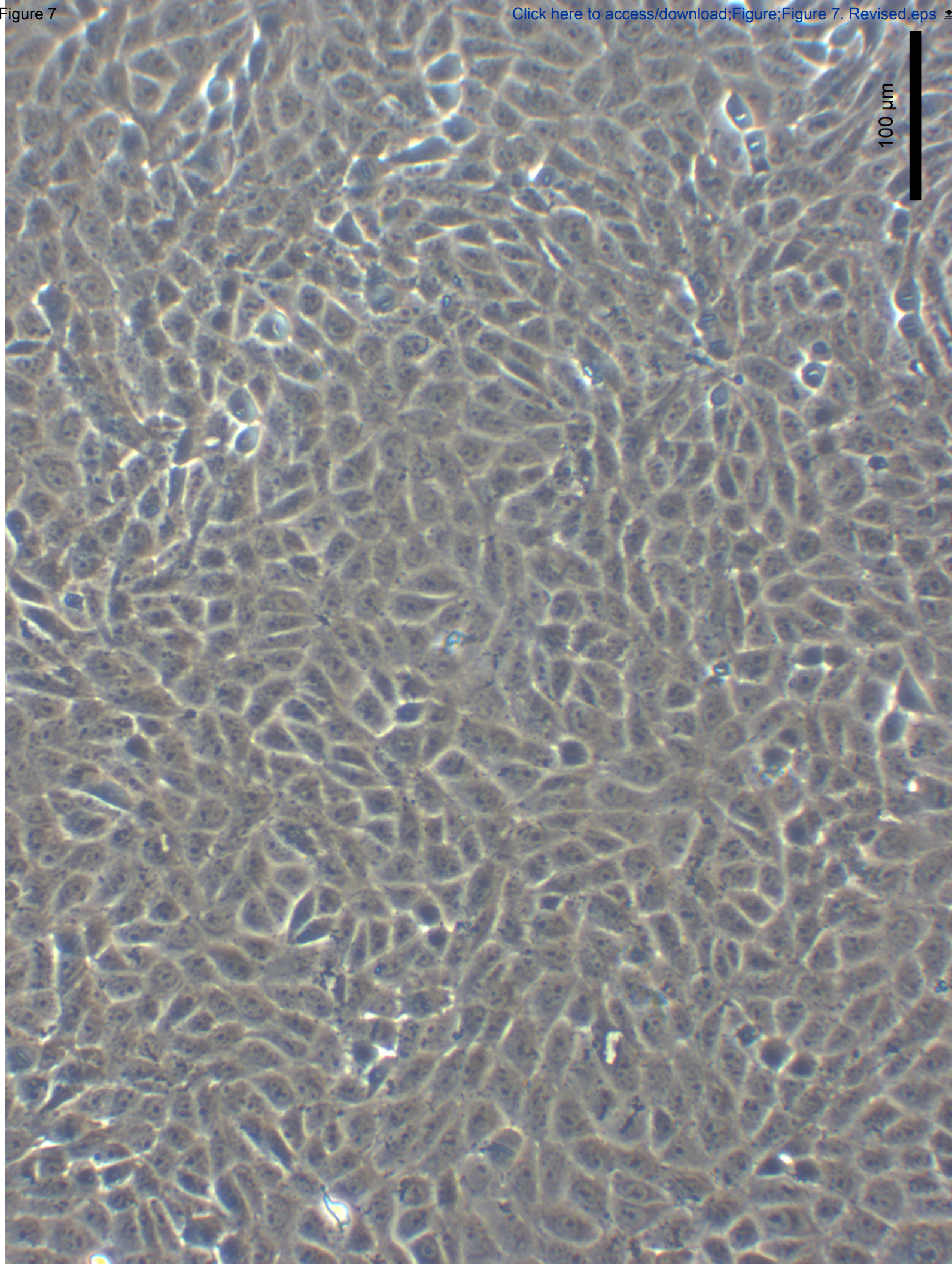
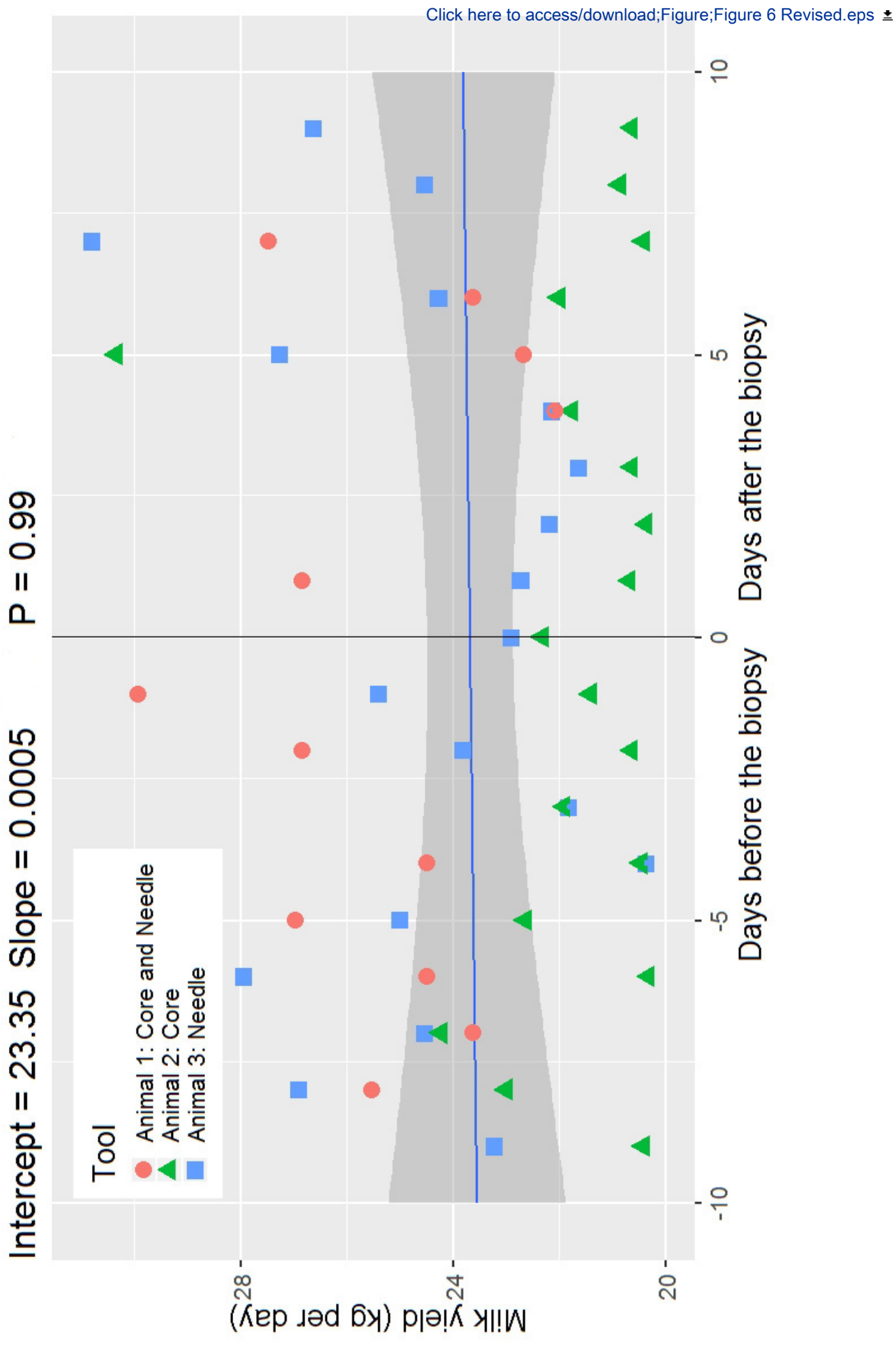


Figure 6



Name of Material/ Equipment	Company	Catalog Number
70% Isopropyl alcohol	Walmart	565106257
Aerosol spray to kill and repel flies	MWI	14339
Biopsy needles, 12 G × 16 cm	C. R. Bard	MN1216
Butterfly infusion set (18 G needle)	Fisher	22-258087
Cell culture dishes	Fisher	08-772E
Cordless drill (low speed)	Hitachi	DS10DFL
Core biopsy instrument, Farr et al. (1996)		
Cows		
Flunixin meglumine	MWI/VetOne	501018
Folding table	Amazon	
Forceps	Fisher	09-753-50
Gloves non-sterile	Fisher	17-200-845
Hard brush	Sullivan Supply	18270
Head gate		
Lidocaine hydrochloride 2% injectable	MWI/VetOne	510212
Livestock body wash	eZall Technologies	39384
Needle 18 G (1 to 1/5")	Fisher	14-821-15A
Needle 20 G (1 to 1/5")	Fisher	14-815-526
Phosphate buffered saline (0.9%)	Fisher	20-012-043
Povidone Iodine ointment	Jeffers	#VED1A
Povidone iodine scrub solution (0.75% iodine)	MWI/VetOne	510094
Reusable biopsy instrument	C. R. Bard	MG1522
Rope halter	Nasco farm and ranch	C10852
Scalpel blades (#10)	MWI	033870
Scalpel holders (#3)	MWI	602008
Self seal autoclave pouch 10 x 5.5 in.	Fisher	19-130-0038
Sterile cotton gauze sponges	Fisher	22-037-986
Sterile gauze pads	Fisher	19-090-735
Sterile surgical gloves	Surgical gloves	19-166-679
Sterile surgical towels	Fisher	50-118-0339
Stethoscope	Littmann Master Classic II	1392
Surgical clipper	Oster A5	078005-010-003

Surgical clipper blades (#40)	Oster	78919-016
Surgical staple remover	MWI	541
Surgical stapler pre-loaded	MWI	17713
Syringes of 10 mL	Fisher	14-823-224
Syringes of 2 mL	Fisher	22-028854
Syringes of 20 mL	Fisher	22-034507
Syringes of 5 mL	Fisher	22-028855
Thermometer	Agri-Pro Enterprises Inc	72000
Tolazine hydrochloride	Akorn Animal Health	61311-486-10
Tweezer	Fisher	14-955-025
Water hose	Miracle-Gro, Walmart	554990501
Water-resistant aerosol bandage (aluminum powder 40 mg)	MWI	010728
Xylazine hydrochloride	MWI/VetOne	510650

Comments/Description

1 L

1 bottle (if necessary)

2

1

4

1

2, custom metal fabrication. To request the tool contact the authors.

cattle healthy

1.1 to 2.2 mg/kg of body weight

1

1

9, size dependent

1, to wash the cows

1, customized for dairy cows

6 mL was used, from 3 to 8 mL

1, to wash the cows

6

6

1 L

500 g (if necessary)

1 L

1

2, cow size

2

1

1 case of 800

4

4

3, size dependent

6

1

1, preparation of the animal for biopsy

1, preparation of the animal for biopsy

1

5

3

3

3

3

1

2 to 4 mg/kg of body weight (if necessary)

1, for handle the tissue sample

1, to wash the cows

1 bottle

0.01 to 0.05 mg/kg of body weight



1 Alewife Center #200
Cambridge, MA 02140
tel. 617.845.9051
www.jove.com

ARTICLE AND VIDEO LICENSE AGREEMENT - UK

Title of Article: Bovine Mammary Gland Biopsy Techniques

Author(s): Veridiana L. Daley, Charles Dye, Sophie H. Borges, R. Michael Akers, Francisco C. Rodrigues, John P. Cant, John Doelman, Peter Yoder, Karan Kumar, Dave Webster, Mark D. Havigan

Item 1 (check one box): The Author elects to have the Materials be made available (as described at

<http://www.jove.com/author>) via: ☐ Standard Access ☒ Open Access

Item 2 (check one box):

- ☒ The Author is NOT a United States government employee.
- ☐ The Author is a United States government employee and the Materials were prepared in the course of his or her duties as a United States government employee.
- ☐ The Author is a United States government employee but the Materials were NOT prepared in the course of his or her duties as a United States government employee.

ARTICLE AND VIDEO LICENSE AGREEMENT

1. Defined Terms. As used in this Article and Video License Agreement, the following terms shall have the following meanings: "Agreement" means this Article and Video License Agreement; "Article" means the article specified on the last page of this Agreement, including any associated materials such as texts, figures, tables, artwork, abstracts, or summaries contained therein; "Author" means the author who is a signatory to this Agreement; "Collective Work" means a work, such as a periodical issue, anthology or encyclopedia, in which the Materials in their entirety in unmodified form, along with a number of other contributions, constituting separate and independent works in themselves, are assembled into a collective whole; "CRC License" means the Creative Commons

Attribution 3.0 Agreement (also known as CC-BY), the terms and conditions of which can be found at: <http://creativecommons.org/licenses/by/3.0/us/legalcode>;

"Derivative Work" means a work based upon the Materials or upon the Materials and other pre-existing works, such as a translation, musical arrangement, dramatization, fictionalization, motion picture version, sound recording, art reproduction, abridgment, condensation, or any other form in which the Materials may be recast, transformed, or adapted; "Institution" means the institution, listed on the last page of this Agreement, by which the Author was employed at the time of the creation of the Materials; "JoVE" means MyJoVE Corporation, a Massachusetts corporation and the publisher of *The Journal of Visualized Experiments*;

"Materials" means the Article and / or the Video; "Parties" means the Author and JoVE; "Video" means any video(s) made by the Author, alone or in conjunction with any other parties, or by JoVE or its affiliates or agents, individually or in collaboration with the Author or any other parties, incorporating all or any portion of the Article, and in which the Author may or may not appear.

2. Background. The Author, who is the author of the Article, in order to ensure the dissemination and protection of the Article, desires to have the JoVE publish the Article and create and transmit videos based on the Article. In furtherance of such goals, the Parties desire to memorialize in this Agreement the respective rights of each Party in and to the Article and the Video.

3. Grant of Rights in Article. In consideration of JoVE agreeing to publish the Article, the Author hereby grants to JoVE, subject to Sections 4 and 7 below, the exclusive, royalty-free, perpetual (for the full term of copyright in the Article, including any extensions thereto) license (a) to publish, reproduce, distribute, display and store the Article in all forms, formats and media whether now known or hereafter developed (including without limitation in print, digital and electronic form) throughout the world, (b) to translate the Article into other languages, create adaptations, summaries or extracts of the Article or other Derivative Works (including, without limitation, the Video) or Collective Works based on all or any portion of the Article and exercise all of the rights set forth in (a) above in such translations, adaptations, summaries, extracts, Derivative Works or Collective Works and

(c) to license others to do any or all of the above. The foregoing rights may be exercised in all media and formats, whether now known or hereafter devised, and include the right to make such modifications as are technically necessary to exercise the rights in other media and formats. If the "Open Access" box has been checked in Item 1 above, JoVE and the Author hereby grant to the public all such rights in the Article as provided in, but subject to all limitations and requirements set forth in, the CRC License.

4. Retention of Rights in Article. Notwithstanding the exclusive license granted to JoVE in Section 3 above, the

Author shall, with respect to the Article, retain the non-exclusive right to use all or part of the Article for the non-commercial purpose of giving lectures, presentations or teaching classes, and to post a copy of the Article on the Institution's website or the Author's personal website, in each case provided that a link to the Article on the JoVE website is provided and notice of JoVE's copyright in the Article is included. All non-copyright intellectual property rights in and to the Article, such as patent rights, shall remain with the Author.

5. Grant of Rights in Video – Standard Access. This **Section 5** applies if the "Standard Access" box has been checked in **Item 1** above or if no box has been checked in **Item 1** above. In consideration of JoVE agreeing to produce, display or otherwise assist with the Video, the Author hereby acknowledges and agrees that, Subject to **Section 7** below, JoVE is and shall be the sole and exclusive owner of all rights of any nature, including, without limitation, all copyrights, in and to the Video. To the extent that, by law, the Author is deemed, now or at any time in the future, to have any rights of any nature in or to the Video, the Author hereby disclaims all such rights and transfers all such rights to JoVE.

6. Grant of Rights in Video – Open Access. This **Section 6** applies only if the "Open Access" box has been checked in **Item 1** above. In consideration of JoVE agreeing to produce, display or otherwise assist with the Video, the Author hereby grants to JoVE, subject to **Section 7** below, the exclusive, royalty-free, perpetual (for the full term of copyright in the Article, including any extensions thereto) license (a) to publish, reproduce, distribute, display and store the Video in all forms, formats and media whether now known or hereafter developed (including without limitation in print, digital and electronic form) throughout the world, (b) to translate the Video into other languages, create adaptations, summaries or extracts of the Video or other Derivative Works or Collective Works based on all or any portion of the Video and exercise all of the rights set forth in (a) above in such translations, adaptations, summaries, extracts, Derivative Works or Collective Works and (c) to license others to do any or all of the above. The foregoing rights may be exercised in all media and formats, whether now known or hereafter devised, and include the right to make such modifications as are technically necessary to exercise the rights in other media and formats.

7. Government Employees. If the Author is a United States government employee and the Article was prepared in the course of his or her duties as a United States government employee, as indicated in **Item 2** above, and any of the licenses or grants granted by the Author hereunder exceed the scope of the 17 U.S.C. 403, then the rights granted hereunder shall be limited to the maximum rights permitted under such statute. In such case, all provisions contained herein that are not in conflict with such statute shall remain in full force and effect, and all provisions contained herein that do so conflict

shall be deemed to be amended so as to provide to JoVE the maximum rights permissible within such statute.

8. Likeness, Privacy, Personality. The Author hereby grants JoVE the right to use the Author's name, voice, likeness, picture, photograph, image, biography and performance in any way, commercial or otherwise, in connection with the Materials and the sale, promotion and distribution thereof. The Author hereby waives any and all rights he or she may have, relating to his or her appearance in the Video or otherwise relating to the Materials, under all applicable privacy, likeness, personality or similar laws.

9. Author Warranties. The Author represents and warrants that the Article is original, that it has not been published, that the copyright interest is owned by the Author (or, if more than one author is listed at the beginning of this Agreement, by such authors collectively) and has not been assigned, licensed, or otherwise transferred to any other party. The Author represents and warrants that the author(s) listed at the top of this Agreement are the only authors of the Materials. If more than one author is listed at the top of this Agreement and if any such author has not entered into a separate Article and Video License Agreement with JoVE relating to the Materials, the Author represents and warrants that the Author has been authorized by each of the other such authors to execute this Agreement on his or her behalf and to bind him or her with respect to the terms of this Agreement as if each of them had been a party hereto as an Author. The Author warrants that the use, reproduction, distribution, public or private performance or display, and/or modification of all or any portion of the Materials does not and will not violate, infringe and/or misappropriate the patent, trademark, intellectual property or other rights of any third party. The Author represents and warrants that it has and will continue to comply with all government, institutional and other regulations, including, without limitation all institutional, laboratory, hospital, ethical, human and animal treatment, privacy, and all other rules, regulations, laws, procedures or guidelines, applicable to the Materials, and that all research involving human and animal subjects has been approved by the Author's relevant institutional review board.

10. JoVE Discretion. If the Author requests the assistance of JoVE in producing the Video in the Author's facility, the Author shall ensure that the presence of JoVE employees, agents or independent contractors is in accordance with the relevant regulations of the Author's institution. If more than one author is listed at the beginning of this Agreement, JoVE may, in its sole discretion, elect not take any action with respect to the Article until such time as it has received complete, executed Article and Video License Agreements from each such author. JoVE reserves the right, in its absolute and sole discretion and without giving any reason therefore, to accept or decline any work submitted to JoVE. JoVE and its employees, agents and independent contractors shall have full, unfettered access to the facilities of the Author or of the Author's institution as necessary to make the Video, whether actually published or not. JoVE has sole discretion as to the method of making and publishing the Materials, including,

without limitation, to all decisions regarding editing, lighting, filming, timing of publication, if any, length, quality, content and the like.

11. Indemnification. The Author agrees to indemnify JoVE and/or its successors and assigns from and against any and all claims, costs, and expenses, including attorney's fees, arising out of any breach of any warranty or other representations contained herein. The Author further agrees to indemnify and hold harmless JoVE from and against any and all claims, costs, and expenses, including attorney's fees, resulting from the breach by the Author of any representation or warranty contained herein or from allegations or instances of violation of intellectual property rights, damage to the Author's or the Author's institution's facilities, fraud, libel, defamation, research, equipment, experiments, property damage, personal injury, violations of institutional, laboratory, hospital, ethical, human and animal treatment, privacy or other rules, regulations, laws, procedures or guidelines, liabilities and other losses or damages related in any way to the submission of work to JoVE, making of videos by JoVE, or publication in JoVE or elsewhere by JoVE. The Author shall be responsible for, and shall hold JoVE harmless from, damages caused by lack of sterilization, lack of cleanliness or by contamination due to the making of a video by JoVE its employees, agents or independent contractors. All sterilization, cleanliness or decontamination procedures shall be solely the responsibility of the Author and shall be undertaken at the Author's expense. All indemnifications provided herein shall include JoVE's attorney's fees and costs related to said losses or

damages. Such indemnification and holding harmless shall include such losses or damages incurred by, or in connection with, acts or omissions of JoVE, its employees, agents or independent contractors.

12. Fees. To cover the cost incurred for publication, JoVE must receive payment before production and publication the Materials. Payment is due in 21 days of invoice. Should the Materials not be published due to an editorial or production decision, these funds will be returned to the Author. Withdrawal by the Author of any submitted Materials after final peer review approval will result in a US\$1,200 fee to cover pre-production expenses incurred by JoVE. If payment is not received by the completion of filming, production and publication of the Materials will be suspended until payment is received.

13. Transfer, Governing Law. This Agreement may be assigned by JoVE and shall inure to the benefits of any of JoVE's successors and assignees. This Agreement shall be governed and construed by the internal laws of the Commonwealth of Massachusetts without giving effect to any conflict of law provision thereunder. This Agreement may be executed in counterparts, each of which shall be deemed an original, but all of which together shall be deemed to be one and the same agreement. A signed copy of this Agreement delivered by facsimile, e-mail or other means of electronic transmission shall be deemed to have the same legal effect as delivery of an original signed copy of this Agreement.

A signed copy of this document must be sent with all new submissions. Only one Agreement required per submission.

AUTHOR:

Name:

VERIDIANA L. DALEX

Department:

NATIONAL ANIMAL NUTRITION PROGRAM (NANP), DEPARTMENT OF ANIMAL AND FOOD SCIENCES

Institution:

UNIVERSITY OF KENTUCKY, KY, USA

Article Title:

Bovine Mammary Gland Biopsy Techniques

Signature:

VERIDIANA L. DALEX

Date:

6/7/2018

Please submit a signed and dated copy of this license by one of the following three methods:

- 1) Upload a scanned copy as a PDF to the JoVE submission site upon manuscript submission (preferred);
- 2) Fax the document to +1.866.381.2236; or
- 3) Mail the document to JoVE / Attn: JoVE Editorial / 1 Alewife Center Suite 200 / Cambridge, MA 02140

For questions, please email editorial@jove.com or call +1.617.945.9051.

MS # (internal use):

Dr. Veridiana L Daley
 Department of Dairy Science
 3290 Litton-Reaves Hall
 175 West Campus Drive
 Blacksburg, VA 24061

November 10th, 2018

Subject: Rebuttal letter for the manuscript JoVE58602. "Bovine Mammary Gland Biopsy Techniques.

Dear Editors

We would like to thank the editors and reviewers for the valuable comments on our submitted video and manuscript.

Please find below the reviewers' comments and our responses.

Yours sincerely,

Dr. Veridiana L. Daley
 On behalf of all authors

1) Changes to be made by the Author(s) regarding the video:

Your manuscript, JoVE58602R1 "Bovine Mammary Gland Biopsy Techniques," has been editorially reviewed and the following comments need to be addressed. One minor revision for the video is needed before we can formally accept your manuscript. No changes are requested for the written manuscript.

2:18 - This chapter is now numbered III, but there was only one chapter preceding it. The video numbering could be removed entirely to not be confused with the numbering of the protocol text.

The revise high-resolution video can be uploaded here:
<https://www.dropbox.com/request/tdjEgmVqTxYPx8haOFzN>

Authors: Revised. The video numbering has been removed and uploaded. No changes were made in the written manuscript.