

Journal of Visualized Experiments

From Start to Finish: A Guide for the Development and Angiographic Use of the Rabbit VX2 Model for Liver Cancer

--Manuscript Draft--

Article Type:	Methods Article - JoVE Produced Video
Manuscript Number:	JoVE58600R1
Full Title:	From Start to Finish: A Guide for the Development and Angiographic Use of the Rabbit VX2 Model for Liver Cancer
Keywords:	VX2; Rabbit; Liver; cancer; Translational; Model; Hepatocellular carcinoma; Arteriography
Corresponding Author:	Ron C Gaba University of Illinois at Chicago College of Medicine Chicago, UNITED STATES
Corresponding Author's Institution:	University of Illinois at Chicago College of Medicine
Corresponding Author E-Mail:	rgaba@uic.edu
Order of Authors:	Ramzy Khabbaz Yu-Hui Huang Alexandra A Smith Kelly D Garcia R Peter Lokken Ron C Gaba
Additional Information:	
Question	Response
Please indicate whether this article will be Standard Access or Open Access.	Standard Access (US\$2,400)
Please indicate the city, state/province, and country where this article will be filmed . Please do not use abbreviations.	1740 West Taylor St, MC 533

TITLE:

Development and Angiographic Use of the Rabbit VX2 Model for Liver Cancer

AUTHORS AND AFFILIATIONS:

Ramzy C Khabbaz^{1, 2}, Yu-Hui Huang^{1, 2}, Alexandra A Smith³, Kelly D Garcia³, R Peter Lokken¹, Ron C Gaba¹

¹Department of Radiology, University of Illinois, Chicago, IL, USA

²College of Medicine, University of Illinois, Chicago, IL, USA

³Department of Biological Resources Laboratory, University of Illinois, Chicago, IL, USA

Corresponding Author:

Ron C. Gaba

rgaba@uic.edu

312-996-0242

Email Addresses of Co-Authors:

Ramzy C. Khabbaz (khabbaz1@uic.edu)

Yu-Hui Huang (yhuang61@uic.edu)

Alexandra S. Smith (smithale@uic.edu)

Kelly Garcia (kellygar@uic.edu)

R. Peter Lokken (plokken@uic.edu)

KEYWORDS:

VX2, Rabbit, Liver, Cancer, Translational, Model, Hepatocellular carcinoma, Arteriography

SUMMARY:

The goal of this article is to provide a primer for the development and use of the VX2 carcinoma rabbit model for liver cancer.

ABSTRACT:

The rabbit VX2 tumor is an animal model commonly utilized for translational research regarding hepatocellular carcinoma (HCC) in the field of Interventional Radiology. This model employs an anaplastic squamous cell carcinoma that is easily and reliably propagated in the skeletal muscle of donor rabbits for eventual harvest and allograft implantation into the liver of naïve recipients. This tumor graft rapidly grows within the liver of recipient rabbits into an angiographically identifiable tumor characterized by a necrotic core surrounded by a viable hypervascular capsule. The physical size of the rabbit anatomy is sufficient to facilitate vascular instrumentation allowing for the application and testing of various interventional techniques. Despite these benefits, there exists a paucity of technical resources to act as a concrete reference for researchers working with the model. Herein, we present a comprehensive visual outline for the technical aspects of development, growth, propagation, and angiographic utilization of the rabbit VX2 tumor model for use by novice and experienced researchers alike.

INTRODUCTION:

The rabbit VX2 tumor model has played a role in experimental oncology since its development in 1935^{1,2}. This tumor is a virus-induced anaplastic squamous cell carcinoma characterized by hypervascularity, rapid growth, and easy propagation in skeletal muscle^{3,4}. While the rabbit VX2 tumor model has been used to investigate a multitude of cancers⁵⁻⁸; the focus of this paper is liver cancer⁹.

The purpose of the method described is to present a model for primary liver cancer, or hepatocellular carcinoma (HCC), that can be used by Interventional Radiologists for translational research. It can be used for pharmacokinetic studies, therapeutic investigations, and ablative method testing¹⁰⁻¹⁵.

The method detailed herein yields multiple advantages over other models within the same sphere such as rodent models like rats, mice, and woodchucks, or larger models like primates¹⁶. One of the primary benefits is the rapid and reliable tumor growth which allows researchers to establish an active tumor line within a month of first hind limb propagation¹⁷. Additionally, this tumor has straightforward sonographic visibility and a hypervascular periphery which allows for both transarterial locoregional treatments and ablative therapies. Finally, and most importantly, the size of the rabbit vasculature permits feasible and technically easy utilization of vascular instrumentation¹⁸.

PROTOCOL:

The following protocol follows all requirements and guidelines mandated by the University of Illinois - Chicago. It was reviewed and approved by the local Institutional Animal Care and Use Committee prior to execution.

1. VX2 Hind Limb Tumor Development

1.1. Procure the VX2 tumor cell line from the National Cancer Institute Division of Cancer Treatment Diagnosis and Treatment Tumor/Cell Line Repository.

Note: At this time, the order catalog can be found at the following link: <https://dtp.cancer.gov/repositories/>.

1.2. To prepare the cell suspension for injection, place the frozen VX2 sample and methylcellulose medium in lukewarm water until they have thawed.

1.2.1. Aspirate 0.5–1 mL of the thawed cell suspension and an equal volume of thawed methylcellulose medium into a 5-mL syringe.

Note: It may help to use a 21 or 22 G needle to aspirate the cell suspension and a larger gauge needle to aspirate the methylcellulose medium. Place the syringes on ice.

1.3 Prepare the hind limb tumor donor rabbit for inoculation of cell suspension, starting with

sedation using 1 mg/kg acepromazine and 0.02 mg/kg buprenorphine given intramuscularly. Shave the inoculation site (hind limb) with clippers and clean the shaved area with an alcohol- or iodine-based agent.

Note: Meloxicam can be given at a dose of 0.2 mg/kg subcutaneously for analgesia. Rabbit fur is difficult to shave. It is recommended that the researcher perform multiple passes, first focusing on clearing a bulk of the fur and then pressing the clippers against the skin and going against the grain.

1.4 Attach a 16 G needle to the 5-mL syringe containing the cell suspension and inject 1 mL of the suspension into the belly of the hind limb muscle of the donor rabbit, roughly 1 cm deep. Be sure to guard the sciatic nerve running within a palpable groove along the femur.

Note: Fresh VX2 successfully inoculates 88% of subjects while frozen and thawed VX2 is only successful 33% of the time¹⁹.

CAUTION: The VX2 tumor will grow quickly. Side effects that may be noted as the tumor progresses are: increased respiratory rate, lethargy, decreased alertness, and/or behavioral changes (*e.g.*, unusual aggressiveness). Consequently, recommendations are to monitor the animals closely and to plan for tumor harvest within two weeks after inoculation.

2. VX2 Hind Limb Tumor Growth and Harvesting

Note: Assuming successful inoculation, there should be a palpable (3–4 cm) tumor nodule at the injection site within 2 weeks. Usually, this nodule will be palpable around 1 week; however, it is better to let the tumor grow to allow for sufficient tissue collection. Typically, this nodule will be firm, indurated, and elevated above the level of the muscle. If

2.1. Palpate the inoculated area at 2 weeks from inoculation. If no tumor growth is detected at 2 weeks, perform step 1 again. See **Figure 1**.

Note: The presence of tumor can also be assessed via ultrasound. While there have been no studies to assess the difference in tumor growth metrics when propagated from frozen stock as compared to fresh stock, it has been our experience that the frozen stock tumor grows slightly slower and will be detectable after its fresh stock counterpart. Regardless, either method should yield a harvestable tumor by 2 weeks.

2.2. Prepare the hind limb tumor donor for tumor harvest. Anesthetize the rabbit with 45 mg/kg ketamine and 5 mg/kg xylazine. Euthanize with an intravenous (IV) dose of sodium pentobarbital exceeding 390 mg/kg.

2.3. Once the rabbit has been euthanized, begin harvesting the tumor by removing the cutaneous and subcutaneous tissue overlying the tumor nodule using a scalpel with whichever size blade the researcher sees fit. See **Figure 2**.

2.4. Once the tumor nodule has been identified within the hind limb muscle, remove the tumor *en bloc* using wide curvilinear margins. For this, cut the tendinous attachment points at the proximal and distal ends of the of the muscle and then trace the scalpel blade along the underlying bone. Bisect the explanted specimen exposing the tumor capsule and necrotic core.

See **Figure 3**.

Note: The VX2 tumor has a highly necrotic core. Be sure to use proper eye protection and other personal protective equipment when harvesting the tumor, since any damage to the tumor capsule can result in high pressure ejection of necrotic debris.

2.5. Gently scrape the necrotic core with a blunt object (*e.g.* forceps, hemostats) to clean the tumor. This should allow for better visualization of the tumor capsule and the transition point between capsule and surrounding muscle. See **Figure 4**.

2.6. From this sample, harvest several pieces of tumor approximately 1–2 mm³ and immediately store them in a cup containing room temperature sterile saline.

Note: These tumor samples will be used for subsequent intrahepatic implantation.

2.7. Place the remaining tumor in a sterile Petri dish and bathe it with Dulbecco's Modified Eagle's Medium (DMEM). If this specimen is kept cold on ice, it can be preserved for handling up to 2–3 h later.

3. Liver Tumor Implantation via Laparotomy

3.1. Prepare the recipient rabbit for laparotomy. Anesthetize the recipient rabbit using 45 mg/kg ketamine and 5 mg/kg xylazine for induction followed by intubation and maintenance with 1%--3% isoflurane as needed. When the rabbit is anesthetized, shave the surgical site using hair clippers. Prepare and drape the abdomen in a sterile surgical fashion.

3.2. Using a #15-blade, initiate the laparotomy by making a small downward vertical midline incision through the rabbit's skin starting from the xiphoid process. This should be easily palpated and tends to be roughly the size of an American penny. See **Figure 5**.

3.3. Reflect the skin and identify the *linea alba*. This should be a reflective white band of tissue traveling inferiorly in the midline. Use blunt dissection to traverse the *linea alba* and expose the peritoneum. See **Figure 6**.

Note: The peritoneum is easily identified since it will be directly overlying the bowel, which can be seen moving with respiration.

CAUTION: The peritoneum tends to be adherent to the underlying bowel due to surface tension. Using blunt trauma to dissect the *linea alba* helps to dissipate the risk of perforating the

underlying bowel.

3.4. Once the peritoneum is exposed, carefully dissect through it to enter the peritoneal cavity. The liver can now be identified. To better navigate the abdominal space, extend the midline incision 1–2 cm inferiorly through the skin, muscle, and peritoneum.

Note: Extending the midline incision can be easily and safely done by carefully inserting a curved hemostat into the peritoneal space with the curved tip facing superficially towards the peritoneum. Then open the hemostat slightly and use a blade to cut the tissue between the two arms of the hemostat.

3.5. Identify the left lobe of the liver in order to select a site for tumor implantation. The left lobe is infero-lateral to the medial lobe which sits in the midline.

3.6. Before attempting to draw the liver out of the peritoneal space, place a dry piece of gauze at the inferior aspect of the incision.

Note: The gauze will provide an adherent surface to lay the liver on to prevent it from retracting back into the abdomen.

3.7. Using either atraumatic forceps or a piece of wet gauze over the fingers, carefully draw the left lobe of the liver out of the abdomen through the incision and lay it down on the dry gauze placed earlier. See **Figure 7**.

CAUTION: The liver capsule is sensitive and can easily rupture. It is critical to be gentle when handling this organ to prevent capsular bleed, liver bruising, and/or eventual hemoperitoneum.

Note: Usually, the liver will declare itself visually upon entering the peritoneal space; however, if the rabbit's stomach is distended, the liver can be pushed cranially out of sight. If this is the case, gently lift the abdominal wall using a blunt probe. In this scenario, the liver tends to adhere to the ventral aspect of the diaphragm due to surface tension so carefully separate the liver using a blunt probe and it should detach. Then use atraumatic forceps to draw the liver out.

3.8. At this point, prepare the tumor tissue for implantation and place a piece of wet gauze over the liver to protect it.

3.9. Select a 1–2 mm³ piece of tumor tissue that was generated during step 2.6 for implantation into the liver. See **Figure 8**.

3.10. Using a #11-blade, puncture the liver tissue at a 45° angle making a 0.5 cm deep pocket, taking care not to penetrate the dorsal aspect of the liver capsule. Leave the blade in place after making the puncture. See **Figure 9**.

3.11. Gently lift the blade in a ventral direction to create a small pocket in the liver bed. Take the

tumor piece using forceps, place the tumor piece in this pocket and then remove the blade.

Note: The blade can be removed prior to inserting the tumor piece, however, the liver will bleed and this can obscure the puncture site making it difficult to identify.

CAUTION: Be sure to minimize contact of the tumor with any other structures to prevent unintentional tumor seeding. This can also be avoided by setting aside any tools used to assist with implantation afterwards.

3.12. At this point, place a piece of hemostatic agent, such as gel foam, over the tumor pocket to promote hemostasis and to prevent ejection of the tumor piece.

3.13. Return the liver to the abdomen, once hemostasis is confirmed.

3.14. Close the abdominal wall with 3-0 polydioxanone suture on a taper needle using a simple continuous stitch and close the skin with 4-0 polyglactin 910 sutures on a cutting needle using continuous subcuticular stitch.

CAUTION: When closing the abdominal wall, take care not to damage the omentum or other bowel structures in a suture throw.

Note: While this tumor will take at least 2 weeks to be definitively radiographically identifiable, it reaches a size of 1.5–2 cm diameter at 3 weeks of growth. Be careful not to allow the hepatic tumor to grow past 3.5–4 weeks since the tumor will form an exophytic mass and aggressively spread locally.

4. VX2 Tumor Suspension Preparation

4.1. Place a 40 μ m strainer into the mouth of a 50-mL conical propylene tube. Using the tumor from step 2.7, use a #15-blade to scrape the tumor surface to collect viable tumor and place these scrapings into the strainer.

4.2. Wash the viable tumor scrapings through a strainer using DMEM and then centrifuge the propylene tube at 1600 rpm for 8 min.

4.3. After the centrifuge is complete, remove the supernatant and discard it. Then add methylcellulose to the remaining cell block at a 1:1 volumetric ratio.

4.4 Inject this suspension into a hind limb donor rabbit following steps 1.3–1.4. Place the remaining suspension into 1 mL aliquots in cryogenic tubes and freeze them in liquid nitrogen for later use.

5. Angiographic Utilization of the VX2 Liver Tumor

5.1. Prepare the rabbit as described in step 3.1.

5.2. Palpate the femoral groove in the groin. When the groove has been identified, make a 2–3 cm linear incision along the groove. See **Figure 10**.

5.3. Using blunt dissection, locate and isolate the femoral bundle containing the femoral vein, artery, and nerve. See **Figure 11**.

5.4. Again, use blunt dissection to separate the femoral artery from the rest of the structures in the bundle and isolate the artery atop a scalpel handle. See **Figure 12**.

5.5. With a 3-French introducer kit, utilize the Seldinger technique to gain access with a needle. Insert a guidewire and remove the needle to advance the 3-French sheath into the vessel. See **Figure 13**.

CAUTION: Avoid using excessive force in advancing the 3-French sheath, as this can result in transection of the femoral artery.

5.6. Under fluoroscopic guidance and using a catheter, guidewire, and iohexol contrast agent, select for the celiac trunk — typically located at the T12 level — and then advance the catheter into the left hepatic artery via the common hepatic and proper hepatic.

5.7. At this point, administer the agent of choice through the catheter. Once the agent is administered, remove the catheter.

5.8. Using 3-0 silk suture, ligate the femoral artery proximally and distally to the insertion point of the sheath. Be sure to tighten the knot proximal to the sheath as it is withdrawn to prevent bleeding.

5.9. Close the groin incision with 4-0 polyglactin 910 sutures on a cutting needle using a subcuticular stitch.

5.10. Maintain standard post-operative care and monitor animal recovery. Perform euthanasia and necropsy as needed using standard techniques.

REPRESENTATIVE RESULTS:

When looking at **Figure 1**, it is clear that the quadricep of the rabbit is enlarged. Additionally, multiple small discrete nodules, typically correlating with tumor growth through the fascia, are visible. Upon palpation, the injected limb should appear than the non-injected limb. If a researcher requires more definitive assurance of tumor presence, ultrasound imaging can be used to identify the tumor embedded in the muscle. If a tumor is not detected, the hind limb should be re-injected with a tumor cell suspension.

In order to confirm successful vascular access, blood return into the sheath is observed on

aspiration as seen in **Figure 13D**. If vascular access was unsuccessful, attempted aspiration will yield air in the sheath or present with significant resistance when pulling the plunger of the syringe.

For liver tumor growth, there are two ways to confirm successful propagation: angiographically and on necropsy. On angiography, identification of the tumor may occur immediately as is the case in **Figure 14A** where the tumor draws blood supply directly from the common hepatic artery. It may also take some time in cases where the tumor is lateral as is the case in **Figure 14D**. If the tumor is not readily visible after injection of contrast into the common hepatic artery, the researcher should attempt to inject contrast into left and right hepatic arteries in order to improve the chances of highlighting the tumor. It may also help to look for aberrant arteries traveling laterally towards the distal edge of the liver as seen in **Figure 14C**. On necropsy, the tumor should be readily visible as seen in **Figure 15B** (compare to **Figure 15A**).

FIGURE AND TABLE LEGENDS:

Figure 1: Rabbit hind limb. Shaved rabbit hind limb with mass indicative of tumor growth.

Figure 2: Exposed hind limb. The same limb as shown **Figure 1** with overlying skin reflected revealing a large area of hypervascularity and discoloration distinct from the surrounding muscle representing the location of the tumor (white dotted line).

Figure 3: Tumor removed *en bloc* and bisected. (A) Tumor and surrounding muscle removed *en bloc*. **(B)** Tumor has been bisected to reveal its capsular wall and necrotic core. Tumor process can be seen in both halves as well as some necrotic debris.

Figure 4: Tumor capsule. A piece of tumor (T), adjacent muscle (M), and tumor capsule (white dotted line) separating the two.

Figure 5: Exposed xiphoid process. Skin and underlying muscle have been reflected to allow for visualization of the xiphoid process (black arrow) and gut (white arrow). The white star denotes the cranial direction.

Figure 6: Linea alba. Overlying skin and fascia have been reflected to allow for visualization of the *linea alba* (black arrow) running in a cranial to caudal direction. This area is avascular and provides for blood-loss free access of the peritoneal space.

Figure 7: Lobe of liver outside peritoneum. This image shows a lobe of the liver that was gently extracted from the peritoneal space and placed on a piece of gauze.

Figure 8: Post-processed tumor piece for implantation. A piece of tumor processed to the appropriate size for implantation placed next to the tip of a #11-blade for scale.

Figure 9: Creating a pocket in the liver for tumor implantation. An #11-blade is inserted to the

appropriate depth in the extracted lobe of the liver. This will create an appropriately sized pocked for the implantation of the tumor piece from **Figure 8**.

Figure 10: The femoral groove and initial incision. (A) Palpation of the hind limb allows for visualization of the femoral groove (white dotted line). (B) Initial incision in the hind limb made along the femoral groove.

Figure 11: Identification of the femoral bundle. Blunt dissection of the initial incision reveals femoral vein (black arrow).

Figure 12: Dissection of femoral bundle and isolation of femoral artery. (A) Dissection of the femoral bundle allows us to individually distinguish (from left to right) the femoral vein (FV), femoral artery (FA), and femoral nerve (FN). (B) The femoral artery isolated on a scalpel handle. Note the blood column allowing for distinction from the femoral nerve.

Figure 13: Vascular access. (A) A guidewire (G) is advanced into the femoral artery (FA) through the access needle (N) which was previously inserted into the femoral artery. (B) A sheath (S) and dilator (D) are advanced over the guidewire (G) into the femoral artery (FA). (C) Sheath (S) and dilator are advanced fully into the femoral artery (FA) up to the sheath hub. (D) Sheath is secured with silk after the dilator and guidewire have been removed. Aspiration yields blood (black arrow) in the sheath.

Figure 14: Angiographic imaging of hepatic tumor. (A) Catheter tip (white arrow) delivering contrast directly into artery feeding the tumor (white star). (B) Catheter tip (white arrow) delivering contrast into distal left hepatic artery and moderate contrast uptake by lateral tumor (white star). (C) Further contrast injection into tumor from B demonstrating an aberrant artery (white line) traveling from the catheter (white arrow) to the tumor (white star). (D) The tumor from B after further contrast uptake.

Figure 15: Rabbit liver. (A) A healthy rabbit liver showing the left medial lobe (white star) overlying the left lateral lobe (black star). (B) A rabbit liver with a fully developed hepatic tumor (white arrow).

DISCUSSION:

The first critical step in the VX2 tumor methodology is successful propagation of a tumor in the hind limb of a donor rabbit. Refer to the first paragraph in the “Representative Results” section for more information regarding this step.

The next critical step is ensuring that the viable tumor capsule is properly identified. Not only will this be necessary for tumor suspension preparation, but it is also important for selecting and generating tumor pieces for hepatic implantation. The demarcation between viable tumor and surrounding muscle tissue is annotated in **Figure 4**. If the incorrect tissue sample is scraped during suspension preparation, subsequent hind limb propagation will fail. If this occurs during hepatic implantation, tumor growth in the liver will not occur. This will not be apparent until angiography.

During the hepatic implantation process, care should be taken when approaching the left lobe of the liver. Oftentimes, if the liver is readily apparent when entering the peritoneum, it is actually the medial lobe of the liver that operators are observing. Implantation into the medial lobe of the liver presents a handful of issues for angiographic use. The first is the medial lobe's anatomic relationship with the spine. A medial lobe tumor can often be obfuscated by the spine on fluoroscopy making confirmation and treatment of the tumor difficult. Additionally, the gastroduodenal artery is more often associated with the vasculature supplying the medial lobe. This increases the risk of non-target embolization of the gut and can potentially lead to bowel ischemia/infarction and possible death of the animal. As stated earlier, this will not qualify as a failure; however, it does warrant more care during visualization and treatment.

The final critical step is successful and stable femoral artery access. As seen in **Figure 12**, the femoral artery should be isolated atop a scalpel blade handle. While this is mostly done to allow the researcher to more accurately perform the Seldinger technique²⁰, it should be maintained throughout the procedure. This is because removing the scalpel handle once the sheath has been introduced can cause unintended motion of the sheath within the vasculature leading to sheath occlusion and possible damage of the vasculature and surrounding structures. If the sheath becomes dislodged during the procedure, apply pressure in the femoral groove proximal to the access site in order to stop the bleeding, and the artery can then be ligated. Do not attempt to reinsert the sheath. The researcher can attempt to gain access from the contralateral femoral artery.

While the VX2 platform is a robust model in current use for translational research regarding HCC, it does have relevant shortcomings. The primary weakness of this model is that its disease state does not mimic that of a human HCC. The tumor induced is not pathologically similar to human HCC nor is the non-cirrhotic liver parenchymal microenvironment. Moreover, the VX2 tumor shows substantial internal necrosis, which excludes this model from use for treatment efficacy studies. Some alternative models include rodent models such as mice, rats, and woodchucks or larger animal models such as pigs and primates.^{16,21} These alternatives all provide different advantages and disadvantages; however, in the opinion of the authors, for angiographic utilization and cost efficacy, the VX2 rabbit remains dominant.

ACKNOWLEDGMENTS:

We would like to acknowledge the veterinary staff at the University of Illinois – Chicago's Biological Resources Laboratory.

DISCLOSURES:

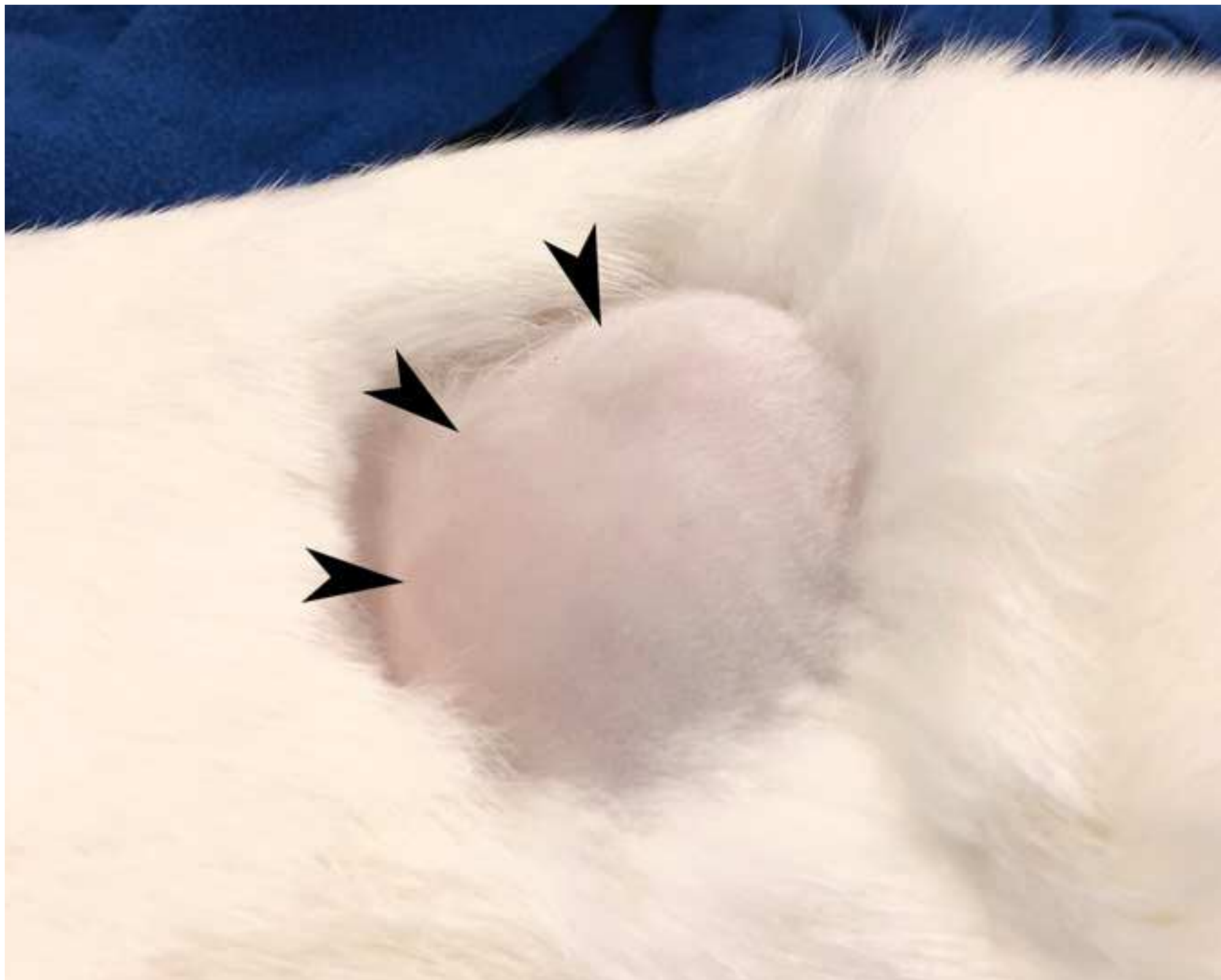
The authors have no conflicts to disclose.

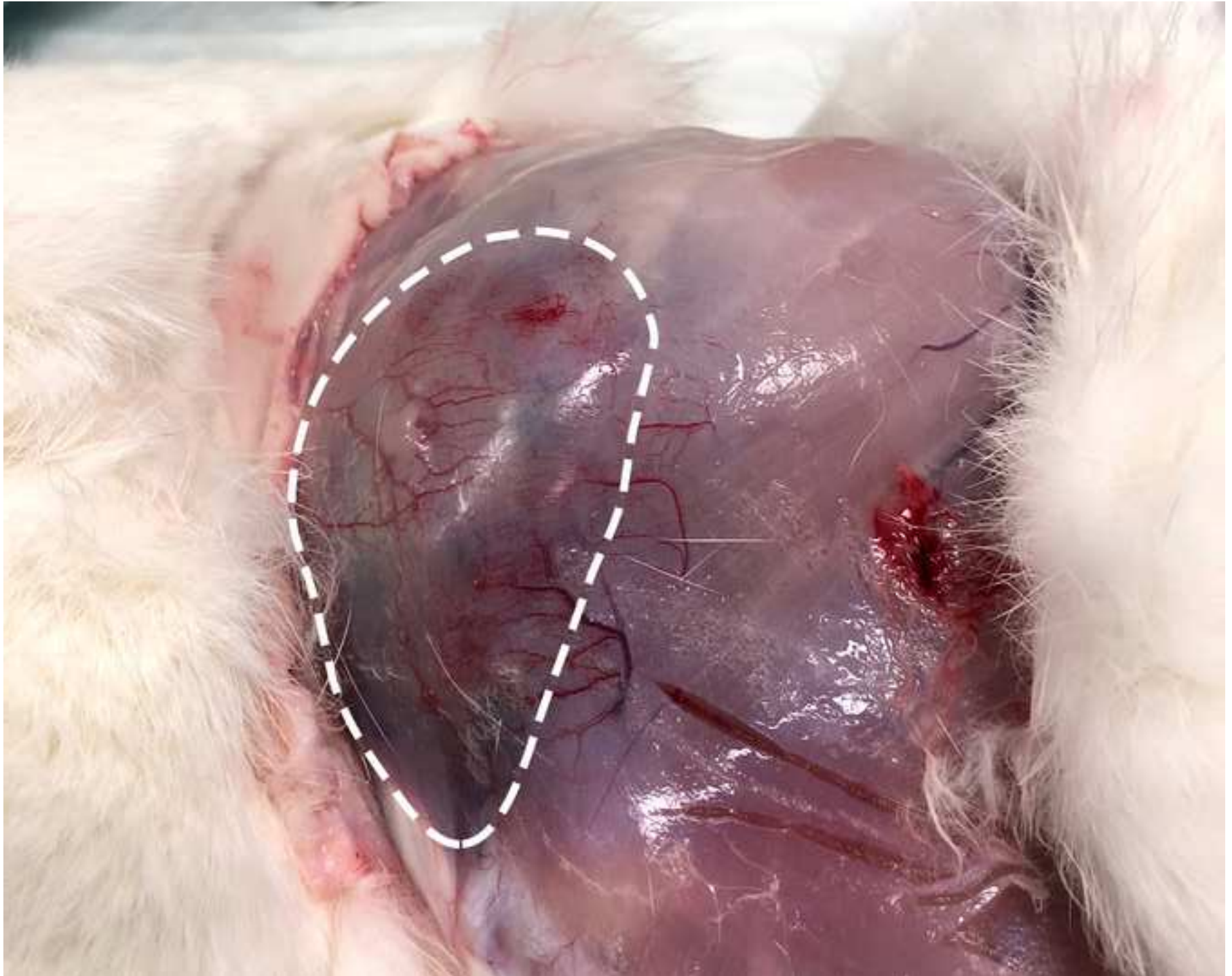REFERENCES:

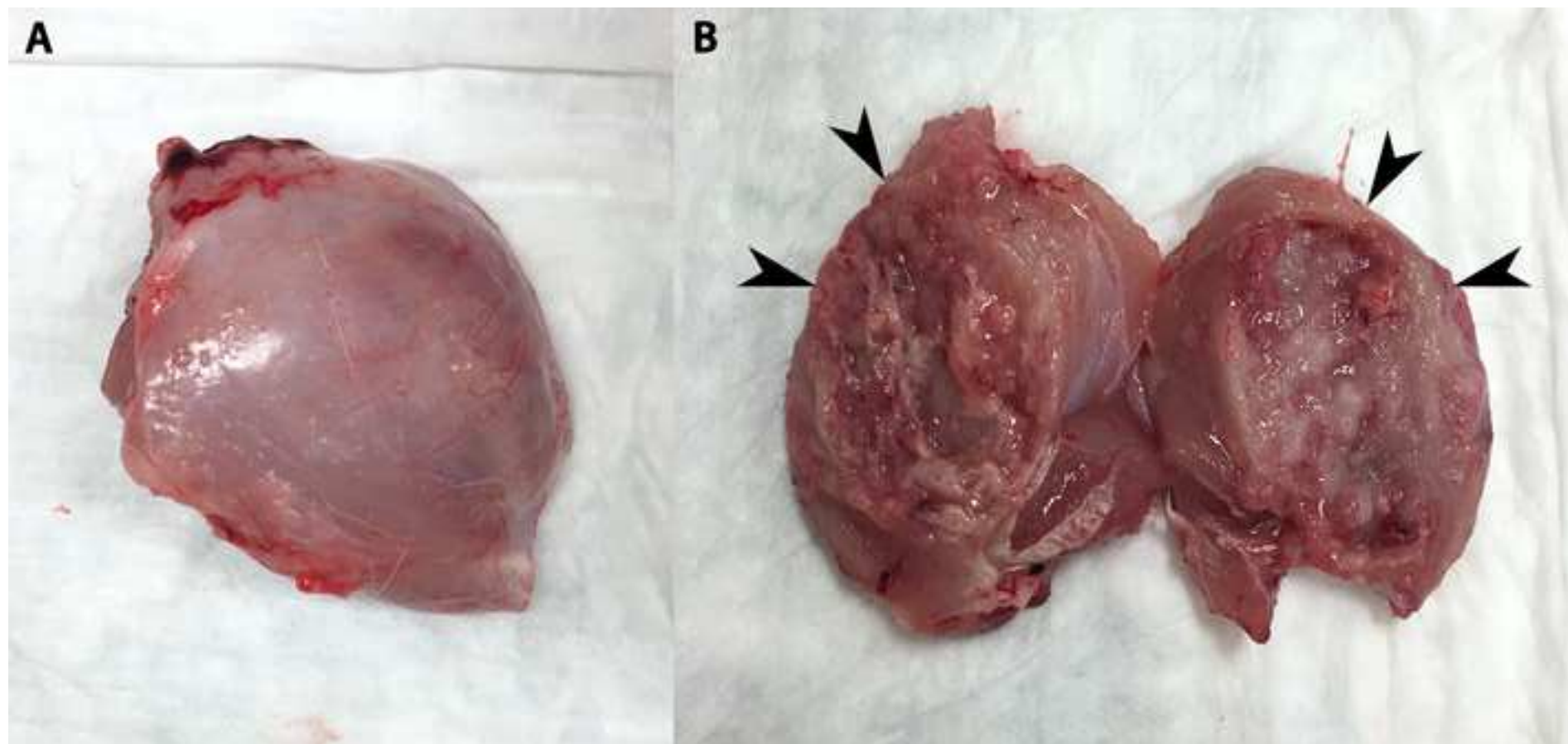
1. Rous, P., Beard, J.W. The Progression To Carcinoma of Virus-Induced Rabbit Papillomas (Shope). *The Journal of Experimental Medicine*. **62** (4), 523-548 (1935).

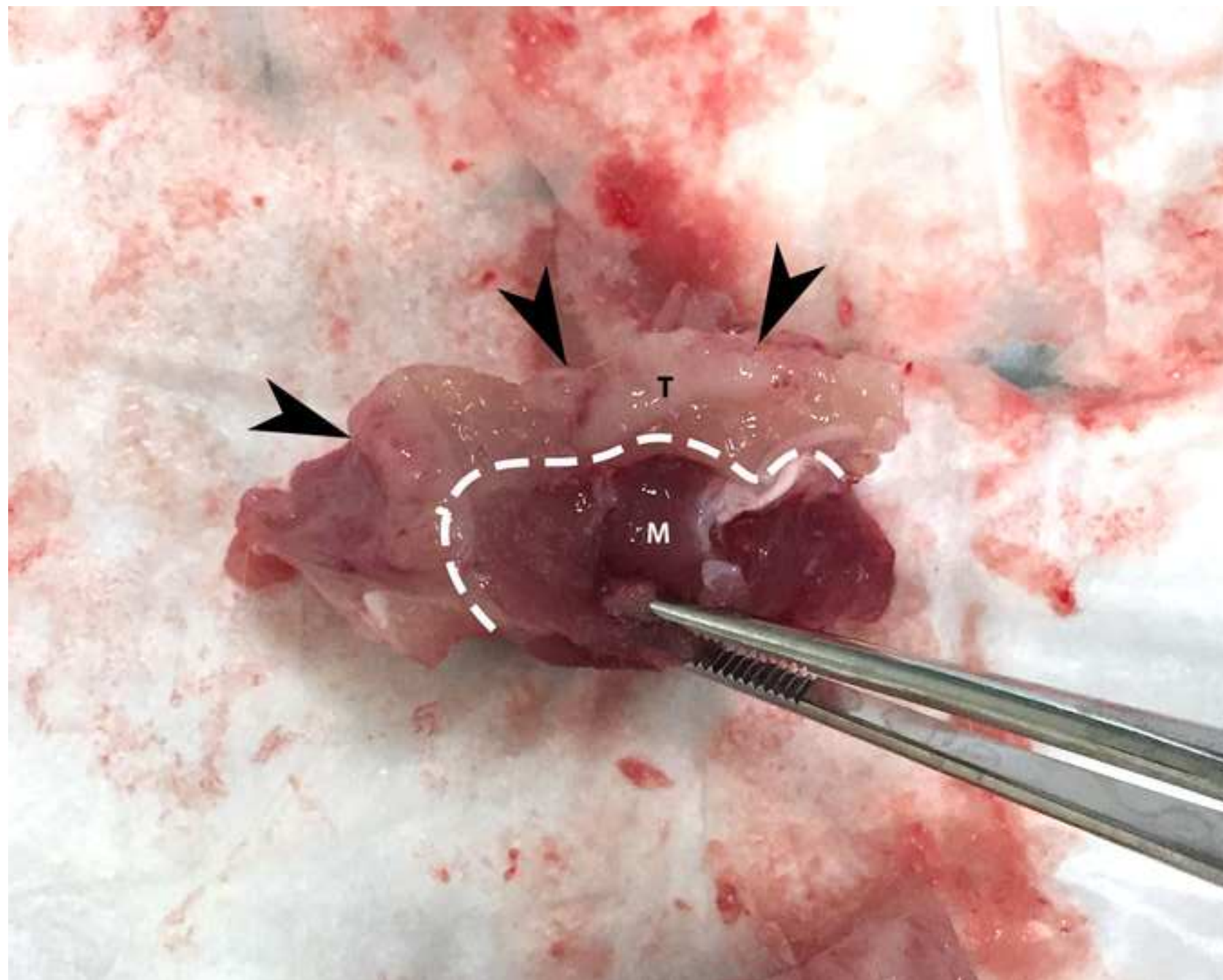
2. Kidd, J.G., Rous, P. A transplantable rabbit carcinoma originating in a virus-induced papilloma and containing the virus in masked or altered form. *The Journal of Experimental Medicine*. **71** (6), 813-838 (1940).
3. Galasko, C.S.B., Muckle, D.S. Intrasarcolemmal proliferation of the vx2 carcinoma. *British Journal of Cancer*. **29** (1), 59-65 (1974).
4. Maruyama, H. *et al.* Sonographic shift of hypervascular liver tumor on blood pool harmonic images with definity: Time-related changes of contrast-enhanced appearance in rabbit VX2 tumor under extra-low acoustic power. *European Journal of Radiology*. **56** (1), 60-65 (2005).
5. Horkan, C. *et al.* Radiofrequency Ablation: Effect of Pharmacologic Modulation of Hepatic and Renal Blood Flow on Coagulation Diameter in a VX2 Tumor Model. *Journal of Vascular and Interventional Radiology*. **15** (3), 269-274 (2004).
6. Bimonte, S. *et al.* Induction of VX2 para-renal carcinoma in rabbits: generation of animal model for loco-regional treatments of solid tumors. *Infectious Agents and Cancer*. **11** (1), 1-8 (2016).
7. Goldberg, S.N., Gazelle, G.S., Compton, C.C., Mueller, P.R., McCloud, T.C. Radio-frequency tissue ablation of VX2 tumor nodules in the rabbit lung. *Academic Radiology*. **3** (11), 929-935 (1996).
8. Rhee, T.K. *et al.* Rabbit VX2 Tumors as an Animal Model of Uterine Fibroids and for Uterine Artery Embolization. *Journal of Vascular and Interventional Radiology*. **18** (3), 411-418 (2007).
9. Parvinian, A., Casadaban, L.C., Gaba, R.C. Development, growth, propagation, and angiographic utilization of the rabbit VX2 model of liver cancer: A pictorial primer and "how to" guide. *Diagnostic and Interventional Radiology*. **20** (4), 335-340 (2014).
10. Xia, X. *et al.* Intra-arterial interleukin-12 gene delivery combined with chemoembolization: Anti-tumor effect in a rabbit hepatocellular carcinoma (HCC) model. *Acta Radiologica*. **54** (6), 684-689 (2013).
11. Gaba, R.C. *et al.* Ethiodized oil uptake does not predict doxorubicin drug delivery after chemoembolization in VX2 liver tumors. *Journal of Vascular and Interventional Radiology*. **23** (2), 265-273 (2012).
12. Choi, Y.H. *et al.* Novel Intraarterial Therapy for Liver Cancer Using Ethylbromopyruvate Dissolved in an Iodized Oil. *Academic Radiology*. **18** (4), 471-478 (2011).
13. Ma, H.L., Xu, Y.F., Qi, X.R., Maitani, Y., Nagai, T. Superparamagnetic iron oxide nanoparticles stabilized by alginate: Pharmacokinetics, tissue distribution, and applications in detecting liver cancers. *International Journal of Pharmaceutics*. **354** (1-2), 217-226 (2008).
14. Wang, D. *et al.* Liver tumors: Monitoring embolization in rabbits with VX2 tumors -

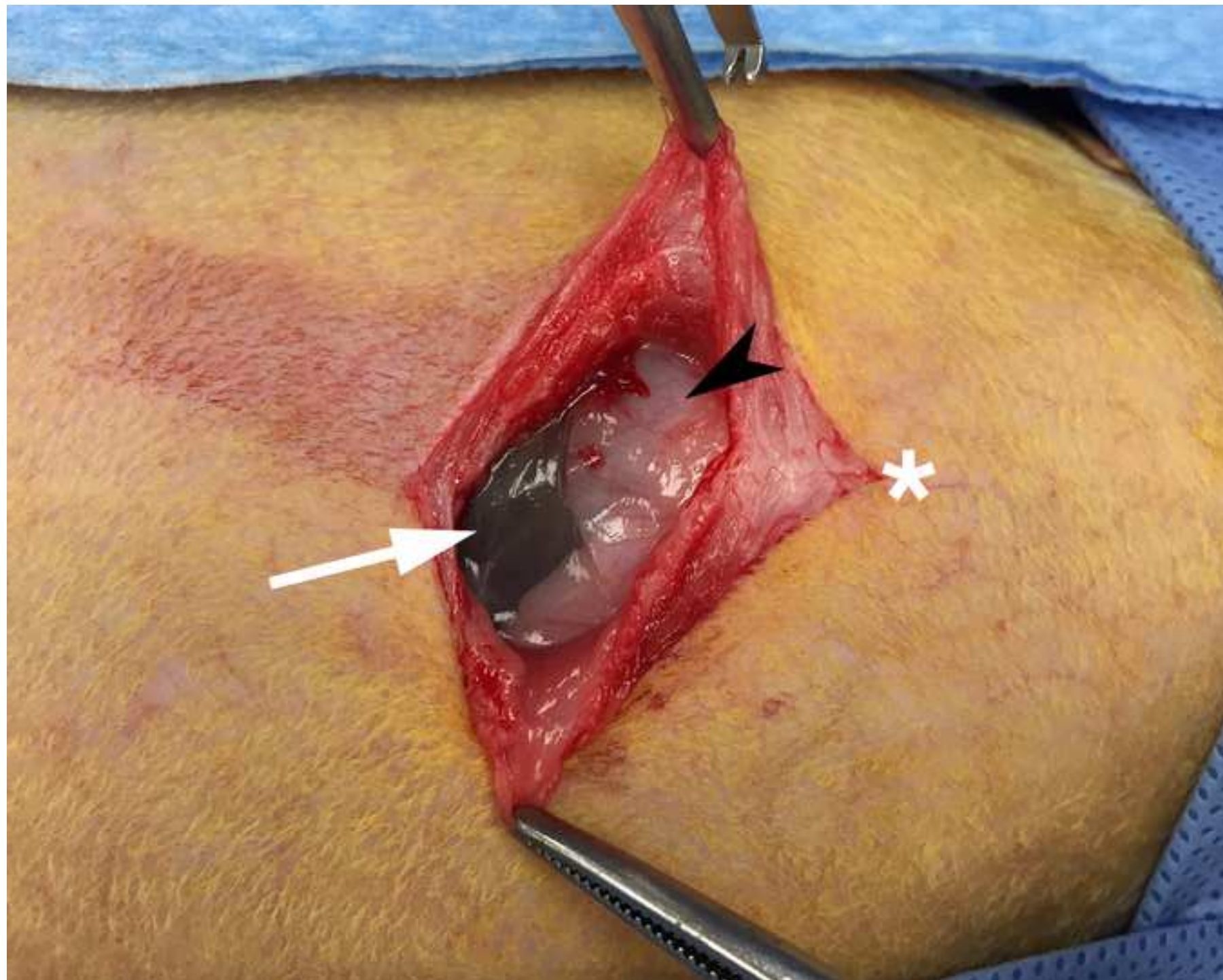
- Transcatheter intraarterial first-pass perfusion MR imaging. *Radiology*. **245** (1), 130-139 (2007).
15. Bimonte, S. *et al.* Radio-frequency ablation-based studies on VX2rabbit models for HCC treatment. *Infectious Agents and Cancer*. **11** (1) (2016).
16. Gaba, R., Obeid, M., Khabbaz, R., Garcia, K., Schachtschneider, K. Translational Animal Models for Liver Cancer. *American Journal of Interventional Radiology*. **2** (2), 1-8 (2018).
17. Kuszyk, B.S. *et al.* Local tumor recurrence following hepatic cryoablation: radiologic-histopathologic correlation in a rabbit model. *Radiology*. **217** (2), 477-486 (2000).
18. Geschwind, J. *et al.* Chemoembolization of Liver Tumor in a Rabbit Model : Assessment of Tumor Cell Death with Diffusion-Weighted MR Imaging and Histologic Analysis. *Journal of Vascular and Interventional Radiology*. **11** (10), 1245-1255 (2000).
19. Virmani, S. *et al.* Comparison of Two Different Methods for Inoculating VX2 Tumors in Rabbit Livers and Hind Limbs. *Journal of Vascular and Interventional Radiology*. **19** (6), 931-936 (2008).
20. Seldinger, S.I. Catheter replacement of the needle in percutaneous arteriography: A new technique. *Acta Radiologica*. **49** (SUPPL. 434), 47-52 (2008).
21. Schook, L.B. *et al.* A genetic porcine model of cancer. *PLoS One*. **10** (7), e0128864 (2015).

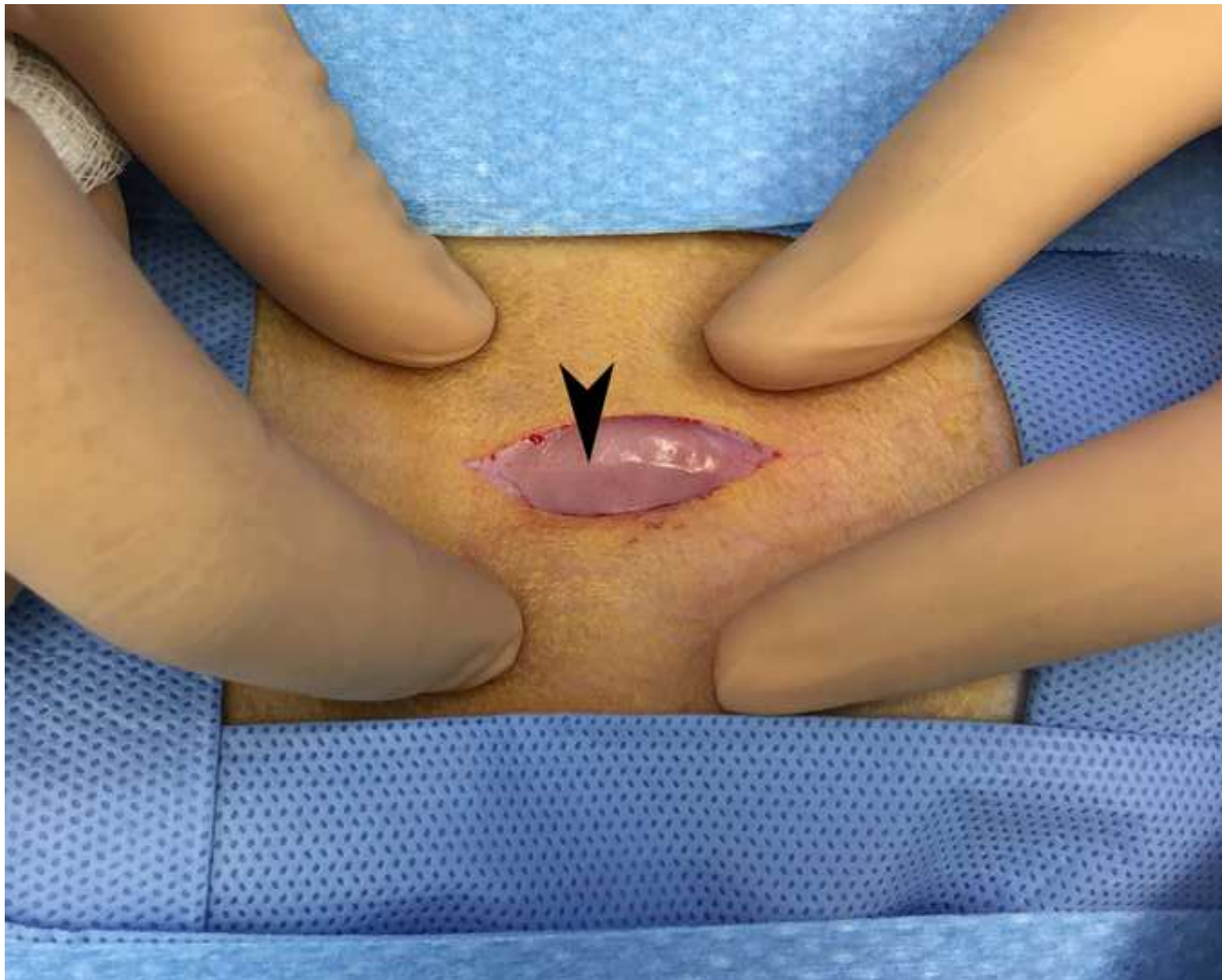


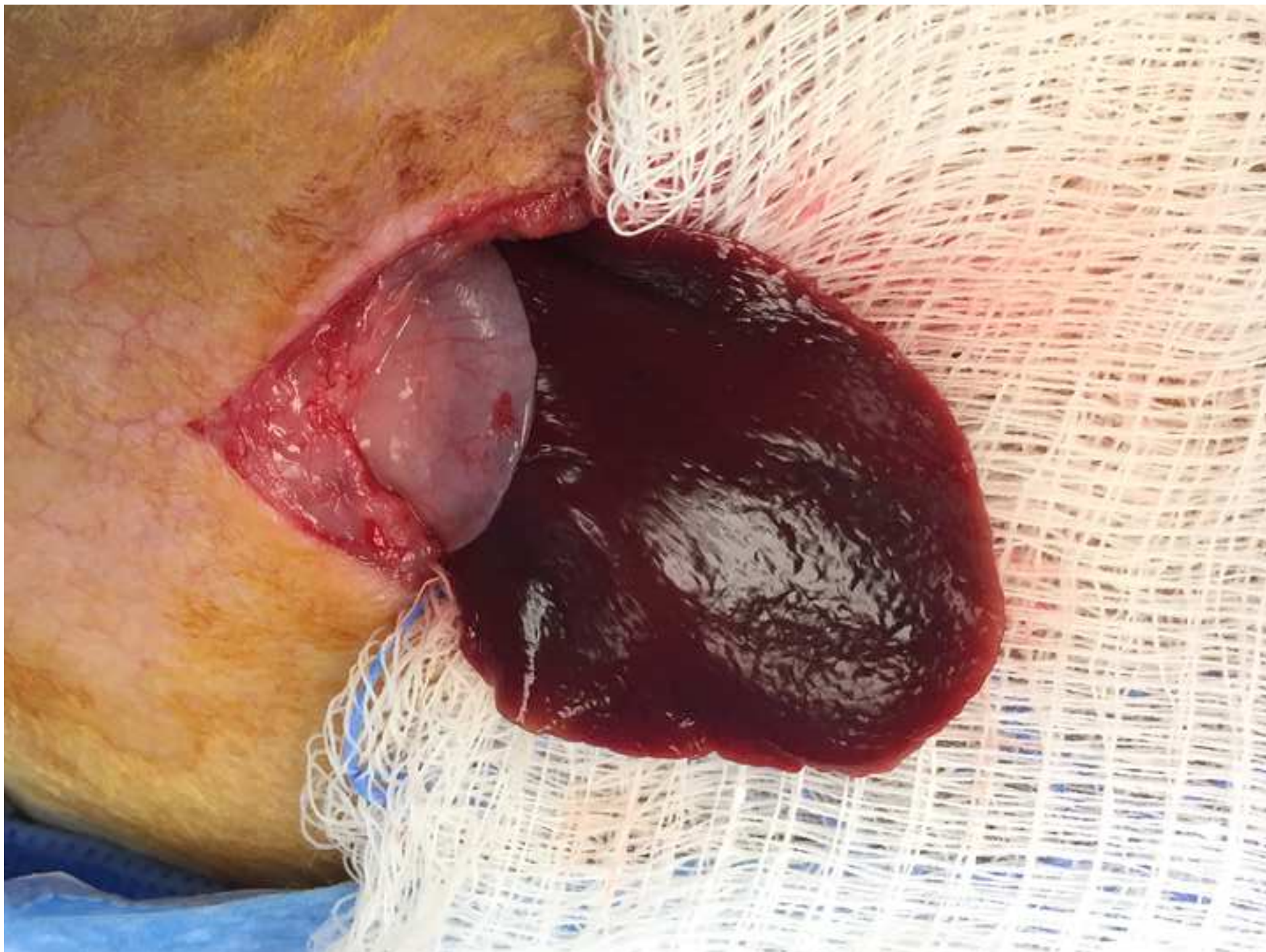

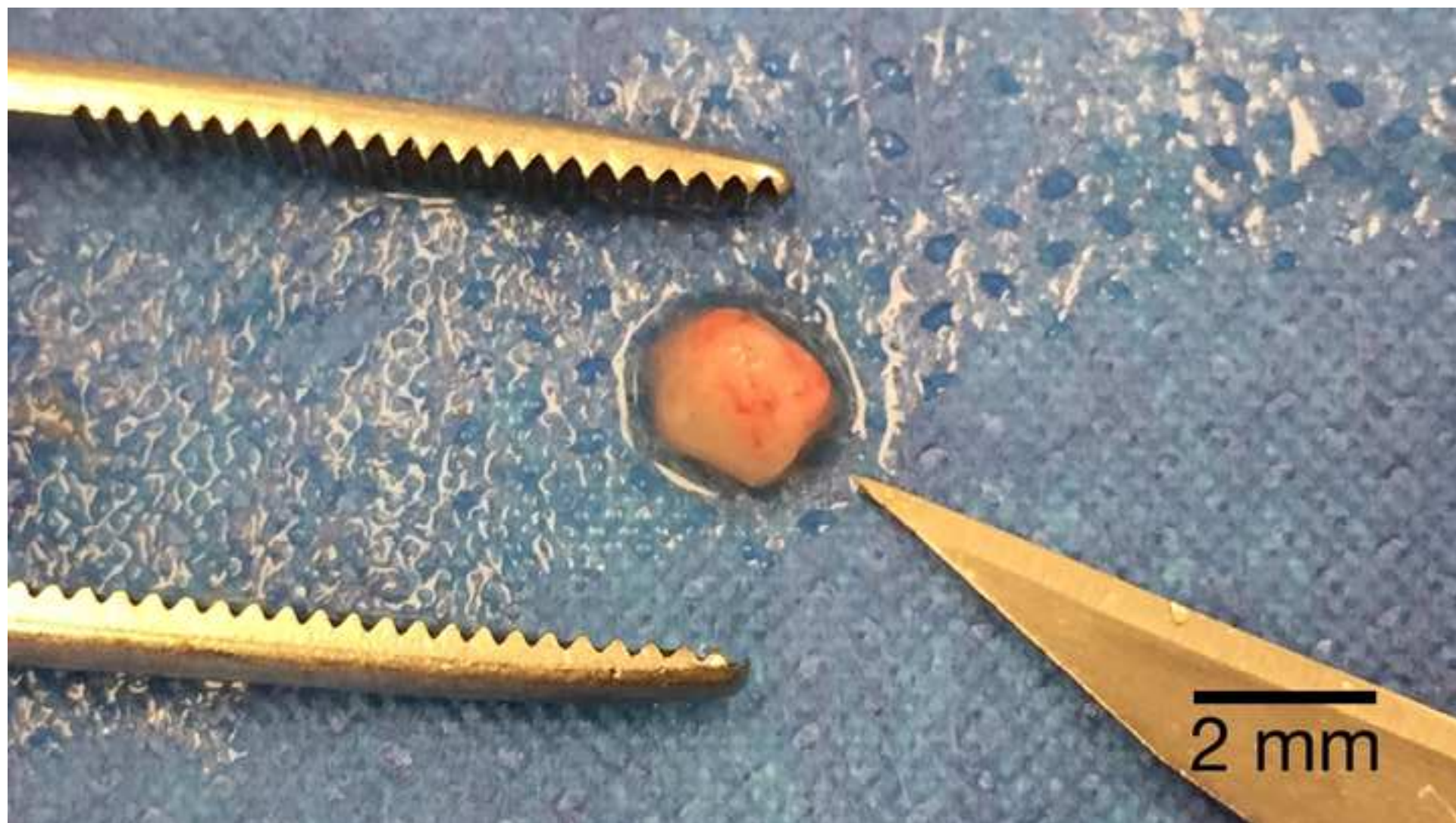



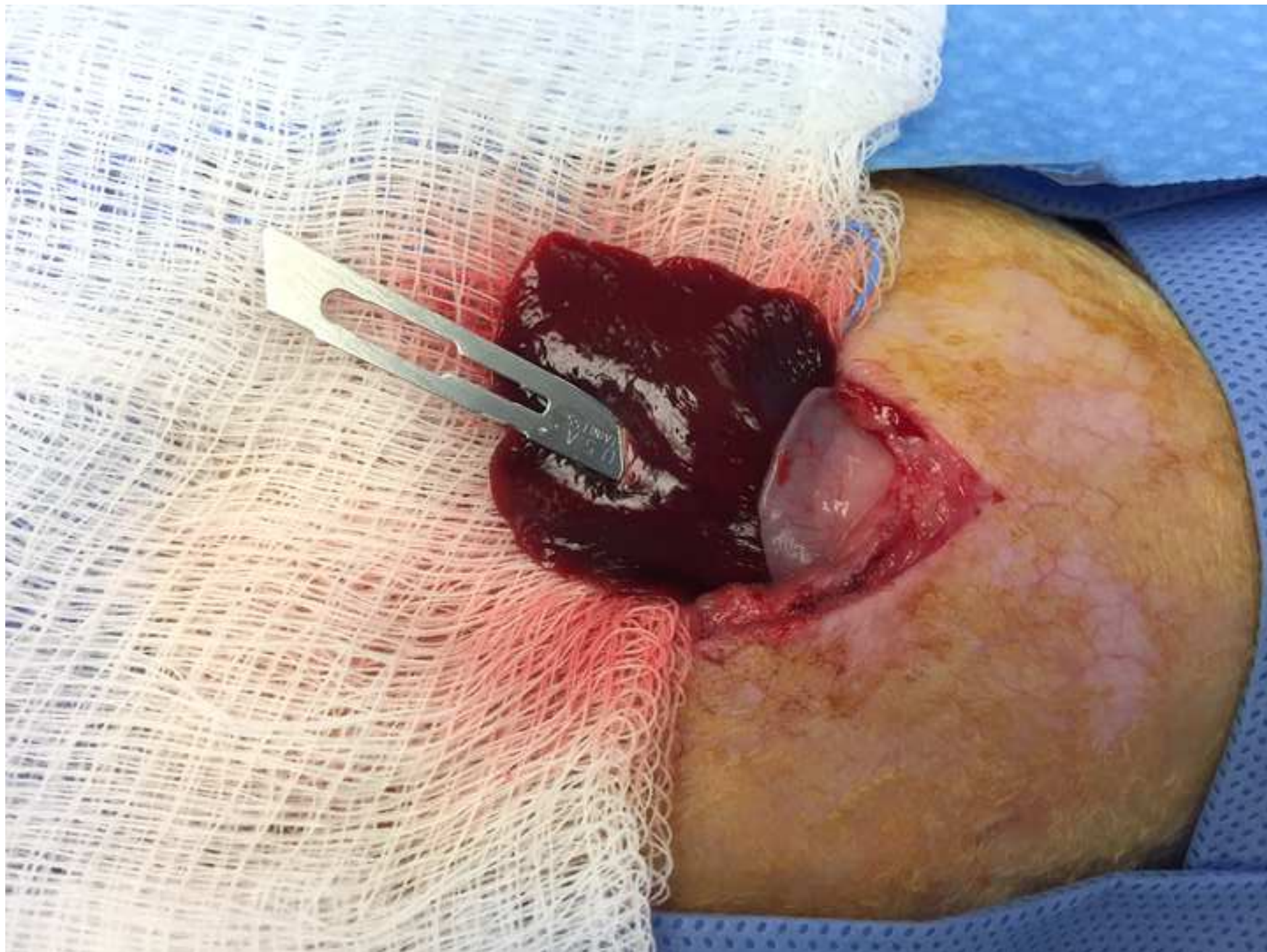
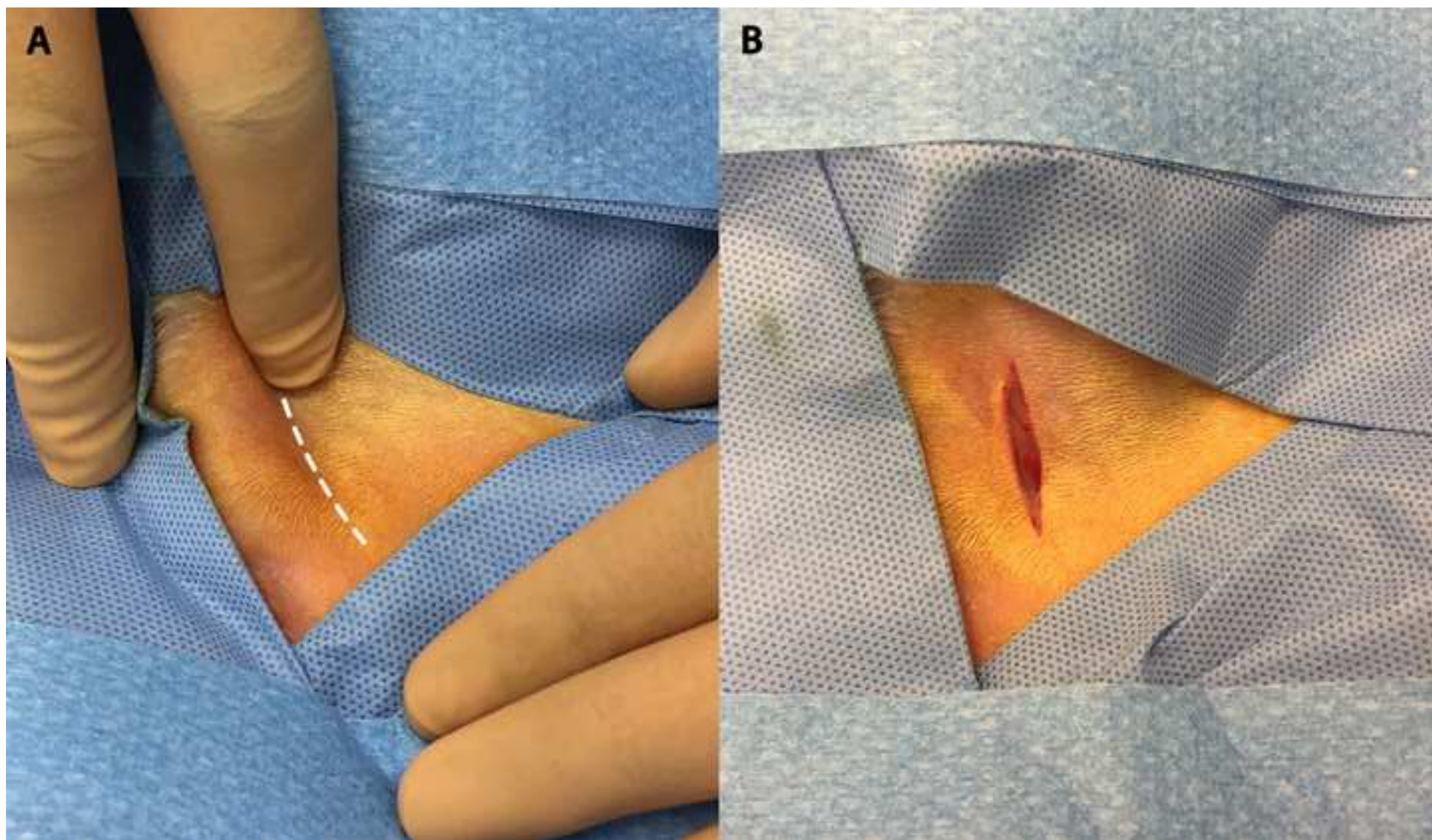


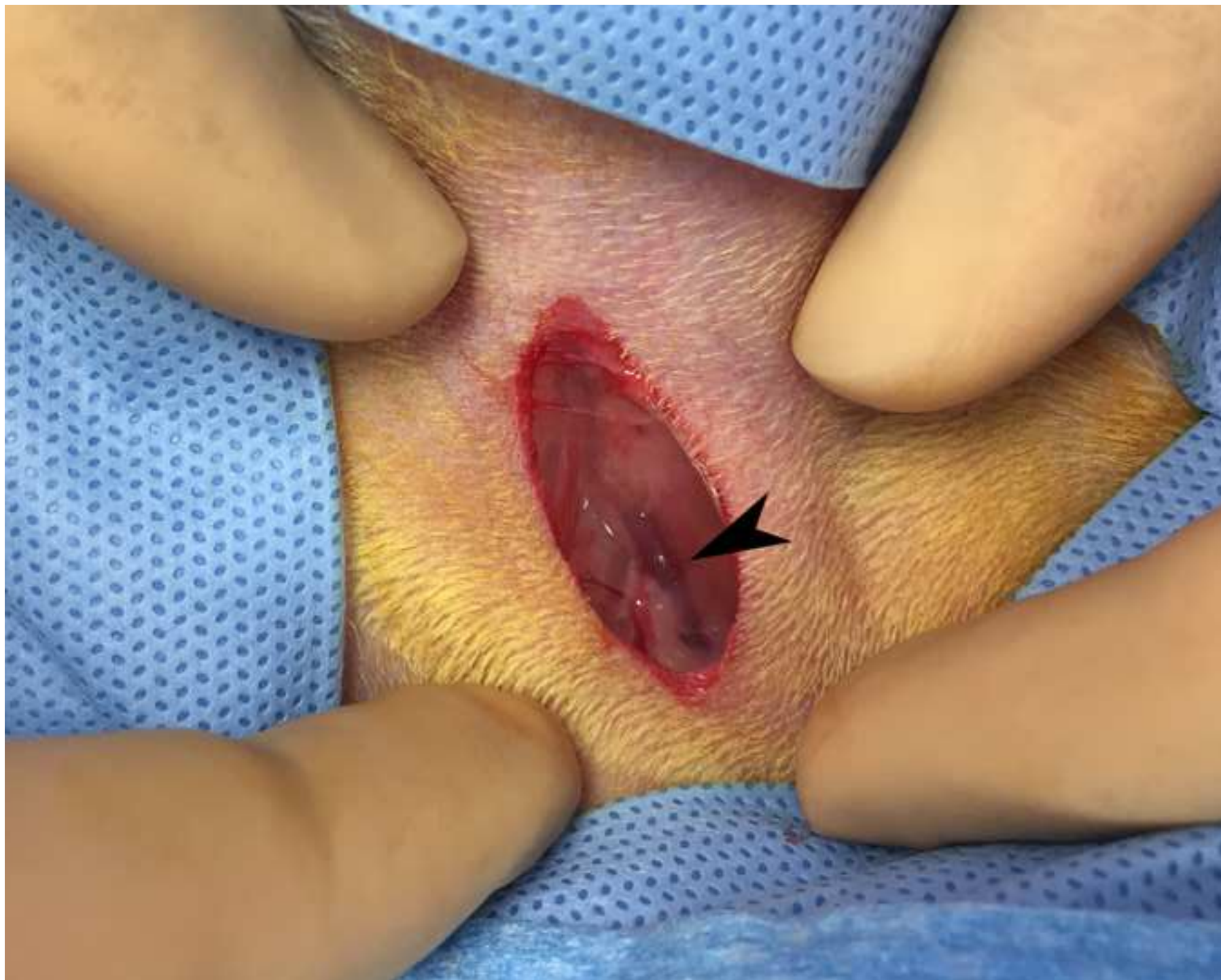


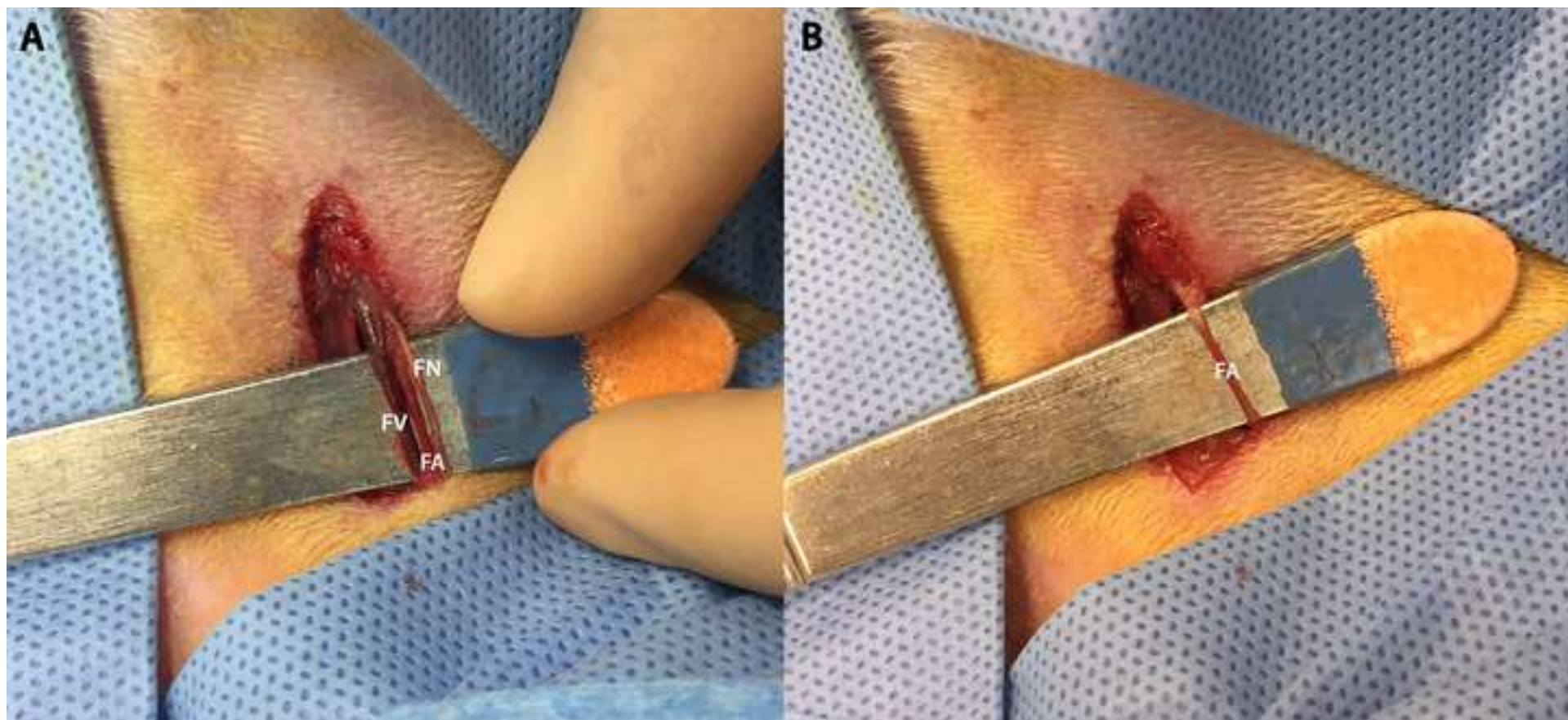


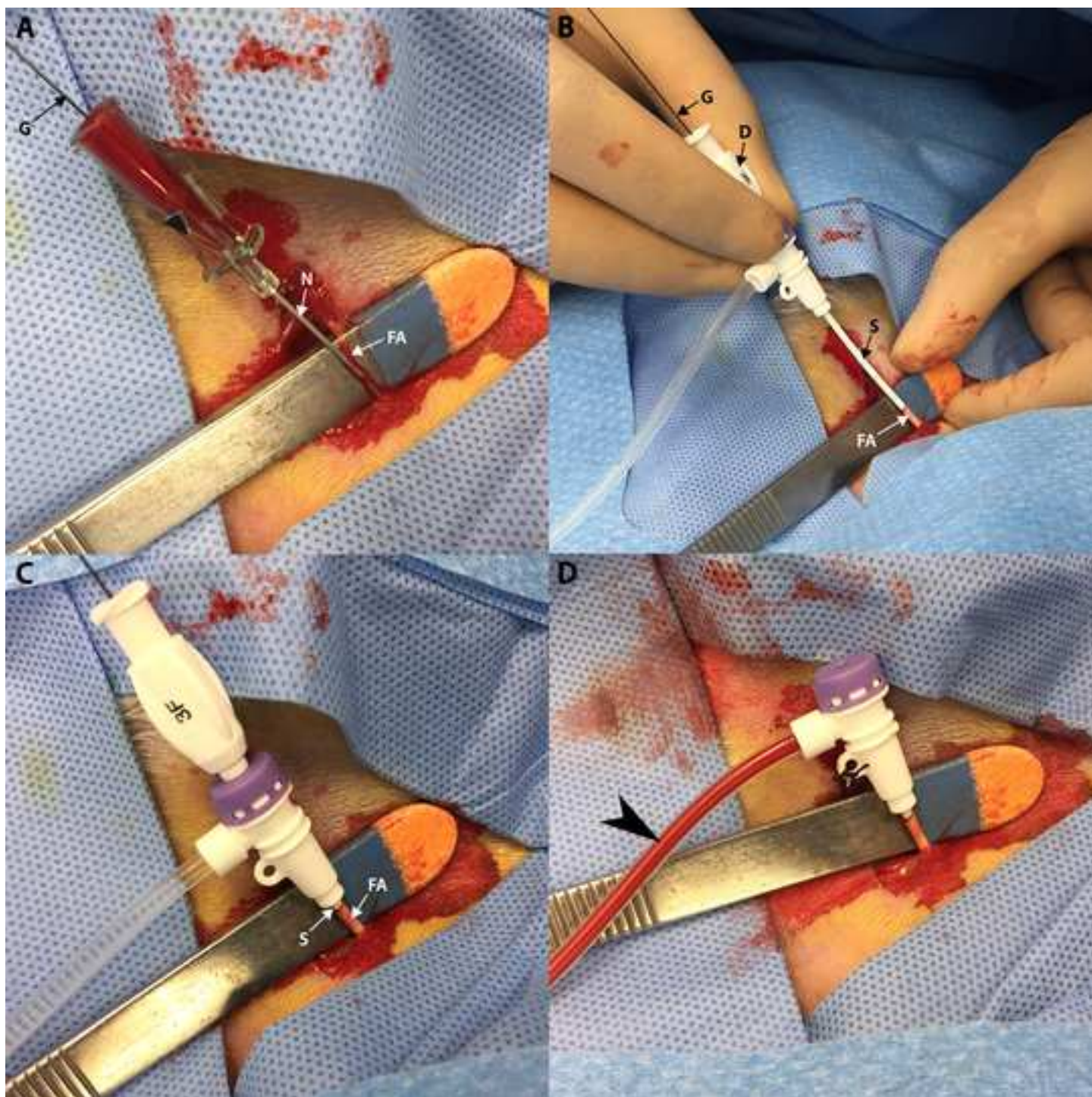


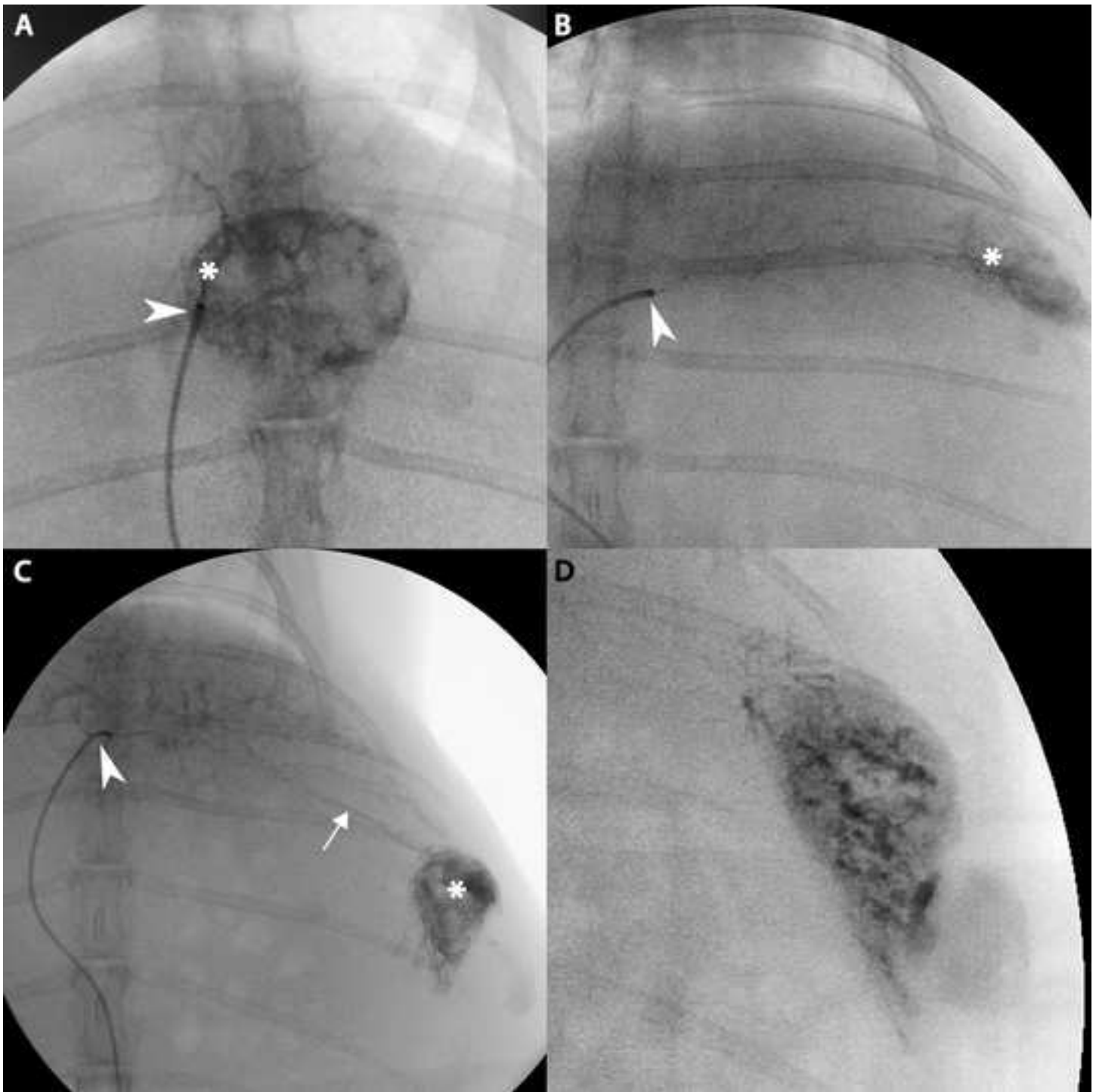


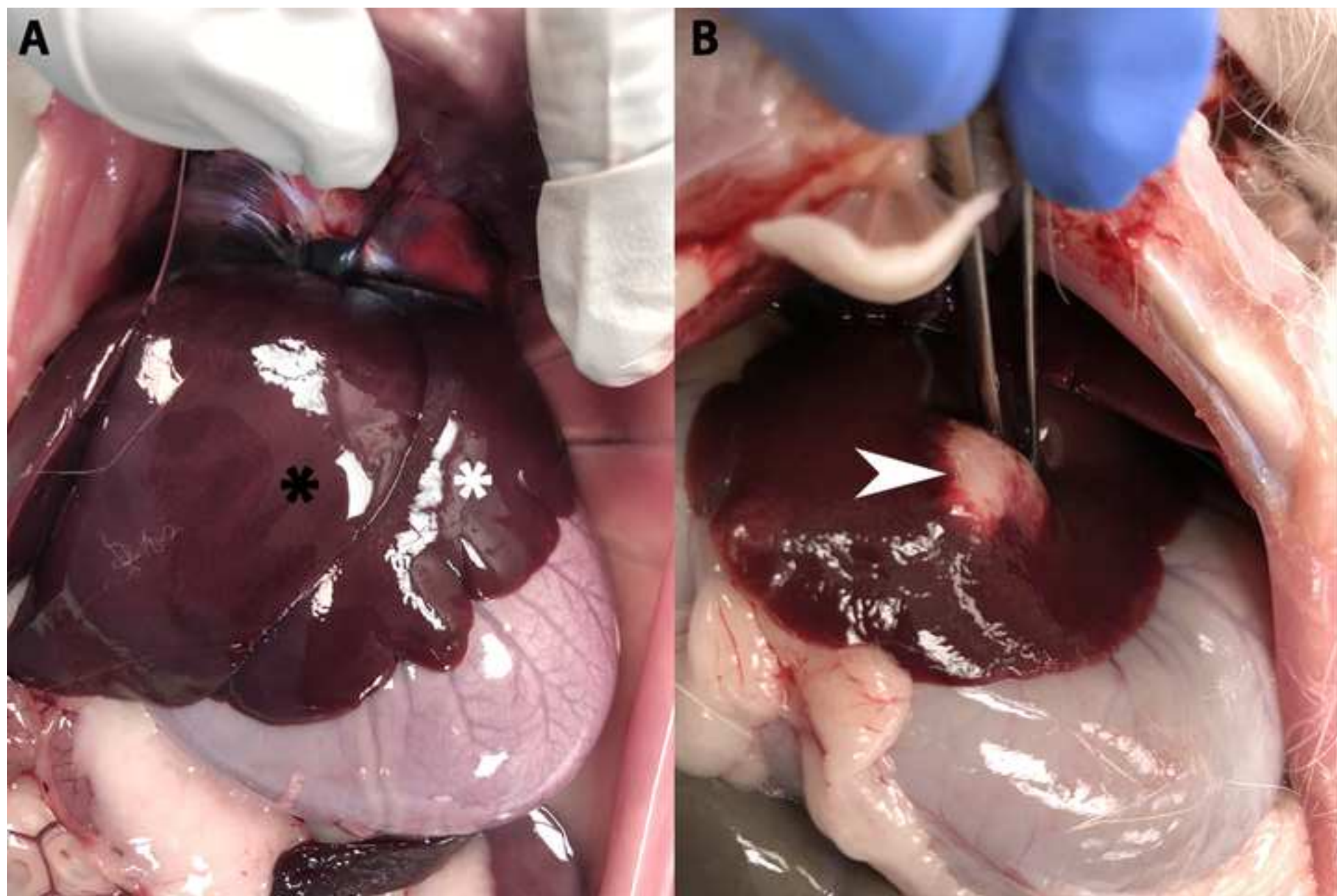












Name of Material/ Equipment	Company	Catalog Number	Comments/Description
MethoCult (Methycellulose)	Stemcell Technologies	M3134	
VX2 Cell Line	NCI	VX-2	
5 mL Syringe	BD	309646	
16-Gauge Needle	BD	305197	
22-Gauge Needle	BD	305155	
Hair Clippers	Wahl	41870-0438	
Foam Insulated Box	Mr. Box Online	10 x 10 x 4	
Acepromazine	Henry Schein	003845	
Buprenorphine	Par	42023-179-05	
Meloxicam	Henry Schein	049755	
Alcohol Pads	Covidien	5033	
Ketamine	Henry Schein	056344	
Xylazine	Akorn	59399-110-20	
Pentobarbital (Fatal-Plus)	Vortech	9373	
Sterile Petri Dish	Thermo Fisher	172931	
DMEM	Gibco	11965092	
Saline	Baxter	2F7124	
15-Blade	Steris	02-050-015	
Scalpel Handle x 2	Steris	22-2381	
Curved Hemostat	WPI	501288	
Atraumatic Forceps	Sklar	52-5077	
Gauze	Medline	NON21430LF	
11-Blade	Steris	02-050-011	
Surgicel	Ethicon	1951	
3-0 PDS / Taper	Ethicon	Z305H	
4 - 0 Vicryl / Cutting	Ethicon	J392H	
40 micron strainer	BD	352340	
50 mL conical tube	Thermo Fisher	339652	
plastic pipette	Thomas Scientific	HS206371B	
Centrifuge	Sorvall	75004240	

1.40mL Tubes (Internal Thread)	Micronic	MP32131-Z20
		Custom Order
3-F VSI Micro-HV Introducer Kit	Vascular Solutions	(P15180391)
.018 45-degree angle glidewire	Terumo	RG*GA1818SA
Direxion bern-shape		
microcatheter	Boston Scientific	M001195230
Omnipaque	GE	Y510



1 Alewife Center #200
Cambridge, MA 02140
tel. 617.945.9051
www.jove.com

ARTICLE AND VIDEO LICENSE AGREEMENT

Title of Article: From Start to Finish: A Guide for the Development and Angiographic Use of the Rabbit VX2 Model for Liver Cancer

Author(s): Ramzy C Khabbaz, Yu-Hui Huang, Alexandra A Smith, Kelly D Garcia, R Peter Lokken, Ron C Gaba

Item 1 (check one box): The Author elects to have the Materials be made available (as described at <http://www.jove.com/author>) via: ☒ Standard Access ☐ Open Access

Item 2 (check one box):

- ☒ The Author is NOT a United States government employee.
- ☐ The Author is a United States government employee and the Materials were prepared in the course of his or her duties as a United States government employee.
- ☐ The Author is a United States government employee but the Materials were NOT prepared in the course of his or her duties as a United States government employee.

ARTICLE AND VIDEO LICENSE AGREEMENT

1. **Defined Terms.** As used in this Article and Video License Agreement, the following terms shall have the following meanings: “**Agreement**” means this Article and Video License Agreement; “**Article**” means the article specified on the last page of this Agreement, including any associated materials such as texts, figures, tables, artwork, abstracts, or summaries contained therein; “**Author**” means the author who is a signatory to this Agreement; “**Collective Work**” means a work, such as a periodical issue, anthology or encyclopedia, in which the Materials in their entirety in unmodified form, along with a number of other contributions, constituting separate and independent works in themselves, are assembled into a collective whole; “**CRC License**” means the Creative Commons Attribution-Non Commercial-No Derivs 3.0 Unported Agreement, the terms and conditions of which can be found at: <http://creativecommons.org/licenses/by-nc-nd/3.0/legalcode>; “**Derivative Work**” means a work based upon the Materials or upon the Materials and other pre-existing works, such as a translation, musical arrangement, dramatization, fictionalization, motion picture version, sound recording, art reproduction, abridgment, condensation, or any other form in which the Materials may be recast, transformed, or adapted; “**Institution**” means the institution, listed on the last page of this Agreement, by which the Author was employed at the time of the creation of the Materials; “**JoVE**” means MyJoVE Corporation, a Massachusetts corporation and the publisher of *The Journal of Visualized Experiments*; “**Materials**” means the Article and / or the Video; “**Parties**” means the Author and JoVE; “**Video**” means any video(s) made by the Author, alone or in conjunction with any other parties, or by JoVE or its affiliates or agents, individually or in collaboration with the Author or any other parties, incorporating all or any portion of the Article, and in which the Author may or may not appear.

2. **Background.** The Author, who is the author of the Article, in order to ensure the dissemination and protection of the Article, desires to have the JoVE publish the Article and create and transmit videos based on the Article. In furtherance of such goals, the Parties desire to memorialize in this Agreement the respective rights of each Party in and to the Article and the Video.

3. **Grant of Rights in Article.** In consideration of JoVE agreeing to publish the Article, the Author hereby grants to JoVE, subject to **Sections 4** and **7** below, the exclusive, royalty-free, perpetual (for the full term of copyright in the Article, including any extensions thereto) license (a) to publish, reproduce, distribute, display and store the Article in all forms, formats and media whether now known or hereafter developed (including without limitation in print, digital and electronic form) throughout the world, (b) to translate the Article into other languages, create adaptations, summaries or extracts of the Article or other Derivative Works (including, without limitation, the Video) or Collective Works based on all or any portion of the Article and exercise all of the rights set forth in (a) above in such translations, adaptations, summaries, extracts, Derivative Works or Collective Works and (c) to license others to do any or all of the above. The foregoing rights may be exercised in all media and formats, whether now known or hereafter devised, and include the right to make such modifications as are technically necessary to exercise the rights in other media and formats. If the “Open Access” box has been checked in **Item 1** above, JoVE and the Author hereby grant to the public all such rights in the Article as provided in, but subject to all limitations and requirements set forth in, the CRC License.

ARTICLE AND VIDEO LICENSE AGREEMENT

4. Retention of Rights in Article. Notwithstanding the exclusive license granted to JoVE in **Section 3** above, the Author shall, with respect to the Article, retain the non-exclusive right to use all or part of the Article for the non-commercial purpose of giving lectures, presentations or teaching classes, and to post a copy of the Article on the Institution's website or the Author's personal website, in each case provided that a link to the Article on the JoVE website is provided and notice of JoVE's copyright in the Article is included. All non-copyright intellectual property rights in and to the Article, such as patent rights, shall remain with the Author.

5. Grant of Rights in Video – Standard Access. This **Section 5** applies if the "Standard Access" box has been checked in **Item 1** above or if no box has been checked in **Item 1** above. In consideration of JoVE agreeing to produce, display or otherwise assist with the Video, the Author hereby acknowledges and agrees that, Subject to **Section 7** below, JoVE is and shall be the sole and exclusive owner of all rights of any nature, including, without limitation, all copyrights, in and to the Video. To the extent that, by law, the Author is deemed, now or at any time in the future, to have any rights of any nature in or to the Video, the Author hereby disclaims all such rights and transfers all such rights to JoVE.

6. Grant of Rights in Video – Open Access. This **Section 6** applies only if the "Open Access" box has been checked in **Item 1** above. In consideration of JoVE agreeing to produce, display or otherwise assist with the Video, the Author hereby grants to JoVE, subject to **Section 7** below, the exclusive, royalty-free, perpetual (for the full term of copyright in the Article, including any extensions thereto) license (a) to publish, reproduce, distribute, display and store the Video in all forms, formats and media whether now known or hereafter developed (including without limitation in print, digital and electronic form) throughout the world, (b) to translate the Video into other languages, create adaptations, summaries or extracts of the Video or other Derivative Works or Collective Works based on all or any portion of the Video and exercise all of the rights set forth in (a) above in such translations, adaptations, summaries, extracts, Derivative Works or Collective Works and (c) to license others to do any or all of the above. The foregoing rights may be exercised in all media and formats, whether now known or hereafter devised, and include the right to make such modifications as are technically necessary to exercise the rights in other media and formats. For any Video to which this Section 6 is applicable, JoVE and the Author hereby grant to the public all such rights in the Video as provided in, but subject to all limitations and requirements set forth in, the CRC License.

7. Government Employees. If the Author is a United States government employee and the Article was prepared in the course of his or her duties as a United States government employee, as indicated in **Item 2** above, and any of the licenses or grants granted by the Author hereunder exceed the scope of the 17 U.S.C. 403, then the rights granted hereunder shall be limited to the maximum rights permitted under such

statute. In such case, all provisions contained herein that are not in conflict with such statute shall remain in full force and effect, and all provisions contained herein that do so conflict shall be deemed to be amended so as to provide to JoVE the maximum rights permissible within such statute.

8. Likeness, Privacy, Personality. The Author hereby grants JoVE the right to use the Author's name, voice, likeness, picture, photograph, image, biography and performance in any way, commercial or otherwise, in connection with the Materials and the sale, promotion and distribution thereof. The Author hereby waives any and all rights he or she may have, relating to his or her appearance in the Video or otherwise relating to the Materials, under all applicable privacy, likeness, personality or similar laws.

9. Author Warranties. The Author represents and warrants that the Article is original, that it has not been published, that the copyright interest is owned by the Author (or, if more than one author is listed at the beginning of this Agreement, by such authors collectively) and has not been assigned, licensed, or otherwise transferred to any other party. The Author represents and warrants that the author(s) listed at the top of this Agreement are the only authors of the Materials. If more than one author is listed at the top of this Agreement and if any such author has not entered into a separate Article and Video License Agreement with JoVE relating to the Materials, the Author represents and warrants that the Author has been authorized by each of the other such authors to execute this Agreement on his or her behalf and to bind him or her with respect to the terms of this Agreement as if each of them had been a party hereto as an Author. The Author warrants that the use, reproduction, distribution, public or private performance or display, and/or modification of all or any portion of the Materials does not and will not violate, infringe and/or misappropriate the patent, trademark, intellectual property or other rights of any third party. The Author represents and warrants that it has and will continue to comply with all government, institutional and other regulations, including, without limitation all institutional, laboratory, hospital, ethical, human and animal treatment, privacy, and all other rules, regulations, laws, procedures or guidelines, applicable to the Materials, and that all research involving human and animal subjects has been approved by the Author's relevant institutional review board.

10. JoVE Discretion. If the Author requests the assistance of JoVE in producing the Video in the Author's facility, the Author shall ensure that the presence of JoVE employees, agents or independent contractors is in accordance with the relevant regulations of the Author's institution. If more than one author is listed at the beginning of this Agreement, JoVE may, in its sole discretion, elect not take any action with respect to the Article until such time as it has received complete, executed Article and Video License Agreements from each such author. JoVE reserves the right, in its absolute and sole discretion and without giving any reason therefore, to accept or decline any work submitted to JoVE. JoVE and its employees, agents and independent contractors shall have

ARTICLE AND VIDEO LICENSE AGREEMENT

full, unfettered access to the facilities of the Author or of the Author's institution as necessary to make the Video, whether actually published or not. JoVE has sole discretion as to the method of making and publishing the Materials, including, without limitation, to all decisions regarding editing, lighting, filming, timing of publication, if any, length, quality, content and the like.

11. **Indemnification.** The Author agrees to indemnify JoVE and/or its successors and assigns from and against any and all claims, costs, and expenses, including attorney's fees, arising out of any breach of any warranty or other representations contained herein. The Author further agrees to indemnify and hold harmless JoVE from and against any and all claims, costs, and expenses, including attorney's fees, resulting from the breach by the Author of any representation or warranty contained herein or from allegations or instances of violation of intellectual property rights, damage to the Author's or the Author's institution's facilities, fraud, libel, defamation, research, equipment, experiments, property damage, personal injury, violations of institutional, laboratory, hospital, ethical, human and animal treatment, privacy or other rules, regulations, laws, procedures or guidelines, liabilities and other losses or damages related in any way to the submission of work to JoVE, making of videos by JoVE, or publication in JoVE or elsewhere by JoVE. The Author shall be responsible for, and shall hold JoVE harmless from, damages caused by lack of sterilization, lack of cleanliness or by contamination due to the making of a video by JoVE its employees, agents or independent contractors. All sterilization, cleanliness or decontamination procedures shall be solely the responsibility of the Author and shall be undertaken at the Author's

expense. All indemnifications provided herein shall include JoVE's attorney's fees and costs related to said losses or damages. Such indemnification and holding harmless shall include such losses or damages incurred by, or in connection with, acts or omissions of JoVE, its employees, agents or independent contractors.

12. **Fees.** To cover the cost incurred for publication, JoVE must receive payment before production and publication the Materials. Payment is due in 21 days of invoice. Should the Materials not be published due to an editorial or production decision, these funds will be returned to the Author. Withdrawal by the Author of any submitted Materials after final peer review approval will result in a US\$1,200 fee to cover pre-production expenses incurred by JoVE. If payment is not received by the completion of filming, production and publication of the Materials will be suspended until payment is received.

13. **Transfer, Governing Law.** This Agreement may be assigned by JoVE and shall inure to the benefits of any of JoVE's successors and assignees. This Agreement shall be governed and construed by the internal laws of the Commonwealth of Massachusetts without giving effect to any conflict of law provision thereunder. This Agreement may be executed in counterparts, each of which shall be deemed an original, but all of which together shall be deemed to be one and the same agreement. A signed copy of this Agreement delivered by facsimile, e-mail or other means of electronic transmission shall be deemed to have the same legal effect as delivery of an original signed copy of this Agreement.

A signed copy of this document must be sent with all new submissions. Only one Agreement required per submission.

CORRESPONDING AUTHOR:

Name:	<input type="text" value="Ron C Gaba"/>	
Department:	<input type="text" value="Radiology"/>	
Institution:	<input type="text" value="University of Illinois"/>	
Article Title:	<input type="text" value="From Start to Finish: A Guide for the Development and Angiographic Use of the Rabbit VX2 Model for Liver Cancer"/>	
Signature:	<input type="text" value="Ron Gaba"/>	Date: <input type="text"/>

Ron Gaba
Ron Gaba (Jun 6, 2018)

Please submit a signed and dated copy of this license by one of the following three methods:

- 1) Upload a scanned copy of the document as a pdf on the JoVE submission site;
- 2) Fax the document to +1.866.381.2236;
- 3) Mail the document to JoVE / Attn: JoVE Editorial / 1 Alewife Center #200 / Cambridge, MA 02139

For questions, please email submissions@jove.com or call +1.617.945.9051

Dear Journal of Visualized Experiments editorial office,

This letter accompanies submission of a revised version of the manuscript JoVE58600 entitled, "From Start to Finish: A Guide for the Development and Angiographic Use of the Rabbit VX2 Model for Liver Cancer." We thank the reviewers for their careful appraisal and suggested revisions, which have resulted in a strengthened manuscript. Responses to specific requested revisions are listed below, addressed after each reviewer comment. Also, please note that both an annotated and clean revision of the paper has been resubmitted.

Editorial Comments:

- Please take this opportunity to thoroughly proofread the manuscript to ensure that there are no spelling or grammatical errors.

RESPONSE: We have reviewed the manuscript as suggested.

- Please include an ethics statement before your numbered protocol steps indicating that the protocol follows the animal care guidelines of your institution.

RESPONSE: An ethics statement has been added, as requested (line 68-69, Ethics Statement: "The following protocol follows all requirements and guidelines mandated by the University of Illinois - Chicago. It was reviewed and approved by IACUC prior to execution."

- Protocol Detail: Please note that your protocol will be used to generate the script for the video, and must contain everything that you would like shown in the video (e.g. all surgical tools and actions need to be mentioned, oxygen flow rate, dosages etc.). Please ensure you answer the "how" question, i.e., how is the step performed? Alternatively, for steps that will not be filmed, add references to published material specifying how to perform the protocol action. There should be enough detail in each step to supplement the actions seen in the video so that viewers can easily replicate the protocol.

RESPONSE: We have reviewed the manuscript as suggested.

- Protocol Highlight: Please highlight ~2.5 pages or less of text (which includes headings and spaces) in yellow, to identify which steps should be visualized to tell the most cohesive story of your protocol steps.

1) The highlighting must include all relevant details that are required to perform the step. For example, if step 2.5 is highlighted for filming and the details of how to perform the step are given in steps 2.5.1 and 2.5.2, then the sub-steps where the details are provided must be included in the highlighting.

2) Some of your shorter protocol steps can be combined so that individual steps contain 2-3 actions and maximum of 4 sentences per step.

3) The highlighted steps should form a cohesive narrative, that is, there must be a logical flow from one highlighted step to the next.

4) Please highlight complete sentences (not parts of sentences). Include sub-headings and spaces when calculating the final highlighted length.

5) Notes cannot be filmed and should be excluded from highlighting.

6) Please bear in mind that anesthesia/euthanasia will not be filmed and should not be highlighted.

RESPONSE: Tumor Implantation and fluoroscopy have been highlighted.

- Discussion: JoVE articles are focused on the methods and the protocol, thus the discussion should be similarly focused. Please ensure that the discussion covers the following in detail:

modifications and troubleshooting, limitations of the technique, significance with respect to existing methods, future applications and critical steps within the protocol.

RESPONSE: We have reviewed the manuscript as suggested.

- Figures:

- 1) Please number your figures 1, 2, 3 etc and avoid the current hyphenated number scheme.
- 2) Please ensure that figures are called outs at appropriate locations in text.
- 3) Please add scale references to all figures where relevant.

RESPONSE: All figures were renumbered. Scale was added where relevant.

- Please define all abbreviations at first use.

RESPONSE: We have reviewed the manuscript as suggested.

- Please use standard abbreviations and symbols for SI Units such as μL , mL, L, etc., and abbreviations for non-SI units such as h, min, s for time units. Please use a single space between the numerical value and unit.

RESPONSE: We have reviewed the manuscript as suggested.

- If your figures and tables are original and not published previously or you have already obtained figure permissions, please ignore this comment. If you are re-using figures from a previous publication, you must obtain explicit permission to re-use the figure from the previous publisher (this can be in the form of a letter from an editor or a link to the editorial policies that allows you to re-publish the figure). Please upload the text of the re-print permission (may be copied and pasted from an email/website) as a Word document to the Editorial Manager site in the "Supplemental files (as requested by JoVE)" section. Please also cite the figure appropriately in the figure legend, i.e. "This figure has been modified from [citation]."

RESPONSE: No figures or tables from previous publications were used.

Comments from Peer-Reviewers:

Reviewer #1:

Manuscript Summary:

The description of VX2 model in rabbit is in detail and would be useful for the experiment of other, so it was interesting.

Minor Concerns:

1. In line 84, cause the hair of rabbit was not easy to shave, so do you have better method to do this? If you have some trick, please add it into the manuscript.

RESPONSE: The following has been added to the manuscript: "Note: Rabbit fur is difficult to shave. It is recommended that the researcher perform multiple passes, first focusing on clearing a bulk of the fur and then pressing the clippers against the skin and going against the grain."

2. In line 204, the volume or size of tumor piece should be clear in here.

RESPONSE: Placed a size estimate in the line in question. Now in line 213.

Reviewer #2:

Manuscript Summary:

The Manuscript is well-structured and describes the methods for the development of VX2 rabbit liver model and its use for the study on liver cancer.

Major Concerns:

None

Minor Concerns:

The bibliography needs to be improved.

Please add:

1) Induction of VX2 para-renal carcinoma in rabbits: generation of animal model for loco-regional treatments of solid tumors.

Bimonte S, et al. Infect Agent Cancer. 2016.

Authors

Bimonte S, Leongito M, Piccirillo M, Tamma ML, Vallifuoco M, Bracco A, Mancini A, Di Napoli D, Castaldo S, Cozzolino S, Iacobellis F, Grassi R, Granata V, Lastoria S, Curley S, Izzo F

1) Radio-frequency ablation-based studies on VX2 rabbit models for HCC treatment.

Bimonte S, Leongito M, Piccirillo M, de Angelis C, Pivonello C, Granata V, Izzo F.

RESPONSE: As requested, added citations to paper in lines 49 and 55.