

# Journal of Visualized Experiments

## Laparoscopic Intracapsular Rotary-cut Procedure, a modified myomectomy procedure facilitating fertility preservation --Manuscript Draft--

<b>Article Type:</b>	Invited Methods Article - JoVE Produced Video
<b>Manuscript Number:</b>	JoVE58410R3
<b>Full Title:</b>	Laparoscopic Intracapsular Rotary-cut Procedure, a modified myomectomy procedure facilitating fertility preservation
<b>Keywords:</b>	uterine fibroid; pseudo-capsule; laparoscopic myomectomy; Intracapsular Rotary-cut Procedure (IRCP); fertility preservation
<b>Corresponding Author:</b>	Wu Ruifang, MD Peking University Shenzhen Hospital Shenzhen, Guangdong CHINA
<b>Corresponding Author's Institution:</b>	Peking University Shenzhen Hospital
<b>Corresponding Author E-Mail:</b>	wurf100@126.com
<b>Order of Authors:</b>	Weixia Wei Shilin Zhong Liping Zeng X Dr. Qu Wei Zhang Yuting Xiang Xinfeng Qu Ruifang Wu
<b>Additional Information:</b>	
<b>Question</b>	<b>Response</b>
Please indicate whether this article will be Standard Access or Open Access.	Standard Access (US\$2,400)
Please indicate the <b>city, state/province, and country</b> where this article will be <b>filmed</b> . Please do not use abbreviations.	Department of Obstetrics and Gynecology, Peking University Shenzhen Hospital, 1120 Lianhua Road, Futian District, Shenzhen 518036, China

**TITLE:**

Laparoscopic Intracapsular Rotary-Cut Procedure: A Modified Myomectomy Procedure Facilitating Fertility Preservation

**AUTHORS & AFFILIATIONS:**

Liping Zeng<sup>1,2</sup>, Weixia Wei<sup>1,2</sup>, Shilin Zhong<sup>1,2</sup>, Wei Zhang<sup>1,2</sup>, Yuting Xiang<sup>1</sup>, Xinfeng Qu<sup>3</sup>, Ruifang Wu<sup>1,2</sup>

<sup>1</sup>Department of Obstetrics and Gynecology, Peking University Shenzhen Hospital, Shenzhen, China

<sup>2</sup>Shenzhen Key Laboratory of Gynecological Diagnostic Technology Research, Shenzhen, China

<sup>3</sup>Specialist of SZSM Project, Peking University Shenzhen Hospital, Shenzhen, China

**Corresponding Author:**

Ruifang Wu  
wurf100@126.com

**Email Addresses of Co-authors:**

Liping Zeng	(zengliping@163.com)
Weixia Wei	(weixwei_2031@126.com)
Shilin Zhong	(zhongshilin2013@163.com)
Wei Zhang	(dafeng333@163.com)
Xinfeng Qu	(steve1005@me.com)
Yuting Xiang	(380576683@qq.com)

**KEYWORDS:**

Uterine fibroid, pseudo-capsule, laparoscopic myomectomy, intracapsular rotary-cut procedure (IRCP), fertility preservation

**SUMMARY:**

Here, we present a protocol for performing an intracapsular rotary-cut procedure (IRCP), a modified laparoscopic intracapsular myomectomy that promotes fertility preservation.

**ABSTRACT:**

Uterine fibroids are common benign tumors in the female reproductive system. A hysterectomy is the most effective treatment for symptomatic fibroids. For patients desiring pregnancy, laparoscopic intracapsular myomectomy (LM) is an alternative surgery option. Although LM is widely accepted to treat fibroids, it is technically demanding with risk of excessive bleeding and difficult suturing, especially in cases with large fibroids or tumors in unusual locations. Therefore, we developed an intracapsular rotary-cut procedure (IRCP) as a modification of laparoscopic intracapsular myomectomy, with the intention to minimize risks of LM and help uterine healing. A summary of the improvements to the IRCP is described: 1) making an incision at the site of the fibroid with a length of one-third to one-half of the fibroid's diameter at a depth reaching the fibroid's surface; 2) holding the fibroid stably and making rotary cuts on the

fibroid at a depth of 0.5-1 cm within its pseudo-capsule while pulling it outward slightly, making sure not to cut off any pieces of the fibroid; and 3) repeating the cutting-and-pulling until the longest dimension of the fibroid is outside the incision. The multiple cuts are to minimize the diameter and extend the length of the fibroid. When the multiple cuts cause half of the fibroid body to “shrink”, the fibroid is squeezed out by contraction of the surrounding myometrium. Evaluation of the outcomes of IRCP showed that the time of enucleation and suturing, intraoperative bleeding, and decline of hemoglobin were significantly lower in the IRCP group than the LM group. As for reproductive outcomes, the full-term live birth rate of the IRCP group was significantly higher than that of LM group. However, there was no difference in delivery modes between the two groups. In conclusion, IRCP significantly benefits fertility preservation by minimizing damage to the uterus, protecting myofibers of the pseudo-capsule, and resulting in a shallower residual cavity, which eases stitching and causes less bleeding. It is worthwhile to adopt IRCP in younger patients who desire preservation of their fertility.

## **INTRODUCTION:**

Uterine fibroids are the most common pelvic tumors observed in gynecologic practice. The incidence is estimated to be about 20-25% worldwide<sup>1</sup>. Most uterine fibroids are asymptomatic but sometimes cause abnormal uterine bleeding, pelvic pressure, pelvic pain, and adverse reproductive outcomes, thus diminishing the quality of life of women<sup>2,3</sup>. Management of fibroids depends on individual situations and includes options such as surgery, medication, and revisit observation<sup>4</sup>. A hysterectomy is an important method to treat uterine fibroids and is a radical surgery that can prevent recurrence<sup>3,5</sup>. Myomectomy, however, is becoming popular as doctors are paying more attention to the fertility preservation of patients at reproductive ages, especially during the era of the two-child policy in China<sup>6</sup>.

As Tinelli and his colleagues have described, in the procedure of laparoscopic myomectomy (LM)<sup>7</sup>, the visceral peritoneum is incised in the midline longitudinally by monopolar scissors or a crochet needle electrode, proceeding at a certain depth into the myometrium to identify the pseudo-capsule. The pseudo-capsule is opened longitudinally by monopolar scissors or a hook electrode at a low wattage (30 W) to expose the fibroid. Then, the fibroid is hooked by a myoma screw for gentle enucleation with help from an irrigator cannula that is inserted in the space between the pseudo-capsule and fibroid. Hemostasis of the small vessels is made to free the base of the myoma and connective bridges from the pseudo-capsule. The myometrium is then closed in a single layer for subserous fibroids and as double layers for intramural fibroids.

Although LM is widely applied around the world, there are still some limitations of this procedure. Since LM is more technically demanding than laparotomy, it should be applied to selected cases with relatively smaller sizes and numbers of fibroids<sup>8,9</sup>. It remains a great challenge to remove intramural fibroids greater than 8 cm or subserous ones greater than 12 cm with laparoscopy<sup>10</sup>. Published data have shown that transfusion-requiring bleeding and postoperative hematomas significantly increased when applying LM to removal of intra-broad ligamentous fibroids<sup>11</sup>. Other researchers believe that excessive bleeding, prolonged operation time, and potential dissemination of cells when applying morcellation are concerning problems with LM<sup>12,13</sup>. The risk of during-pregnancy uterine rupture after LM is reported to be higher

than abdominal myomectomy due to the technical difficulties of suturing<sup>14</sup>. The safety of pregnancy succeeding LM remains controversial<sup>15</sup>. As postoperative healing of the myometrium is very important for patients who need to maintain fertility either clinically or by request, LM procedures need to be more applicable, which can be accomplished by reducing the technical difficulties and promoting uterine healing after the surgery.

In order to minimize the damage to the patient's fertility, here we present a modified myomectomy procedure, the intracapsular rotary-cut procedure (IRCP)<sup>16</sup>. This procedure shortens the incision on uterine wall as much as possible and reduces the technical difficulties of LM. Also, it helps to protect fibers and blood vessels of the pseudo-capsule that plays an important role in uterine healing after myomectomy, ultimately reducing the risk of postoperative hematoma and uterine rupture in subsequent pregnancy. After being reviewed and approved by the Institutional Review Board of Peking University Shenzhen Hospital on December 15, 2012, we began the application of IRCP and evaluation of the outcomes of IRCP by comparison with traditional LM.

#### **PROTOCOL:**

All the procedures in the following protocol were reviewed and approved by the Institutional Review Board of Peking University Shenzhen Hospital for application on patients on December, 15, 2012.

#### **1. Patient Preparation**

1.1. Use the following inclusion criteria: abnormal uterine bleeding; fibroids compressing surrounding organs and causing urinary, digestive, or sexual symptoms; infertility; fibroid is larger than 4 cm while the patient is preparing for pregnancy.

1.2. Use the following exclusion criteria: suspected malignancy; suspected fibroid degeneration; pedunculated, cervical, or intra-broad ligamentous fibroids; preoperative use of gonadotrophin-releasing hormone analogues; acute systemic inflammation or pelvic inflammatory disease; patient is currently pregnant, within puerperium, or within three months after abortion; severe coagulation disorders; any other contraindications for general anesthesia or laparoscopy.

1.3. Conduct a pelvic palpation and ultrasound examination to determine the location, number, and size of the fibroids.

1.4. Inform the patient of the benefits and risks of surgery and obtain written consent, discussing the risks of excessive bleeding and blood transfusion, conversion to laparotomy, tumor cell dissemination during the operation, and postoperative infection.

1.5. Perform the surgery under general anesthesia with endotracheal intubation. Administer to each patient a prophylactic antibiotic dosage of 2 g of cefamandole intravenously 30 min before induction of anesthesia.

## 2. Pre-IRCP Preparation

2.1. After standard skin sterilization, establish the ports by standard techniques: a 10 mm umbilical port, and 5 mm and 10 mm ancillary ports in the lower abdomen. Connect the 5 mm port with a plastic tube for vacuum drainage, which can suck the smoke during surgery.

2.2. During the surgery, have an anesthesiologist carefully monitor vital signs of the patient.

2.3. Maintain the intraabdominal pressure and gas flow rate at 13 kPa and 12 L/min, respectively.

## 3. Intracapsular Rotary-Cut Procedure (IRCP)

3.1. Inspect the pelvis carefully to confirm the size, number, and location of the fibroids. Inject an ischemic solution (6 U pituitrin and 20 U oxytocin diluted in 10 mL of saline) into the myometrium around the fibroids with a 10 mL syringe.

3.2. Determine the incision position on the most-protruding site of the fibroid and incise longitudinally by a monopolar hook electrode at low wattage (30 W), ensuring the length is no longer than half of the fibroid diameter. Open the pseudo-capsule by a longitudinal cut to expose the fibroid surface (**Figure 1A**).

3.3. Hold the fibroid with the laparoscopic forceps and pull it outward, keeping a certain tension to expose the boundary between the fibroid and the pseudo-capsule (**Figure 1B**).

3.4. Perform multiple rotary cuts on the fibroid (**Figure 1C1**) with a monopolar electrical knife in depths of 5-10 mm, shrinking the diameter of the tumor (**Figure 1C2**) and ensuring not to cut any pieces of the fibroid off.

3.4.1. Meanwhile, keep pulling outward to facilitate further exposure of the gap between the fibroid and the pseudo-capsule. Remove the smoke by vacuum drainage to keep a clear field.

3.5. Repeat the cutting-pulling procedures on the fibroid in the manner described above with 10 mm intervals, ensuring that each cut is at a certain angle with the prior cut, until the longest dimension of the fibroid is outside the incision. Then, the fibroid will be squeezed out by contraction of the pseudo-capsule and myometrium (**Figure 1D**). Avoid pulling too hard and blunt dissection to protect fibers and vessels of the pseudo-capsule.

3.6. Gently pull the fibroid outward, and the pseudo-capsule should slip off to the base of the fibroid. Continue the cuts on the fibroid until the base of the fibroid is exposed and isolate it from its pseudo-capsule (**Figure 1E**). Use bipolar electrocautery forceps to coagulate and cut off the blood vessels, always at 30 W. After removal of the fibroid, only a shallow residual cavity is left (**Figure 1F**).

3.7. Close the residual cavity in a single layer with a 30 cm 1-0 polyglyconate unidirectional barbed thread. Begin the running suture at 5 mm outside of the incisional edge with 1 cm increments. Make sure that the stitching passes through the bottom of the residual cavity, and leave no dead space.

Note: Generally, a single-layer suture is enough to close the residual cavity (**Figures 1G and 1H**). Occasionally, the fibroid was over 12 cm in diameter and occupied more than 2/3 of the myometrium. In these cases, a “folding suture” can be adopted, in which the myometrium on one side of the incision can be sutured on top of the other side to close the residual cavity and strengthen the myometrium.

3.8. After suturing, enlarge the 10 mm port to a 15-20 mm port for the introduction of the morcellator. Morcellate the fibroids with a reusable morcellator.

#### 4. Postoperative Management

4.1. Document the intra- and post-operative parameters carefully, including the diameters of the fibroids (represented by the diameter of the largest one in cases of multiple fibroids), operation time (from the beginning of incision to the end of suturing), blood loss (calculated by vacuum drainage), and rate of conversion to laparotomy.

4.2. Follow up patients by pelvic examination and ultrasound as well as phone interviews.

4.3. Evaluate the outcomes of IRCP by comparison with those of traditional LM around the same period. Perform statistical analysis by SPSS software and consider  $p < 0.05$  as statistically significant.

#### REPRESENTATIVE RESULTS:

IRCP was performed on 41 patients with uterine fibroids and traditional LM was performed on 72 patients from 2013 to 2016. 9 cases (12.5%) in the LM group were converted to laparotomy because of massive bleeding, difficulty in enucleation, or suturing, while laparoscopy was performed successfully in all cases in the IRCP group. The percentage of conversion to laparotomy was significantly higher in the LM group ( $p = 0.025$ ). Excluding the 9 cases converted to laparotomy, the average age of patients in the IRCP group ( $n = 41$ ) and LM group ( $n = 63$ ) were  $38.6 \pm 5.9$  years and  $38.1 \pm 6.2$  years, respectively, suggesting no difference between the two groups ( $p = 0.632$ ). As is shown in **Table 1**, the mean diameters of the fibroids were also comparable between the two groups ( $p = 0.265$ ). However, the time of enucleation and suturing, intraoperative bleeding, and decline of hemoglobin were all significantly lower in the IRCP group than the LM group ( $p = 0.015$ ,  $p = 0.014$ ,  $p = 0.024$ ). Postoperatively, none of the 113 cases experienced fever, urinary infections, postoperative hematomas, or other complications.

After discharged, the patients were followed up by outpatient visits and telephone interviews. When evaluating reproductive outcomes, only those who desired fertility after surgery were included. In the IRCP group, all patients were successfully followed up. Among them, 31 (75.6%) patients achieved full-term births, including 2 vaginal births and 29 caesarean sections. On the other hand, in the LM group, 56 (88.9%) patients were successfully followed up, and the rate of full-term live birth was 23.2% (13/56), consisting of 1 vaginal birth and 12 caesarean sections. The full-term live birth rate of the IRCP group was significantly higher than that of the LM group ( $p = 0.000$ ). However, no difference existed between the delivery modes in the two groups ( $p = 1.000$ ). In addition, there was no uterine rupture observed in either group during follow-up.

#### FIGURE AND TABLE LEGENDS:

**Table 1. Comparison of perioperative outcomes between two groups.** The average age of patients and diameter of fibroids were comparable between the two groups. However, the time of enucleation and suturing, intraoperative bleeding, and decline of hemoglobin were all significantly lower in the IRCP group than in LM group.

**Figure 1. Steps of intracapsular rotary-cut procedures (IRCP).** (A) Make a longitudinal incision on the uterine wall where the fibroid was located by a monopolar hook electrode at 30 W, with an incisive length of 3 cm (1/3 of the fibroid diameter). (B) Hold the fibroid and pull it outward, keeping a certain tension to expose the boundary between the fibroid and the pseudo-capsule. (C1) Perform multiple rotary cuts on the fibroid. (C2) Shrink the diameter of the tumor. (D) Repeat the cuts, and the fibroid will be squeezed out by myometrial contraction. (E) Gently pull the fibroid outward, expose the basis of the fibroid, and isolate it from its pseudo-capsule. (F) Removed the fibroid (left), leaving a shallow residual cavity (right). (G) Close the residual cavity with a single-layer suture. (H) The suture was finished.

#### DISCUSSION:

Uterine fibroids are the most common benign tumors of the female reproductive system, affecting 20-25% of all women<sup>1</sup> and causing abnormal uterine bleeding, recurrent miscarriage, pelvic pain, premature birth, and infertility in 10-30% cases<sup>2</sup>. As most patients with uterine fibroids are asymptomatic, the actual incidence may be higher than recognized<sup>1</sup>. Management of uterine fibroids are generally based on various factors including the age and symptoms of the patient, size and location of the fibroids, patient desire to preserve the uterus, techniques and experience of the gynecologists, and accessibility of technical equipment<sup>17</sup>. Technically, hysterectomy is the most effective treatment for symptomatic uterine fibroids. As reported, uterine fibroids accounted for most cases of hysterectomy from 1990 to 1997 in the United States<sup>18</sup>. According to a cross-sectional study conducted from 2009 to 2011 in China, the major indication for hysterectomy is still uterine fibroids in rural regions of China, accounting for 70.67% of all cases<sup>19</sup>. For patients who desire pregnancy, however, myomectomy is an alternative that can be performed by laparotomy or laparoscopy. A systemic review of nine randomized controlled trials has demonstrated that LM is associated with less subjectively reported postoperative pain, lower postoperative fever occurrence, and shorter hospital stays compared to open myomectomy; furthermore, there was no difference in recurrence risk<sup>20</sup>. Also, LM resulted in less adhesion formation<sup>9</sup>. Because of its superiority, LM is the most

frequent choice for patients who desire preservation of uterus and subsequent pregnancy, especially for subserous or intramural fibroids.

In recent years, researchers have achieved a better understanding about the vascular structure surrounding uterine fibroids, namely the pseudo-capsule. It is believed that the pseudo-capsule is a part of myometrium compressed by the tumor and is contains abundant collagen fibers, blood vessels, and neurofibers<sup>21</sup>. The integrity of the pseudo-capsule is important for blood supply and uterine healing after myomectomy. Therefore, the widely accepted principle is to perform an intracapsular myomectomy. During this procedure, the fibroids are stretched and extracted directly from the pseudo-capsule. Since detachment of the fibroids is performed inside the pseudo-capsule, it causes decreased blood loss<sup>22</sup>. Tinelli<sup>7</sup> has postulated that laparoscopic intracapsular intramural and subserous myomectomy spares the intact fibrovascular network surrounding the myoma, reducing bleeding and damage to the myometrium, which can also maximize the potential for future fertility and minimize risk of uterine rupture during pregnancy. However, the risk of massive bleeding, difficulty of suturing, and demands of the required techniques are major limitations of traditional LM. Based on this, we developed the modified myomectomy procedure, IRCP.

In an earlier article on the evaluation of IRCP published by our team, we have demonstrated that IRCP was associated with smaller incision, less time of suturing, less intraoperative blood loss, and reduced decline of hemoglobin, compared to traditional LM<sup>16</sup>. The results of this study were consistent with the previous data, confirming the advantages of ICRP over traditional LM. Meanwhile, the full-term live birth rate was higher in the IRCP group than the LM group, suggesting that IRCP facilitated fertility preservation. Researchers have illustrated that previous laparoscopic myomectomy with adequate suturing of the myometrium was not a contraindication for vaginal delivery<sup>23</sup>. The reported rate of vaginal birth after traditional LM was 67.0%<sup>7</sup>, but in our study, the rate of vaginal birth was much lower than reported. The past decades have witnessed a remarkable increase of the caesarean section rate in mainland China<sup>24</sup>, which has resulted from various factors, including patient concerns about pain and uneasy doctor-patient relationships. Also, some women believe that a caesarean section is safer for the fetus. Thus, for women with previous history of myomectomy, obstetricians tend to be more cautious and are more likely to recommend scheduled caesarean sections because of the concerns about uterine rupture<sup>25</sup>. Uterine rupture is a rare but devastating complication during post-myomectomy pregnancy, especially in the third trimester<sup>26,27</sup>. In spite of the extreme low incidence, it may cause unfavorable outcomes for the mother and fetus. Reported risk factors included excessive use of electrical equipment and inadequate suturing<sup>28</sup>. No case of uterine rupture was observed in our study. By IRCP, the application of electrical equipment is limited, and suturing is less technically demanding due to the shallower residual cavity, which may contribute to a lower risk of uterine rupture; however, more evidence is needed.

As discussed, the advantages of laparoscopic IRCP are clear in comparison to traditional LM. First, a smaller incision of the uterus is made. Traditional LM requires an incision over half of the fibroid diameter. For multiple fibroids with unregular shapes, the incision may be equal to



the diameter of the fibroid, which may cause severe damage to the pseudo-capsule. IRCP, however, enables the fibroid to be removed from an incision that is no more than half of its diameter, protecting the integrity of the pseudo-capsule as much as possible. Second, IRCP causes less bleeding. Traditional LM causes bleeding due to damage to the blood vessels of the pseudo-capsule. Specifically, blunt dissection of the fibroid and its pseudo-capsule usually leads to blood vessel breakage and massive bleeding. IRCP significantly lessens bleeding, as it avoids blunt dissection. Instead, IRCP protects the vessels with rotary-cuts on the fibroid, which has no blood vessels and eases handling of the blood vessels at the base of the fibroid. IRCP achieves detachment of the fibroid by shrinking its diameter and contraction of the surrounding myometrium. The blood vessels at the base of the fibroid can be coagulated by bipolar electrocautery forceps, resulting in less blood loss. Third, a smaller and shallower residual cavity was left. Traditional LM is based on blunt dissection on the muscle layer of the pseudo-capsule, which causes fracture of the muscle fibers to form a residual cavity equal to the fibroid size after it is removed. IRCP enables removal of the fibroid in its pseudo-capsule without damage to the muscle fibers. Therefore, the fairly protected muscle layer can contract after the fibroid is removed, leaving a smaller and shallower residual cavity. Although both traditional LM and IRCP emphasized removing the fibroid within its pseudo-capsule, the residual cavity is much smaller and shallower in IRCP due to injection of ischemic solutions, better contraction of the myometrium, and a smaller incision. Lastly, IRCP makes suturing easier; as IRCP requires smaller incisions in the uterus, it enables the achieving of smaller and shallower residual cavities and little bleeding, making it easy to suture with no dead space remaining. Usually, a single-layer suture is enough to close the residual cavity, and no layered suture is needed. Also, it is less technically demanding for the surgeon.

Still, we acknowledge that there are still some limitations of IRCP. For example, IRCP is not suitable for pedunculated subserous fibroids or submucous ones. Also, it remains to be determined whether IRCP should be applied to degenerated fibroids. Red degeneration, cystic degeneration and fatty degeneration all lead to softer texture of the tumor and impaired contraction of the myometrium. In this case, it is not easy to detach the fibroid from its pseudo-capsule by IRCP. Besides, as a moderated morcellation procedure, IRCP may result in potential dissemination if malignancy exists. However, with a careful pre-operative evaluation for risk of malignancy and by strictly following the procedures to perform inside of the pseudo-capsule, this risk can be minimized. In addition, it is difficult to operate when the major part of the fibroid is still inside the pseudo-capsule, and it requires patience. However, when most of the fibroid is outside the incision, it will slip out spontaneously.

Eventually, we concluded that IRCP significantly shortens operation time and reduces intraoperative bleeding. This procedure also better protects the integrity of the pseudo-capsule and myometrium by shrinking the diameter of the fibroid and facilitating uterine healing, which is of fundamental importance for subsequent pregnancy and vaginal delivery. It is worthwhile to adopt IRCP in young patients who desire maintenance of fertility. IRCP is especially suitable for cervical and intra-ligamentous fibroids. Although fibroids in unusual locations are not illustrated in the current article, we have achieved successful experience in managing cervical and intra-ligamentous fibroids with IRCP. As the surgery is performed inside the pseudo-

capsule, it effectively avoids injury to uterine blood vessels and ureters. Usually, the pseudo-capsule of intra-ligamentous fibroids is looser, so it is easier and safer to perform IRCP. As for cervical fibroids, we have successfully performed IRCP on 9 patients with large cervical fibroids, which will be illustrated in detail in later reports.

#### DISCLOSURES:

The study was funded by the Shenzhen Municipal Government (JCYJ20150601090833370 and SZSM201412010), Shenzhen, China.

#### REFERENCES:

- 1 Drayer, S. M., Catherino, W. H. Prevalence, morbidity, and current medical management of uterine leiomyomas. *International Journal of Gynecology & Obstetrics*. **131** (2), 117-122 (2015).
- 2 Wu, J., *et al.* Prevalence and clinical significance of mediator complex subunit 12 mutations in 362 Han Chinese samples with uterine leiomyoma. *Oncology Letters*. **14** (1), 47-54 (2017).
- 3 Falcone, T., Parker, W. H. Surgical management of leiomyomas for fertility or uterine preservation. *Obstetrics & Gynecology*. **121** (4), 856-868 (2013).
- 4 Donnez, J., Dolmans, M. M. Uterine fibroid management: from the present to the future. *Human Reproduction Update*. **22** (6), 665-686 (2016).
- 5 Gu, Y., Zhu, L., Liu, A., Ma, J., Lang, J. Analysis of hysterectomies for patients with uterine leiomyomas in China in 2010. *International Journal of Gynecology & Obstetrics*. **129** (1), 71-74 (2015).
- 6 Cheng, P. J., Duan, T. China's new two-child policy: maternity care in the new multiparous era. *BJOG*. **123 Suppl 3**, 7-9 (2016).
- 7 Tinelli, A., *et al.* Laparoscopic myomectomy focusing on the myoma pseudocapsule: technical and outcome reports. *Human Reproduction*. **27** (2), 427-435 (2012).
- 8 Agdi, M., Tulandi, T. Minimally invasive approach for myomectomy. *Seminars in Reproductive Medicine*. **28** (3), 228-234 (2010).
- 9 Al-Talib, A. Factors contributing to failure of laparoscopic myomectomy. *Surgical Technology International*. **23** 149-151 (2013).
- 10 Saccardi, C., *et al.* Limits and complications of laparoscopic myomectomy: which are the best predictors? A large cohort single-center experience. *Archives of Gynecology and Obstetrics*. **290** (5), 951-956 (2014).
- 11 Sizzi, O., *et al.* Italian multicenter study on complications of laparoscopic myomectomy. *Journal of Minimally Invasive Gynecology*. **14** (4), 453-462 (2007).
- 12 Buckley, V. A., *et al.* Laparoscopic myomectomy: clinical outcomes and comparative evidence. *Journal of Minimally Invasive Gynecology*. **22** (1), 11-25 (2015).
- 13 Glaser, L. M., Friedman, J., Tsai, S., Chaudhari, A., Milad, M. Laparoscopic myomectomy and morcellation: A review of techniques, outcomes, and practice guidelines. *Best Practice & Research: Clinical Obstetrics & Gynaecology*. **46**, 99-112 (2018).
- 14 Kelly, B. A., Bright, P., Mackenzie, I. Z. Does the surgical approach used for myomectomy influence the morbidity in subsequent pregnancy? *Journal of Obstetrics & Gynaecology*. **28** (1), 77-81 (2008).

- 15 Tian, Y. C., Long, T. F., Dai, Y. M. Pregnancy outcomes following different surgical approaches of myomectomy. *Journal of Obstetrics and Gynaecological Research*. **41** (3), 350-357 (2015).
- 16 Zhong, S. L., Zeng, L. P., Li, H., Wu, R. F. Development and evaluation of an improved laparoscopic myomectomy adopting intracapsular rotary-cut procedures. *European Journal of Obstetrics & Gynecology and Reproductive Biology*. **221**, 5-11 (2018).
- 17 Vilos, G. A., Allaire, C., Laberge, P. Y., Leyland, N., Special, C. The management of uterine leiomyomas. *Journal of Obstetrics and Gynaecology Canada*. **37** (2), 157-178 (2015).
- 18 Lethaby, A., Vollenhoven, B. Fibroids (uterine myomatosis, leiomyomas). *BMJ Clinical Evidence*. (2011).
- 19 Liu, F., *et al.* The epidemiological profile of hysterectomy in rural Chinese women: a population-based study. *BMJ Open*. **7** (6), e015351 (2017).
- 20 Bhawe Chittawar, P., Franik, S., Pouwer, A. W., Farquhar, C. Minimally invasive surgical techniques versus open myomectomy for uterine fibroids. *Cochrane Database of Systematic Reviews*. (10), CD004638 (2014).
- 21 Tinelli, A., *et al.* Angiogenesis and Vascularization of Uterine Leiomyoma: Clinical Value of Pseudocapsule Containing Peptides and Neurotransmitters. *Current Protein and Peptide Science*. **18** (2), 129-139 (2017).
- 22 Tinelli, A., *et al.* Surgical management of neurovascular bundle in uterine fibroid pseudocapsule. *Journal of the Society of Laparoendoscopic Surgeons*. **16** (1), 119-129 (2012).
- 23 Fagherazzi, S., *et al.* Pregnancy outcome after laparoscopic myomectomy. *Clinical and Experimental Obstetrics and Gynecology*. **41** (4), 375-379 (2014).
- 24 Liu, Y., *et al.* A descriptive analysis of the indications for caesarean section in mainland China. *BMC Pregnancy Childbirth*. **14**, 410 (2014).
- 25 Weibel, H. S., Jarcevic, R., Gagnon, R., Tulandi, T. Perspectives of obstetricians on labour and delivery after abdominal or laparoscopic myomectomy. *Journal of Obstetrics & Gynaecology Canada*. **36** (2), 128-132 (2014).
- 26 Vandenberghe, G., *et al.* Nationwide population-based cohort study of uterine rupture in Belgium: results from the Belgian Obstetric Surveillance System. *BMJ Open*. **6** (5), e010415 (2016).
- 27 You, S. H., Chang, Y. L., Yen, C. F. Rupture of the scarred and unscarred gravid uterus: Outcomes and risk factors analysis. *Taiwan Journal of Obstetrics & Gynecology*. **57** (2), 248-254 (2018).
- 28 Wu, X., Jiang, W., Xu, H., Ye, X., Xu, C. Characteristics of uterine rupture after laparoscopic surgery of the uterus: clinical analysis of 10 cases and literature review. *Journal of Internal Medicine Research*. (2018).

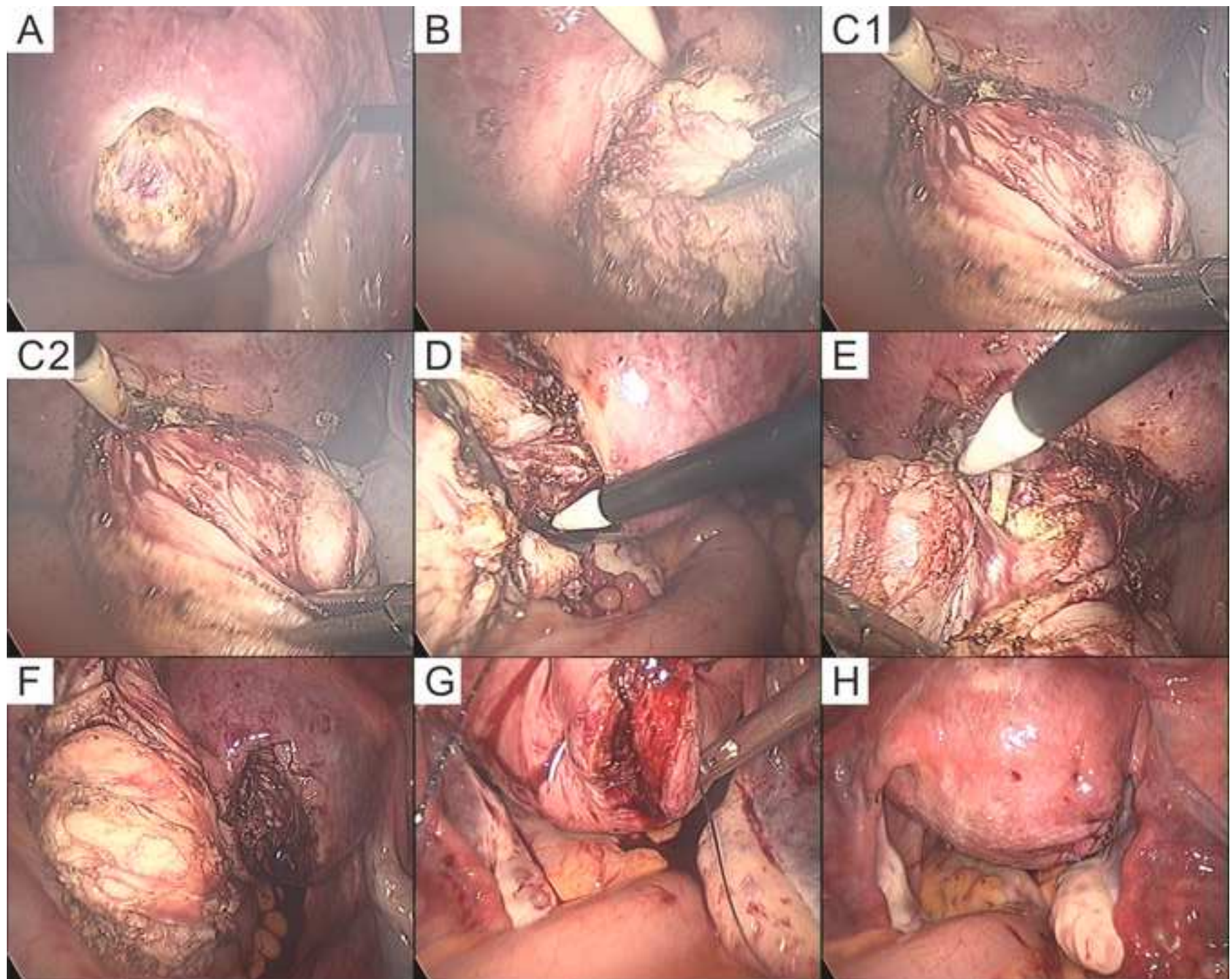


Table 1 Comparison of perioperative outco

	LM group (n=63)
age (year)	38.1±6.2
diameter (cm)	6.7±2.1
time of enucleation and suture (min)	56.8± 32.4
intraoperative bleeding (ml)	103.1±150.4
decline of hemoglobin (g/L)	18.0±10.3

comes between two groups

IRCP group (n=41)	t	P
38.6±5.9	0.480	0.632
7.2±2.3	1.120	0.265
42.4± 26.9	2.46	0.015
43.1+38.5	2.5	0.014
13.4+9.5	2.28	0.024

Name of Material/ Equipment	Company	Catalog Number	Comments/Description
laparoscopy	Stryker Corporation	X 800	
morcellator	Kangji Medical	KJ-301A	
30-cm 1-0 polyglyconate unidirectional barbed thread	Covidien	V-Loc 180	





1 Alewife Center #200  
Cambridge, MA 02110  
Tel: 617.945.9051  
www.jove.com

## ARTICLE AND VIDEO LICENSE AGREEMENT

Title of Article: Laparoscopic Intracapsular Rotary-Cut Procedure, a modified myomectomy procedure facilitating fertility preservation  
 Author(s): Liping Zeng, Weixia Wei, Yuting Xiang, Shilin Zhang, Wei Zhang, Xinfeng Qu, Ruifang Wu.

Item 1: The Author elects to have the Materials be made available (as described at <http://www.jove.com/publish>) via:

☒ Standard Access

☐ Open Access

Item 2: Please select one of the following items:

☒ The Author is **NOT** a United States government employee.

☐ The Author is a United States government employee and the Materials were prepared in the course of his or her duties as a United States government employee.

☐ The Author is a United States government employee but the Materials were NOT prepared in the course of his or her duties as a United States government employee.

### ARTICLE AND VIDEO LICENSE AGREEMENT

1. **Defined Terms.** As used in this Article and Video License Agreement, the following terms shall have the following meanings: "Agreement" means this Article and Video License Agreement; "Article" means the article specified on the last page of this Agreement, including any associated materials such as texts, figures, tables, artwork, abstracts, or summaries contained therein; "Author" means the author who is a signatory to this Agreement; "Collective Work" means a work, such as a periodical issue, anthology or encyclopedia, in which the Materials in their entirety in unmodified form, along with a number of other contributions, constituting separate and independent works in themselves, are assembled into a collective whole; "CRC License" means the Creative Commons Attribution-Non Commercial-No Derivs 3.0 Unported Agreement, the terms and conditions of which can be found at: <http://creativecommons.org/licenses/by-nc-nd/3.0/legalcode>; "Derivative Work" means a work based upon the Materials or upon the Materials and other pre-existing works, such as a translation, musical arrangement, dramatization, fictionalization, motion picture version, sound recording, art reproduction, abridgment, condensation, or any other form in which the Materials may be recast, transformed, or adapted; "Institution" means the institution, listed on the last page of this Agreement, by which the Author was employed at the time of the creation of the Materials; "JoVE" means MyJoVE Corporation, a Massachusetts corporation and the publisher of The Journal of Visualized Experiments; "Materials" means the Article and / or the Video; "Parties" means the Author and JoVE; "Video" means any video(s) made by the Author, alone or in conjunction with any other parties, or by JoVE or its affiliates or agents, individually or in collaboration with the Author or any other parties, incorporating all or any portion

of the Article, and in which the Author may or may not appear.

2. **Background.** The Author, who is the author of the Article, in order to ensure the dissemination and protection of the Article, desires to have the JoVE publish the Article and create and transmit videos based on the Article. In furtherance of such goals, the Parties desire to memorialize in this Agreement the respective rights of each Party in and to the Article and the Video.

3. **Grant of Rights in Article.** In consideration of JoVE agreeing to publish the Article, the Author hereby grants to JoVE, subject to Sections 4 and 7 below, the exclusive, royalty-free, perpetual (for the full term of copyright in the Article, including any extensions thereto) license (a) to publish, reproduce, distribute, display and store the Article in all forms, formats and media whether now known or hereafter developed (including without limitation in print, digital and electronic form) throughout the world, (b) to translate the Article into other languages, create adaptations, summaries or extracts of the Article or other Derivative Works (including, without limitation, the Video) or Collective Works based on all or any portion of the Article and exercise all of the rights set forth in (a) above in such translations, adaptations, summaries, extracts, Derivative Works or Collective Works and (c) to license others to do any or all of the above. The foregoing rights may be exercised in all media and formats, whether now known or hereafter devised, and include the right to make such modifications as are technically necessary to exercise the rights in other media and formats. If the "Open Access" box has been checked in Item 1 above, JoVE and the Author hereby grant to the public all such rights in the Article as provided in, but subject to all limitations and requirements set forth in, the CRC License.

612542.6 For questions, please contact us at [submissions@jove.com](mailto:submissions@jove.com) or +1.617.945.9051.





100 Brookline Avenue, Suite 200  
Cambridge, MA 02140  
Tel: 617.945.9051  
www.jove.com

## ARTICLE AND VIDEO LICENSE AGREEMENT

4. **Retention of Rights in Article.** Notwithstanding the exclusive license granted to JoVE in **Section 3** above, the Author shall, with respect to the Article, retain the non-exclusive right to use all or part of the Article for the non-commercial purpose of giving lectures, presentations or teaching classes, and to post a copy of the Article on the Institution's website or the Author's personal website, in each case provided that a link to the Article on the JoVE website is provided and notice of JoVE's copyright in the Article is included. All non-copyright intellectual property rights in and to the Article, such as patent rights, shall remain with the Author.

5. **Grant of Rights in Video – Standard Access.** This **Section 5** applies if the "Standard Access" box has been checked in **Item 1** above or if no box has been checked in **Item 1** above. In consideration of JoVE agreeing to produce, display or otherwise assist with the Video, the Author hereby acknowledges and agrees that, Subject to **Section 7** below, JoVE is and shall be the sole and exclusive owner of all rights of any nature, including, without limitation, all copyrights, in and to the Video. To the extent that, by law, the Author is deemed, now or at any time in the future, to have any rights of any nature in or to the Video, the Author hereby disclaims all such rights and transfers all such rights to JoVE.

6. **Grant of Rights in Video – Open Access.** This **Section 6** applies only if the "Open Access" box has been checked in **Item 1** above. In consideration of JoVE agreeing to produce, display or otherwise assist with the Video, the Author hereby grants to JoVE, subject to **Section 7** below, the exclusive, royalty-free, perpetual (for the full term of copyright in the Article, including any extensions thereto) license (a) to publish, reproduce, distribute, display and store the Video in all forms, formats and media whether now known or hereafter developed (including without limitation in print, digital and electronic form) throughout the world, (b) to translate the Video into other languages, create adaptations, summaries or extracts of the Video or other Derivative Works or Collective Works based on all or any portion of the Video and exercise all of the rights set forth in (a) above in such translations, adaptations, summaries, extracts, Derivative Works or Collective Works and (c) to license others to do any or all of the above. The foregoing rights may be exercised in all media and formats, whether now known or hereafter devised, and include the right to make such modifications as are technically necessary to exercise the rights in other media and formats. For any Video to which this **Section 6** is applicable, JoVE and the Author hereby grant to the public all such rights in the Video as provided in, but subject to all limitations and requirements set forth in, the CRC License.

7. **Government Employees.** If the Author is a United States government employee and the Article was prepared in the course of his or her duties as a United States government employee, as indicated in **Item 2** above, and any of the licenses or grants granted by the Author hereunder exceed the scope of the 17 U.S.C. 403, then the rights granted hereunder shall be limited to the maximum

rights permitted under such statute. In such case, all provisions contained herein that are not in conflict with such statute shall remain in full force and effect, and all provisions contained herein that do so conflict shall be deemed to be amended so as to provide to JoVE the maximum rights permissible within such statute.

8. **Protection of the Work.** The Author(s) authorize JoVE to take steps in the Author(s) name and on their behalf if JoVE believes some third party could be infringing or might infringe the copyright of either the Author's Article and/or Video.

9. **Likeness, Privacy, Personality.** The Author hereby grants JoVE the right to use the Author's name, voice, likeness, picture, photograph, image, biography and performance in any way, commercial or otherwise, in connection with the Materials and the sale, promotion and distribution thereof. The Author hereby waives any and all rights he or she may have, relating to his or her appearance in the Video or otherwise relating to the Materials, under all applicable privacy, likeness, personality or similar laws.

10. **Author Warranties.** The Author represents and warrants that the Article is original, that it has not been published, that the copyright interest is owned by the Author (or, if more than one author is listed at the beginning of this Agreement, by such authors collectively) and has not been assigned, licensed, or otherwise transferred to any other party. The Author represents and warrants that the author(s) listed at the top of this Agreement are the only authors of the Materials. If more than one author is listed at the top of this Agreement and if any such author has not entered into a separate Article and Video License Agreement with JoVE relating to the Materials, the Author represents and warrants that the Author has been authorized by each of the other such authors to execute this Agreement on his or her behalf and to bind him or her with respect to the terms of this Agreement as if each of them had been a party hereto as an Author. The Author warrants that the use, reproduction, distribution, public or private performance or display, and/or modification of all or any portion of the Materials does not and will not violate, infringe and/or misappropriate the patent, trademark, intellectual property or other rights of any third party. The Author represents and warrants that it has and will continue to comply with all government, institutional and other regulations, including, without limitation all institutional, laboratory, hospital, ethical, human and animal treatment, privacy, and all other rules, regulations, laws, procedures or guidelines, applicable to the Materials, and that all research involving human and animal subjects has been approved by the Author's relevant institutional review board.

11. **JoVE Discretion.** If the Author requests the assistance of JoVE in producing the Video in the Author's facility, the Author shall ensure that the presence of JoVE employees, agents or independent contractors is in accordance with the relevant regulations of the Author's institution. If more than one author is listed at the beginning of this Agreement, JoVE may, in its sole



1 Alewife Center #200  
Cambridge, MA 02140  
Tel: 617.945.9051  
www.jove.com

## ARTICLE AND VIDEO LICENSE AGREEMENT

discretion, elect not take any action with respect to the Article until such time as it has received complete, executed Article and Video License Agreements from each such author. JoVE reserves the right, in its absolute and sole discretion and without giving any reason therefore, to accept or decline any work submitted to JoVE. JoVE and its employees, agents and independent contractors shall have full, unfettered access to the facilities of the Author or of the Author's institution as necessary to make the Video, whether actually published or not. JoVE has sole discretion as to the method of making and publishing the Materials, including, without limitation, to all decisions regarding editing, lighting, filming, timing of publication, if any, length, quality, content and the like.

12. **Indemnification.** The Author agrees to indemnify JoVE and/or its successors and assigns from and against any and all claims, costs, and expenses, including attorney's fees, arising out of any breach of any warranty or other representations contained herein. The Author further agrees to indemnify and hold harmless JoVE from and against any and all claims, costs, and expenses, including attorney's fees, resulting from the breach by the Author of any representation or warranty contained herein or from allegations or instances of violation of intellectual property rights, damage to the Author's or the Author's institution's facilities, fraud, libel, defamation, research, equipment, experiments, property damage, personal injury, violations of institutional, laboratory, hospital, ethical, human and animal treatment, privacy or other rules, regulations, laws, procedures or guidelines, liabilities and other losses or damages related in any way to the submission of work to JoVE, making of videos by JoVE, or publication in JoVE or elsewhere by JoVE. The Author shall be responsible for, and shall hold JoVE harmless from, damages caused by lack of sterilization, lack of cleanliness or by contamination due to

the making of a video by JoVE its employees, agents or independent contractors. All sterilization, cleanliness or decontamination procedures shall be solely the responsibility of the Author and shall be undertaken at the Author's expense. All indemnifications provided herein shall include JoVE's attorney's fees and costs related to said losses or damages. Such indemnification and holding harmless shall include such losses or damages incurred by, or in connection with, acts or omissions of JoVE, its employees, agents or independent contractors.

13. **Fees.** To cover the cost incurred for publication, JoVE must receive payment before production and publication the Materials. Payment is due in 21 days of invoice. Should the Materials not be published due to an editorial or production decision, these funds will be returned to the Author. Withdrawal by the Author of any submitted Materials after final peer review approval will result in a US\$1,200 fee to cover pre-production expenses incurred by JoVE. If payment is not received by the completion of filming, production and publication of the Materials will be suspended until payment is received.

14. **Transfer, Governing Law.** This Agreement may be assigned by JoVE and shall inure to the benefits of any of JoVE's successors and assignees. This Agreement shall be governed and construed by the internal laws of the Commonwealth of Massachusetts without giving effect to any conflict of law provision thereunder. This Agreement may be executed in counterparts, each of which shall be deemed an original, but all of which together shall be deemed to be one and the same agreement. A signed copy of this Agreement delivered by facsimile, e-mail or other means of electronic transmission shall be deemed to have the same legal effect as delivery of an original signed copy of this Agreement.

A signed copy of this document must be sent with all new submissions. Only one Agreement is required per submission.

### CORRESPONDING AUTHOR

Name:

Ruifang Wu

Department:

Obstetrics and Gynecology

Institution:

Peking University Shenzhen Hospital

Title:

Laparoscopic Intracapsular Rotary-Cut Procedure, a modified myomectomy procedure facilitating fertility preservation.

Signature:

Ruifang Wu

Date:

Aug 14 / 2018

Please submit a **signed** and **dated** copy of this license by one of the following three methods:

1. Upload an electronic version on the JoVE submission site
2. Fax the document to +1.866.381.2236
3. Mail the document to JoVE / Attn: JoVE Editorial / 1 Alewife Center #200 / Cambridge, MA 02140

612542.6 For questions, please contact us at [submissions@jove.com](mailto:submissions@jove.com) or +1.617.945.9051.

Dear Editors and Reviews,

Thank you for your letter and valuable comments.

We have carefully revised the manuscript according to editorial comments and the instructions for authors. Major modification has been made. Specifically, when evaluating the outcomes of the procedure, only patients undergoing laparoscopy were included in the revised article. Patients with cervical or intraligamentous fibroids were also excluded. Thus, the number of cases is lessened.

Besides, Yuting Xiang should be added as a co-author. This decision is approved by all the other authors of this article, as she contributed a lot to the revision of this manuscript.

The responds to reviewers' comments are as follows:

#### Review #1:

##### Major Concerns:

**Is this technique practical in all types of cases, specially in degenerated myomas?**

Response: In the revised manuscript, we illustrated the inclusion and exclusion criteria of patients. Patients with degenerated fibroids were excluded in the current study. But it remains to be determined whether IRCP should be applied to degenerated fibroids. Red degeneration, cystic degeneration and fatty degeneration all lead to softer texture of the tumor and impaired contraction of the myometrium. In this case, it is not easy to detach the fibroid from its pseudo-capsule by IRCP.

**The use of monopolar for making semiring incisions on myomas will produce a lot of smoke which can interfere with visibility of surgical field.**

Response: The ports were established by standard techniques: a 10 mm umbilical port, as well as a 5 mm and a 10 mm ancillary ports in the lower abdomen. The 5 mm port was connected with a plastic tube for vacuum drainage, which can suck the smoke during surgery.

##### Minor Concerns:

**How do you explain that the total time of the surgery is less, as the technique involves time for multiple semiring incisions in a smoke filled operative field?**

Response: It seems to take more time for fibroid detachment. But the residual cavity is shallower and easier to suture, so it takes less time for suturing. Thus, the total time of the surgery can be less.

**The weakness of the study is not highlighted.**

Response: we acknowledge that there exist some limitations of IRCP:

1. IRCP is not suitable for pedunculated subserous fibroids or submucous ones.

2. It remains to be determined whether IRCP should be applied to degenerated fibroids. Red degeneration, cystic degeneration and fatty degeneration all lead to softer texture of the tumor and impaired contraction of the myometrium. In this case, it is not easy to detach the fibroid from its pseudo-capsule by IRCP.

3. As a moderated morcellation procedure, IRCP may result in potential dissemination if malignancy exists. However, with careful pre-operation evaluation for risk of malignancy and strictly following the procedures to perform inside of the pseudo-capsule, this risk can be minimized. In addition, it is difficult to operate when the major part of the fibroid is still inside the pseudo-capsule and it requires some patience. But when most part the fibroid is outside the incision, it slips out spontaneously.

#### Review #2:

##### Major Concerns:

The original intracapsular laparoscopic myomectomy technique should be reported in the introduction and in the references. I probably did not understand the reasons for the modification of the technique, because the authors perform multiple rotary-cuts on the fibroid with a monopolar electrical knife. What advantage do they have compared to the traditional method.

Response: Thanks for the comments. We have carefully reviewed the articles on laparoscopic myomectomy.

The similarities between IRCP and the traditional method include: 1) intracapsular procedure. 2) Incise on the most protruding site of the fibroid and open the pseudo-capsule by longitudinally. 3) hold the fibroid longitudinally to expose the boundary between the fibroid and pseudo-capsule.

The difference is as follows:

	IRCP	traditional LM
ischemic solution	6 U Pituitrin and 20 U Oxytocin diluted in 10 mL saline	not used
length of incision	no more than half of the fibroid diameter	not described
procedure	Perform multiple rotary cuts on the fibroid in depths of 5-10 mm, shrinking the diameter of the tumor. Then the fibroid will be squeezed out by contraction of the pseudo-capsule and myometrium.	The fibroid is removed after detachment from the pseudo-capsule.
residual cavity	small and shallow	not described

suture	a single-layered suture	a single layer for subserous fibroids and double layers for intramural ones
--------	-------------------------	---

The advantages of IRCP compared to the traditional method:

1)smaller incision; 2)shallower residual cavity; 3)less bleeding; 4)easier to suture

The smaller incision caused less damage to the myometrium, which can protect the neurovascular structure of the pseudo-capsule as much as possible. It is beneficial for postoperative uterine healing and fertility preservation. Patients desiring pregnancy can conceive six months after surgery.

The infra-ligament myomas are VERY DANGEROUS, as in these structures the uterine vessels, the ureters and the large iliac vessels run.

Response: This procedure is performed inside the pseudo-capsule and it is especially suitable for cervical and intra-ligamentous fibroids. Although fibroids of unusual locations are not illustrated in the current article, we have achieved successful experience in managing intra-ligamentous fibroids with IRCP. As the surgery is performed inside the pseudo-capsule, it effectively avoids injury of uterine blood vessels and ureters. Usually, the pseudo-capsule of intra-ligamentous fibroids is looser, it is easier and safer to perform IRCP.

Why the authors try to reduce the fibroid from the spheroid fibroid to lobulated shape? What is the real advantage?At the most they can fragment myoma, with all the problems that derive from it.

Response: We perform multiple rotary cuts on the fibroid in depths of 5-10 mm, shrinking the diameter of the tumor, instead of cutting the tumor into pieces. Therefore, the risk of dissemination is not increased.

But how does the pseudocapsule to squeeze the fibroid out of the myometrium ???

Response: The fibroid is pulled out by the instrument and squeezed out by the contraction of surrounding myometrium.

Minor Concerns:

How many WATTS do the authors select the electrosurgical unit to cut the pseudocapsule with scissors?

Response: 30 watts.

Thank you again for your effort.

Sincerely,

Ruifang Wu, M.D.

Email: wurf100@126.com

Department of Obstetrics and Gynecology, Peking University Shenzhen hospital, Shenzhen,  
Shenzhen, China. No.1120 Lian Hua Road, Shenzhen, 518036

China