

Journal of Visualized Experiments

The vessel-sparing excision and primary anastomosis

--Manuscript Draft--

Article Type:	Invited Methods Article - JoVE Produced Video
Manuscript Number:	JoVE58214R2
Full Title:	The vessel-sparing excision and primary anastomosis
Keywords:	Urethroplasty; urethral reconstruction; urethral stricture; bulbar urethral stricture; posterior urethral stricture; urethra; urethrography
Corresponding Author:	Nicolaas Lumen, M.D., Ph.D. Universitair Ziekenhuis Gent Gent, Vlaanderen BELGIUM
Corresponding Author's Institution:	Universitair Ziekenhuis Gent
Corresponding Author E-Mail:	Nicolaas.Lumen@uzgent.be
First Author:	Wesley Verla
Other Authors:	Wesley Verla
	Willem Oosterlinck
	Marjan Waterloos
	Nicolaas Lumen
Author Comments:	<p>Dear,</p> <p>I am Wesley Verla, first author and corresponding author of the submitted manuscript. I could not change the position of corresponding author to me, but communication may take place via Wesley.Verla@UGent.be.</p> <p>Because of problems with the author list, I had to add professor Lumen twice. The correct author list is the following:</p> <p>'Wesley Verla^{1,2}, Willem Oosterlinck¹, Marjan Waterloos¹, Nicolaas Lumen¹ ¹Department of Urology, Ghent University Hospital, C. Heymanslaan 10, 9000 Ghent, Belgium ²Corresponding Author: Wesley Verla Email Address: Wesley.Verla@UGent.be Tel: +32498083423'</p> <p>Kind regards.</p>
Additional Information:	
Question	Response
If this article needs to be "in-press" by a certain date, please indicate the date below and explain in your cover letter.	

The vessel-sparing excision and primary anastomosis: detailed technique and results

Wesley Verla^{1,2}, Willem Oosterlinck¹, Marjan Waterloos¹, Nicolaas Lumen¹

¹Department of Urology, Ghent University Hospital, C. Heymanslaan 10, 9000 Ghent, Belgium

²Corresponding Author: Wesley Verla

Email Address: Wesley.Verla@UGent.be

Tel: +32498083423

Willem Oosterlinck: willem.oosterlinck@ugent.be

Marjan Waterloos: marjan.waterloos@hotmail.com

Nicolaas Lumen: nicolaas.lumen@uzgent.be

KEYWORDS:

Urethroplasty, urethral reconstruction, urethral stricture, bulbar urethral stricture, posterior urethral stricture, urethra, urethrography

TITLE:

Vessel-Sparing Excision and Primary Anastomosis

AUTHORS & AFFILIATIONS:

Wesley Verla¹, Willem Oosterlinck¹, Marjan Waterloos¹, Nicolaas Lumen¹

¹Department of Urology, Ghent University Hospital, C. Heymanslaan 10, 9000 Ghent, Belgium

E-mail addresses of Co-Authors:

Willem Oosterlinck (willem.oosterlinck@ugent.be)

Marjan Waterloos (marjan.waterloos@hotmail.com)

Nicolaas Lumen (nicolaas.lumen@uzgent.be)

Corresponding author:

Wesley Verla (Wesley.Verla@UGent.be)

Tel: +32498083423

KEYWORDS:

Urethroplasty, urethral reconstruction, urethral stricture, bulbar urethral stricture, posterior urethral stricture, urethra, urethrography

SHORT ABSTRACT:

Here, we present an elaborate and efficient protocol to treat isolated short bulbar or posterior urethral strictures with vessel-sparing excision and primary anastomosis.

LONG ABSTRACT:

Urethroplasty is considered to be the standard treatment for urethral strictures since it provides excellent long-term success rates. For isolated short bulbar or posterior urethral strictures, urethroplasty by excision and primary anastomosis (EPA) is recommended. As EPA only requires the excision of the narrowed segment and the surrounding spongiositis, a full-thickness transection of the corpus spongiosum, as performed in the traditional transecting EPA (tEPA), is usually unnecessary. Jordan *et al.* introduced the idea of a vessel-sparing approach in 2007, aiming to reduce surgical trauma, especially to the dual arterial blood supply of the urethra, and, thus, potentially reducing the risk of postoperative erectile dysfunction or glans ischemia. This approach could also be beneficial for subsequent urethral interventions such as redo urethroplasty using a free graft, in which a well-vascularized graft bed is imperative. Nevertheless, these potential benefits are only assumptions as prospective studies comparing the functional outcome of both techniques with validated questionnaires are currently lacking. Moreover, vessel-sparing EPA (vsEPA) should at least be able to provide similar surgical outcomes as tEPA. The aim of this paper is to give an elaborate, step-by-step overview of how to manage patients with isolated short bulbar or posterior urethral strictures with vsEPA. The main objective of this manuscript is to outline the surgical technique and to report the representative surgical outcome. A total of 117 patients were managed according to the described protocol. The analysis was performed on the entire patient cohort and on the bulbar ($n = 91$) and posterior ($n = 26$)

vsEPA group separately. Success rates were 93.4% and 88.5% for the bulbar and posterior vsEPA, respectively. To conclude, vsEPA, as outlined in the protocol, provides excellent success rates with low complication rates for isolated short bulbar and posterior urethral strictures.

INTRODUCTION:

Urethroplasty is considered the standard treatment for urethral strictures as it provides excellent long-term success rates^{1,2}. A numerous amount of surgical techniques has been described, challenging the reconstructive urologist to choose the best approach, considering various stricture modalities such as the number of strictures, the stricture length, the stricture location, the etiology, comorbidities, and previous urethral interventions. For isolated short bulbar urethral strictures, the International Consultation on Urologic Diseases (ICUD) recommends urethroplasty by excision and primary anastomosis (EPA) associated with a composite success rate of 93.8%^{3,4}.

Urethroplasty by EPA embodies an approach in which the entire diseased segment of the urethra is removed and replaced by healthy adjacent urethra without the need for grafts or flaps to bridge the gap. Traditionally, this approach included the full thickness transection of the corpus spongiosum at the level of the stricture⁵. However, as EPA only requires the excision of the narrowed segment and the surrounding spongiofibrosis, a full thickness transection of the corpus spongiosum, and the dual urethral blood supply within it, is usually unnecessary. Given this background, Jordan *et al.* introduced the idea of a vessel-sparing approach in 2007, offering a non-transecting alternative to the classic transecting EPA (tEPA)^{6,7}. This vessel-sparing EPA (vsEPA) has been uprising ever since and several centers have—though slightly modified—implemented this technique in their surgical repertoire⁸⁻¹².

The vessel-sparing technique aims to reduce surgical trauma, especially to the dual arterial blood supply of the urethra embedded in the corpus spongiosum. The preservation of the bulbar arteries potentially reduces the risk of postoperative erectile dysfunction or glans ischemia. Furthermore, it could be beneficial for subsequent urethral interventions such as redo urethroplasty using a free graft, in which a well-vascularized graft bed is imperative^{8,9}. Nevertheless, these potential benefits are only assumptions as prospective studies comparing the functional outcome of both techniques with validated questionnaires are currently lacking.

As important as the functional outcome is, vsEPA should at least be able to provide similar surgical outcomes as tEPA. Promising short-term results have been published and are in line with the success rates reported by the ICUD, but a direct comparison between both techniques has, so far, not been performed^{3,4,8-12}.

Pelvic fracture-related urethral injuries are associated with scar tissue formation and a subsequent urethral stricture or complete obliteration of the membranous urethra. Posterior strictures might also develop after surgery or irradiation to the prostate¹³. For these strictures, urethroplasty with the excision of the scar tissue and bulbo-prostatic anastomosis is recommended as well¹⁴. Traditionally, the bulbar arteries were ligated during this procedure if not already obliterated due to the pelvic fracture. To avoid this, a vessel-sparing variant has been

introduced and reported as well^{15,16}.

The aim of this paper is to give an elaborate, step-by-step overview of how to manage patients with isolated short bulbar or posterior urethral strictures with vsEPA. The main scope is to outline and visualize the surgical technique and to report the representative surgical outcome. An evaluation of the functional outcome parameters is beyond the scope of this paper.

PROTOCOL:

All patients provided a signed written informed consent and the approval of the local Ethics Committee (EC/2014/0438) was obtained.

Note: The inclusion criteria for the presented protocol were: male; age ≥ 18 years; signed written informed consent; fit for operation; isolated urethral stricture; urethral stricture ≤ 3 cm; urethral stricture only at the bulbar or membranous site. The exclusion criteria were: female; transgender; age < 18 years; absence of signed written informed consent; unfit for operation; > 1 concomitant urethral strictures; urethral stricture > 3 cm; urethral stricture outside of the bulbar or membranous site.

1. Preoperative Work-up

1.1. Evaluate the patient through history taking, physical examination, and uroflowmetry followed by an ultrasonic residual volume measurement.

1.2. Confirm the presence of a stricture by urethrography (retrograde and/ or antegrade). If there is any doubt, additionally perform urethroscopy.

1.3. After the appropriate diagnosis, schedule patients with isolated short bulbar urethral strictures or with strictures at the membranous urethra for urethroplasty by vessel-sparing excision and primary anastomosis (vsEPA). Plan the surgery at least 3 months after any urethral manipulation including catheter use, dilation, or direct vision internal urethrotomy (DVIU). In the case of urinary retention, place a suprapubic catheter to ensure urinary derivation. In the case of pelvic fracture-related urethral injuries, perform urethroplasty at least 3 months after the initial trauma.

1.4. Perform preoperative investigations to evaluate the patient's fitness for operation as prescribed by local guidelines. If necessary, conduct therapeutic interventions accordingly.

1.5. One week before surgery, perform a urine culture with an antibiogram and, in the case of a urinary infection, start the appropriate antibiotics 24 h before surgery. If there is no urinary infection, administer a single shot of 1 g of cefazoline (dissolved in 10 cc of NaCl, 0.9%) intravenously (through the peripheral venous catheter using a 20-cc syringe and an 18 G needle) at the start of the operation.

1.6. Obtain routine venous thrombo-embolism prophylaxis by the administration of compression

stockings.

1.7. Keep the patients sober at least 6 h before surgery.

2. Initiation of Surgical Procedure

Note: The following steps take place after the surgical safety checklist and the administration of general anesthesia.

2.1. Patient's positioning

2.1.1. Place the patient on the operating table in a supine position.

2.1.2. Place the patient in a modified lithotomy position in which the knees and the hips are flexed 60 – 90° with 45° of abduction and the feet and calves are supported in supportive boots.

Make sure the patient's buttocks slightly pass the caudal border of the operating table to provide sufficient accessibility. Check extensively for areas with excessive compression to prevent neurovascular compression syndromes.

2.1.3. If necessary, obtain a 10 - 15° Trendelenburg position to fully visualize the diseased urethra.

2.2. Start-up of the surgical procedure

2.2.1. Shave and disinfect the exposed perineum and external genitals using an iodine-based scrub as antiseptic.

2.2.2. In the case of the presence of a suprapubic catheter, instill the bladder with 100 mL of diluted (10%) iodine-based scrub.

2.2.3. Create a sterile operating field by the administration of sterile drapes. Keep the operating field as small as possible and include the penis and scrotum without the anus. In the case of the presence of a suprapubic catheter, include this in the operating field to ensure suprapubic access to the urethra, if necessary.

2.2.4. As the surgeon is seated between the legs of the patient, position an assistant next to him/her and place the instrumentalist on the left side of the patient, handing over the instruments from above the operating field.

3. Surgical Procedure

3.1. Accessing the bulbar urethra

3.1.1. Make a midline perineal skin incision using a scalpel (blade number 24) and dissect the

subcutaneous fat tissue through Colles' fascia with a monopolar electrocauter (coagulation and cutting mode on 25 Watt and pure) until the bulbospongious muscle is encountered. Coagulate any bleeding vessels with the monopolar electrocauter.

3.1.2. Incise the bulbospongious muscle at the midline using a surgical blade number 24 and dissect it away from the underlying corpus spongiosum with Jones scissors.

3.1.3. Fix the bulbospongious muscle at the perineal skin using 4 silk 2-0 stay sutures and ensure further surgical exposure by a self-retaining retractor: attach the hooks of the elastic stays to the bulbospongious muscle, create sufficient traction, and secure the elastics to one of the slots of the retractor (**Figure 1**).

3.1.4. Identify the bulbar urethra.

3.2. Mobilization of the bulbar urethra

3.2.1. Dissect the bulbar urethra circumferentially in a sharp fashion with Jones scissors starting at the mid-bulbar region. Incise Buck's fascia on each side of the bulbar urethra with Jones scissors allowing a further dorsal dissection of the urethra and a detachment of the dorsal Buck's fascia from the tunica albuginea of the corpora cavernosa.

3.2.2. Encircle the bulbar urethra with a vessel loop and secure it with a Kocher clamp to facilitate manipulation (**Figure 2**).

3.2.3. First, continue the dorsal dissection and detachment in the distal direction, towards the penoscrotal angle. Use sharp scissors dissection, closely follow Buck's fascia in this dorsal detachment as it provides a rather avascular surgical plane. Coagulate the communicating vessels between the corpus spongiosum and the corpora cavernosa with a monopolar electrocauter.

3.2.4. Continue the dorsal dissection proximally, towards the urogenital diaphragm. Do not dissect the bulb of the corpus spongiosum at the anal side and leave the perineal body intact.

3.3. Opening of the stricture

3.3.1. Introduce a 20Fr silicone urethral catheter in the meatus urethrae and pass it up toward the distal extent of the urethral stricture.

3.3.2. At this level, open the urethra dorsally in a longitudinal fashion (dorsal stricturotomy) using a scalpel (blade number 15).

3.3.3. Place 2 silk 3-0 stay sutures (1 on each side of the opened urethra) to facilitate the exposure of the urethral lumen.

3.3.4. Insert a 3Fr ureteral catheter through the dorsally-opened urethra and pass it up

proximally through the strictured area.

3.3.5. Further open the stricture on this 3Fr ureteral catheter using Jones scissors or a surgical blade number 15 until healthy urethral tissue is encountered.

3.3.6. Evaluate the patency and caliber of the proximal urethra by introducing a 20Fr metal sound and move it up toward the bladder.

3.3.7. Place 2 silk 3-0 stay sutures (1 on each side) on the opened proximal urethra.

3.3.8. For bulbar strictures, resect the stricture as well as the surrounding spongiositis using Jones scissors until healthy spongy tissue is encountered ventrally. Leave this healthy spongy tissue intact.

3.3.9. For strictures at the membranous urethra, fully resect the scar tissue using Jones scissors or a surgical blade number 15 until the apex of the prostate is reached. After the removal of the suprapubic catheter, introduce a cystoscope through the suprapubic tract to facilitate the identification of the prostatic apex.

3.4. Urethral anastomosis

3.4.1. If necessary, split the corpora cavernosa to shorten the distance towards the proximal urethra. Use a surgical blade number 15 on the midline between the corpora cavernosa and once the avascular plane between both corpora is encountered, continue with a blunt dissection.

3.4.2. Grasp the urethral mucosa with a DeBakey forceps with a large grip.

3.4.3. In the case of a bulbar stricture

3.4.3.1. Create the ventral urethral plate by suturing the ventral ends of the proximal and distal urethra from the inside of the urethral lumen using interrupted 4-0 sutures (polyglactin 910).

3.4.3.2. Dorsally, spatulate the healthy urethral edges for about 1 cm using Jones scissors and remove the stay sutures.

3.4.3.3. Close the dorsal edges of the urethral ends transversely over a 20Fr silicone urethral catheter with interrupted 4-0 sutures (polyglactin 910).

3.4.3.4. Close the corpus spongiosum over the urethra (spongiosoplasty) using 4-0 sutures (polyglactin 910).

3.4.4. In the case of a stricture or obliteration at the membranous urethra

3.4.4.1. Spatulate the distal urethral end dorsally and the proximal urethral end ventrally over 1

cm using Jones scissors.

3.4.4.2. Place eight 4-0 sutures (polyglactin 910) and pass a 20Fr silicone urethral catheter into the bladder.

3.5. Catheter drain and wound closure

3.5.1. Leave a 20Fr silicone urethral catheter in place.

3.5.2. Leave a 10Fr suction drain behind between the corpus spongiosum and the bulbospongiosus muscle. Perforate the skin of the right inguinal region with the 10Fr drain needle. Cut the needle off.

3.5.3. Cut the stay sutures with Mayo-Stille scissors, remove the retractor, and close the bulbospongiosus muscle over the underlying urethra, corpus spongiosum, and suction drain using a 3-0 running suture (polyglactin 910).

3.5.4. Suture Colles' fascia in a running fashion, also using a 3-0 suture (polyglactin 910). Suture the skin with interrupted Donati stitches using 3-0 sutures (polyglactin 910).

3.5.5. Fix the suction drain at the groin using a silk 2-0 suture and attach the suction drain to the vacuum flask. Apply a perineal compressive dressing.

3.5.6. Flip the penis and transurethral catheter toward the lower abdomen and keep them in place by supporting and compressive underwear.

3.5.7. If a suprapubic catheter was present, remove this, except in the case of previous irradiation.

4. Postoperative Care

4.1. After recovery, bring the patient to his room and provide standard postoperative care.

4.2. Remove the suction drain after 24 h.

4.3. In the case of a preoperatively established urinary infection, continue the antibiotic treatment regimen as prescribed.

4.4. Disinfect the perineal wound repeatedly and use a hair dryer 3 - 5x a day to keep the wound dry and neat.

4.5. In the case of no major complications, discharge the patient from the hospital on postoperative day 2 with the indwelling transurethral catheter in place. Give further instructions, especially regarding wound care, and foresee an appointment to remove the catheter.

5. Follow-up Visits

5.1. After 7 (simple repair) to 14 days (irradiated cases), perform a voiding cystourethrography (VCUG) and, if there is no or insignificant contrast leakage, remove the transurethral catheter. In the case of significant extravasation, replace the transurethral catheter and perform the VCUG again 1 week later.

5.2. Schedule follow-up visits 3 months postoperatively, 12 months postoperatively, and annually thereafter. During these visits, evaluate the patient through history taking, a physical examination, uroflowmetry, and an ultrasonic residual volume measurement. Perform further technical investigations such as retrograde urethrography (RUG), VCUG, or urethroscopy only in the case of arguments for stricture recurrence such as symptoms, an obstructive voiding curve, or high residual urinary volumes.

5.3. Define surgical failure as stricture recurrence requiring additional urethral manipulation, including dilation.

REPRESENTATIVE RESULTS:

Between 2011 and 2017, a total of 117 patients with isolated short bulbar ($n = 91$) or posterior ($n = 26$) urethral strictures were treated with vsEPA at Ghent University Hospital. The baseline characteristics are displayed in **Table 1**. The median follow-up was 35 and 45 months for bulbar and posterior strictures, respectively. The strictures were longer in the patients who underwent posterior vsEPA and, accordingly, the number of patients with a calculated U-score of 5 was higher in this group¹⁷. In contrast to the bulbar vsEPA group, posterior strictures were predominantly traumatic (57.7%), whereas the bulbar vsEPA group mainly consisted of idiopathic urethral strictures (45.3%). Iatrogenic strictures at the bulbar site were largely caused by prior catheter use (6.6%) or a transurethral resection of the prostate (TURP) (18.7%), whereas posterior strictures occurred after irradiation, radical prostatectomy, or TURP in respectively 5 (19.2%), 3 (11.5%), and 4 (15.4%) patients. Traumatic posterior strictures were documented as 'complete obliteration' and 'incomplete obliteration' in, respectively, 5 (19.2%) and 10 (38.5%) patients. Seven of these patients were treated with a prior realignment procedure (2 open and 5 endoscopically) after the initial urethral disruption injury. A vast majority of the total patient cohort (82.1%) underwent prior urethral interventions, either open or endoscopically. The posterior vsEPA group, however, contained more patients without any former urethral intervention. Furthermore, the presence of a suprapubic catheter and a urinary infection was higher in the patients with posterior urethral strictures.

Per- and postoperative characteristics are displayed in **Table 2**. The median hospital stay and the catheter dwell time were 2 and 10 days, respectively. The operation time and the catheter stay were longer in the posterior vsEPA group. A total of 7 patients (6.6%) showed significant extravasation at the first VCUG and needed a catheter reinsertion for at least 1 week. The complication rate (23.9%) was comparable between the groups and mainly consisted of low-grade complications (Clavien-Dindo grade 1 - 2: 23.0%) such as wound dehiscence, wound

infection, urinary infection, bladders spasms, and hematoma. One of the encountered hematomas required surgical drainage under general anesthesia and was categorized as a 3b complication according to the Clavien-Dindo classification¹⁸.

Nine patients (7.7%), consisting of 6 patients (6.6%) from the bulbar vsEPA group and 3 patients (11.5%) from the posterior vsEPA group, were considered a surgical failure. Two failures were observed between the second and the fifth postoperative year. The estimated failure-free survival was 95.3%, 95.3%, and 87.0% at, respectively, 1, 2, and 5 years for the bulbar vsEPA group, and 88.3% at 1, 2, and 5 years for the posterior vsEPA group. A Kaplan-Meier curve was constructed and illustrates the failure-free survival rate (**Figure 3**). The salvage treatment of recurrent urethral strictures consisted of redo urethroplasty, DVIU, dilation, and a combination of urethroplasty and DVIU in, respectively, 5, 2, 1, and 1 patients.

FIGURE AND TABLE LEGENDS:

Figure 1: Exposure of the bulbar urethra with a self-retaining retractor.

Figure 2: Mobilization of the bulbar urethra with a vessel loop.

Figure 3: Kaplan-Meier curve for the failure-free survival. vsEPA = vessel-sparing excision and primary anastomosis.

Table 1: Baseline characteristics. vsEPA = vessel-sparing excision and primary anastomosis; IQR = interquartile range; cm = centimeters; TURP = transurethral resection of the prostate; DVIU = direct vision internal urethrotomy

Table 2: Per- and postoperative characteristics. vsEPA = vessel-sparing excision and primary anastomosis; min = minutes; IQR = interquartile range; VCUG = voiding cystourethrography; SD = standard deviation; FFS = failure-free survival

DISCUSSION:

Urethral stricture repair by vessel-sparing excision and primary anastomosis was initially performed at Ghent University Hospital in 2010. Thereafter, it became a standard of practice in the hospital's management of patients with isolated short bulbar or posterior urethral strictures. As the bulb remains attached to the perineal body, access to the posterior urethra and the resection of the fibrotic tissue at that site can be compromised. A distortion of the pubic rami due to a pelvic fracture might further impede accessibility. If this is the case and a full resection cannot be accomplished because of poor access, a peroperative decision is made to perform a transecting procedure with the ligation of the bulbar arteries and the detachment of the bulb away from the perineal body. The described protocol gives an elaborate, step-by-step overview of the experience at Ghent University Hospital, a tertiary referral center for urethral stricture disease.

Although the protocol offers an extensive description, some crucial steps call for extra attention.

A successful procedure starts with a correct indication. Patients with isolated short bulbar or posterior urethral strictures are ideal candidates for this approach^{3,4,14-16}.

In order to successfully perform an anastomotic repair urethroplasty, both urethral ends need to be well-vascularized and the anastomosis must be completed in a tension-free way. Therefore, as the bulbar urethra has a limited elasticity, traditionally, only strictures up to 3 cm were treated with EPA. In 2006, however, Morey *et al.* reported equivalent success rates in strictures of up to 5 cm treated with anastomotic repair urethroplasty^{3,4,19}. By splitting the corpora cavernosa, strictures up to 5 cm might indeed be treated successfully with EPA.

Nevertheless, the patient series investigated by Morey *et al.* consisted of 11 patients in each group and the mean follow-up was only 22 months. Furthermore, the estimation of the stricture length based upon preoperative investigations should be interpreted carefully, as conventional urethrography might underestimate the actual stricture length at the bulbar site. Nash *et al.* reported a correlation of only 0.69 between conventional urethrography and peroperative length measurements of bulbar urethral strictures²⁰. The telescopic effect in a two-dimensional urethrogram and the different stricture appearances according to the patient's positioning and penile traction might explain this result²⁰.

An underestimation of the stricture length might lead to a peroperative conversion from an anastomotic repair to an augmented repair using a free graft or a pedicled flap. Since the procedure involves a dorsal stricturotomy, a conversion towards a dorsal onlay graft urethroplasty ('Barbagli procedure') is most likely^{21,22}. For this reason, it is of the greatest importance that the surgeon performing the operation masters a variety of urethroplasty techniques in order to address this issue.

Another point of attention is timing, as the introduction of even a small caliber instrument in the urethra may rupture the stricture, causing a significant problem in determining the distal extent of the urethral stricture as discussed in step 3.3.1. This, in turn, could lead to an insufficient urethroplasty procedure leaving fibrotic tissue, and, thus, stricture disease, behind. Therefore, any urethral manipulation must be avoided at least 3 months before surgery²³.

Regarding surgical technique, the described procedure differs from the original vessel-sparing variant of Jordan *et al.* in which the bulbar arteries are dissected free at the bulb of the corpus spongiosum in order to retract them⁶. In fact, this is unnecessary, time-consuming, and causes more surgical trauma⁸. Furthermore, the duration of the catheter stay forms another important issue but is still a matter of debate. However, Poelaert *et al.* concluded that in uncomplicated cases, the catheter can be removed safely after 8 - 10 d postoperatively²⁴.

Regarding the reported results, the bulbar and posterior vsEPA were also considered separately. Comparing these groups is not the focus of this paper, as it is clinically irrelevant, given the fundamentally different nature of the stricture etiology, pathogenesis, and management. Nevertheless, some noteworthy differences were encountered and are worth putting in perspective. The differences in follow-up are most likely coincidental, but the longer strictures in

the posterior vsEPA group can be explained by the fact that the posterior strictures were predominantly caused by pelvic trauma resulting in urethral disruption injuries and the subsequent obliteration or extensive stricture formation at the membranous urethra²⁵. This can also explain the higher U-score of the posterior vsEPA group, as this score is partly based on the stricture length¹⁷. Posterior urethral strictures caused by external trauma are—in acute setting—managed with the placement of a suprapubic catheter to ensure urinary derivation and to reduce the risk of urinary extravasation¹⁴. This, in turn, explains the differences in the presence of suprapubic catheters and, as suprapubic catheters involve a substantial risk of infection, the differences in preoperatively established urinary infections. Due to the more complex character of the strictures in the posterior vsEPA group, their operation time and catheter stay were longer. Posterior strictures require further proximal dissection and a cystoscope can be introduced in the suprapubic tract to facilitate the identification of the prostatic apex which further contributes to a longer operation time in these patients. The complication rate was low and mainly consisted of low-grade complications, which is in line with the experience at other centers¹⁰.

Nine patients, consisting of 6 patients from the bulbar vsEPA group and 3 patients from the posterior vsEPA group, were considered a surgical failure. This corresponds to a success rate of 93.4% and 88.5% for the bulbar and the posterior vsEPA group, respectively. These results are in line with the success rates reported by the ICUD and other centers^{3,4,8-12,14-16}. Although Andrich *et al.* reported failures to occur within the first year after surgery, 2 failures were observed between the second and the fifth postoperative year, underlining the need for a prolonged follow-up in these patients, which is in line with suggestions from Han *et al.*^{26,27}. It is plausible that a rigid follow-up scheme with cystoscopy would lead to earlier diagnoses of recurrence²⁸. However, every transurethral procedure, even flexible cystoscopy, is potentially harmful to the urethra. Both this and the prevention of overusing technical investigations are the rationale behind the follow-up scheme at Ghent University Hospital, administering further technical investigations only in the case of a suspicion of stricture recurrence.

The major limitation of vsEPA is the anastomosis: it is of the utmost importance to complete the anastomosis without any tension and with 2 well-vascularized urethral ends. Even by splitting the corpora cavernosa, this technique is limited to strictures up to 5 cm. Furthermore, in posterior urethral strictures, the bulbar arteries, as well as the cavernous vasculo-nervous bundles, may already be obliterated due to the pelvic fracture, abolishing the potential benefits of a vessel-sparing approach. Moreover, the anatomical proximity of the membranous urethra to the cavernous vasculo-nervous bundles and the urinary sphincter should be taken into account and, if possible, a sphincter-sparing variant of posterior vsEPA might be superior in terms of continence preservation²⁹. In addition, Blakely *et al.* reported dorsal onlay graft urethroplasty to be beneficial for continence preservation as well, though in a limited number of patients ($n = 16$)³⁰. Future studies directly comparing the surgical outcome of the vessel-sparing and transecting technique are required, as are studies comparing the functional outcome of both techniques with validated questionnaires. So far, Le *et al.* performed a randomized controlled trial (RCT) in 23 patients with traumatic posterior urethral strictures¹⁵. In the near future, an RCT will be set up for bulbar urethral strictures in which vsEPA and tEPA will be compared for both their surgical and functional outcome.

To conclude, vsEPA, as outlined in the protocol, provides excellent success rates with low complication rates for isolated short bulbar and posterior urethral strictures.

ACKNOWLEDGMENTS:

The authors have no acknowledgments.

DISCLOSURES:

The authors have nothing to disclose.

REFERENCES:

1. Hampson, L.A., McAninch, J.W., Breyer, B.N. Male urethral strictures and their management. *Nature Reviews Urology*. **11** (1), 43-50 (2014).
2. Andrich, D.E., Mundy, A.R. What is the Best Technique for Urethroplasty? *European Urology*. **54** (5), 1031-1041 (2008).
3. Chapple, C. *et al.* SIU/ICUD Consultation on Urethral Strictures: The Management of Anterior Urethral Stricture Disease Using Substitution Urethroplasty. *Urology*. **83** (3), S31-S47 (2014).
4. Morey, A.F., Watkin, N., Shenfeld, O., Eltahawy, E., Giudice, C. SIU/ICUD Consultation on Urethral Strictures: Anterior Urethra – Primary Anastomosis. *Urology*. **83** (3), S23-S26 (2014).
5. Mundy, A.R. Anastomotic urethroplasty. *BJU International*. **96** (6), 921-944 (2005).
6. Jordan, G.H., Eltahawy, E.A., Virasoro, R. The Technique of Vessel Sparing Excision and Primary Anastomosis for Proximal Bulbous Urethral Reconstruction. *The Journal of Urology*. **177** (5), 1799-1802 (2007).
7. Gur, U., Jordan, G.H. Vessel-sparing excision and primary anastomosis (for proximal bulbar urethral strictures). *BJU International*. **101** (9), 1183-1195 (2008).
8. Andrich, D.E., Mundy, A.R. Non-transecting anastomotic bulbar urethroplasty: a preliminary report. *BJU International*. **109** (7), 1090-1094 (2012).
9. Lumen, N. *et al.* Nontransecting Anastomotic Repair in Urethral Reconstruction: Surgical and Functional Outcomes. *The Journal of Urology*. **196** (6), 1679-1684 (2016).
10. Virasoro, R. *et al.* International multi-institutional experience with the vessel-sparing technique to reconstruct the proximal bulbar urethra: mid-term results. *World Journal of Urology*. **33** (12), 2153-2157 (2015).
11. Bugeja, S., Andrich, D.E., Mundy, A.R. Non-transecting bulbar urethroplasty. *Translational Andrology and Urology*. **4** (1), 41-50 (2015).

529

530 12. Anderson, K.M., Blakely, S.A., O'Donnell, C.I., Nikolavsky, D., Flynn, B.J. Primary non-
531 transecting bulbar urethroplasty long-term success rates are similar to transecting urethroplasty.
532 *International Urology and Nephrology*. **49** (1), 83-88 (2017).

533

534 13. Summerton, D.J., Kitrey, N.D., Lumen, N., Serafetinidis, E., Djakovic, N., European Association
535 of Urology. EAU guidelines on iatrogenic trauma. *European Urology*. **62** (4), 628-639 (2012).

536

537 14. Gómez, R.G. *et al.* SIU/ICUD Consultation on Urethral Strictures: Pelvic Fracture Urethral
538 Injuries. *Urology*. **83** (3), S48-S58 (2014).

539

540 15. Le, W., Li, C., Zhang, J., Wu, D., Liu, B. Preliminary clinical study on non-transecting
541 anastomotic bulbomembranous urethroplasty. *Frontiers in Medicine*. **11** (2), 277-283 (2017).

542

543 16. Gomez, R.G., Campos, R.A., Velarde, L.G. Reconstruction of Pelvic Fracture Urethral Injuries
544 With Sparing of the Bulbar Arteries. *Urology*. **88**, 207-212 (2016).

545

546 17. Eswara, J.R. *et al.* Refinement and validation of the urethral stricture score in categorizing
547 anterior urethral stricture complexity. *Urology*. **85** (2), 474-477 (2015).

548

549 18. Dindo, D., Demartines, N., Clavien, P.-A. Classification of surgical complications: a new
550 proposal with evaluation in a cohort of 6336 patients and results of a survey. *Annals of Surgery*.
551 **240** (2), 205-213 (2004).

552

553 19. Morey, A.F., Kizer, W.S. Proximal Bulbar Urethroplasty Via Extended Anastomotic Approach—
554 What Are the Limits? *The Journal of Urology*. **175** (6), 2145-2149 (2006).

555

556 20. Nash, P.A., McAninch, J.W., Bruce, J.E., Hanks, D.K. Sono-Urethrography in the Evaluation of
557 Anterior Urethral Strictures. *The Journal of Urology*. **154** (1), 72-76 (1995).

558

559 21. Wang, K., Miao, X., Wang, L., Li, H. Dorsal onlay versus ventral onlay urethroplasty for anterior
560 urethral stricture: a meta-analysis. *Urologia Internationalis*. **83** (3), 342-348 (2009).

561

562 22. Barbagli, G., Selli, C., Tosto, A., Palminteri, E. Dorsal Free Graft Urethroplasty. *The Journal of*
563 *Urology*. **155** (1), 123-126 (1996).

564

565 23. Oosterlinck, W., Lumen, N., Van Cauwenberghe, G. Surgical treatment of urethral stenoses:
566 technical aspects. *Annales d'Urologie* (Paris). **41** (4), 173-207 (2007).

567

568 24. Poelaert, F., Oosterlinck, W., Spinoit, A.-F., Lumen, N. Duration of urethral catheterization
569 after urethroplasty: how long is enough? *Minerva Urologica e Nefrologica*. **69** (4), 372-376 (2017).

570

571 25. Barbagli, G., Sansalone, S., Romano, G., Lazzeri, M. Bulbar urethroplasty: transecting vs.
572 nontransecting techniques. *Current Opinion in Urology*. **22** (6), 474-477 (2012).

573
574
575
576
577
578
579
580
581
582
583
584
585
586
587
588
589

26. Andrich, D.E., Duglison, N., Greenwell, T.J., Mundy, A.R. The Long-Term Results of Urethroplasty. *The Journal of Urology*. **170** (1), 90-92 (2003).

27. Han, J.S. *et al.* Risk of urethral stricture recurrence increases over time after urethroplasty. *International Journal of Urology*. **22** (7), 695-699 (2015).

28. Erickson, B.A. *et al.* Multi-institutional 1-year bulbar urethroplasty outcomes using a standardized prospective cystoscopic follow-up protocol. *Urology*. **84** (1), 213-216 (2014).

29. Angulo, J.C., Gómez, R.G., Nikolavsky, D. Reconstruction of Membranous Urethral Strictures. *Current Urology Reports*. **19** (6), 37 (2018).

30. Blakely, S., Caza, T., Landas, S., Nikolavsky, D. Dorsal Onlay Urethroplasty for Membranous Urethral Strictures: Urinary and Erectile Functional Outcomes. *The Journal of Urology*. **195** (5), 1501-1507 (2016).

Figure 1

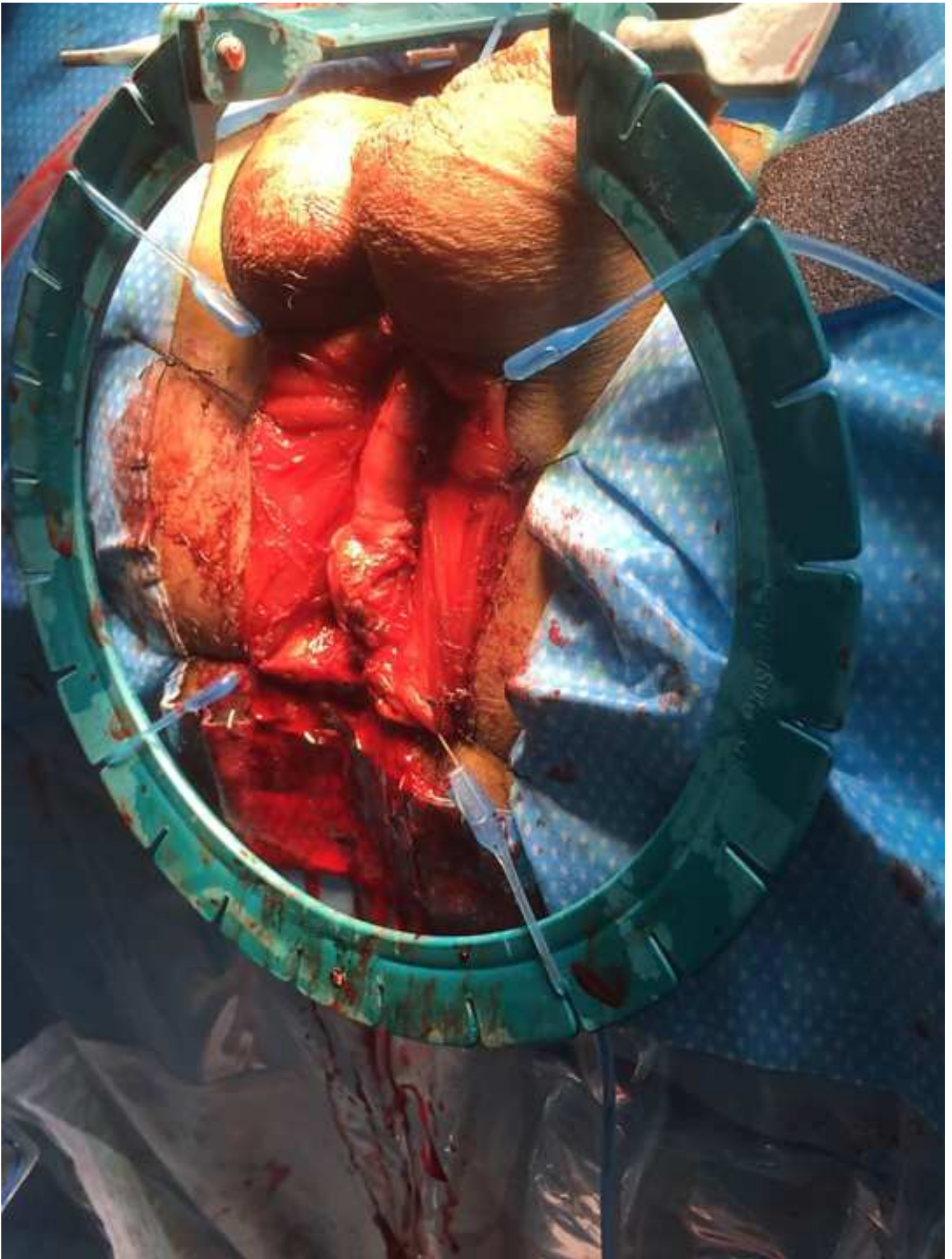


Figure 2

[Click here to download Figure Fig. 2 Mobilization of the bulbar urethra with vessel loop.tiff](#)

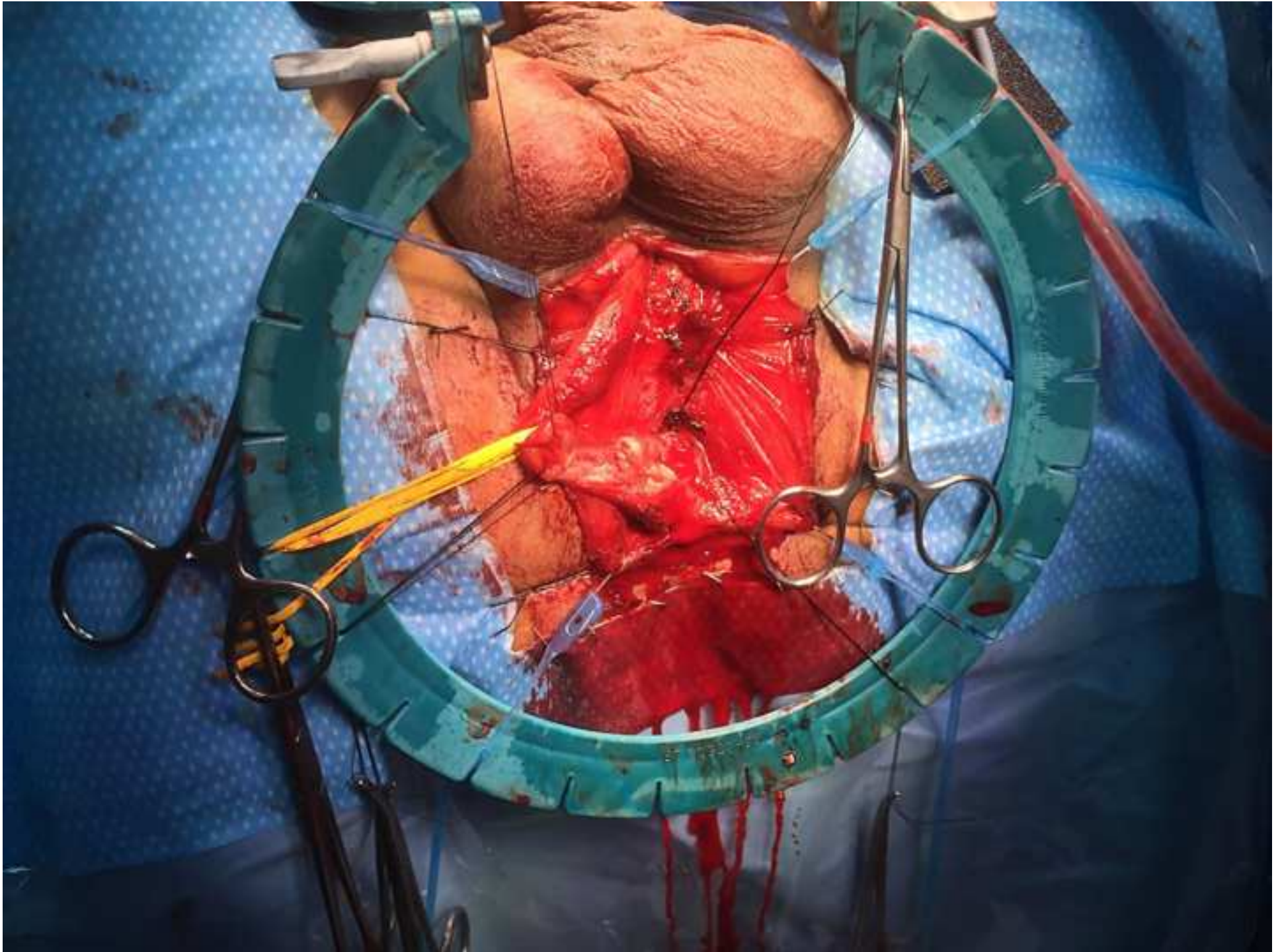
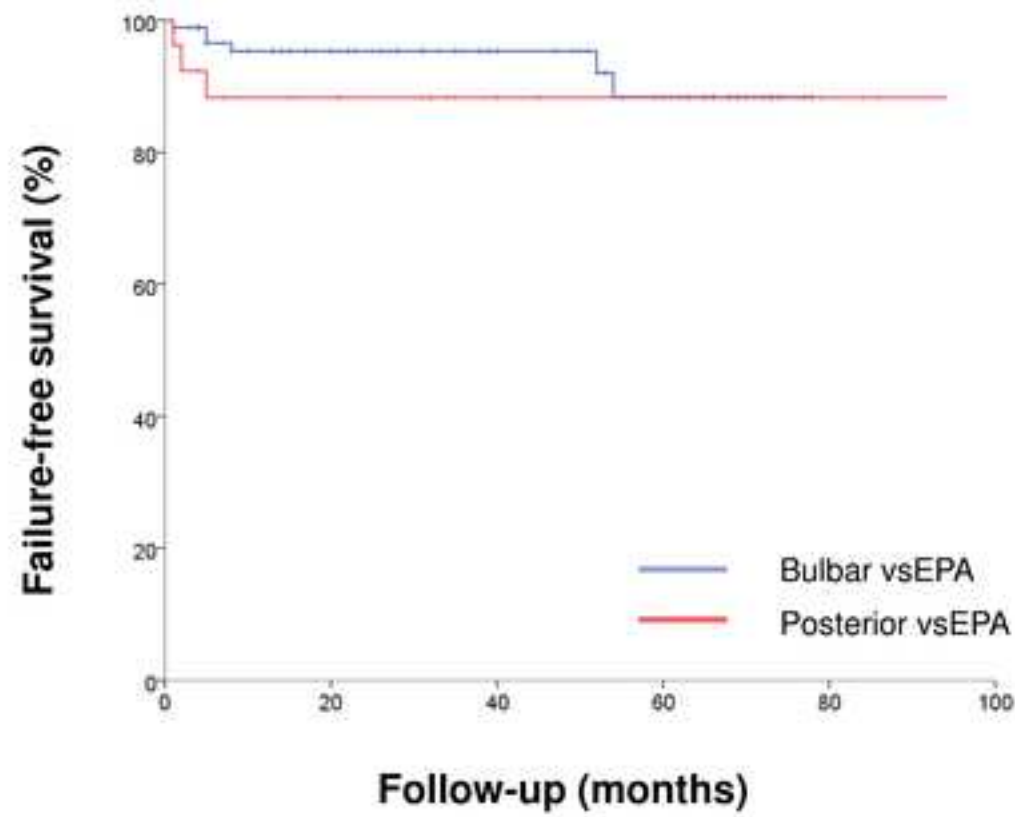


Figure 3

[Click here to download Figure Fig. 3 Kaplan-Meier curve for failure-free survival_revised.tif](#)



Total vsEPA (n = 117)	
Median age (years) (IQR)	47 (30 - 66)
Median follow-up (months) (IQR)	38 (17 - 64)
Median stricture length (cm) (IQR)	1.5 (1.0 - 2.0)
Etiology n (%)	
Idiopathic	53 (45.3)
Iatrogenic	37 (31.6)
Catheter	7 (6.0)
TURP	19 (16.2)
Radical prostatectomy	4 (3.4)
Irradiation	2 (1.7)
TURP + irradiation	3 (2.6)
Radical prostatectomy + irradiation	1 (0.9)
Failed hypospadias repair	1 (0.9)
External trauma	23 (19.7)
Inflammatory	4 (3.4)
U-score n (%)	
4	96 (82.1)
5	20 (17.1)
6	1 (0.9)
Prior interventions n (%)	
None	21 (17.9)
1 DVIU or dilation	33 (28.2)
> 1 DVIU or dilation	41 (35.0)
Urethroplasty	4 (3.4)
Urethroplasty + DVIU or dilation	18 (15.4)
Comorbidity n (%)	
Smoking	13 (11.6)
Diabetes	8 (7.2)
Cardial comorbidity	20 (17.9)
Vascular comorbidity	16 (14.3)
Presence of suprapubic catheter n (%)	27 (23.1)
Preoperative urinary infection n (%)	27 (23.1)

Bulbar vsEPA (n = 91)	Posterior vsEPA (n = 26)
44 (29 - 63)	59 (29 - 73)
35 (15 - 59)	45 (32 - 77)
1.5 (1.0 - 2.0)	2.0 (1.5 - 3.3)
52 (57.1)	1 (3.8)
27 (29.7)	10 (38.5)
6 (6.6)	1 (3.8)
17 (18.7)	2 (7.7)
2 (2.2)	2 (7.7)
0	2 (7.7)
1 (1.1)	2 (7.7)
0	1 (3.8)
1 (1.1)	0
8 (8.8)	15 (57.7)
4 (4.4)	0
82 (90.1)	14 (53.8)
9 (9.9)	11 (42.3)
0	1 (3.8)
11 (12.1)	10 (38.5)
27 (29.7)	6 (23.1)
33 (36.3)	8 (30.8)
4 (4.4)	0
16 (17.6)	2 (7.7)
9 (10.3)	4 (16.0)
4 (4.6)	4 (15.4)
12 (13.8)	8 (32.0)
11 (12.6)	5 (20.0)
16 (17.6)	11 (42.3)
12 (13.2)	15 (57.7)

Total vsEPA (n = 117)	
Median operation time (min) (IQR)	94 (80 - 108)
Median hospital stay (days) (IQR)	2 (1 - 2)
Median catheter stay (days) (IQR)	10 (8 - 15)
Significant extravasation at first VCUG n (%)	7 (6.6)
Complications (Clavien-Dindo) n (%)	
None	89 (76.1)
Grade 1	17 (14.5)
Grade 2	10 (8.5)
Grade 3	1 (0.9)
Failure n (%)	9 (7.7)
Estimated failure-free survival % (SD)	
1y-FFS	
2y-FFS	
5y-FFS	

Bulbar vsEPA (n = 91)	Posterior vsEPA (n = 26)
87 (73 - 100)	109 (100 - 135)
2 (1 - 2)	2 (2 - 3)
9 (8 - 14)	14 (11 - 16)
6 (7.4)	1 (3.8)
68 (74.7)	21 (80.8)
14 (15.4)	3 (11.5)
8 (8.8)	2 (7.7)
1 (1.1)	0
6 (6.6)	3 (11.5)
95.3 (2.3)	88.3 (6.4)
95.3 (2.3)	88.3 (6.4)
88.3 (5.2)	88.3 (6.4)

Name of Material/ Equipment	Company	Catalog Number	Comments/Description
iso-Betadine Dermicum 125 ml (1)	Meda Pharma	A-472825	
Sterile gown (3)	According to surgeon's preference	NA	
Sterile gloves (3 pairs)	According to surgeon's preference	NA	
Sterile drapes (4)	Medline	AGBBA073A	
Bard-Parker scalpel number 3 (1)	Zepf Medical Instruments	06-1003-00	
Bard-Parker scalpel number 4 (1)	KLS Martin Group	10-100-04	
Scalpel blade number 15 (1)	Swann-Morton	0205	
Scalpel blade number 24 (1)	Swann-Morton	0211	
Surgical forceps 14 cm (2)	KLS Martin Group	12-301-14	
Monopolar electrocauter Valleylab (1)	Medtronic	E2100	
Electrocauter blade 15 cm (1)	Comepa	CO 150i	
Debakey forceps 20 cm (2)	Düfner	06232-20	
3-layered compress 30 x 45 cm (5)	Mölnlycke Health Care	175260	
Surgical compress 10 x 10 cm (10)	Hartmann	232088	
Mayo-Hegar needle driver 18 cm (1)	Zepf Medical Instruments	24-1804-18	
Mayo-Hegar needle driver 25 cm (1)	Zepf Medical Instruments	24-1804-25	
Jones scissor 18 cm (1)	Düfner	04940-18	
Mayo-Stille scissor 17 cm (1)	Zepf Medical Instruments	08-1700-17	
Lone Star retractor (1)	CooperSurgical, Trumbull, CT, USA	72403867	
Lone Star elastic stays (4)	CooperSurgical, Trumbull, CT, USA	3311-1G	
Vessel loop 45 cm (1)	Braun	1095137	
Halsted-Mosquito (6)	KLS Martin Group	13-317-21	
20Fr silicone urethral catheter (1)	Yushin Medical Co.	1037B-20	
3Fr ureteral catheter (1)	Teleflex	223602	
20Fr metal sound (1)	Custom made	NA	
Vicryl 4-0 wire (6)	Ethicon	V734D	
Vicryl 3-0 wire (2)	Ethicon	VCP316H	
Vicryl Rapide 3-0 wire (1)	Ethicon	VF2260	

10Fr Drain needle (1)	Vygon	658.10
10Fr Suction drain (1)	Oriplast	203102
Vacuum flask 400 ml (1)	Oriplast	213215AL/QL
Zetuvit 10 x 20 cm (1)	Hartmann	413771



1 Alewife Center #200
Cambridge, MA 02140
tel. 617.945.9051
www.jove.com

ARTICLE AND VIDEO LICENSE AGREEMENT

Title of Article:

THE VESSEL-SAVING EXCISION AND PRIMARY ANASTOMOSIS

DETAILED
TECHNIQUE
AND RESULTS

Author(s):

W. Verbe, W. Oosterlinck, M. Waterloot, N. Lumen

Item 1 (check one box): The Author elects to have the Materials be made available (as described at

<http://www.jove.com/author>) via: ☒ Standard Access ☐ Open Access

Item 2 (check one box):



The Author is NOT a United States government employee.



The Author is a United States government employee and the Materials were prepared in the course of his or her duties as a United States government employee.



The Author is a United States government employee but the Materials were NOT prepared in the course of his or her duties as a United States government employee.

ARTICLE AND VIDEO LICENSE AGREEMENT

1. **Defined Terms.** As used in this Article and Video License Agreement, the following terms shall have the following meanings: “**Agreement**” means this Article and Video License Agreement; “**Article**” means the article specified on the last page of this Agreement, including any associated materials such as texts, figures, tables, artwork, abstracts, or summaries contained therein; “**Author**” means the author who is a signatory to this Agreement; “**Collective Work**” means a work, such as a periodical issue, anthology or encyclopedia, in which the Materials in their entirety in unmodified form, along with a number of other contributions, constituting separate and independent works in themselves, are assembled into a collective whole; “**CRC License**” means the Creative Commons Attribution-Non Commercial-No Derivs 3.0 Unported Agreement, the terms and conditions of which can be found at: <http://creativecommons.org/licenses/by-nc-nd/3.0/legalcode>; “**Derivative Work**” means a work based upon the Materials or upon the Materials and other pre-existing works, such as a translation, musical arrangement, dramatization, fictionalization, motion picture version, sound recording, art reproduction, abridgment, condensation, or any other form in which the Materials may be recast, transformed, or adapted; “**Institution**” means the institution, listed on the last page of this Agreement, by which the Author was employed at the time of the creation of the Materials; “**JoVE**” means MyJoVE Corporation, a Massachusetts corporation and the publisher of *The Journal of Visualized Experiments*; “**Materials**” means the Article and / or the Video; “**Parties**” means the Author and JoVE; “**Video**” means any video(s) made by the Author, alone or in conjunction with any other parties, or by JoVE or its affiliates or agents, individually or in collaboration with the Author or any other parties, incorporating all or any portion of the Article, and in which the Author may or may not appear.

2. **Background.** The Author, who is the author of the Article, in order to ensure the dissemination and protection of the Article, desires to have the JoVE publish the Article and create and transmit videos based on the Article. In furtherance of such goals, the Parties desire to memorialize in this Agreement the respective rights of each Party in and to the Article and the Video.

3. **Grant of Rights in Article.** In consideration of JoVE agreeing to publish the Article, the Author hereby grants to JoVE, subject to **Sections 4 and 7** below, the exclusive, royalty-free, perpetual (for the full term of copyright in the Article, including any extensions thereto) license (a) to publish, reproduce, distribute, display and store the Article in all forms, formats and media whether now known or hereafter developed (including without limitation in print, digital and electronic form) throughout the world, (b) to translate the Article into other languages, create adaptations, summaries or extracts of the Article or other Derivative Works (including, without limitation, the Video) or Collective Works based on all or any portion of the Article and exercise all of the rights set forth in (a) above in such translations, adaptations, summaries, extracts, Derivative Works or Collective Works and (c) to license others to do any or all of the above. The foregoing rights may be exercised in all media and formats, whether now known or hereafter devised, and include the right to make such modifications as are technically necessary to exercise the rights in other media and formats. If the “Open Access” box has been checked in **Item 1** above, JoVE and the Author hereby grant to the public all such rights in the Article as provided in, but subject to all limitations and requirements set forth in, the CRC License.

ARTICLE AND VIDEO LICENSE AGREEMENT

4. Retention of Rights in Article. Notwithstanding the exclusive license granted to JoVE in **Section 3** above, the Author shall, with respect to the Article, retain the non-exclusive right to use all or part of the Article for the non-commercial purpose of giving lectures, presentations or teaching classes, and to post a copy of the Article on the Institution's website or the Author's personal website, in each case provided that a link to the Article on the JoVE website is provided and notice of JoVE's copyright in the Article is included. All non-copyright intellectual property rights in and to the Article, such as patent rights, shall remain with the Author.

5. Grant of Rights in Video – Standard Access. This **Section 5** applies if the "Standard Access" box has been checked in **Item 1** above or if no box has been checked in **Item 1** above. In consideration of JoVE agreeing to produce, display or otherwise assist with the Video, the Author hereby acknowledges and agrees that, Subject to **Section 7** below, JoVE is and shall be the sole and exclusive owner of all rights of any nature, including, without limitation, all copyrights, in and to the Video. To the extent that, by law, the Author is deemed, now or at any time in the future, to have any rights of any nature in or to the Video, the Author hereby disclaims all such rights and transfers all such rights to JoVE.

6. Grant of Rights in Video – Open Access. This **Section 6** applies only if the "Open Access" box has been checked in **Item 1** above. In consideration of JoVE agreeing to produce, display or otherwise assist with the Video, the Author hereby grants to JoVE, subject to **Section 7** below, the exclusive, royalty-free, perpetual (for the full term of copyright in the Article, including any extensions thereto) license (a) to publish, reproduce, distribute, display and store the Video in all forms, formats and media whether now known or hereafter developed (including without limitation in print, digital and electronic form) throughout the world, (b) to translate the Video into other languages, create adaptations, summaries or extracts of the Video or other Derivative Works or Collective Works based on all or any portion of the Video and exercise all of the rights set forth in (a) above in such translations, adaptations, summaries, extracts, Derivative Works or Collective Works and (c) to license others to do any or all of the above. The foregoing rights may be exercised in all media and formats, whether now known or hereafter devised, and include the right to make such modifications as are technically necessary to exercise the rights in other media and formats. For any Video to which this Section 6 is applicable, JoVE and the Author hereby grant to the public all such rights in the Video as provided in, but subject to all limitations and requirements set forth in, the CRC License.

7. Government Employees. If the Author is a United States government employee and the Article was prepared in the course of his or her duties as a United States government employee, as indicated in **Item 2** above, and any of the licenses or grants granted by the Author hereunder exceed the scope of the 17 U.S.C. 403, then the rights granted hereunder shall be limited to the maximum rights permitted under such

statute. In such case, all provisions contained herein that are not in conflict with such statute shall remain in full force and effect, and all provisions contained herein that do so conflict shall be deemed to be amended so as to provide to JoVE the maximum rights permissible within such statute.

8. Likeness, Privacy, Personality. The Author hereby grants JoVE the right to use the Author's name, voice, likeness, picture, photograph, image, biography and performance in any way, commercial or otherwise, in connection with the Materials and the sale, promotion and distribution thereof. The Author hereby waives any and all rights he or she may have, relating to his or her appearance in the Video or otherwise relating to the Materials, under all applicable privacy, likeness, personality or similar laws.

9. Author Warranties. The Author represents and warrants that the Article is original, that it has not been published, that the copyright interest is owned by the Author (or, if more than one author is listed at the beginning of this Agreement, by such authors collectively) and has not been assigned, licensed, or otherwise transferred to any other party. The Author represents and warrants that the author(s) listed at the top of this Agreement are the only authors of the Materials. If more than one author is listed at the top of this Agreement and if any such author has not entered into a separate Article and Video License Agreement with JoVE relating to the Materials, the Author represents and warrants that the Author has been authorized by each of the other such authors to execute this Agreement on his or her behalf and to bind him or her with respect to the terms of this Agreement as if each of them had been a party hereto as an Author. The Author warrants that the use, reproduction, distribution, public or private performance or display, and/or modification of all or any portion of the Materials does not and will not violate, infringe and/or misappropriate the patent, trademark, intellectual property or other rights of any third party. The Author represents and warrants that it has and will continue to comply with all government, institutional and other regulations, including, without limitation all institutional, laboratory, hospital, ethical, human and animal treatment, privacy, and all other rules, regulations, laws, procedures or guidelines, applicable to the Materials, and that all research involving human and animal subjects has been approved by the Author's relevant institutional review board.

10. JoVE Discretion. If the Author requests the assistance of JoVE in producing the Video in the Author's facility, the Author shall ensure that the presence of JoVE employees, agents or independent contractors is in accordance with the relevant regulations of the Author's institution. If more than one author is listed at the beginning of this Agreement, JoVE may, in its sole discretion, elect not take any action with respect to the Article until such time as it has received complete, executed Article and Video License Agreements from each such author. JoVE reserves the right, in its absolute and sole discretion and without giving any reason therefore, to accept or decline any work submitted to JoVE. JoVE and its employees, agents and independent contractors shall have

ARTICLE AND VIDEO LICENSE AGREEMENT

full, unfettered access to the facilities of the Author or of the Author's institution as necessary to make the Video, whether actually published or not. JoVE has sole discretion as to the method of making and publishing the Materials, including, without limitation, to all decisions regarding editing, lighting, filming, timing of publication, if any, length, quality, content and the like.

11. **Indemnification.** The Author agrees to indemnify JoVE and/or its successors and assigns from and against any and all claims, costs, and expenses, including attorney's fees, arising out of any breach of any warranty or other representations contained herein. The Author further agrees to indemnify and hold harmless JoVE from and against any and all claims, costs, and expenses, including attorney's fees, resulting from the breach by the Author of any representation or warranty contained herein or from allegations or instances of violation of intellectual property rights, damage to the Author's or the Author's institution's facilities, fraud, libel, defamation, research, equipment, experiments, property damage, personal injury, violations of institutional, laboratory, hospital, ethical, human and animal treatment, privacy or other rules, regulations, laws, procedures or guidelines, liabilities and other losses or damages related in any way to the submission of work to JoVE, making of videos by JoVE, or publication in JoVE or elsewhere by JoVE. The Author shall be responsible for, and shall hold JoVE harmless from, damages caused by lack of sterilization, lack of cleanliness or by contamination due to the making of a video by JoVE its employees, agents or independent contractors. All sterilization, cleanliness or decontamination procedures shall be solely the responsibility of the Author and shall be undertaken at the Author's

expense. All indemnifications provided herein shall include JoVE's attorney's fees and costs related to said losses or damages. Such indemnification and holding harmless shall include such losses or damages incurred by, or in connection with, acts or omissions of JoVE, its employees, agents or independent contractors.

12. **Fees.** To cover the cost incurred for publication, JoVE must receive payment before production and publication the Materials. Payment is due in 21 days of invoice. Should the Materials not be published due to an editorial or production decision, these funds will be returned to the Author. Withdrawal by the Author of any submitted Materials after final peer review approval will result in a US\$1,200 fee to cover pre-production expenses incurred by JoVE. If payment is not received by the completion of filming, production and publication of the Materials will be suspended until payment is received.

13. **Transfer, Governing Law.** This Agreement may be assigned by JoVE and shall inure to the benefits of any of JoVE's successors and assignees. This Agreement shall be governed and construed by the internal laws of the Commonwealth of Massachusetts without giving effect to any conflict of law provision thereunder. This Agreement may be executed in counterparts, each of which shall be deemed an original, but all of which together shall be deemed to be one and the same agreement. A signed copy of this Agreement delivered by facsimile, e-mail or other means of electronic transmission shall be deemed to have the same legal effect as delivery of an original signed copy of this Agreement.

A signed copy of this document must be sent with all new submissions. Only one Agreement required per submission.

CORRESPONDING AUTHOR:

Name: Wesley Verla
Department: Dept. of Urology
Institution: Uthmaniyah University Hospital
Article Title: The Vesical-sparing excision and primary anastomosis: detailed technique and results
Signature: [Signature] Date: 28/3/18

Please submit a signed and dated copy of this license by one of the following three methods:

- 1) Upload a scanned copy of the document as a pdf on the JoVE submission site;
- 2) Fax the document to +1.866.381.2236;
- 3) Mail the document to JoVE / Attn: JoVE Editorial / 1 Alewife Center #200 / Cambridge, MA 02139

For questions, please email submissions@jove.com or call +1.617.945.9051

Reply to editors (02-05-2018)

Editorial comments:

1. The manuscript is formatted as per journal's style. Please retain the same.

In the revised version, we left the journal's style intact.

2. Please address specific comments marked in the manuscript.

Specific comments were addressed in the revised version.

3. The title of the manuscript shows a match to a part of your previously published manuscript. Please reword the title.

We've entered this title in our search engines and there was no match with a previously published manuscript of our institution. You might find a book chapter with a similar formulation, though this isn't a manuscript of our research department. The authors, however, do cite the article of professor Lumen (reference 9 in our manuscript). We believe this manuscript title is most appropriate.

4. All the commercial names have been removed from the manuscript as JoVE cannot publish manuscripts containing commercial language. This includes trademark symbols (™), registered symbols (®), and company names before an instrument or reagent. Please check.

All commercial names have indeed been removed, which is ok. However, some crucial names have been removed as well and we've replaced these as they weren't of any commercial nature. Jones scissors, a Kocher clamp and Mayo-Stille scissors are types of instruments without any commercial connotation – these names represent the technical specifications of the instrument. It's important to leave these details in the protocol as different types of instruments provide different types of dissection possibilities. To summarize, we've added the following in the revised manuscript: 'Jones scissors', 'a Kocher clamp', 'Mayo-Stille scissors', 'silk sutures' and 'polyglactin 910 sutures'. Note that we've replaced the commercial names of the wires by the name of the material.

5. Please remove trademark (™) and registered (®) symbols from the Table of Equipment and Materials.

Removed.

6. Please obtain explicit copyright permission to reuse any figures from a previous publication. Explicit permission can be expressed in the form of a letter from the editor or a link to the editorial policy that allows re-prints. Please upload this information as a .doc or

.docx file to your Editorial Manager account. The Figure must be cited appropriately in the Figure Legend, i.e. "This figure has been modified from [citation]." Please ignore if figures as the original.

All figures and tables are original.

7. Please discuss all figures in the Representative Results in order. However, for figures showing the experimental set-up, please reference them in the Protocol

In the revised manuscript, references in the text were included for all tables and figures.