

Journal of Visualized Experiments

Intraoperative ultrasound in spinal surgery

--Manuscript Draft--

Article Type:	Invited Methods Article - JoVE Produced Video
Manuscript Number:	JoVE58080R3
Full Title:	Intraoperative ultrasound in spinal surgery
Keywords:	intraoperative ultrasound; spine surgery; intramedullary tumor; thoracic disc herniation; thoracolumbar burst fracture; intradural lesion
Corresponding Author:	Melissa M.J. Chua Brigham and Women's Hospital Boston, MA UNITED STATES
Corresponding Author's Institution:	Brigham and Women's Hospital
Corresponding Author E-Mail:	mel98791@bu.edu
First Author:	Melissa M.J. Chua
Other Authors:	Viren S. Vasudeva Yi Lu
Additional Information:	
Question	Response
If this article needs to be "in-press" by a certain date, please indicate the date below and explain in your cover letter.	

TITLE:

Intraoperative Ultrasound in Spinal Surgery

AUTHORS & AFFILIATIONS:

Melissa M.J. Chua¹, Viren S. Vasudeva¹, Yi Lu¹

¹Brigham and Women's Hospital, Harvard Medical School, Boston, MA, USA

Corresponding Author:

Melissa M.J. Chua (mel98791@bu.edu)

E-mail Addresses of Co-Authors:

Viren S. Vasudeva (VVASUDEVA@partners.org)

Yi Lu (ylu4@bwh.harvard.edu)

KEYWORDS:

intraoperative ultrasound; spine surgery; intramedullary tumor; thoracic disc herniation; thoracolumbar burst fracture; intradural lesion

SHORT ABSTRACT:

Here, we present a protocol on the use of an intraoperative ultrasound in spinal surgery, particularly in cases of intradural lesions and lesions in the ventral spinal canal when using a posterior approach.

LONG ABSTRACT:

Since the 1980s, there have been several reports of the use of an intraoperative ultrasound as a useful adjunct in spinal surgery. However, with the advent of newer cutting-edge imaging modalities, the use of an intraoperative ultrasound in spine surgery has largely fallen out of favor. Despite this, intraoperative ultrasounds continue to provide several advantages over other intraoperative techniques such as magnetic resonance imaging and computed tomography, including being more cost-effective, efficient, and easy to operate and interpret. Additionally, it remains the only method for the real-time visualization of soft tissue and pathologies. This paper focuses on the advantages of using intraoperative ultrasounds, especially in cases of intradural lesions and lesions ventral to the thecal sac when approached posteriorly.

INTRODUCTION:

An ultrasound is one of the most common diagnostic tools in medicine, particularly for visualizing pathology in the abdomen, limbs, and neck. However, its use to investigate cranial and spinal lesions is not currently widely utilized. In 1978, Reid was the first to report the use of an ultrasound to visualize cervical cord cystic astrocytoma¹. Here, scans were performed with the patient's neck flexed to allow an opening of the intralaminar window. Four years later, in 1982, Dohrmann and Rubin reported the use of an ultrasound intraoperatively to visualize the intradural space in 10 patients². Pathologies identified with an intraoperative ultrasound, among the 10 patients, included syringomyelia, spinal cord cysts, and intramedullary and extramedullary

tumors. They further demonstrated the use of an intraoperative ultrasound to guide catheters and probes for the biopsy of tumors, the drainage of cysts, and ventricular shunt catheter placement³. This allowed the real-time monitoring and precise positioning of probes/catheters, reducing the inaccuracy and errors in placement. Following these initial reports, several others have published the use of intraoperative ultrasounds for guiding spinal cord cyst drainage, intramedullary and extramedullary tumor resection, and syringo-subarachnoid shunt catheter placement⁴⁻¹⁰. Additionally, it has been shown to also increase the rate of complete resections of intra-axial solid brain tumors and spinal intradural tumors^{11,12}. Intraoperative ultrasounds have also proven to be useful for the intraoperative surgical planning before a manipulation of the tissue and the subsequent visualization of adequate neural element decompression in patients with spine fractures^{7,9,13-15}.

With the advent of newer intraoperative technology allowing a clearer visualization of soft tissues, such as magnetic resonance imaging (MRI) and computed tomography (CT), intraoperative ultrasounds have become less common and a less favored intraoperative imaging modality among neurosurgeons today¹⁶. However, intraoperative ultrasounds can have advantages over these newer technologies in certain operative cases (**Table 1**). Intraoperative ultrasounds have shown to demonstrate better the soft tissue visualization of intradural structures when compared with intraoperative CT (iCT) or cone-beam CT (cbCT)^{9,17}. While intraoperative MRI (iMRI) is useful, where available, because of the higher soft tissue resolution it provides, it is costly, time-consuming, and does not provide real-time images^{6,16,18}. For instance, in the circumstance of an intradural mass ventral to the thecal sac, the surgeon is unable to directly visualize the proper area. Additionally, despite being operator dependent, from our experience, an intraoperative ultrasound is fairly simple to use and can be easily read without a radiologist.

PROTOCOL:

The protocol illustrated here follows the guidelines of the human research ethics committee at Brigham and Women's Hospital.

1. Preoperative Protocol

1.1. Assess patients with a spinal pathology in the clinic and determine their eligibility for spinal surgery. Perform a neurological assessment and obtain a CT or MRI scan to identify the spinal lesion.

1.2. Include patients who have an intradural pathology, such as schwannoma, ependymoma, meningioma, astrocytoma, *etc.*, or patients who have a ventral compressive extradural pathology, such as a ventral thoracic herniated disc, fracture fragments ventrally, or a spinal bony tumor with ventral compression.

Note: The pathology is determined by spinal imaging with CT or MRI. Exclusion criteria include the patients who cannot tolerate surgery or patients with an extremely poor prognosis.

2. Preparation for Surgery

2.1. Do not allow the patient to consume anything by mouth after the midnight before the surgery.

Note: The patient will be placed under general anesthesia and intubated by the anesthesiologist.

2.2. Position the patient with their back exposed according to the surgeon's preference, for the spinal surgery.

2.3. Sterilize the surgical area with povidone-iodine by scrubbing the area.

3. Surgery

Note: This section of the protocol follows general spine surgery techniques that can be referenced from any reputable spine surgery technique textbook¹⁹.

3.1. Make an incision with a scalpel along the length of the spine over the appropriate vertebrae levels and continue to make a straight incision down until the bone is reached.

Note: The size of the incision will depend on the size of the pathology. For example, if the tumor spans two vertebral levels, then at least two vertebral levels will need to be exposed. When the bone is exposed, an X-ray with a portable X-ray machine can be performed to verify the correct vertebrae.

3.2. Perform a subperiosteal dissection by electrosurgical cautery and expose the spinous process which is visualized as a bulbous bony process. Turn the cutting edge ventrally and sweep it across the laminar.

3.3. Use a combination of a Leksell bone plier and a highspeed drill to remove the bony lamina and spinous process to expose the *ligamentum flavum* underneath.

3.4. Use an angled Curette and Kerrison bone punch to remove the *ligamentum flavum* to reveal the dura mater underneath.

3.5. Use a bipolar and hemostatic matrix to achieve hemostasis.

Note: The success of a good ultrasound image relies on a clean surgical field.

4. Intraoperative Ultrasound

4.1. Use a mobile ultrasound machine and a transducer probe with a 20 mm diameter.

Note: The probe should have a 10 - 4.4 MHz frequency range. Any comparable device with a similar probe diameter and frequency range should suffice.

4.2. After the bony removal and dura exposure, fill the surgical field with sufficient saline solution such that the ultrasound transducer probe can be submerged.

Note: Generally, a range of 100 - 500 mL of saline solution is needed. The saline solution allows for acoustic coupling.

4.3. Turn on the ultrasound machine and place the ultrasound probe within the saline bath at the level of interest to begin acquiring images.

Note: It is not necessary to place the probe directly touching the dura or spinal cord. Images are acquired on the ultrasound screen in real-time and can be interpreted immediately by the surgeon. Images on the screen can be captured at any time by pressing the **Freeze** button and can be saved by pressing the **Save** button.

4.4. Acquire real-time images in the longitudinal plane by placing the ultrasound probe in line with the direction of the spinal canal to visualize the spinal cord and the lesion similar to the sagittal images from the MRI.

4.5. Acquire real-time images in the transverse plane by placing the ultrasound probe perpendicular to the spinal canal to visualize the spinal cord and the lesion like the axial images from the MRI.

4.6. Acquire real-time images to verify the location of lesions that cannot be directly visualized, to correlate with the preoperative CT or MRI images, to guide the surgical tool placement, and/or to confirm the resolution of the pathology.

Note: When needed, a small piece of sterile compressed sponge approximately 0.5 cm x 0.5 cm can be used as a hyperechoic surgical marker to be placed in the surgical field and can help correlate the surgical location with the image location. This helps to locate the lesion during the surgery and also helps to identify the margin of the tumor.

REPRESENTATIVE RESULTS:

On normal spine ultrasound imaging, the dura is an echogenic layer that surrounds the anechoic spinal fluid. The spinal cord is distinguished by its homogeneous appearance and low echogenicity which is surrounded by an echogenic rim. This echogenic rim is due to the density shift from the spinal fluid to the spinal cord. The central canal appears as a bright central echo, while the exiting nerve roots appear highly echogenic, particularly at the cauda equina¹⁶.

An intraoperative ultrasound can play an advantageous role in the intradural mass lesion resection. In a standard case, preoperative CT or MRI approximates the location of an intradural mass with respect to its known adjacent structures. With this approximation, a durotomy is

made, usually with the extension of the durotomy in either direction for a sufficient exposure of the lesion. In cases of cauda equina tumors, the lesion can rostrally migrate with respect to preoperative imaging²⁰. With intraoperative ultrasounds, the lesion can be readily visualized prior to the dural opening, and the durotomy can be made more appropriately and accurately to the exact location of the mass^{20,21}. Furthermore, with intramedullary lesions where there is a need for dissection through the spinal cord to reach tumors, the risk of neural damage and subsequent neurological deficits can be reduced with the use of an intraoperative ultrasound to guide the surgeon²². Additionally, a sterile compressed sponge is easily identified on ultrasound as a hyperechoic material without acoustic wave attenuation and can be utilized as a surgical marker to distinguish tissue planes and limits for dissection^{15,23}. An example is seen in **Figures 1, 2 and 3**, where a cervical intramedullary lesion was approached *via* a midline myelotomy. The intraoperative ultrasound was beneficial in visualizing and delineating the tumor limits, as well as determining the resection and resolution of the tumor mass effect.

Intraoperative ultrasounds are also particularly useful in operative cases with a posterior approach to resect lesions ventral to the thecal sac, especially in the cervical and thoracic spine, where the spinal cord is vulnerable to injury. While the ventral spinal canal can be approached anteriorly for a better visualization of the lesion, there are associated increases in operative time, bleeding, and morbidity. Thus, a posterior approach is preferable, and the inability to visualize the lesion directly can be overcome with an intraoperative ultrasound to guide the surgeon. Cases where this technique is particularly useful include the resection of intervertebral disc herniations, the reduction of thoracolumbar burst fractures, the resection of ventral extradural tumors, and spinal canal stenosis due to the ossification of the posterior longitudinal ligament, where a confirmation of adequate posterior decompression is needed^{13,14,24-34}. In a symptomatic thoracic disc herniation resection by a posterior approach, an intraoperative ultrasound aided in evaluating the decompression and ensuring all compressive disc fragments were excised (**Figures 4 and 5**). Similarly, in the case of a lumbar burst fracture, an intraoperative ultrasound was useful in confirming adequate decompression and the removal of all fragments (**Figures 6 and 7**).

FIGURE AND TABLE LEGENDS:

Table 1: Comparison of intraoperative imaging techniques.

Figure 1: Preoperative images reveal an intramedullary lesion. A 54-year-old male with no significant past medical history came in with a 1-month history of fever. A cervical MRI revealed a C6 intramedullary lesion. The mass size did not change after 1 month and an extensive workup did not reveal other possible causes of his fever. The patient was subsequently brought to the operating room for a definitive diagnosis. **(A)** A sagittal T2-weighted MRI revealed an intramedullary lesion at C5-C7, with a fluid collection at the top of the mass. **(B)** This panel shows a sagittal T1-weighted MRI. **(C)** A sagittal contrast-enhanced MRI shows scant rim enhancement. **(D)** This panel shows an axial T2-weighted MRI at the level of the fluid collection. **(E)** This panel shows an axial T2-weighted MRI of the lower part of the lesion. *This figure has been modified from Vasudeva *et al.*³⁵.

Figure 2: Intraoperative ultrasound of the spinal cord after a laminectomy. The patient underwent a C5-C7 laminectomy and a subsequent resection of the intramedullary lesion. An intraoperative ultrasound was used to guide the surgical path through the spinal cord until the tumor could be visualized. (A) The intraoperative ultrasound correlated with preoperative MRI imaging, revealing a fluid collection (white arrow). (B) An axial intraoperative ultrasound shows the mass encompassing the majority of the spinal cord. (C) A 0.5 cm x 0.5 cm piece of sterile compressed sponge (white arrow) was used during the operation to confirm the caudal limit of the tumor. (D) This panel shows an intraoperative ultrasound postresection, confirming the complete removal of the tumor and the resolution of the mass effect. *This figure has been modified from Vasudeva *et al.*³⁵.

Figure 3: Postoperative resection imaging reveals a complete tumor resection. Postoperatively, the patient returned to baseline and his fever resolved. The pathology revealed grade II ependymoma. (A) This panel shows a sagittal T2-weighted MRI 2 month postoperatively, showing the complete resection of the tumor. (B) This panel shows a T1-weighted MRI without contrast. (C and D) These panels show T1-weighted MRI with contrast. *This figure has been modified from Vasudeva *et al.*³⁵.

Figure 4: Preoperative MRI reveals severe spinal cord compression. A 73-year-old female came in with a history of several months of worsening gait dysfunction, spasticity, and numbness in her lower extremities. Her motor strength was intact on a neurological exam; however, she had a marked clonus, 4+ lower extremity reflexes, and a wide-based staggering gait. CT and MRI revealed a large, noncalcified T10-T11 intervertebral disc herniation with a compression of the spinal cord. The panels here show (A) sagittal and (B) axial T2-weighted MRI revealing T10 - T11 disc herniation with a spinal cord compression. *This figure has been modified from Vasudeva *et al.*³⁵.

Figure 5: Intraoperative ultrasound reveals disc herniation and spinal cord compression. The patient underwent a right-sided T10-T11 hemilaminectomy, facetectomy, and pedicle-sparing microdiscectomy with a T9-T11 fusion. (A) An intraoperative ultrasound was used to accurately determine the location of the disc herniation, (B) and to evaluate the decompression and ensure a complete removal of the herniated disc. The patient returned to her neurological baseline postoperatively, and her prior symptoms had resolved at her 1-month follow up. *This figure has been modified from Vasudeva *et al.*³⁵.

Figure 6: Preoperative CT demonstration of a pathological L2 burst fracture. A 57-year-old female with a history significant for metastatic appendiceal cancer and a balloon kyphoplasty at L1 and L2 a month prior to pathologic compression fractures came in with mechanical back pain and the acute-onset of left anterior thigh pain. Her motor strength was intact throughout; however, she had a decreased sensation to light touch in her left anterior thigh. (A) Sagittal and (B) axial CTs revealed a pathological L2 burst fracture. *This figure has been modified from Vasudeva *et al.*³⁵.

Figure 7: Intraoperative ultrasound reveals a retropulsed bone fragment and the subsequent complete reduction of the fracture. The patient underwent an L1-L2 laminectomy, left transpedicular reduction of the fracture, and a T12-L3 posterolateral fusion. An intraoperative ultrasound was used to identify any residual bone fragments. **(A)** A retropulsed bone fragment that was not directly visualized was seen in the ventral spinal canal, displacing the thecal sac. **(B)** A complete reduction of the fracture and an adequate decompression of the spinal canal was confirmed with ultrasound. Postoperatively, the patient returned to the baseline with symptom resolution. *This figure has been modified from Vasudeva *et al.*³⁵.

DISCUSSION:

Intraoperative ultrasounds in spinal surgery have largely fallen out of favor with the advent of newer technology; however, they continue to provide several advantages over the other available imaging modalities such as MRI and CT^{6,9,16-18}. In addition to being inexpensive, in this protocol, we also show that the method is simple to use and can provide a visualization of structures with an adequate resolution that could otherwise not be directly seen by the surgeon. It is particularly useful in cases where the surgeon is approaching a lesion located ventrally to the spinal canal in a posterior manner. Additionally, the images can be correlated with preoperative MRI or CT images and do not require a radiologist for interpretation. Most importantly, an intraoperative ultrasound remains the only imaging modality that allows for real-time image acquisition³⁶. Ultrasound also poses no radiation risk to the patient or surgeon.

Preoperative MRI or CT images should be analyzed carefully to avoid intraoperative complications and to accurately determine the location of the initial incision. This will help ensure that the ultrasound probe will be precisely at the desired location. After the initial incision is made, an X-ray can be performed intraoperatively at the incision site to confirm the vertebrae location. It is critical that sufficient hemostasis is reached prior to filling the surgical field with saline to acquire clear images, as blood can attenuate ultrasound waves. It is not necessary for the probe to directly touch the dura or spinal cord for the image acquisition. If images are not clear upon the acquisition, drain the saline solution, fill the surgical field with a fresh saline solution, and repeat the image acquisition.

The only limitation to this protocol is that it is operator dependent; however, the learning curve is gentle and surgeons can become proficient after the first or second operation³⁶.

In conclusion, intraoperative ultrasounds are useful in spinal surgery and should be considered especially in cases of intradural lesions and lesions ventral to the thecal sac when approaching these posteriorly. The recent introduction of contrast-enhanced ultrasound has demonstrated its potential use in spinal dural arteriovenous fistulas and vascularized spinal tumors as well^{37,38}. Education and the use of intraoperative ultrasounds in spinal surgery should also be incorporated into residency and fellowship teaching programs. Future developments in the ultrasound technology can further enhance and increase the utility of this imaging modality.

ACKNOWLEDGMENTS:

The authors have no acknowledgments.

DISCLOSURES:

The authors have nothing to disclose.

REFERENCES:

1. Reid, M.H. Ultrasonic visualization of a cervical cord cystic astrocytoma. *AJR. American Journal of Roentgenology*. **131** (5), 907-908 (1978).
2. Dohrmann, G.J., Rubin, J.M. Intraoperative ultrasound imaging of the spinal cord: syringomyelia, cysts, and tumors--a preliminary report. *Surgical Neurology*. **18** (6), 395-399 (1982).
3. Rubin, J.M., Dohrmann, G.J. Use of ultrasonically guided probes and catheters in neurosurgery. *Surgical Neurology*. **18** (2), 143-148 (1982).
4. Braun, I.F., Raghavendra, B.N., Kricheff, I.I. Spinal cord imaging using real-time high-resolution ultrasound. *Radiology*. **147** (2), 459-465 (1983).
5. Hutchins, W.W., Vogelzang, R.L., Neiman, H.L., Fuld, I.L., Kowal, L.E. Differentiation of tumor from syringohydromyelia: intraoperative neurosonography of the spinal cord. *Radiology*. **151** (1), 171-174 (1984).
6. Juthani, R.G., Bilsky, M.H., Vogelbaum, M.A. Current Management and Treatment Modalities for Intramedullary Spinal Cord Tumors. *Current Treatment Options in Oncology*. **16** (8), 39 (2015).
7. Knake, J.E., Gabrielsen, T.O., Chandler, W.F., Latack, J.T., Gebarski, S.S., Yang, P.J. Real-time sonography during spinal surgery. *Radiology*. **151** (2), 461-465 (1984).
8. Montalvo, B.M., Quencer, R.M., Green, B.A., Eismont, F.J., Brown, M.J., Brost, P. Intraoperative sonography in spinal trauma. *Radiology*. **153** (1), 125-134 (1984).
9. Montalvo, B.M., Quencer, R.M. Intraoperative sonography in spinal surgery: current state of the art. *Neuroradiology*. **28** (5-6), 551-590 (1986).
10. Pasto, M.E., Rifkin, M.D., Rubenstein, J.B., Northrup, B.E., Cotler, J.M., Goldberg, B.B. Real-time ultrasonography of the spinal cord: intraoperative and postoperative imaging. *Neuroradiology*. **26** (3), 183-187 (1984).
11. Mari, A.R., Shah, I., Imran, M., Ashraf, J. Role of intraoperative ultrasound in achieving complete resection of intra-axial solid brain tumours. *JPMA. The Journal of the Pakistan Medical Association*. **64** (12), 1343-1347 (2014).
12. Ivanov, M., Budu, A., Sims-Williams, H., Poeata, I. Using Intraoperative Ultrasonography for Spinal Cord Tumor Surgery. *World Neurosurgery*. **97**, 104-111 (2017).

13. Blumenkopf, B., Daniels, T. Intraoperative ultrasonography (IOUS) in thoracolumbar fractures. *Journal of Spinal Disorders*. **1** (1), 86-93 (1988).
14. McGahan, J.P., Benson, D., Chehrazi, B., Walter, J.P., Wagner, F.C. Intraoperative sonographic monitoring of reduction of thoracolumbar burst fractures. *AJR. American Journal of Roentgenology*. **145** (6), 1229-1232 (1985).
15. Quencer, R.M., Montalvo, B.M., Eismont, F.J., Green, B.A. Intraoperative spinal sonography in thoracic and lumbar fractures: evaluation of Harrington rod instrumentation. *AJR. American Journal of Roentgenology*. **145** (2), 343-349 (1985).
16. Sosna, J., Barth, M.M., Kruskal, J.B., Kane, R.A. Intraoperative sonography for neurosurgery. *Journal of Ultrasound in Medicine: Official Journal of the American Institute of Ultrasound in Medicine*. **24** (12), 1671-1682 (2005).
17. Raymond, C.A. Brain, spine surgeons say yes to ultrasound. *JAMA*. **255** (17), 2258-2259, 2262 (1986).
18. Toktas, Z.O., Sahin, S., Koban, O., Sorar, M., Konya, D. Is intraoperative ultrasound required in cervical spinal tumors? A prospective study. *Turkish Neurosurgery*. **23** (5), 600-606 (2013).
19. Watkins III, R.G., Watkins IV, R.G. *Surgical Approaches to the Spine*. Springer-Verlag. New York, NY (2015).
20. Friedman, J.A., Wetjen, N.M., Atkinson, J.L.D. Utility of intraoperative ultrasound for tumors of the cauda equina. *Spine*. **28** (3), 288-290, discussion 291 (2003).
21. Zhou, H. *et al.* Intraoperative ultrasound assistance in treatment of intradural spinal tumours. *Clinical Neurology and Neurosurgery*. **113** (7), 531-537 (2011).
22. Harrop, J.S., Ganju, A., Groff, M., Bilsky, M. Primary intramedullary tumors of the spinal cord. *Spine*. **34** (22 Suppl), S69-S77 (2009).
23. Quencer, R.M., Montalvo, B.M. Normal intraoperative spinal sonography. *AJR. American journal of roentgenology*. **143** (6), 1301-1305 (1984).
24. Aoyama, T., Hida, K., Akino, M., Yano, S., Iwasaki, Y. Detection of residual disc hernia material and confirmation of nerve root decompression at lumbar disc herniation surgery by intraoperative ultrasound. *Ultrasound in Medicine & Biology*. **35** (6), 920-927 (2009).
25. Bose, B. Thoracic extruded disc mimicking spinal cord tumor. *The Spine Journal: Official Journal of the North American Spine Society*. **3** (1), 82-86 (2003).

26. Harel, R., Knoller, N. Intraoperative spine ultrasound: application and benefits. *European Spine Journal: Official Publication of the European Spine Society, the European Spinal Deformity Society, and the European Section of the Cervical Spine Research Society*. **25** (3), 865-869 (2016).
27. Lazennec, J.Y., Saillant, G., Hansen, S., Ramare, S. Intraoperative ultrasonography evaluation of posterior vertebral wall displacement in thoracolumbar fractures. *Neurologia Medico-Chirurgica*. **39** (1), 8-14, discussion 14-15 (1999).
28. Matsuyama, Y. *et al.* Cervical myelopathy due to OPLL: clinical evaluation by MRI and intraoperative spinal sonography. *Journal of Spinal Disorders & Techniques*. **17** (5), 401-404 (2004).
29. Mueller, L.A. *et al.* Ultrasound-guided spinal fracture repositioning, ligamentotaxis, and remodeling after thoracolumbar burst fractures. *Spine*. **31** (20), E739-E746, discussion E747 (2006).
30. Nishimura, Y., Thani, N.B., Tochigi, S., Ahn, H., Ginsberg, H.J. Thoracic discectomy by posterior pedicle-sparing, transfacet approach with real-time intraoperative ultrasonography: Clinical article. *Journal of Neurosurgery. Spine*. **21** (4), 568-576 (2014).
31. Randel, S., Gooding, G.A., Dillon, W.P. Sonography of intraoperative spinal arteriovenous malformations. *Journal of Ultrasound in Medicine: Official Journal of the American Institute of Ultrasound in Medicine*. **6** (9), 539-544 (1987).
32. Seichi, A. *et al.* Intraoperative ultrasonographic evaluation of posterior decompression via laminoplasty in patients with cervical ossification of the posterior longitudinal ligament: correlation with 2-year follow-up results. *Journal of Neurosurgery. Spine*. **13** (1), 47-51 (2010).
33. Tian, W. *et al.* Intraoperative 3-dimensional navigation and ultrasonography during posterior decompression with instrumented fusion for ossification of the posterior longitudinal ligament in the thoracic spine. *Journal of Spinal Disorders & Techniques*. **26** (6), E227-E234 (2013).
34. Tokuhashi, Y., Matsuzaki, H., Oda, H., Uei, H. Effectiveness of posterior decompression for patients with ossification of the posterior longitudinal ligament in the thoracic spine: usefulness of the ossification-kyphosis angle on MRI. *Spine*. **31** (1), E26-E30 (2006).
35. Vasudeva, V.S., Abd-El-Barr, M., Pompeu, Y.A., Karhade, A., Groff, M.W., Lu, Y. Use of Intraoperative Ultrasound During Spinal Surgery. *Global Spine Journal*. **7** (7), 648-656 (2017).
36. Alaqeel, A., Abou Al-Shaar, H., Alaqeel, A., Al-Habib, A. The utility of ultrasound for surgical spinal decompression. *Medical Ultrasonography*. **17** (2), 211-218 (2015).
37. Della Pepa, G.M. *et al.* Real-time intraoperative contrast-enhanced ultrasound (CEUS) in vascularized spinal tumors: a technical note. *Acta Neurochirurgica*. **160** (6), 1259-1263 (2018).

439

440 38. Della Pepa, G.M. *et al.* Integration of Real-Time Intraoperative Contrast-Enhanced Ultrasound
441 and Color Doppler Ultrasound in the Surgical Treatment of Spinal Cord Dural
442 Arteriovenous Fistulas. *World Neurosurgery*. **112**, 138-142 (2018).

443

Figure 1

[Click here to download Figure Figure 1.JPG](#)

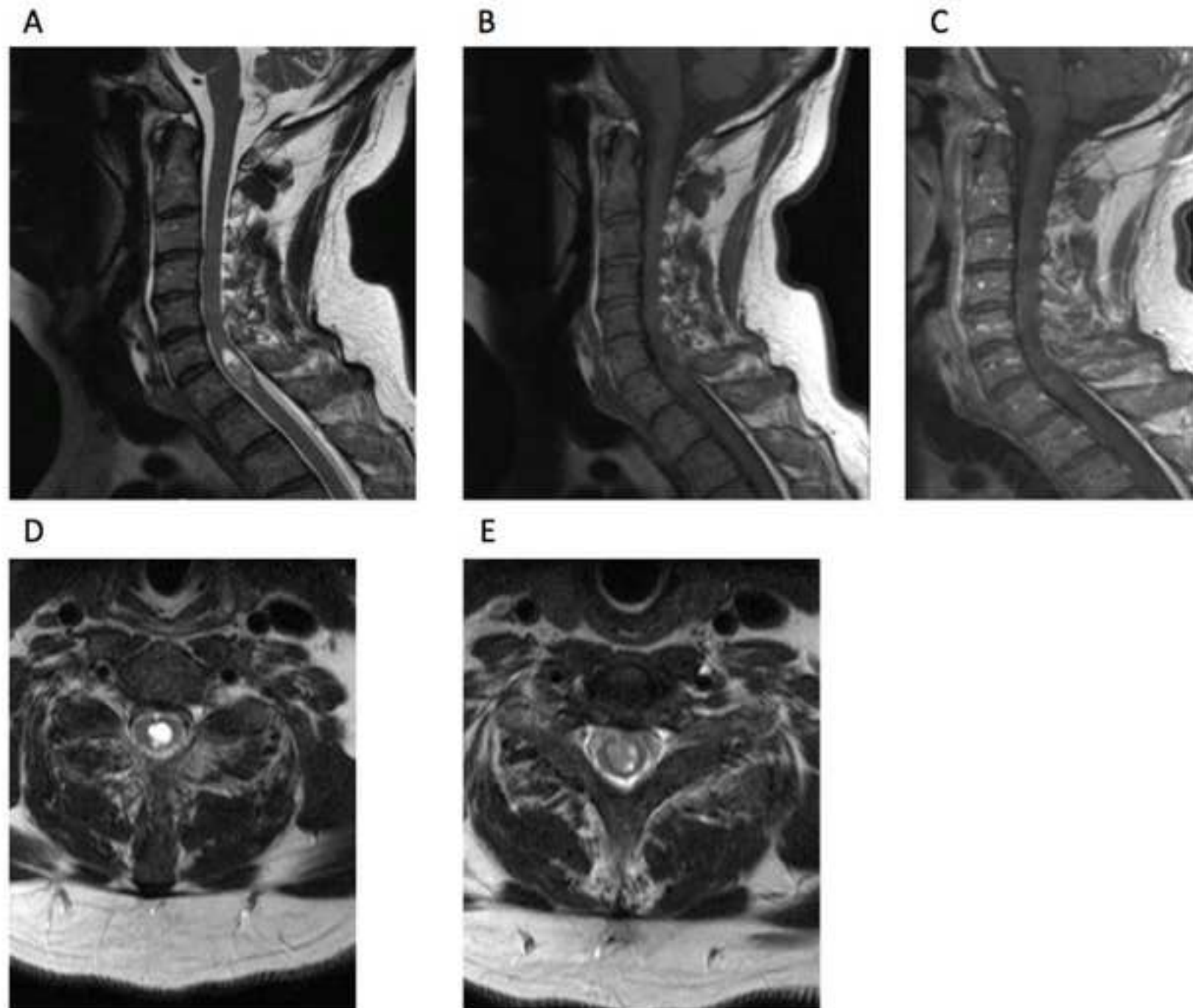
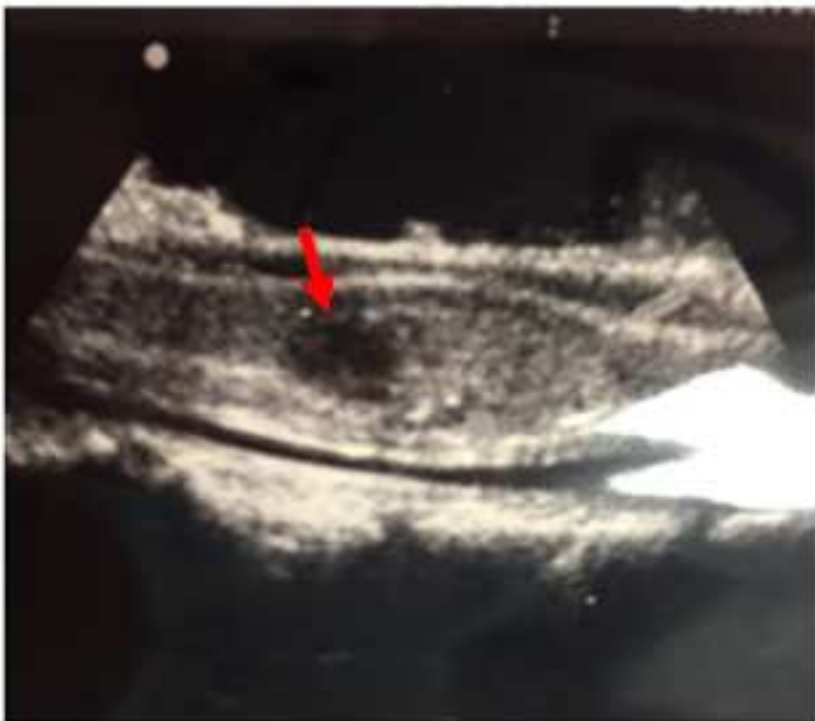

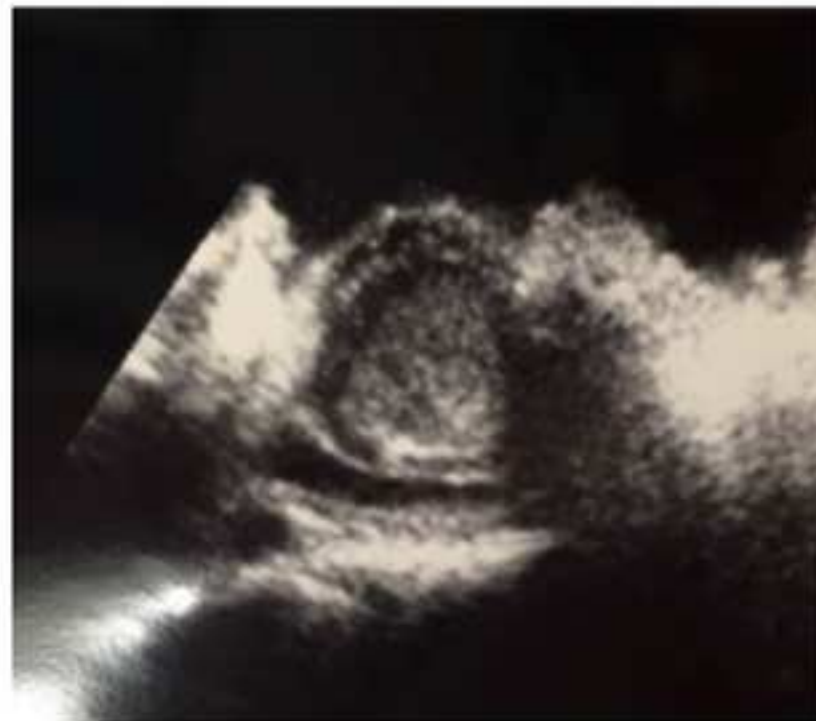Figure 2

[Click here to download Figure Figure 2.JPG](#)

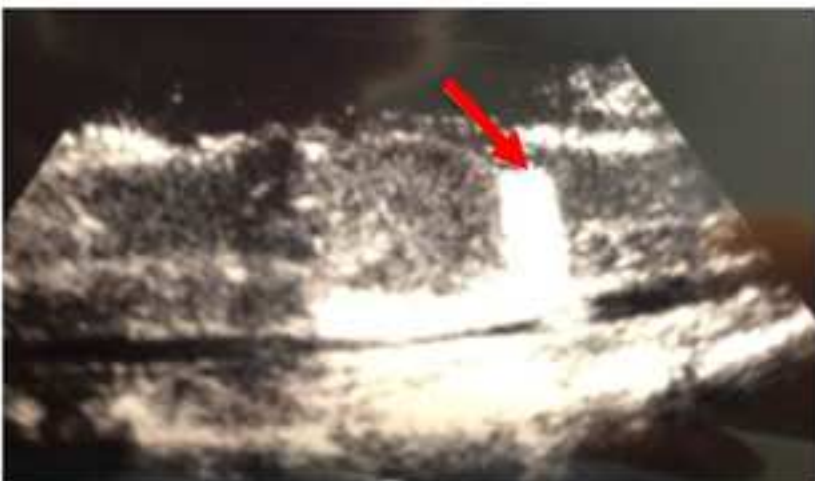A



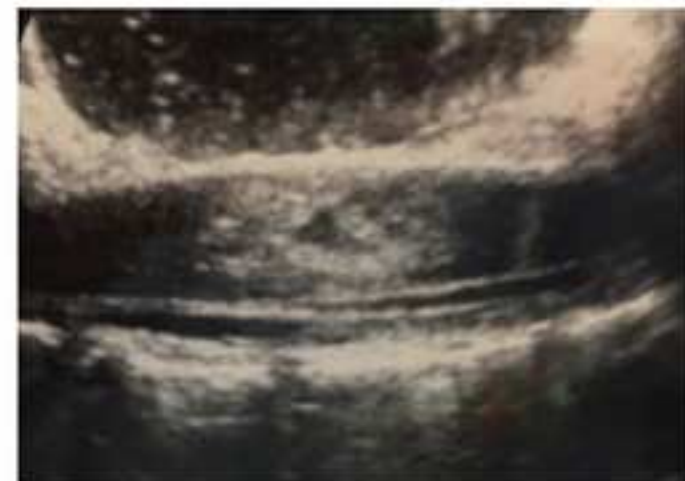B



C



D



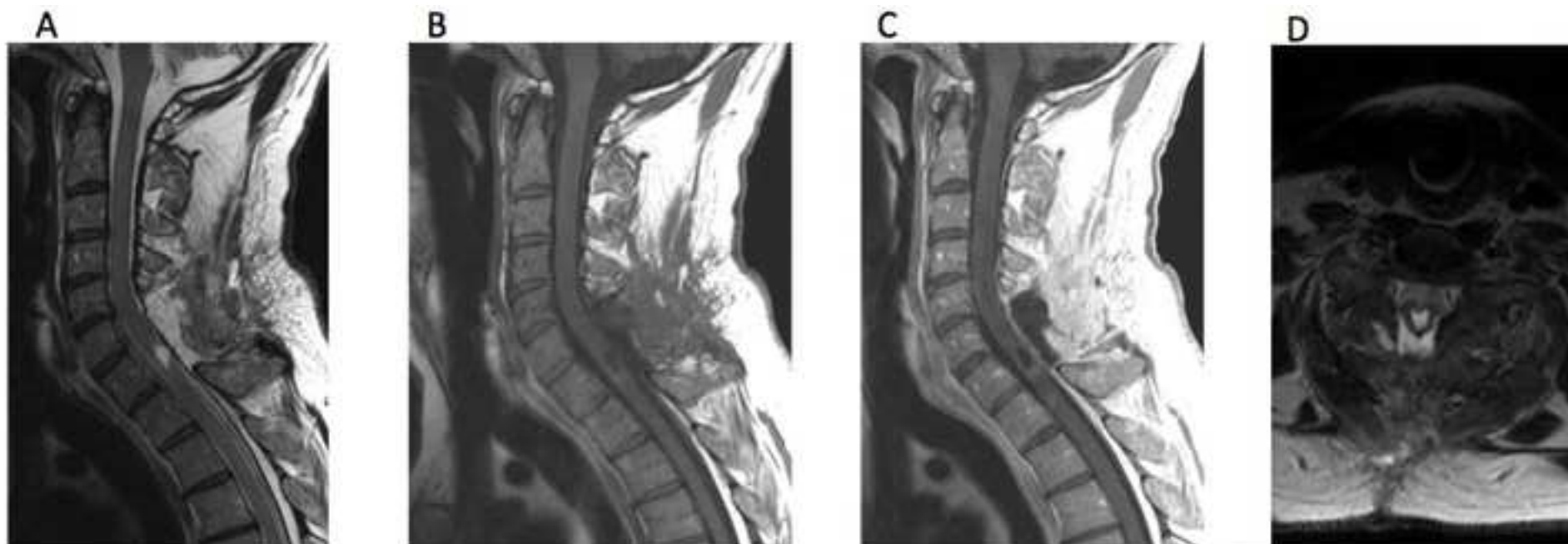


Figure 4

[Click here to download Figure Ultrasound figure 4.jpg](#)

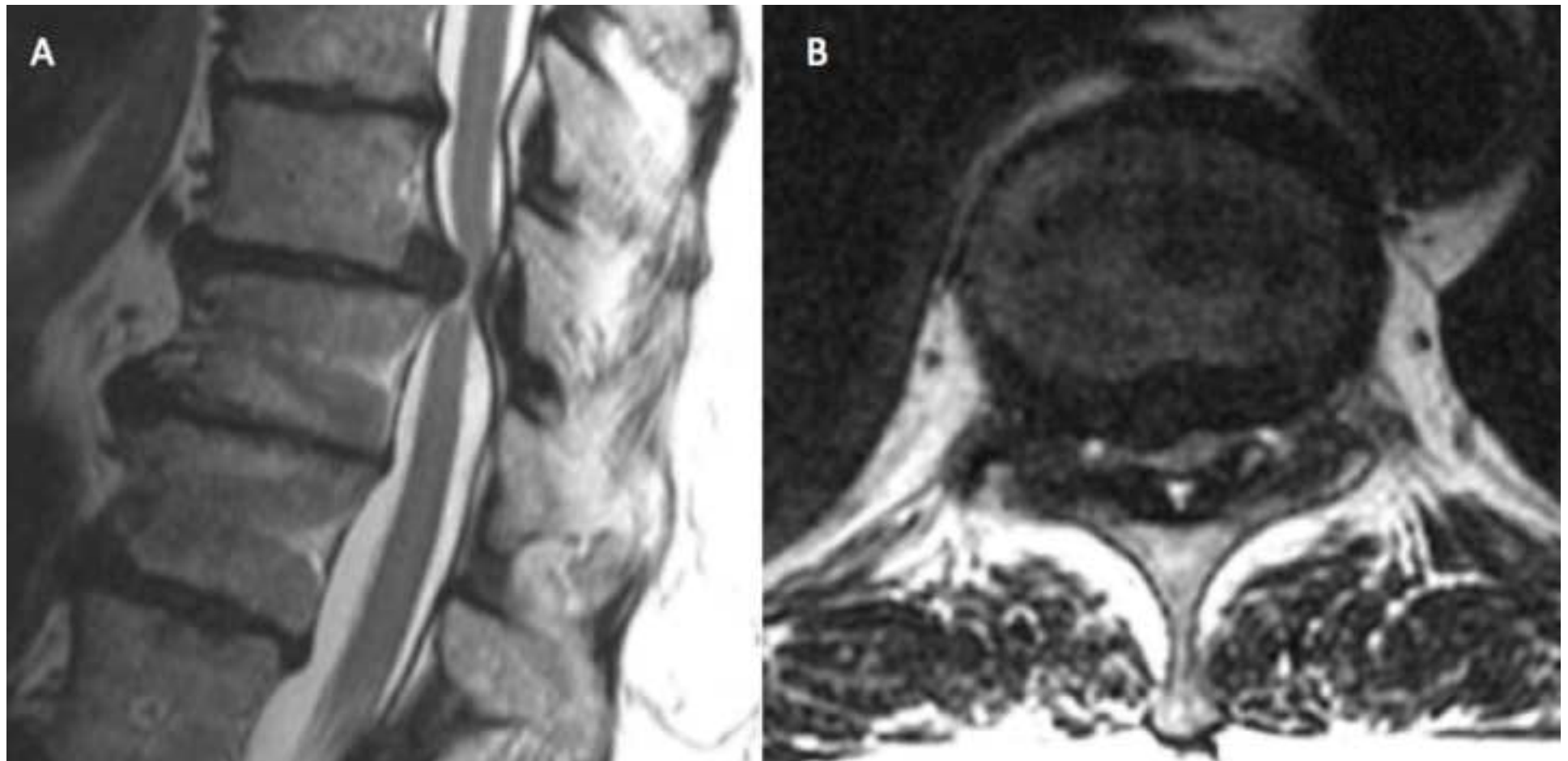


Figure 5

[Click here to download Figure Ultrasound figure 5.jpg](#)

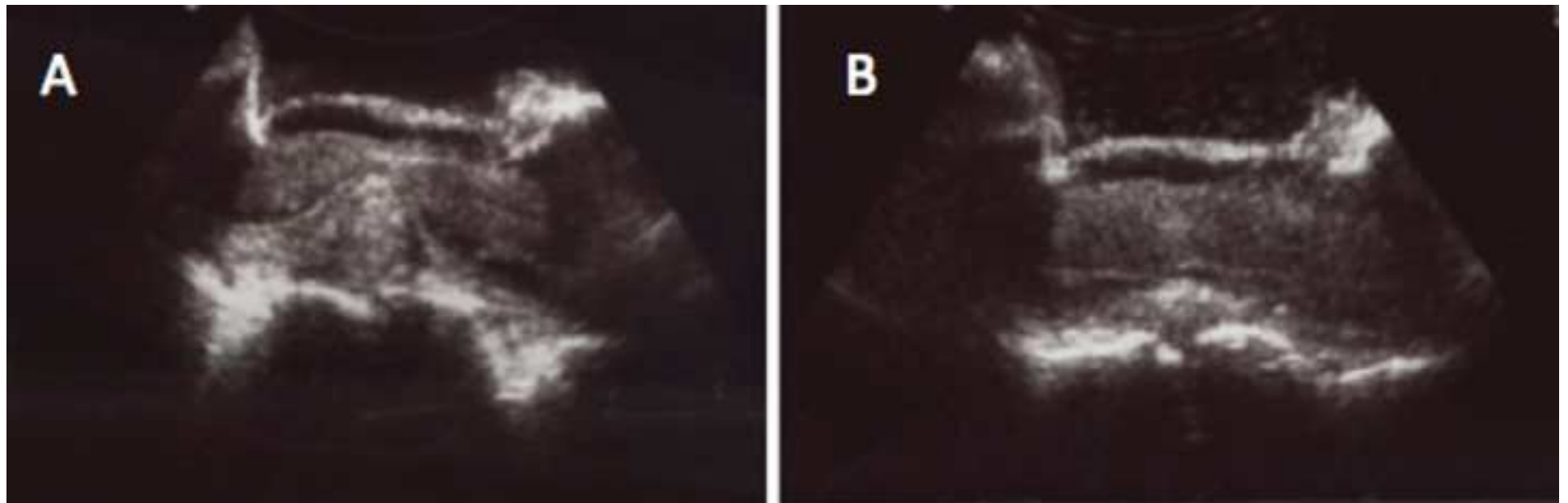


Figure 6

[Click here to download Figure Ultrasound figure 6.jpg](#)

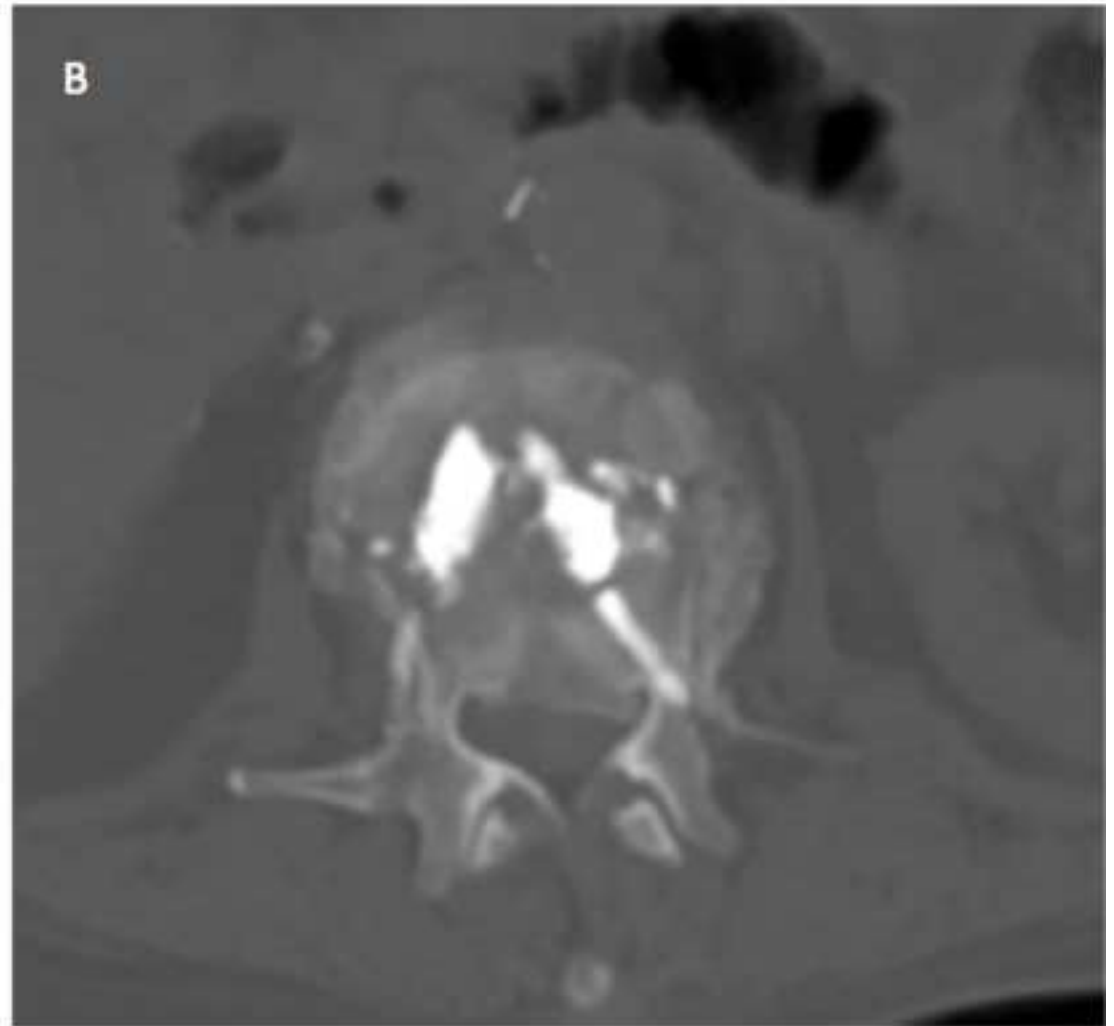
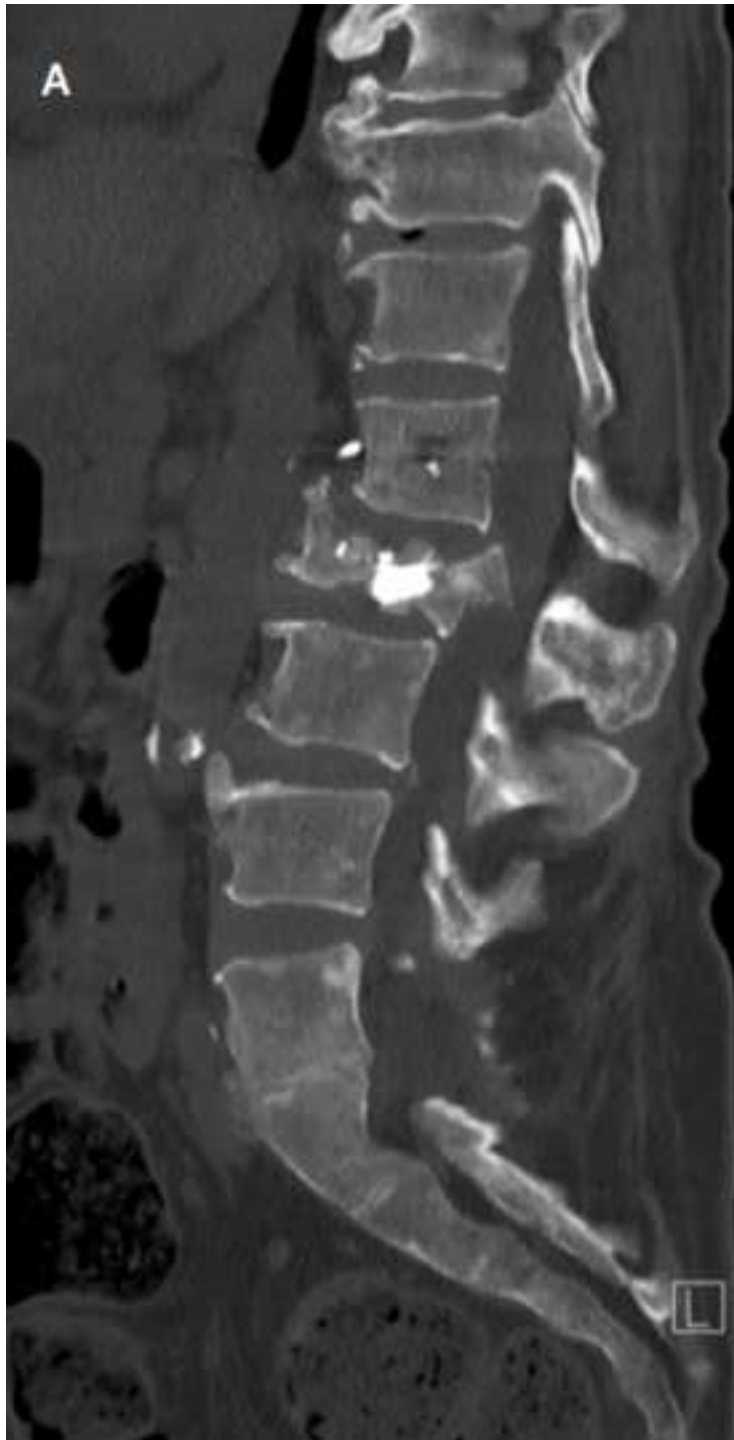
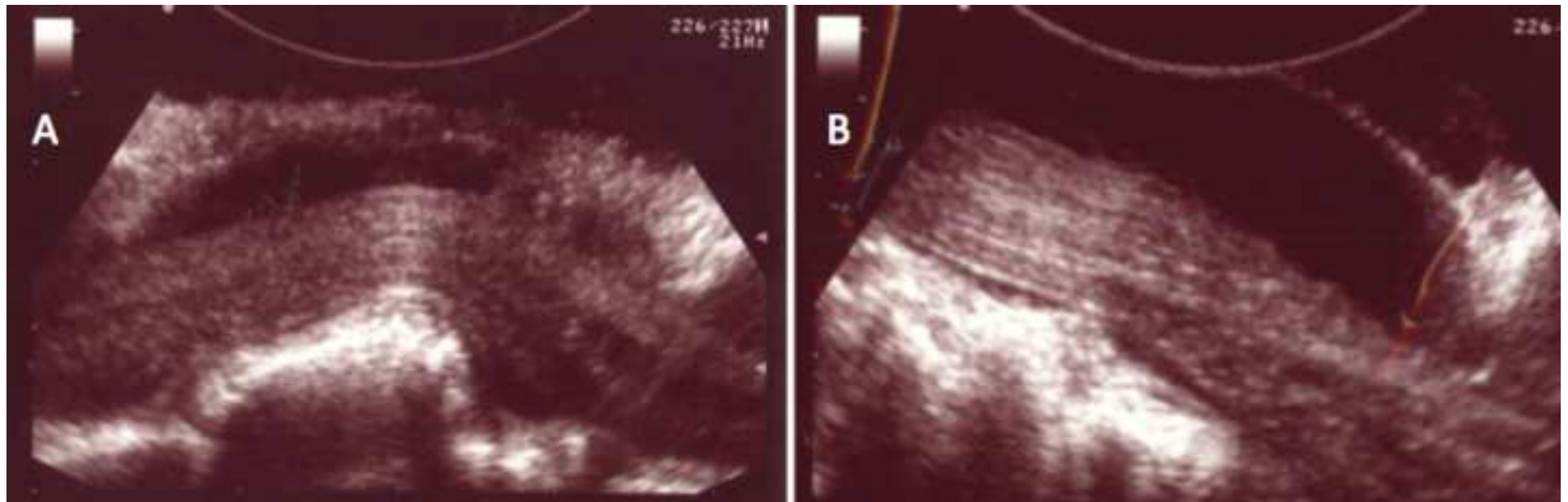




Figure 7

[Click here to download Figure Ultrasound figure 7.jpg](#)






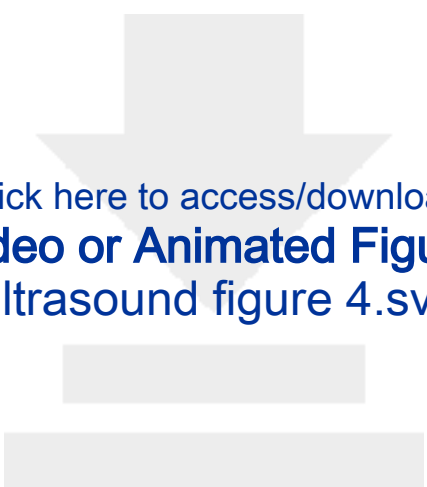
Click here to access/download
Video or Animated Figure
Figure1.svg



Click here to access/download
Video or Animated Figure
Figure2.svg



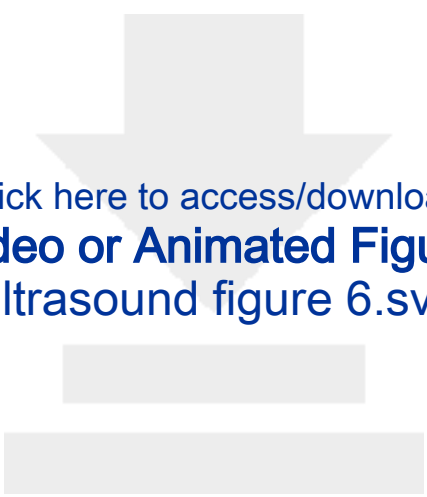
Click here to access/download
Video or Animated Figure
figure3.svg



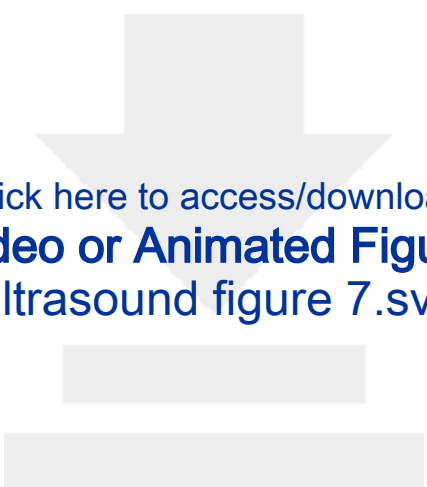
Click here to access/download
Video or Animated Figure
Ultrasound figure 4.svg



Click here to access/download
Video or Animated Figure
Ultrasound figure 5.svg



Click here to access/download
Video or Animated Figure
Ultrasound figure 6.svg



Click here to access/download
Video or Animated Figure
Ultrasound figure 7.svg

Imaging technology	Advantage
Intraoperative ultrasound	<ul style="list-style-type: none">• Real-time• Excellent soft tissue resolution
Cone beam CT and intraoperative CT	<ul style="list-style-type: none">• 3D and multiplanar reconstructions• Able to be paired with navigation systems
Intraoperative MRI	<ul style="list-style-type: none">• Multiplanar reconsutrctions• Excellent soft tissue resolution
Intraoperative fluoroscopy	<ul style="list-style-type: none">• Real-time• 2D images of bony structures

Name of Material/ Equipment	Company
Aloka Prosound 5 mobile ultrasound n	Hitachi
UST-9120 transducer probe.	Hitachi

Catalog Number	Comments/Description
N/A	any comparable devices on the market s
UST-9120	Has a 20mm diameter with 10 to 4.4 MHz

should suffice

Hz frequency range (any comparable compatible transducer should suffice).



1 Alewife Center #200
 Cambridge, MA 02140
 tel. 617.945.9051
www.jove.com

ARTICLE AND VIDEO LICENSE AGREEMENT

Title of Article:

Intraoperative ultrasound in spinal surgery

Author(s):

Melissa M.J. Chua, Viren S. Vasudeva, MD, Yi Lu, MD, PhD

Item 1 (check one box): The Author elects to have the Materials be made available (as described at <http://www.jove.com/author>) via: ☒ Standard Access ☐ Open Access

Item 2 (check one box):

- ☒ The Author is NOT a United States government employee.
- ☐ The Author is a United States government employee and the Materials were prepared in the course of his or her duties as a United States government employee.
- ☐ The Author is a United States government employee but the Materials were NOT prepared in the course of his or her duties as a United States government employee.

ARTICLE AND VIDEO LICENSE AGREEMENT

1. **Defined Terms.** As used in this Article and Video License Agreement, the following terms shall have the following meanings: “**Agreement**” means this Article and Video License Agreement; “**Article**” means the article specified on the last page of this Agreement, including any associated materials such as texts, figures, tables, artwork, abstracts, or summaries contained therein; “**Author**” means the author who is a signatory to this Agreement; “**Collective Work**” means a work, such as a periodical issue, anthology or encyclopedia, in which the Materials in their entirety in unmodified form, along with a number of other contributions, constituting separate and independent works in themselves, are assembled into a collective whole; “**CRC License**” means the Creative Commons Attribution-Non Commercial-No Derivs 3.0 Unported Agreement, the terms and conditions of which can be found at: <http://creativecommons.org/licenses/by-nc-nd/3.0/legalcode>; “**Derivative Work**” means a work based upon the Materials or upon the Materials and other pre-existing works, such as a translation, musical arrangement, dramatization, fictionalization, motion picture version, sound recording, art reproduction, abridgment, condensation, or any other form in which the Materials may be recast, transformed, or adapted; “**Institution**” means the institution, listed on the last page of this Agreement, by which the Author was employed at the time of the creation of the Materials; “**JoVE**” means MyJoVE Corporation, a Massachusetts corporation and the publisher of *The Journal of Visualized Experiments*; “**Materials**” means the Article and / or the Video; “**Parties**” means the Author and JoVE; “**Video**” means any video(s) made by the Author, alone or in conjunction with any other parties, or by JoVE or its affiliates or agents, individually or in collaboration with the Author or any other parties, incorporating all or any portion of the Article, and in which the Author may or may not appear.

2. **Background.** The Author, who is the author of the Article, in order to ensure the dissemination and protection of the Article, desires to have the JoVE publish the Article and create and transmit videos based on the Article. In furtherance of such goals, the Parties desire to memorialize in this Agreement the respective rights of each Party in and to the Article and the Video.

3. **Grant of Rights in Article.** In consideration of JoVE agreeing to publish the Article, the Author hereby grants to JoVE, subject to **Sections 4** and **7** below, the exclusive, royalty-free, perpetual (for the full term of copyright in the Article, including any extensions thereto) license (a) to publish, reproduce, distribute, display and store the Article in all forms, formats and media whether now known or hereafter developed (including without limitation in print, digital and electronic form) throughout the world, (b) to translate the Article into other languages, create adaptations, summaries or extracts of the Article or other Derivative Works (including, without limitation, the Video) or Collective Works based on all or any portion of the Article and exercise all of the rights set forth in (a) above in such translations, adaptations, summaries, extracts, Derivative Works or Collective Works and (c) to license others to do any or all of the above. The foregoing rights may be exercised in all media and formats, whether now known or hereafter devised, and include the right to make such modifications as are technically necessary to exercise the rights in other media and formats. If the “Open Access” box has been checked in **Item 1** above, JoVE and the Author hereby grant to the public all such rights in the Article as provided in, but subject to all limitations and requirements set forth in, the CRC License.

ARTICLE AND VIDEO LICENSE AGREEMENT

4. Retention of Rights in Article. Notwithstanding the exclusive license granted to JoVE in **Section 3** above, the Author shall, with respect to the Article, retain the non-exclusive right to use all or part of the Article for the non-commercial purpose of giving lectures, presentations or teaching classes, and to post a copy of the Article on the Institution's website or the Author's personal website, in each case provided that a link to the Article on the JoVE website is provided and notice of JoVE's copyright in the Article is included. All non-copyright intellectual property rights in and to the Article, such as patent rights, shall remain with the Author.

5. Grant of Rights in Video – Standard Access. This **Section 5** applies if the "Standard Access" box has been checked in **Item 1** above or if no box has been checked in **Item 1** above. In consideration of JoVE agreeing to produce, display or otherwise assist with the Video, the Author hereby acknowledges and agrees that, Subject to **Section 7** below, JoVE is and shall be the sole and exclusive owner of all rights of any nature, including, without limitation, all copyrights, in and to the Video. To the extent that, by law, the Author is deemed, now or at any time in the future, to have any rights of any nature in or to the Video, the Author hereby disclaims all such rights and transfers all such rights to JoVE.

6. Grant of Rights in Video – Open Access. This **Section 6** applies only if the "Open Access" box has been checked in **Item 1** above. In consideration of JoVE agreeing to produce, display or otherwise assist with the Video, the Author hereby grants to JoVE, subject to **Section 7** below, the exclusive, royalty-free, perpetual (for the full term of copyright in the Article, including any extensions thereto) license (a) to publish, reproduce, distribute, display and store the Video in all forms, formats and media whether now known or hereafter developed (including without limitation in print, digital and electronic form) throughout the world, (b) to translate the Video into other languages, create adaptations, summaries or extracts of the Video or other Derivative Works or Collective Works based on all or any portion of the Video and exercise all of the rights set forth in (a) above in such translations, adaptations, summaries, extracts, Derivative Works or Collective Works and (c) to license others to do any or all of the above. The foregoing rights may be exercised in all media and formats, whether now known or hereafter devised, and include the right to make such modifications as are technically necessary to exercise the rights in other media and formats. For any Video to which this Section 6 is applicable, JoVE and the Author hereby grant to the public all such rights in the Video as provided in, but subject to all limitations and requirements set forth in, the CRC License.

7. Government Employees. If the Author is a United States government employee and the Article was prepared in the course of his or her duties as a United States government employee, as indicated in **Item 2** above, and any of the licenses or grants granted by the Author hereunder exceed the scope of the 17 U.S.C. 403, then the rights granted hereunder shall be limited to the maximum rights permitted under such

statute. In such case, all provisions contained herein that are not in conflict with such statute shall remain in full force and effect, and all provisions contained herein that do so conflict shall be deemed to be amended so as to provide to JoVE the maximum rights permissible within such statute.

8. Likeness, Privacy, Personality. The Author hereby grants JoVE the right to use the Author's name, voice, likeness, picture, photograph, image, biography and performance in any way, commercial or otherwise, in connection with the Materials and the sale, promotion and distribution thereof. The Author hereby waives any and all rights he or she may have, relating to his or her appearance in the Video or otherwise relating to the Materials, under all applicable privacy, likeness, personality or similar laws.

9. Author Warranties. The Author represents and warrants that the Article is original, that it has not been published, that the copyright interest is owned by the Author (or, if more than one author is listed at the beginning of this Agreement, by such authors collectively) and has not been assigned, licensed, or otherwise transferred to any other party. The Author represents and warrants that the author(s) listed at the top of this Agreement are the only authors of the Materials. If more than one author is listed at the top of this Agreement and if any such author has not entered into a separate Article and Video License Agreement with JoVE relating to the Materials, the Author represents and warrants that the Author has been authorized by each of the other such authors to execute this Agreement on his or her behalf and to bind him or her with respect to the terms of this Agreement as if each of them had been a party hereto as an Author. The Author warrants that the use, reproduction, distribution, public or private performance or display, and/or modification of all or any portion of the Materials does not and will not violate, infringe and/or misappropriate the patent, trademark, intellectual property or other rights of any third party. The Author represents and warrants that it has and will continue to comply with all government, institutional and other regulations, including, without limitation all institutional, laboratory, hospital, ethical, human and animal treatment, privacy, and all other rules, regulations, laws, procedures or guidelines, applicable to the Materials, and that all research involving human and animal subjects has been approved by the Author's relevant institutional review board.

10. JoVE Discretion. If the Author requests the assistance of JoVE in producing the Video in the Author's facility, the Author shall ensure that the presence of JoVE employees, agents or independent contractors is in accordance with the relevant regulations of the Author's institution. If more than one author is listed at the beginning of this Agreement, JoVE may, in its sole discretion, elect not take any action with respect to the Article until such time as it has received complete, executed Article and Video License Agreements from each such author. JoVE reserves the right, in its absolute and sole discretion and without giving any reason therefore, to accept or decline any work submitted to JoVE. JoVE and its employees, agents and independent contractors shall have

ARTICLE AND VIDEO LICENSE AGREEMENT

full, unfettered access to the facilities of the Author or of the Author's institution as necessary to make the Video, whether actually published or not. JoVE has sole discretion as to the method of making and publishing the Materials, including, without limitation, to all decisions regarding editing, lighting, filming, timing of publication, if any, length, quality, content and the like.

11. **Indemnification.** The Author agrees to indemnify JoVE and/or its successors and assigns from and against any and all claims, costs, and expenses, including attorney's fees, arising out of any breach of any warranty or other representations contained herein. The Author further agrees to indemnify and hold harmless JoVE from and against any and all claims, costs, and expenses, including attorney's fees, resulting from the breach by the Author of any representation or warranty contained herein or from allegations or instances of violation of intellectual property rights, damage to the Author's or the Author's institution's facilities, fraud, libel, defamation, research, equipment, experiments, property damage, personal injury, violations of institutional, laboratory, hospital, ethical, human and animal treatment, privacy or other rules, regulations, laws, procedures or guidelines, liabilities and other losses or damages related in any way to the submission of work to JoVE, making of videos by JoVE, or publication in JoVE or elsewhere by JoVE. The Author shall be responsible for, and shall hold JoVE harmless from, damages caused by lack of sterilization, lack of cleanliness or by contamination due to the making of a video by JoVE its employees, agents or independent contractors. All sterilization, cleanliness or decontamination procedures shall be solely the responsibility of the Author and shall be undertaken at the Author's


expense. All indemnifications provided herein shall include JoVE's attorney's fees and costs related to said losses or damages. Such indemnification and holding harmless shall include such losses or damages incurred by, or in connection with, acts or omissions of JoVE, its employees, agents or independent contractors.

12. **Fees.** To cover the cost incurred for publication, JoVE must receive payment before production and publication the Materials. Payment is due in 21 days of invoice. Should the Materials not be published due to an editorial or production decision, these funds will be returned to the Author. Withdrawal by the Author of any submitted Materials after final peer review approval will result in a US\$1,200 fee to cover pre-production expenses incurred by JoVE. If payment is not received by the completion of filming, production and publication of the Materials will be suspended until payment is received.

13. **Transfer, Governing Law.** This Agreement may be assigned by JoVE and shall inure to the benefits of any of JoVE's successors and assignees. This Agreement shall be governed and construed by the internal laws of the Commonwealth of Massachusetts without giving effect to any conflict of law provision thereunder. This Agreement may be executed in counterparts, each of which shall be deemed an original, but all of which together shall be deemed to be one and the same agreement. A signed copy of this Agreement delivered by facsimile, e-mail or other means of electronic transmission shall be deemed to have the same legal effect as delivery of an original signed copy of this Agreement.

A signed copy of this document must be sent with all new submissions. Only one Agreement required per submission.

CORRESPONDING AUTHOR:

Name:	Melissa Ming Jie Chua	
Department:	Neurosurgery	
Institution:	Brigham and Women's Hospital	
Article Title:	Intraoperative ultrasound in spinal surgery	
Signature:		Date: 2/26/2018

Please submit a signed and dated copy of this license by one of the following three methods:

- 1) Upload a scanned copy of the document as a pdf on the JoVE submission site;
- 2) Fax the document to +1.866.381.2236;
- 3) Mail the document to JoVE / Attn: JoVE Editorial / 1 Alewife Center #200 / Cambridge, MA 02139

For questions, please email submissions@jove.com or call +1.617.945.9051



BRIGHAM AND
WOMEN'S HOSPITAL



HARVARD
MEDICAL SCHOOL

Melissa Ming Jie Chua
Medical Student
Brigham and Women's Hospital
Department of Neurosurgery
75 Francis Street, AB-136
Boston, MA 02115
Email: mel98791@bu.edu
Cell: (617)-935-4032

June 1, 2018

Vineeta Bajaj, Ph.D
Review Editor – JoVE

Dear Dr. Vineeta Bajaj,

We would like to thank you and the reviewers for the comments to improve our manuscript. To address the comments, we have made the following changes as below. We hope we have addressed the reviewers concerns and we look forward to hearing from you regarding our submission. We would be glad to address any further comments or suggestions. Please do not hesitate to call or email me.

Sincerely,

A handwritten signature in black ink, appearing to read 'Melissa Chua'.

Melissa Chua, M.A.

Line 41: Quotes removed.

Line 75: Patients with spinal pathology are assessed in clinic for eligibility for spinal surgery.

Line 78-81: Spinal pathologies are determined with CT or MRI imaging.

Line 88: Consent to surgery requires that the patient does not consume anything by mouth after the midnight before surgery.

Line 90: The surgeon is not involved in the anesthesia process. The patient is placed under general anesthesia as determined by a trained anesthesiologist, who continues to monitor the patient throughout the surgery.

Line 94: The surgical area is sterilized by scrubbing the area with povidine-iodine.

Line 106: Yes, the X-ray is done during the surgery.

Line 109: Electrosurgical dissection is achieved by using a monopolar cautery.

Line 116-119: These steps are highly standard procedures which any trained surgeon will be able to understand and we are unable to further explain these steps.

Line 123: No contrast is needed during surgery.



BRIGHAM AND
WOMEN'S HOSPITAL



HARVARD
MEDICAL SCHOOL

Line 130: An estimation of the amount of saline solution is included in the note below, roughly 100-500mL.

Line 160: As the focus of this paper is the intraoperative procedure, we have removed the post-operative section which is patient-dependent.

Line 199: One liner titles for figures have been added.

Link to the editorial policy:

<https://s100.copyright.com/AppDispatchServlet?startPage=648&pageCount=9&author=Viren+S.+Vasudeva%2C+Muhammad+Abd-El-Barr%2C+Yuri+A.+Pompeu%2C+et+al&orderBeanReset=true&imprint=SAGE+Publications+Inc&volumeNum=7&issueNum=7&contentID=10.1177%2F2192568217700100&title=Use+of+Intraoperative+Ultrasound+During+Spinal+Surgery&pa=&oa=CC+BY-NC-ND&issn=2192-5682&publisherName=sage&publication=j839&rpt=n&endPage=656&publicationDate=10%2F01%2F2017>

“This article is available under the Creative Commons CC-BY-NC-ND license and permits non-commercial use of the work as published, without adaptation or alteration provided the work is fully attributed.”