

Journal of Visualized Experiments

Ethanol-induced cervical sympathetic ganglion block applications for promoting canine inferior alveolar nerve regeneration using an artificial nerve --Manuscript Draft--

Article Type:	Invited Methods Article - JoVE Produced Video
Manuscript Number:	JoVE58039R1
Full Title:	Ethanol-induced cervical sympathetic ganglion block applications for promoting canine inferior alveolar nerve regeneration using an artificial nerve
Keywords:	Neuroscience; In situ tissue engineering; Artificial nerve conduit; Polyglycolic acid-collagen tube; Cervical sympathetic ganglion block; Canine model
Corresponding Author:	Yoshiki Shionoya, DDS, ph.D. Nippon Dental University Hospital Tokyo, Chiyodaku JAPAN
Corresponding Author's Institution:	Nippon Dental University Hospital
Corresponding Author E-Mail:	ysk.shionoya@gmail.com
First Author:	Yoshiki Shionoya, DDS, ph.D.
Other Authors:	Katsuhisa Sunada Gentarou Tsujimoto Keiji Shigeno Tatsuo Nakmamura
Author Comments:	
Additional Information:	
Question	Response
If this article needs to be "in-press" by a certain date, please indicate the date below and explain in your cover letter.	

TITLE:

Ethanol-Induced Cervical Sympathetic Ganglion Block Applications for Promoting Canine Inferior Alveolar Nerve Regeneration Using an Artificial Nerve

AUTHORS AND AFFILIATIONS:

Yoshiki Shionoya¹, Katsuhisa Sunada², Gentarou Tsujimoto², Keiji Shigeno³, Tatsuo Nakamura³

¹Department of Dental Anesthesia, Nippon Dental University Hospital at Tokyo, Tokyo, Japan

²Department of Dental Anesthesiology, Nippon Dental University School of Life Dentistry at Tokyo, Tokyo, Japan

³Department of Bioartificial Organs, Institute for Frontier Medical Science, Kyoto University, Kyoto, Japan

Corresponding author:

Yoshiki Shionoya

ysk.shionoya@gmail.com

Tel: +81-3-3261-6083

Email Addresses of Co-authors:

Katsuhisa Sunada (katsu.sunada@nifty.com)

Gentarou Tsujimoto (Gen.tsujimoto@gmail.com)

Keiji Shigeno (shigera77@gmail.com)

Tatsuo Nakamura (nodenkita1287@gmail.com)

KEYWORDS:

neuroscience, *in situ* tissue engineering, artificial nerve conduit, polyglycolic acid-collagen tube, cervical sympathetic ganglion block, canine model

SUMMARY:

We evaluated the effect of cervical sympathetic ganglion block on nerve repair using artificial nerve conduits. Male beagle dogs were each implanted with an artificial nerve across a 10-mm gap in the left inferior alveolar nerve; left cervical sympathetic ganglion was blocked by injecting 99.5% ethanol via lateral thoracotomy.

ABSTRACT:

Polyglycolic acid collagen (PGA-C) tubes are bio-absorbable nerve tubes filled with collagen of multi-chamber structure, which consist of thin collagen films. Favorable clinical outcomes have been achieved when using these tubes for the treatment of damaged inferior alveolar nerve (IAN). A critical factor for the successful nerve regeneration using PGA-C tubes is blood supply to the surrounding tissue. Cervical sympathetic ganglion block (CSGB) creates a sympathetic blockade in the head and neck region thus increasing blood flow in the area. To ensure an adequate effect, the blockade must be administered with local anesthetics one to two times a day for several consecutive weeks; this poses a challenge when creating animal models for investigating this technique. To address this limitation, we developed an ethanol-induced CSGB in a canine model

of long-term increase in blood flow in the orofacial region. We examined whether IAN regeneration via PGA-C tube implantation can be enhanced by this model. Fourteen Beagles were each implanted with a PGA-C tube across a 10-mm gap in the left IAN. The IAN is located within the mandibular canal surrounded by bone, therefore we chose piezoelectric surgery, consisting of ultrasonic waves, for bone processing, in order to minimize the risk of nerve and vessel injury. A good surgical outcome was obtained with this approach. A week after surgery, seven of these dogs were subjected to left CSGB by injection of ethanol. Ethanol-induced CSGB resulted in improved nerve regeneration, suggesting that the increased blood flow effectively promotes nerve regeneration in IAN defects. This canine model can contribute to further research on the long-term effects of CSGB.

INTRODUCTION:

In many cases, traumatic injury of the inferior alveolar nerve (IAN) is iatrogenic, being frequently caused by the extraction of the third molar or the placement of dental implants¹⁻³. Injury of the IAN can lead to deficits in thermal and touch sensations as well as paresthesia, dysesthesia, hypoesthesia, and allodynia. Nerve injury is treated not only by conservative therapy but also by other methods, including suturing and autograft placement. However, these methods have drawbacks, which often include the lack of symptom improvement and neurological defects at the donor site⁴⁻⁶.

The artificial nerve — polyglycolic acid-collagen (PGA-C) tube was originally developed in Japan. It is a bio-absorbable tube with its inner lumen filled with a spongiform collagen⁷. In animal experiments, this tube was used to enhance nerve regeneration in beagle dogs with peroneal nerve defect, and was shown to promote higher level of recovery than autologous nerve transplantation⁸. The clinical application of the PGA-C tube began in 2002 in patients with peripheral nerve injuries. Moreover, favorable clinical outcomes have been achieved in the treatment of trigeminal neuropathy (IAN and lingual nerve)⁹⁻¹¹. A critical factor for successful nerve regeneration using PGA-C tubes is blood supply to the surrounding tissue⁸. Cervical sympathetic ganglion block (CSGB) creates a sympathetic blockade in the head and neck region and increases blood flow to the respective innervated area¹²; thus, it has been used in the treatment of complex regional pain syndrome and circulatory insufficiency¹³⁻¹⁵. However, there have been only a few experimental investigations on the efficacy of CSGB in increasing blood flow¹⁶⁻¹⁷. To ensure adequate CSGB efficiency, the blockade must be applied together with local anesthetics once or twice daily for several weeks, thus posing a challenge when generating animal models to investigate this technique. To address this limitation, in a previous study, we developed a canine model of long-term increased blood flow in the orofacial region¹⁸. The model was generated by performing a CSGB by injecting 99.5% ethanol. We evaluated the oral mucosal blood flow and nasal skin temperature by laser Doppler flowmetry and infrared thermography once per week for 12 weeks. We found that the blood flow of the orofacial region was increased for 7 – 10 weeks in this model.

In the present study, we evaluated the effects of ethanol-induced CSGB on nerve regeneration. The PGA-C tube was implanted into beagle dogs across a 10-mm gap in the left IAN. A week later, CSGB was performed by injecting ethanol. Three months after surgery, we performed a variety

of electrophysiological, histological, and morphological studies to evaluate the effects of CSGB on nerve regeneration. We provide a detailed protocol for IAN reconstruction using a PGA-C tube and ethanol-induced CSGB.

PROTOCOL:

This study was conducted in accordance with the Guiding Principles for the Care and Use of Animals and approved by the Committee for Animal Research of Kyoto University (Kyoto, Japan; authorization number: R-16-16). All efforts were made to minimize animal suffering, and all sections of this report adhere to the ARRIVE (Animal Research: Reporting of *in Vivo* Experiments) guidelines.

1. Fabrication of the PGA-C tube

1.1. To fabricate the artificial nerve conduit by means of an absorbable polyglycolic acid (PGA) tube, use a tubular braiding machine equipped with 48 spindles and five PGA fibers, comprised of bundles of 26 filaments (**Figure 1**)¹⁸.

1.2. To render the PGA tube surface hydrophilic, expose it to plasma discharge.

1.3. Use 1% v/w atelocollagen in hydrochloride solution⁷.

Note: Atelocollagen is extracted from porcine skin via enzyme treatment and subjected to a virus check. It mainly consists of type I (70–80%) and type III collagen, the ratio of which is described in detail elsewhere⁷. Prepare the collagen solution by dissolving 1 g collagen in 100 mL hydrochloride solution (pH = 3.0). Since the density of the hydrochloride solution is approximately 1.0, the w/w collagen concentration is almost 1%.

1.4. Coat the tube with the collagen layers by repeatedly dipping it into the 1% collagen hydrochloride solution for 5 s each time.

1.4.1. After dipping, dry the tube on a clean bench at room temperature. Perform next dipping after ensuring the tube is completely dry (about 6 h for air-drying).

1.4.2. Repeat the coating process 10 times.

1.5. Subject the PGA-C tube to 140 °C for 24 h under vacuum (dehydrothermal treatment), in order to control bio-absorption and crosslinking of the collagen molecules. Perform the entire process under aseptic conditions.

Note: This procedure generates a tube of 14-mm final length, 3-mm inner diameter, and 50-μm wall thickness.

2. Surgical Procedure Set-up

133 2.1. Use adult male beagles weighing 9.0 to 13.0 kg.

134
135 2.1.1. House animals in separate cages, under controlled kennel conditions (12-h light and dark
136 cycle).

137
138 2.1.2. Provide solid food and water *ad libitum*.

139
140 2.2. Weigh the beagles.

141
142 2.3. Autoclave all surgical instruments.

143
144 2.4. Don sterilized gloves and disinfect all surfaces of the operating setting with an 80% ethanol
145 solution. Discard the used gloves.

146
147 2.5. Perform surgical handwashing.

148
149 2.6. Put on a fresh mask, gown, and sterile gloves.

150 151 **3. Anesthesia and Skin Preparation**

152
153 3.1. Anesthetize the dog with a mixture of 5 mg/kg ketamine hydrochloride and 1 mg/kg xylazine
154 by an intramuscular injection.

155
156 3.2. Intubate by a tracheal tube of 7.5 mm diameter and 25 cm length.

157
158 3.3. Place the dog on the right lateral position. Maintain general anesthesia with 1.5%
159 sevoflurane in oxygen (4 L/min) and air (6 L/min).

160
161 3.4. Use a heating pad to maintain body temperature at 37 °C.

162
163 3.5. Apply an ophthalmic gel over the anterior surface of the eyes to avoid corneal abrasion.

164
165 3.6. Carefully shave the surgical field (left side chest area) using surgical clippers.

166
167 3.7. Record the heart rate and oxygen saturation during surgery.

168 169 **4. Inferior Alveolar Nerve Reconstruction Using PGA-C tube: Development of the** 170 **Reconstruction-only Model**

171
172 4.1. Inject 3 mL of 1% lidocaine using a 27 G needle to the left mandibular gingiva as a local
173 anesthetic and analgesic.

174
175 4.2. Perform a 5-cm transverse incision with a number 15 scalpel blade in the left mandibular
176 gingiva, to expose the mandibles of the animal.

4.3. Use piezoelectric ultrasonic vibrations to grind the proximal aspect of the mandible into a 3-cm × 8-mm rectangle through the posterior mental foramen.

Note: The vibration frequency was 28 – 32 kHz.

4.4. Remove the frontal part of the mandibular bone plate (dimensions, 3 cm × 8 mm) to expose the left IAN (**Figure 2A**)¹⁸.

Note: The reconstruction site corresponds to the root apex of the first molar

4.5. Transect the IAN with a scalpel to remove a 10-mm segment.

4.6. Insert the proximal and distal stumps of the severed nerve into the nerve tube to a depth of 2 mm.

4.7. Use 8-0 nylon sutures and a surgical microscope at 8X magnification to suture the tube to the proximal and distal nerve ends (**Figure 2B**)¹⁸.

4.8. Return the bone plate to its original site in the mandible.

4.9. Close the wound with 4-0 nylon sutures.

4.10. One day after surgery, confirm that the mandibular bone plate is in its proper position.

4.10.1 Perform computed tomography (CT) imaging of the facial bone under anesthesia. Set CT parameters as follows: 120 kVp, 200 mAs, 0.5 mm/s, 0.5-mm slice thickness.

4.10.1.1. Administer anesthesia using a mixture of 5 mg/kg ketamine hydrochloride and 1 mg/kg xylazine (**Figure 3**).

4.11. Administer isepamicin sulfate (100 mg/day) as an antibiotic for a week after surgery.

5. Ethanol-induced CSGB: Development of the Reconstruction + CSGB Model

5.1. Perform IAN reconstruction as described in section 4 and allow a week for recovery.

5.2. Anesthetize the animal with 1.5% sevoflurane in oxygen (4 L/min) and air (6 L/min). Shave and clean the intended surgical field, as described in section 3.

5.3. Mark the incision line with a surgical skin marker by drawing a line on the left side chest area (**Figure 4**, the incision line is 20 cm in length).

220 5.4. Inject 5 mL of 1% lidocaine using a 21 G needle to the left side chest area as a local anesthetic
221 and analgesic.

222
223 5.5. Incise the left side chest skin with a number 10 scalpel blade.

224
225 5.6. Incise the fat layer with an electric scalpel to expose the muscle fascia.

226
227 5.7. Expose the serratus ventralis muscle and scalenus muscle.

228
229 5.7. Raise the serratus ventralis muscle and scalenus muscle from ventral to dorsal to expose the
230 second and third ribs (**Figure 5**).

231
232 5.8. Perform a left lateral thoracotomy at the second and third intercostal space to expose the
233 left cervical sympathetic ganglion (**Figure 6**).

234
235 5.9. Inject 0.2 mL of 99.5% ethanol into the cervical sympathetic ganglion using a 30 G needle
236 under direct visualization (**Figure 7**).

237
238 5.10. Close the intercostal space with interrupted 1-0 absorbable stitches.

239
240 5.11. Close the skin with interrupted 3-0 nylon stitches.

241
242 5.12. Administer isepamicin sulfate (100 mg/day) for a week after surgery, as antibiotic.

243
244 5.13. At 1 week after CSGB, measure facial skin temperature with infrared thermography to
245 confirm the CSGB.

246 247 **6. Electrophysiological Recordings**

248
249 6.1. To measure sensory nerve action potential (SNAP) and sensory nerve conduction velocity
250 (SCV) of the IAN three months after reconstruction, anesthetize animals as described in section
251 3.

252
253 Note: SNAP and SCV should be measured on both the experimental and normal control sides for
254 each dog in both treatment groups.

255
256 6.2. Make an incision in the left mandibular gingiva with a number 10 scalpel blade.

257
258 6.3. Carefully remove the mandibular bone plate to avoid physically damaging the regenerated
259 nerve.

260
261 6.3. Stimulate the IAN using a pair of needle electrodes, to record the SNAP and SCV.

262
263 6.3.1. Insert the electrodes proximally to the nerve conduit.

264
265 6.3.2. Apply 10-kHz electrical stimulus 20 times.

266
267 6.4. Analyze the results.

268
269 6.4.1. Determine SNAP by calculating the average response amplitude to the electrical
270 stimulation.

271
272 6.4.2. Measure the peak latency and peak amplitude from the chart recordings.

273
274 6.4.3. Calculate the recovery index with the following equation: peak amplitude of the left IAN of
275 the reconstruction-only or reconstruction + CSGB group / peak amplitude of the right IAN of the
276 reconstruction-only group¹⁹⁻²⁰.

277 278 **7. Histological Analysis**

279 280 **7.1. Section Preparation**

281
282 7.1.1. Three months after reconstruction, harvest the left IAN, including 1 cm of the nerve on
283 either side of the reconstructed site.

284
285 7.1.2. Harvest the right IAN at the level corresponding to the harvest site on the left side.

286
287 7.1.3. Prefix the harvested nerves by immersion in 2.5% glutaraldehyde in a 0.1 M cacodylate
288 buffer solution (pH 7.4, 48 °C, 24 h).

289
290 7.1.4. Postfix with 2% osmium tetroxide solution (48 °C, 4 h) and potassium ferrocyanide in 0.1
291 M phosphate buffer solution (pH 7.4, 2 h).

292
293 7.1.5. Dehydrate the nerves with a series of graded ethanol solutions.

294
295 7.1.6. Embed in epoxy resin (paraffin).

296
297 7.1.7. Section the specimens at a thickness of 0.5 – 1.0 µm.

298 299 **7.2. Toluidine Blue Staining and Morphological Analysis**

300
301 7.2.1. Stain sections with toluidine blue solution.

302
303 7.2.2. Obtain microscopy images using an optical microscope, at 400X magnification at the
304 following regions along the samples: left IAN, the center of the regenerated segment and 2 mm
305 distally to the stump; right IAN, the center of the IAN segment corresponding to the harvest site
306 on the left side.

7.2.3. Select images of all regions with regenerated nerve fibers.

7.2.3.1. Randomly select 8 – 10 areas of 100 μm \times 100 μm containing regenerated nerve fibers.

7.2.3.2. Perform morphological analysis using an appropriate software to measure the following parameters: myelinated nerve fiber diameter (μm) and density (count/area), nerve tissue percentage, and G-ratio (myelinated axon diameter/myelinated nerve fiber diameter).

7.3. Immunostaining

7.3.1. Follow standard protocols for paraffin section staining.

7.3.2. Incubate with primary antibodies for 30 min at 25 $^{\circ}\text{C}$.

7.3.3. Wash with phosphate-buffered saline 3 times at 25 $^{\circ}\text{C}$.

7.3.4. Incubate with secondary antibodies labeled with horseradish-peroxidase for 30 min at 25 $^{\circ}\text{C}$.

7.3.5. Obtain images using a light microscope.

7.4. Transmission Electron Microscopy (TEM)

7.4.1. Prepare nerves as described in step 7.1.

7.4.2. Section nerves at a thickness of 70 – 90 μm using an ultramicrotome.

7.4.3. Stain sections with Reynold's lead citrate and uranyl.

7.4.4. Examine and image by transmission electron microscopy.

REPRESENTATIVE RESULTS:

We observed an increase in the facial skin temperature of the blocked side 1 week after the left CSGB (**Figure 8**).

At 3 months post-reconstruction, the PGA-C tube at the reconstruction area was absorbed and regeneration of the inferior alveolar nerve was observed in the reconstruction-only and reconstruction + CSGB groups (**Figure 9A, B**)¹⁸.

SNAP was measurable in both reconstruction sides of the reconstruction + CSGB and nerve reconstruction groups. The results of the electrophysiological evaluation are summarized in **Table 1**¹⁸. The recovery index and SCV were significantly higher in the reconstruction + CSGB than in the reconstruction-only group.

We observed myelinated nerve fibers at the central and distal segments of the regenerated IAN in the reconstruction-only and reconstruction + CSGB groups (**Figure 10A, B**)¹⁸. The reconstruction-only and reconstruction + CSGB groups showed smaller regenerated myelinated nerve diameters as compared to the normal control group (central segment of the right IAN in the reconstruction group, **Figure 10C**). Immature myelinated nerve fibers were also observed.

Examination of the reconstruction-only, reconstruction + CSGB groups using TEM showed regenerated myelinated nerve fibers and Schwann cells (**Figure 10D, E**). **Figure 10F** shows these results of TEM for the normal control group (central segment of the right IAN in the reconstruction group).

The presence of regenerated axons and Schwann cells was confirmed at the central and distal segments of the reconstruction-only and reconstruction + CSGB groups, by staining with anti-neurofilament (NF) and anti-S100 antibodies, respectively (**Figure 11**)¹⁸.

Morphological evaluation results are summarized in **Table 2**¹⁸. The myelinated nerve fiber diameter at the center of the regenerated left IAN segment was $4.27 \pm 1.5 \mu\text{m}$ in the reconstruction group and $5.11 \pm 1.98 \mu\text{m}$ in the CSGB group, while at the distal segment of the regenerated left IAN the diameter was $3.47 \pm 1.21 \mu\text{m}$ in the reconstruction group and $4.53 \pm 1.36 \mu\text{m}$ in the CSGB group. In both cases, the diameter was significantly larger in the CSGB group, which also demonstrated a significantly higher myelinated nerve fiber density and nerve tissue percentage in both the center and the distal segment of the regenerated left IAN. The G-ratio at the center of the regenerated left IAN was 0.75 ± 0.04 in the reconstruction group and 0.68 ± 0.05 in the CSGB group, while at the distal part it was 0.74 ± 0.04 in the reconstruction group and 0.69 ± 0.04 in the CSGB group. Thus, in both cases, the G-ratio was significantly smaller in the CSGB group.

The sample sizes for the reconstruction-only and reconstruction + CSGB groups were $n = 7$. The statistical analyses for the myelinated nerve fiber diameter and density, G-ratio, and SCV were performed using Dunnett's test. Analysis of the recovery index was performed using an unpaired Student's *t*-test. The level of statistical significance was set at 5% ($p < 0.05$).

FIGURE AND TABLE LEGENDS:

Figure 1: Polyglycolic acid tube filled with collagen sponge. A) Gross image of the tube. The final dimensions of the nerve conduit were 14 mm length, 3 mm inner diameter, and 50 μm wall thickness. **B)** Scanning electron micrograph of the tube. This figure was previously published by Shionoya *et al.*¹⁸ and is reprinted with permission.

Figure 2: Left inferior alveolar nerve (IAN) pre- and post-reconstruction. A) Pre-reconstruction image of the left IAN after being exposed by removal of bone. **B)** Post-reconstruction image of the left IAN reconstructed using a polyglycolic acid-collagen tube. This figure was previously published by Shionoya *et al.*¹⁸ and is reprinted with permission.

Figure 3: Computed tomography imaging of the facial bone after left inferior alveolar nerve reconstruction. The image shows that the mandibular bone plate is in the proper position.

Figure 4: Pre-operative skin markings on the left side chest area prior to surgery. Photograph showing the skin markings before performing the cervical sympathetic ganglion block. The incision line is 20 cm in length.

Figure 5: Operating view of the cervical sympathetic ganglion block: pre-thoracotomy. Image shows the second and third ribs after raising the serratus ventralis and scalenus muscles.

Figure 6: Operating view of the cervical sympathetic ganglion block: post-thoracotomy. Image shows the left cervical sympathetic ganglion after lateral thoracotomy at the second and third intercostal space.

Figure 7: Cervical sympathetic ganglion pre- and post-ethanol injection using a 30 G needle. A) Pre-ethanol injection image of the left cervical sympathetic ganglion. **B)** Post-ethanol injection image of the left cervical sympathetic ganglion.

Figure 8: Thermogram after left cervical sympathetic ganglion block (CSGB). The thermogram was acquired one week after CSGB by ethanol injection. Note that the facial skin temperature on the left side is higher than on the contralateral side. The color bar indicates temperatures in °C.

Figure 9: Regenerated inferior alveolar nerve (IAN). A) Image of the IAN in the reconstruction-only group. **B)** Image of the IAN in the reconstruction + CSGB (cervical sympathetic ganglion block) group. Nerve regeneration (region between white arrowheads) is observed in both groups. This figure was previously published by Shionoya *et al.*¹⁸ and is reprinted with permission.

Figure 10: Toluidine blue and transmission electron microscopy analysis of the regenerated inferior alveolar nerve (IAN). A – C) Semi-thin transverse sections of the IAN at 3 months post-reconstruction stained with toluidine blue. Images show the distal segments of the regenerated left IAN in each group, as indicated. **D – F)** Transmission electron microscopy images from semi-thin sections showing myelinated and non-myelinated nerve fibers (black and white arrowheads, respectively). Scale bars represent 50 µm in (A) – (C) and 5 µm (D) – (F). Normal control: central segment of the right IAN in the reconstruction-only group. This figure was previously published by Shionoya *et al.*¹⁸ and is reprinted with permission.

Figure 11: Immunohistochemical analysis of distal segments of the regenerated left inferior alveolar nerve (IAN). A, B) Sections of the regenerated IAN at 3 months post-reconstruction stained with an anti-neurofilament (NF) antibody for the reconstruction-only group (A) and reconstruction + cervical sympathetic ganglion block (CSGB; B) groups. Black arrowheads indicate regenerated axons. **C, D)** Sections of the regenerated IAN at 3 months post-reconstruction stained with an anti-S-100 antibody for the reconstruction-only group (C) and reconstruction + CSGB (D) groups. White arrowheads indicate Schwann cells. Scale bars, 50 µm. This figure was previously published by Shionoya *et al.*¹⁸ and is reprinted with permission.

Table 1: Electrophysiological findings in the inferior alveolar nerve (IAN) at 3 months after surgery. Data are presented as mean \pm standard deviation ($n = 7$). Comparisons were made using an unpaired Student's t -test. IAN, inferior alveolar nerve; CSGB, cervical sympathetic ganglion block. *, $p < 0.05$ in comparison with the normal control group; #, $p < 0.05$ in comparison with the reconstruction-only group. Normal control: central segment of the right IAN in the reconstruction-only group; Recovery index: ratio of the peak amplitude of the left IAN of the reconstruction-only or reconstruction + CSGB group to the peak amplitude of the normal control. This table was previously published by Shionoya *et al.*¹⁸ and is reprinted with permission.

Table 2: Morphological findings in the inferior alveolar nerve (IAN) at 3 months after surgery. Data are presented as mean \pm standard deviation ($n = 7$). Comparisons were made using Dunnett's test. IAN, inferior alveolar nerve; CSGB, cervical sympathetic ganglion block. *, $p < 0.05$ in comparison with the normal control group; *#, $p < 0.05$ in comparison with the central segment of the left IAN in the reconstruction-only group; *\$, $p < 0.05$ in comparison with the distal end of the left IAN in the reconstruction-only group. Normal control: central segment of the right IAN in the reconstruction-only group; G ratio is the ratio of the myelinated axon diameter to the total myelinated fiber diameter. This table was previously published by Shionoya *et al.*¹⁸ and is reprinted with permission.

DISCUSSION:

We present an efficient method for IAN regeneration by using a bioabsorbable nerve tube in combination with ethanol-induced CSGB. For this study we used dogs, since other animal models, like mice, rats, and rabbits, have a short life expectancy and small body size, and hence cannot be used to perform the precise surgical procedures. As the IAN is located within the mandibular canal surrounded by bone, a surgical technique is necessary to avoid nerve and blood vessel damage when performing nerve reconstruction. An important technical tip for the procedure is to carefully remove the mandibular bone plate in order to minimize the risk of nerve and vessel injury. Traditional burs and micro saws cannot distinguish between hard and soft tissue²¹. Additionally, these tools tend to slip causing damaging the adjacent tissue, especially the IAN, by accidental contact²². We therefore used piezoelectric surgical tools for the bone processing steps. This is a new and innovative bone surgery technique that uses ultrasonic microvibrations of specialized scalpels. Therefore, soft tissue are not damaged even upon accidental contact with the cutting tips²³⁻²⁴. Microvibrations of 60 – 200 $\mu\text{m/s}$ at 24 – 29 kHz are optimal for cutting elastic mineralized tissue while sparing elastic soft tissue; this is not possible at frequencies above 50 kHz²⁵. Moreover, rotational burs or oscillating saws require a force to counteract the rotation or vibration of the instrument. Compared to these instruments, piezoelectric surgical tools do not need application of extra force and so safe and accurate bone processing is possible²⁶. This is especially important in the hands of a novel user.

Another important aspect in our method is that the bone plate was not fixed using metallic plates but was placed in its original position in the mandible after the placement of the PGA-C tube. The reason for this was to avoid the risk of exposure of the plate to oral mucosal necrosis, which arises when using metallic plates for fixation. However, in some cases the bone plate deviated

from the original site. Therefore, it is crucial to perform a CT scan of the facial bone to confirm that the mandibular bone plate is in the proper position after surgery. When using a metallic plate for fixation, tight suturing should be avoided as it may cause oral mucosal necrosis due to blood flow disturbances.

CSGB is an effective treatment for peripheral vascular diseases and pain syndromes of the face and neck¹³⁻¹⁵. However, the mechanisms underlying its therapeutic effects remain unclear. One reason for the lack of research on the therapeutic effects of CSGB is the difficulty in obtaining a consistent and uniform sympatholytic effect. For example, the spread of sympathetic blockade after percutaneous CSGB is not uniform²⁷⁻²⁸. Mullenheim *et al.*²⁹ implanted dogs with a polyethylene catheter, after thoracotomy, under the fascia and alongside the upper sympathetic chain, and performed CSGB by injecting lidocaine via the catheter. Although this approach can spread sympathetic blockade at the targeted areas, it carries risks of catheter occlusion or dislocation, as well as infection, especially in long-term experiments. In our canine model of CSGB, the direct injection of 99.5% ethanol produced long-term increases in blood flow to the ipsilateral orofacial region. In our approach, block injection was administered under direct visualization, so CSGB could be performed with precision. Therefore, our approach reduces the risk of uneven spread of the sympatholytic effect and of the sympathetic blockade. This is considered to be advantageous especially in long-term experiments. Moreover, we used thermography to confirm the success of CSGB, since facial skin temperature increases on the block side upon successful CSGB. In this case, thermography is useful, because it is simple and noninvasive. Importantly, the nasal and not the facial skin temperature should be measured, since it is not affected by the dog's hair. Our model could contribute to further research on the therapeutic effects of CSGB. In our previous study, blood flow in the orofacial area increased for 6-11 weeks after cervical sympathetic ganglionectomy. Researchers can choose this alternative method³⁰ if desired.

The limitation of this study is that ethanol-induced CSGB poses the risk of developing permanent Horner's syndrome (ptosis and miosis)³¹. Other methods, including radiofrequency ablation, phenol, and sympathetic ganglionectomy have been used for performing sympathectomies; however, specifically for sympathectomy of the cervical sympathetic ganglion, only radiofrequency ablation has been employed in clinical practice³²⁻³⁵. Therefore, radiofrequency ablation and local anesthetics can be considered as an alternative method to ethanol-induced CSGB. Future studies would be necessary to validate how nerve regeneration mediated by a bioabsorbable nerve tube can be enhanced by CSGB with a local anesthetic or radiofrequency ablation.

ACKNOWLEDGMENTS:

This work was supported by the Department of Bioartificial Organs in Kyoto University Institute for Frontier Medical Science. We would like to thank the veterinary staff of the Institute for Frontier Medical Science.

DISCLOSURES:

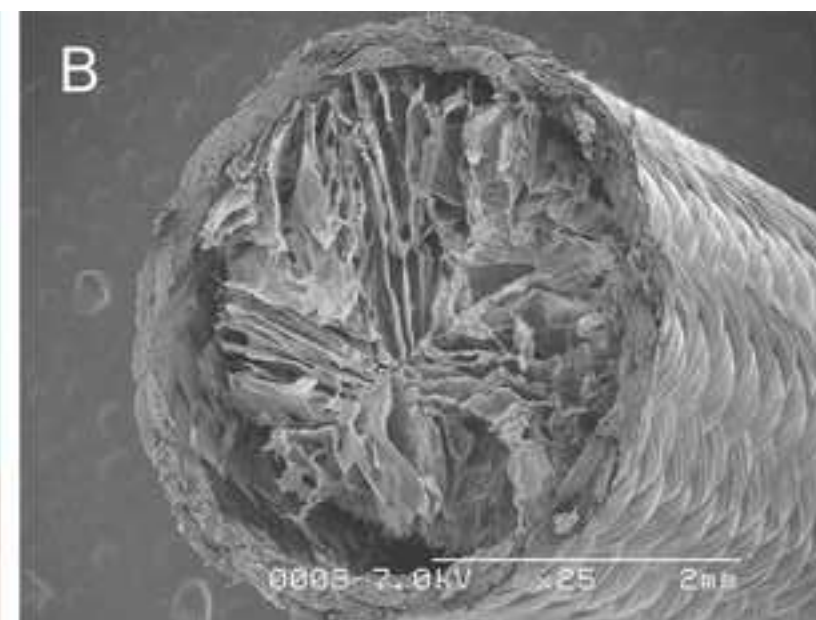

The authors have nothing to disclose.

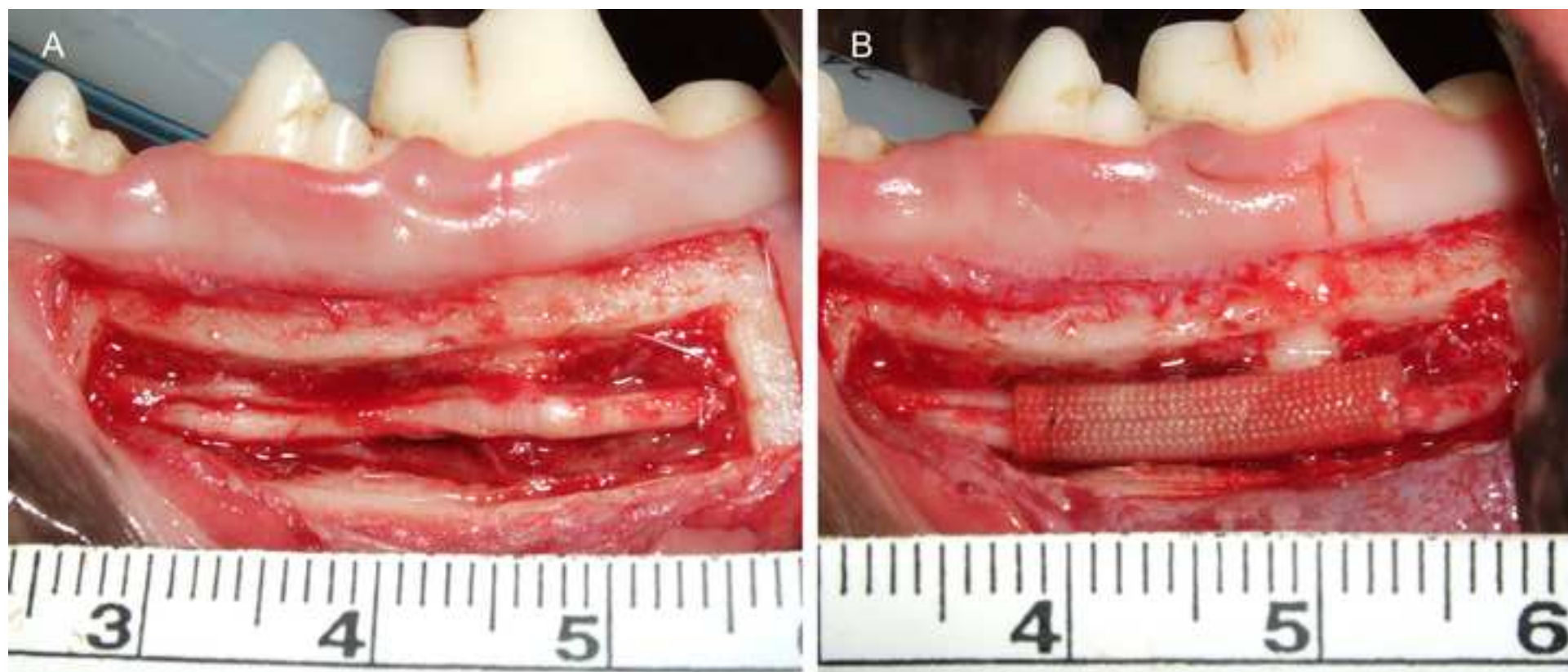
REFERENCES:

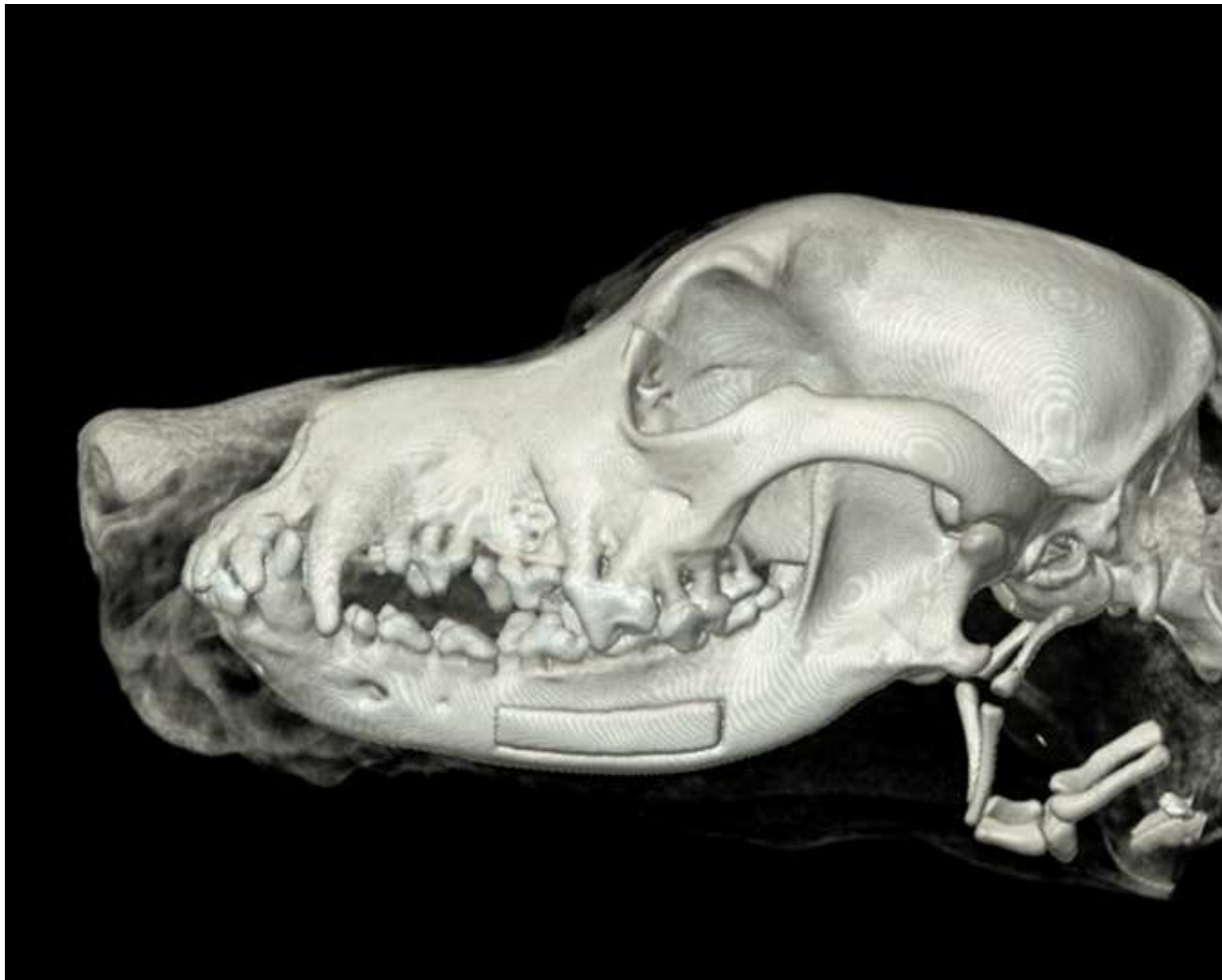
1. Al-Sabbagh, M., Okeson, J.P., Bertoli, E., Medynski, D.C., Khalaf, M.W. Persistent pain and neurosensory disturbance after dental implant surgery: prevention and treatment. *Dental Clinics of North America*. **59** (1), 143-156 (2015).
2. Chaushu, G., Taicher, S., Halamish-Shani, T., Givol, N. Medicolegal aspects of altered sensation following implant placement in the mandible. *International Journal of Oral and Maxillofacial Implants*. **17** (3), 413-415 (2002).
3. Robinson, P.P., Loescher, A.R., Yates, J.M., Smith, K.G. Current management of damage to the inferior alveolar and lingual nerves as a result of removal of third molars. *British Journal of Oral and Maxillofacial Surgery*. **42** (4), 285-292 (2004).
4. Gregg, J.M. Studies of traumatic neuralgia in the maxillofacial region: symptom complexes and response to microsurgery. *Journal of Oral and Maxillofacial Surgery*. **48** (2), 135-140 (1990).
5. Pogre, M.A. The results of microneurosurgery of the inferior alveolar and lingual nerve. *Journal of Oral and Maxillofacial Surgery*. **60** (5), 485-489 (2002).
6. Strauss, E.R., Ziccardi, V.B., Janal, M.N. Outcome assessment of inferior alveolar nerve microsurgery: a retrospective review. *Journal of Oral and Maxillofacial Surgery*. **64** (12), 1767-1770 (2006).
7. Nakamura, T., et al. Experimental study on the regeneration of peripheral nerve gaps through a polyglycolic acid-collagen (PGA-collagen) tube. *Brain Research*. **1027** (1-2), 18-29 (2004).
8. Yoshitani, M., et al. Experimental repair of phrenic nerve using a polyglycolic acid and collagen tube. *Journal of Thoracic and Cardiovascular Surgery*. **133** (3), 726-732 (2007).
9. Seo, K., et al. One-year outcome of damaged lingual nerve repair using a PGA-collagen tube: a case report. *Journal of Oral and Maxillofacial Surgery*. **66** (7), 1481-1484 (2008).
10. Seo, K., et al. Protracted delay in taste sensation recovery after surgical lingual nerve repair: a case report. *Journal of Medical Case Reports*. **7**, 77 (2013).
11. Seo, K., Terumitsu, M., Inada, Y., Nakamura, T., Shigeno, K., Tanaka, Y. Prognosis after surgical treatment of trigeminal neuropathy with a PGA-c tube: report of 10 Cases. *Pain Medicine*. **17** (12), 2360-2368 (2016).
12. Okuda, Y., Kitajima, T. Comparison of stellate ganglion block with intravascular infusion of prostaglandin e1 on brachial artery blood flow in dogs. *Anesthesia and Analgesia*. **84** (6), 1329-1332 (1997).
13. Kohjitani, A., Miyawaki, T., Kasuya, K., Shimada, M. Sympathetic activity-mediated neuropathic facial pain following simple tooth extraction: a case report. *Cranio*. **20** (2), 135-138 (2002).
14. Melis, M., Zawawi, K., al-Badawi, E., Lobo Lobo, S., Mehta N. Complex regional pain syndrome in the head and neck: a review of the literature. *Journal of Orofacial Pain*. **16** (2), 93-104 (2002).
15. Salvaggio, I., Adducci, E., Dell'Aquila, L., Rinaldi, S., Marini, M., Zappia, L., Mascaro, A. Facial pain: a possible therapy with stellate ganglion block. *Pain Medicine*. **9** (7), 958-962 (2008).
16. Atsumi, M., Sunada, K. The effect of superior cervical ganglion resection on peripheral facial palsy in rats. *Journal of Anesthesia*. **30** (4), 677-683 (2016).
17. Hanamatsu, N., Yamashiro, M., Sumitomo, M., Furuya, H. Effectiveness of cervical sympathetic ganglia block on regeneration of the trigeminal nerve following transection in rats. *Regional Anesthesia and Pain Medicine*. **27** (3), 268-276 (2002).

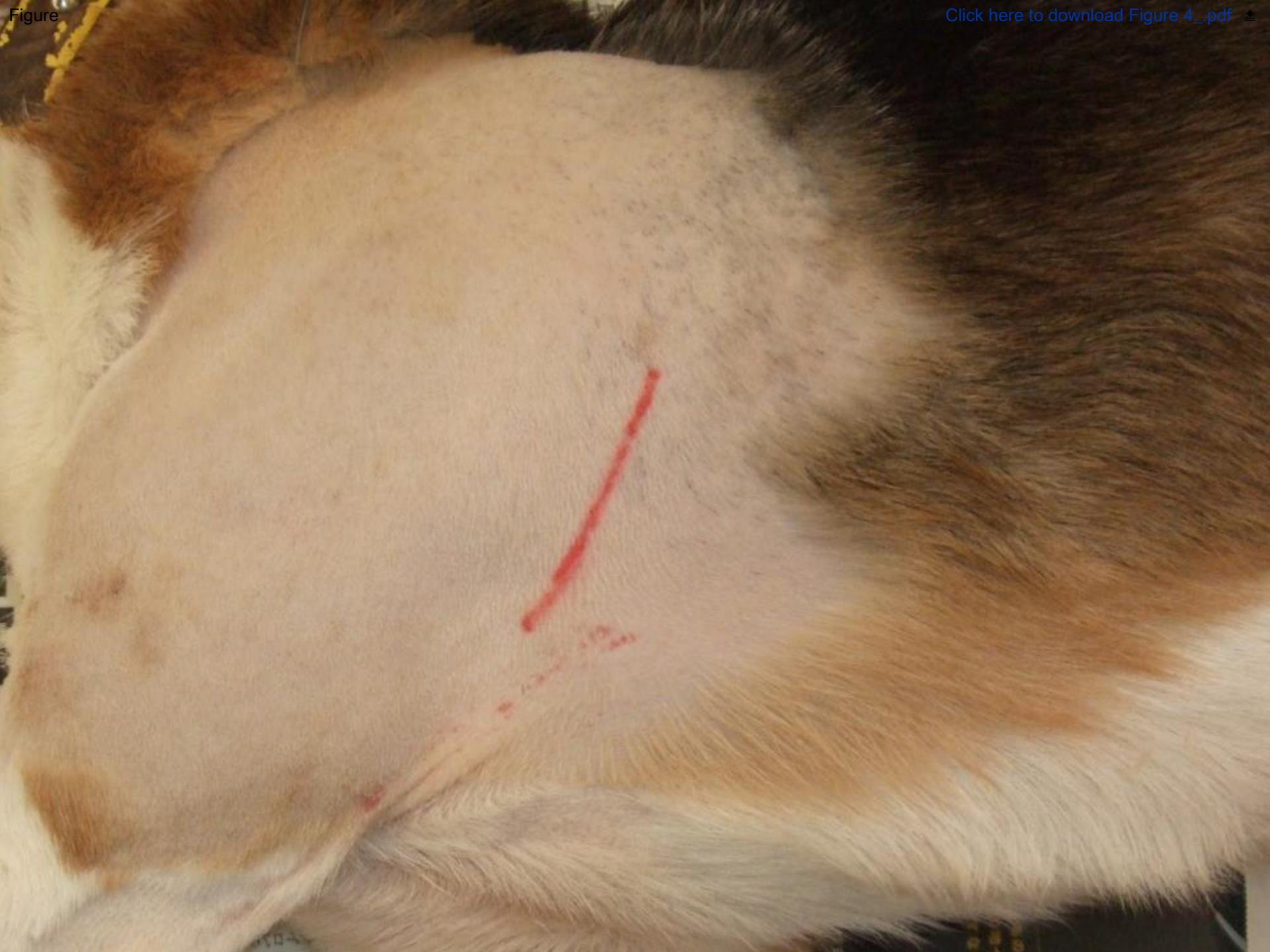18. Shionoya, Y., Sunada, K., Shigeno, K., Nakada, A., Honda, M., Nakamura T. Can nerve regeneration on an artificial nerve conduit be enhanced by ethanol-induced cervical sympathetic ganglion block? *PLoS One*. **12** (12), e0189297 (2017).
19. Suzuki, Y., Tanihara, M., Ohnishi, K., Suzuki, K., Endo, K., Nishimura, Y. Cat peripheral nerve regeneration across 50 mm gap repaired with a novel nerve guide composed of freeze-dried alginate gel. *Neuroscience Letters*. **259** (2), 75-78 (1999).
20. Ichihara, S., et al. Development of new nerve guide tube for repair of long nerve defects. *Tissue Engineering, Part C, Methods*. **15** (3), 387-402 (2009).
21. Grenga, V., Bovi, M. Piezoelectric surgery for exposure of palatally impacted canines. *Journal of Clinical Orthodontics*. **38**, 446-448 (2004).
22. Degerliyurt, K., Akar, V., Denizci, S., Yucel, E. Bone lid technique with piezosurgery to preserve inferior alveolar nerve. *Oral Surgery, Oral Medicine, Oral Pathology, Oral Radiology, and Endodontology*. **108** (6), e1-5 (2009).
23. Kotrikova, B., et al. Piezosurgery-a new safe technique in cranial osteoplasty? *International Journal of Oral and Maxillofacial Surgery*. **35** (5), 461-465 (2006).
24. Vercellotti, T. Piezoelectric surgery in implantology: a case report-a new piezoelectric ridge expansion technique. *International Journal of Periodontics and Restorative Dentistry*. **20** (4), 358-365 (2000).
25. Stübinger, S., Kuttenger, J., Filippi, A., Sader, R., Zeilhofer, H.F. Intraoral piezosurgery: Preliminary results of a new technique. *Journal of Oral and Maxillofacial Surgery*. **63** (9), 1283-1287 (2005).
26. Eggers, G., Klein, J., Blank, J., Hassfeld, S. Piezosurgery: an ultrasound device for cutting bone and its use and limitations in maxillofacial surgery. *British Journal of Oral and Maxillofacial Surgery*. **42** (5), 451-453 (2004).
27. Hardy, P.A., Wells, J.C. Extent of sympathetic blockade after stellate ganglion block with bupivacaine. *Pain*. **36** (2), 193-196 (1989).
28. Hogan, Q.H., Erickson, S.J., Haddox, J.D., Abram, S.E. The spread of solutions during stellate ganglion block. *Regional Anesthesia*. **17** (2), 78-83 (1992).
29. Mullenheim, J., et al. Left stellate ganglion block has only small effects on left ventricular function in awake dogs before and after induction of heart failure. *Anesthesia and Analgesia*. **91** (4), 787-792 (2000).
30. Tsujimoto, G., Sunada, K., Nakamura, T. Effect of cervical sympathetic ganglionectomy on facial nerve reconstruction using polyglycolic acid-collagen tubes. *Brain Research*. **1669**, 79-88 (2017).
31. Ghai, A., Kaushik, T., Kumar, R., Wadhera, S. Chemical ablation of stellate ganglion for head and neck cancer pain. *Acta Anaesthesiologica Belgica*. **67** (1), 6-8 (2016).
32. Forouzanfar, T., van Kleef, M., Weber, W.E. Radiofrequency lesions of the stellate ganglion in chronic pain syndromes: retrospective analysis of clinical efficacy in 86 patients. *Clinical Journal of Pain*. **16** (2), 164-168 (2000).
33. Ohno, K., Oshita, S. Transdiscal lumbar sympathetic block: a new technique for a chemical sympathectomy. *Anesthesia and Analgesia*. **85** (6), 1312-1316 (1997).
34. Slappendel, R., Thijssen, H.O., Crul, B.J., Merx, J.L. The stellate ganglion in magnetic resonance imaging: a quantification of the anatomic variability. *Anesthesiology*. **83** (2), 424-426 (1995).

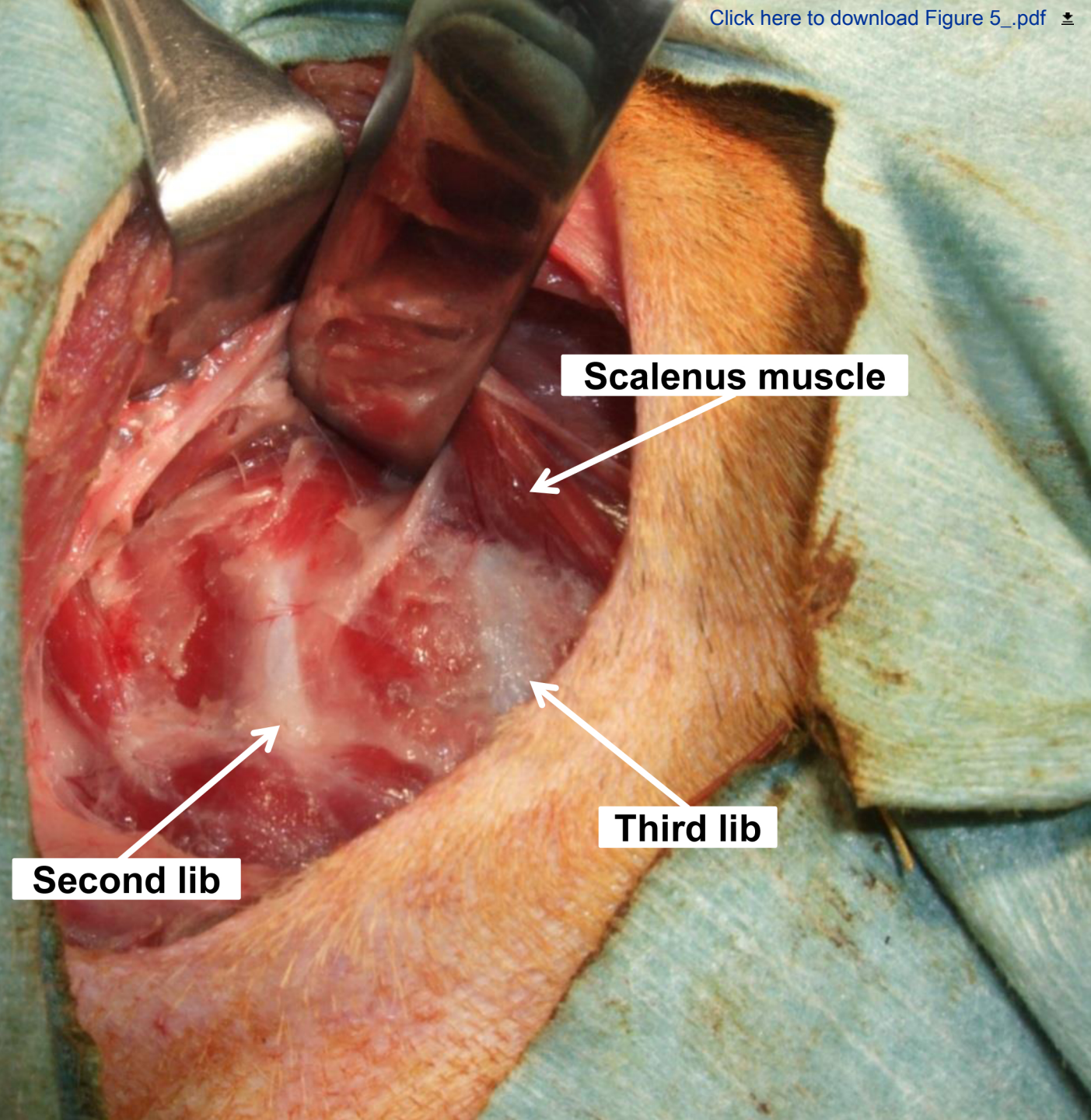
614 35. Wang, Y.C., Wei, S.H., Sun, M.H., Lin, C.W. A new mode of percutaneous upper thoracic
615 phenol sympathectomy: report of 50 cases. *Neurosurgery*. **49** (3), 628-634 (2001).



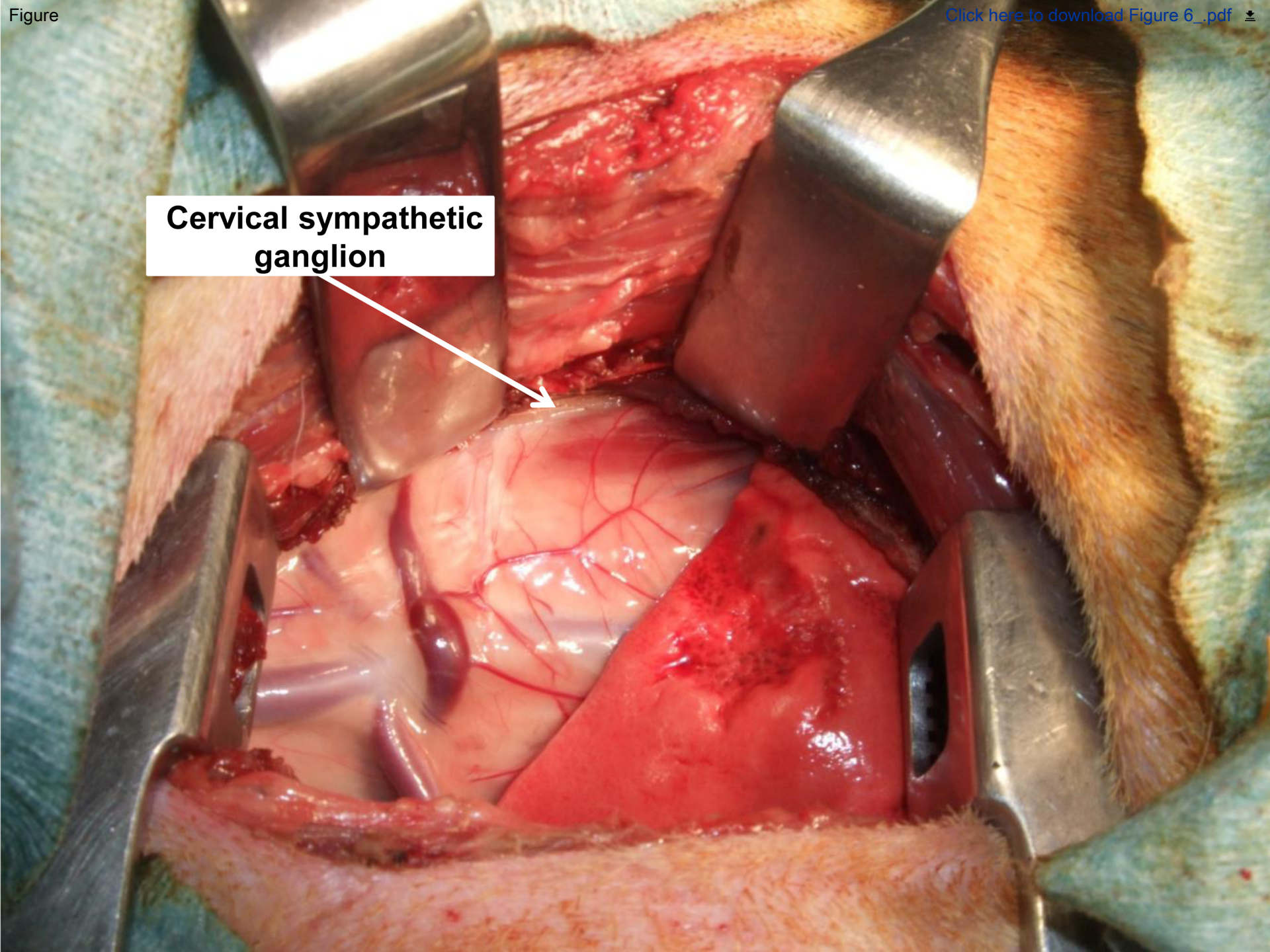


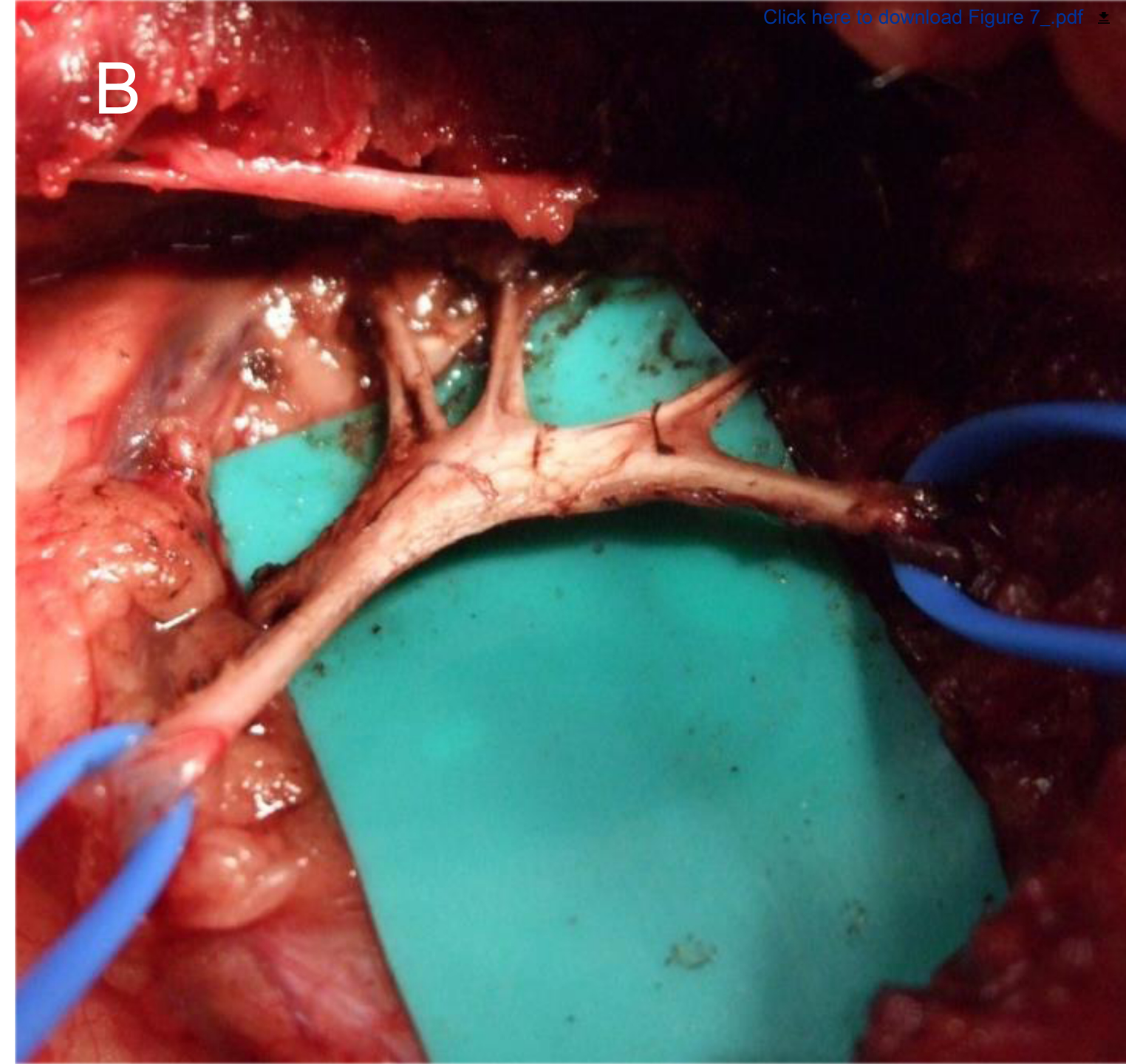
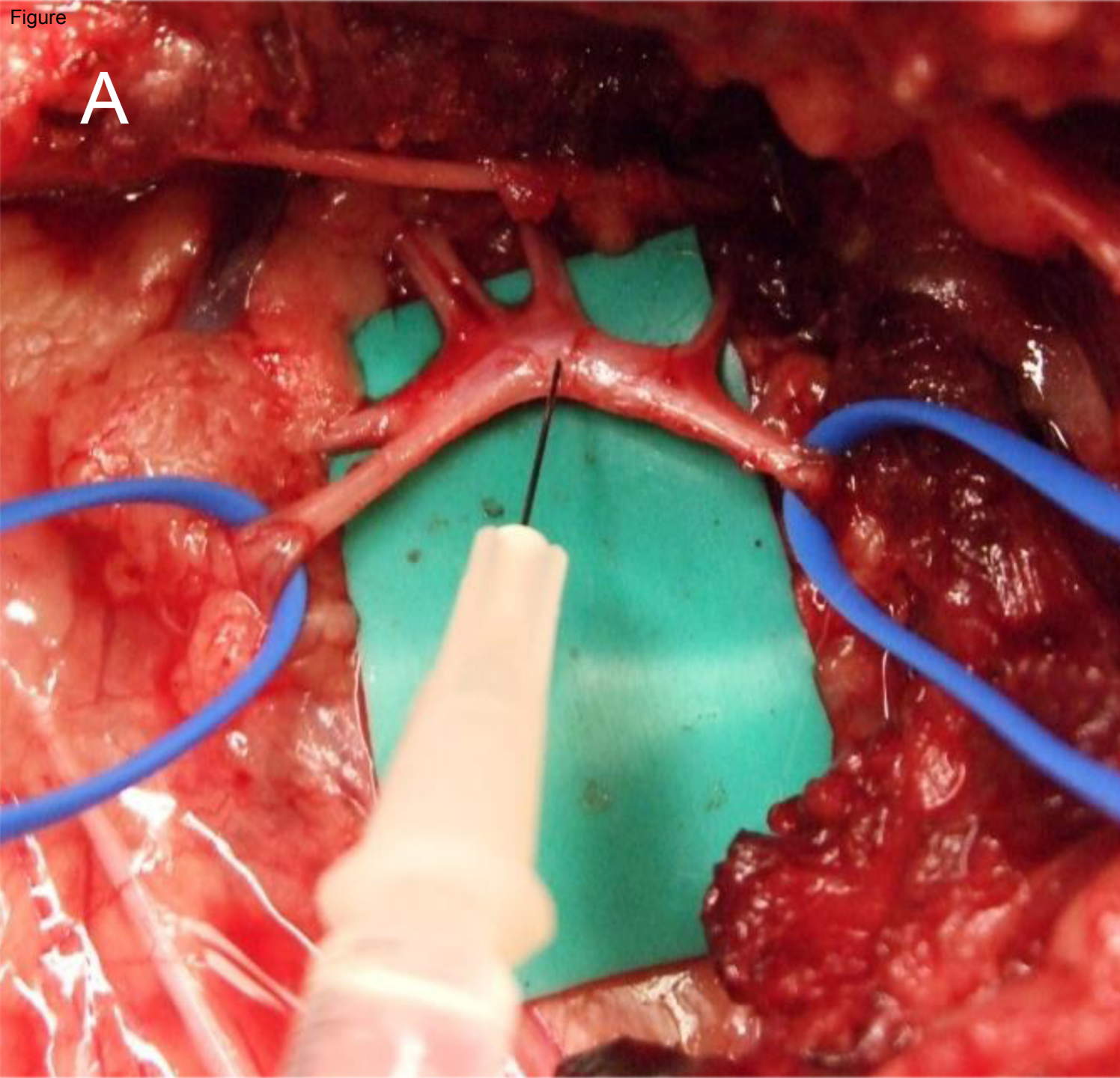


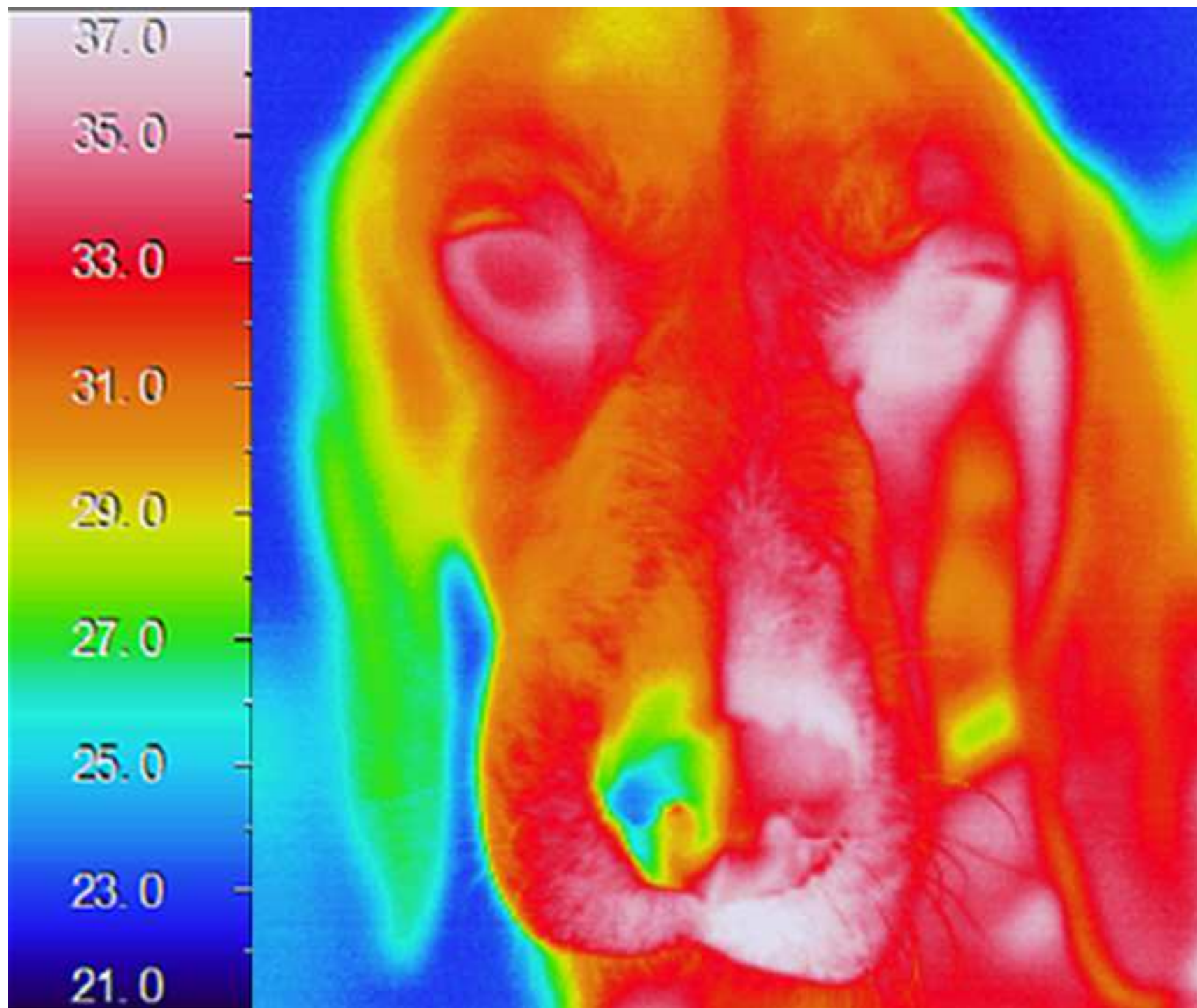


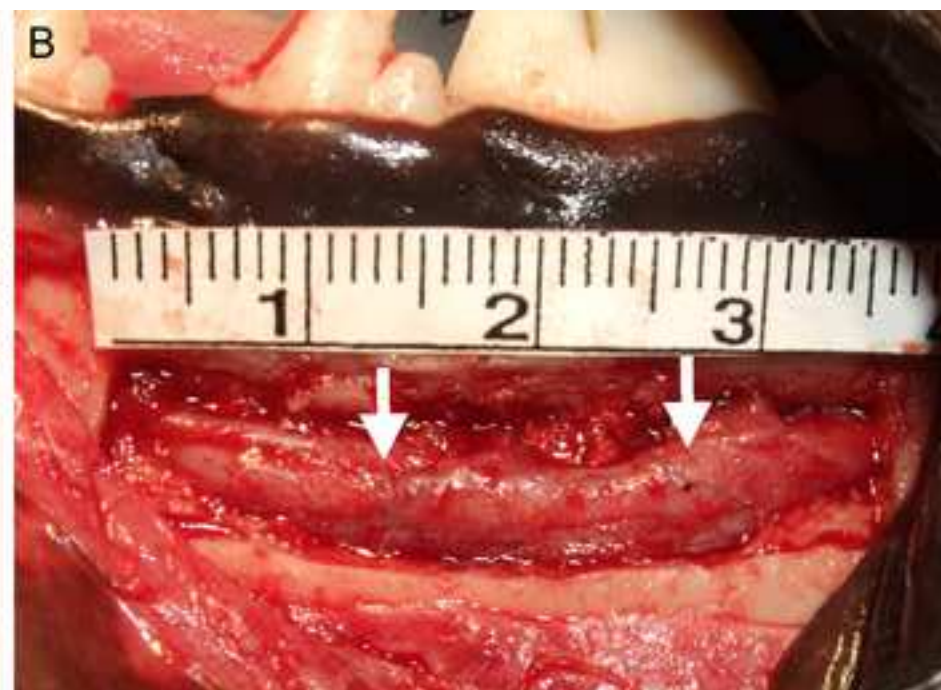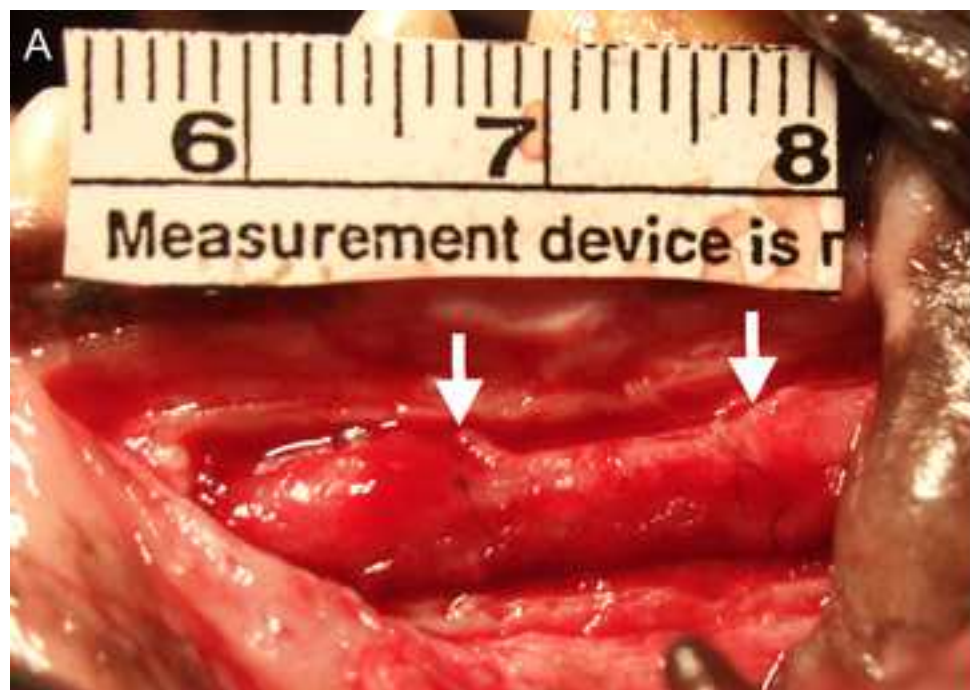


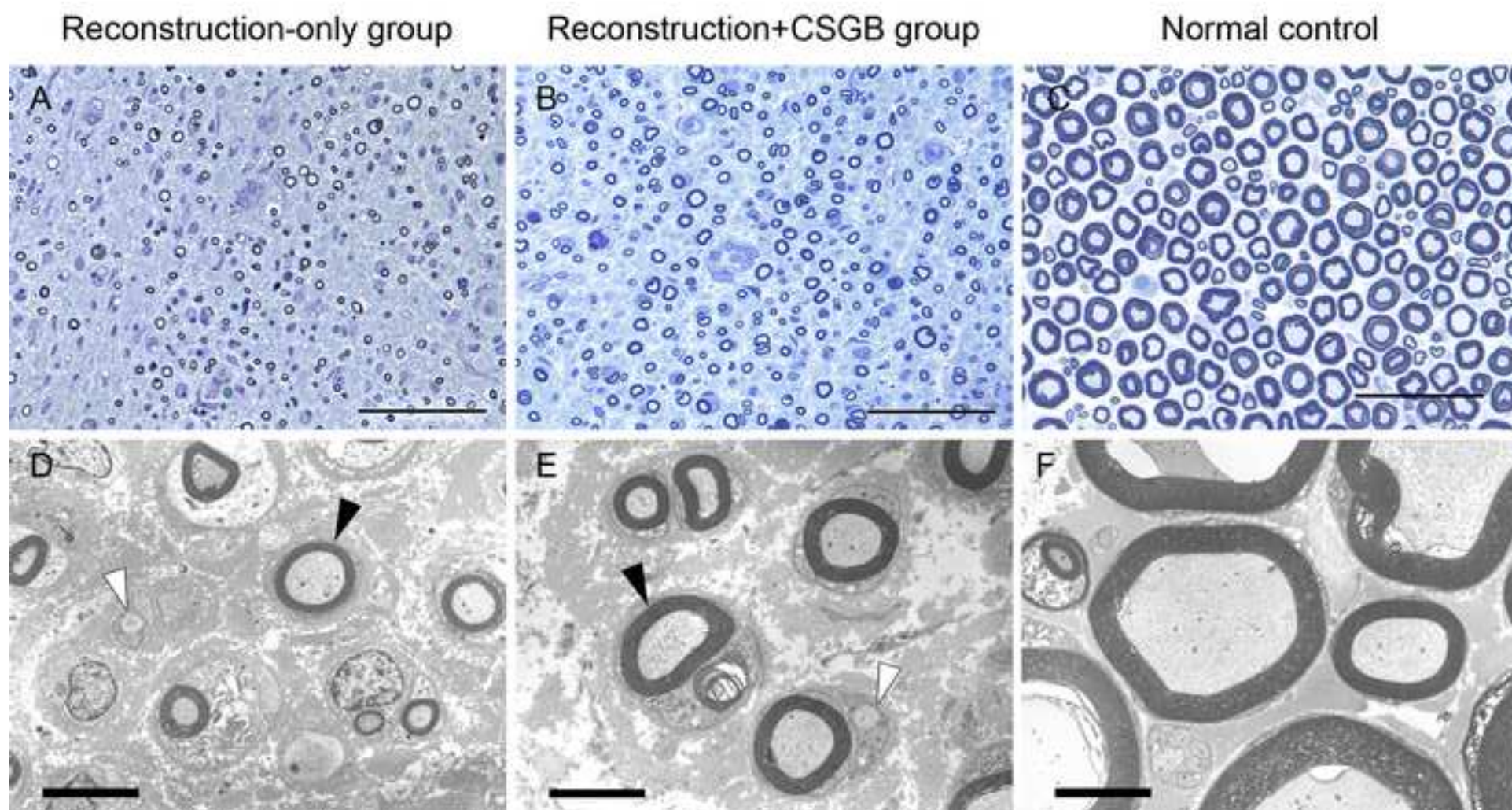
**Cervical sympathetic
ganglion**



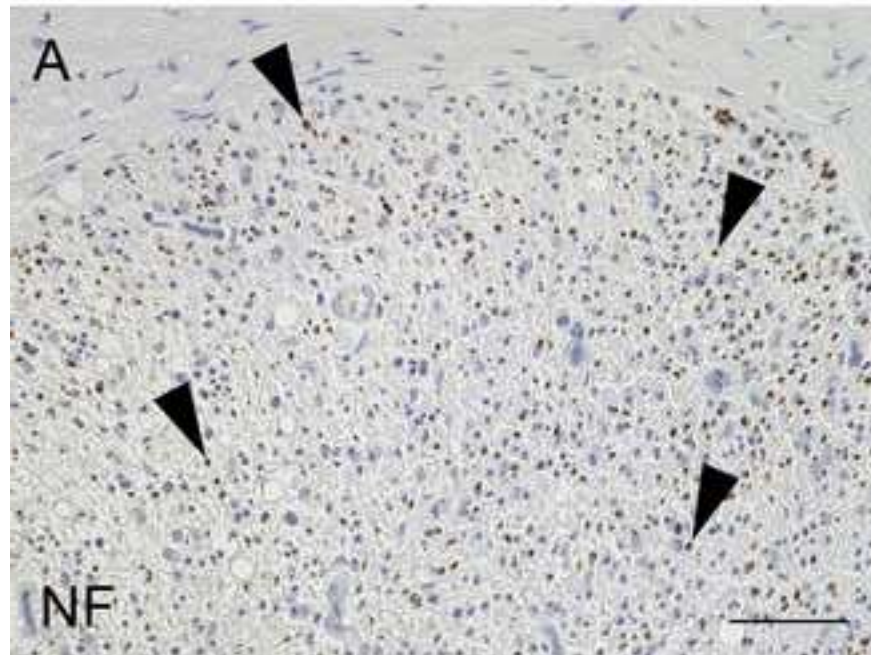








Reconstruction only group



Reconstruction+SGB group

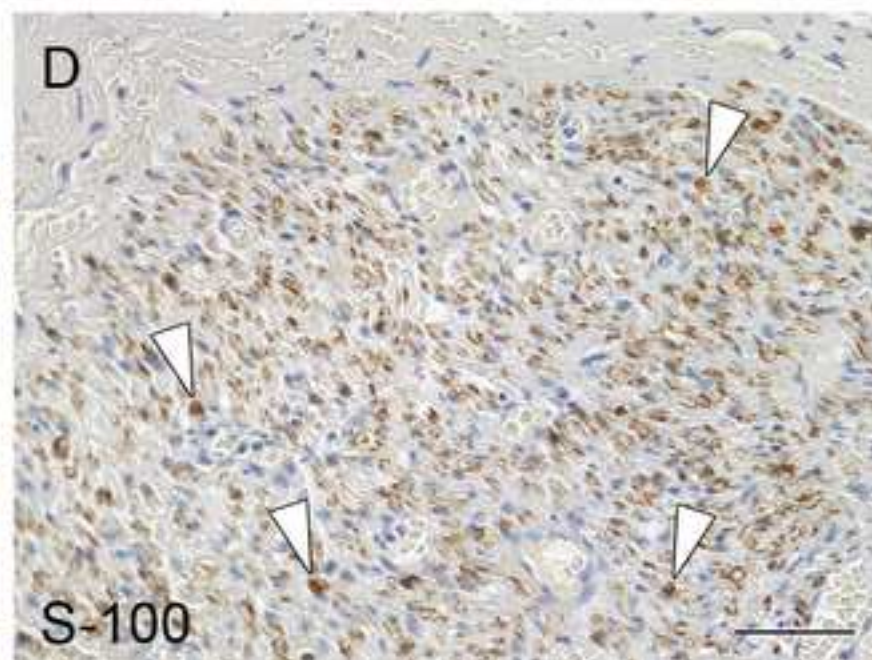
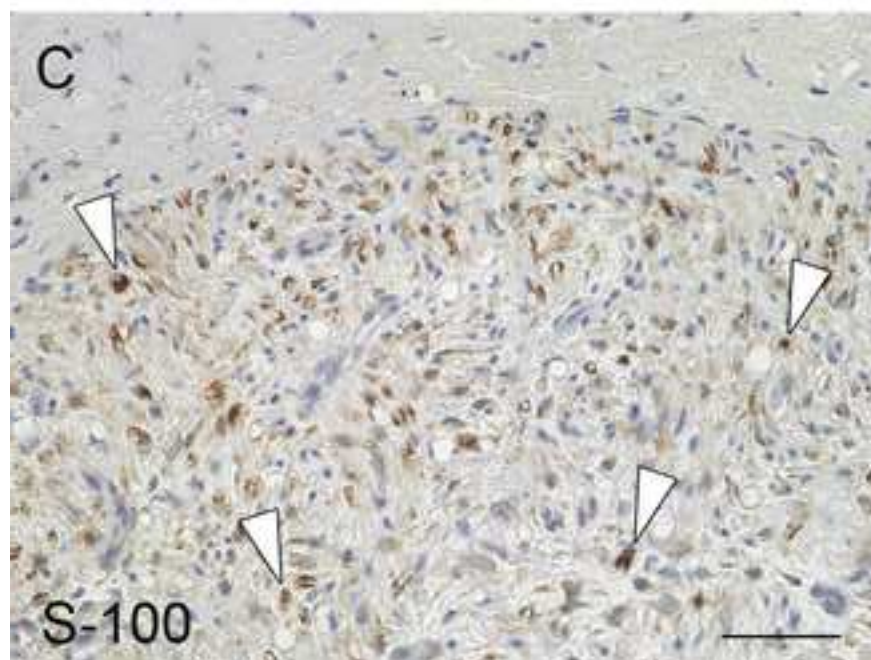
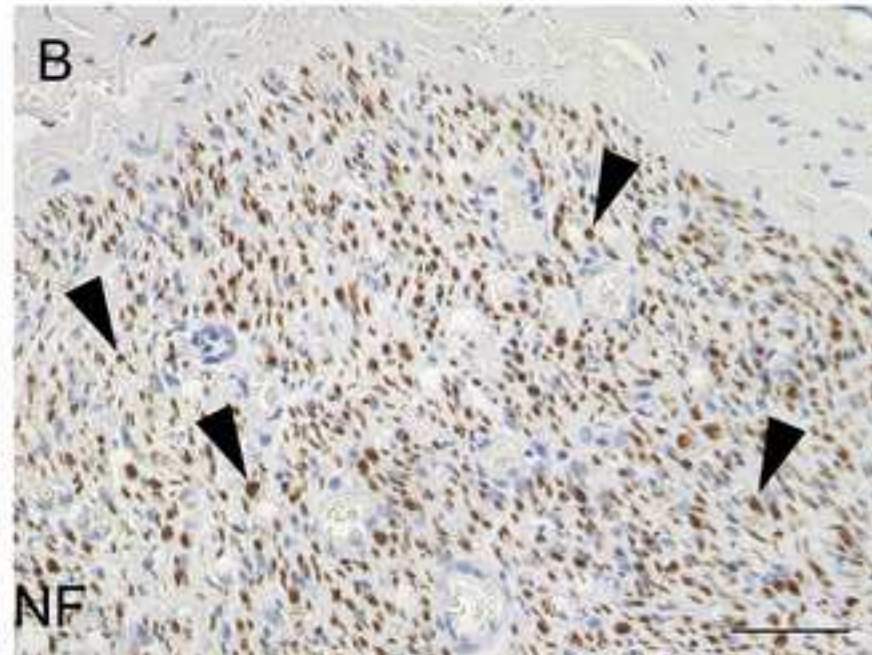


Table 1. Electrophysiological fin

Normal control
Reconstruction-only group
Reconstruction+CSGB group

dings in the IAN at 3 months aft

Sensory nerve conduction
(m/s)

48.5 ± 2.8

36.8 ± 2.9*

42.0 ± 2.4*[#]

ter surgery

Recovery index

—

0.22 ± 0.04

$0.35 \pm 0.06^{\#}$

Table 2. Morphological findings in the IAN at 3 months

		Myelinated nerve fiber diameter (μm)
Normal control	Center	8.83 ± 3.11
Reconstruction- only group	Center	$4.27 \pm 1.5^*$
	Distal	$3.47 \pm 1.21^*$
Reconstruction+C SGB group	Center	$5.11 \pm 1.98^{* \#}$
	Distal	$4.53 \pm 1.36^{* \$}$

ths after surgery

Myelinated nerve fiber density (count/100 μm^2)	Proportion of nerve tissue (%)	G ratio
103 \pm 8	41.3 \pm 3.9	0.62 \pm 0.03
126 \pm 20*	11.6 \pm 2.1*	0.75 \pm 0.04*
109 \pm 17*	7.3 \pm 2.0*	0.74 \pm 0.04*
140 \pm 22* [#]	15.9 \pm 3.0* [#]	0.68 \pm 0.05* [#]
123 \pm 15* ^{\$}	12.5 \pm 2.1* ^{\$}	0.69 \pm 0.04* ^{\$}

Name of Material/ Equipment	Company	Catalog Number
NMP Collagen PS	Nippon Meatpackers	301-84621
Surgical clippers	Roboz Surgical Instrument Company	RC-5903
Disposable scalpel (No.15)	Kai medical	219ABBZX00073000
VarioSurg3	Nakanishi	VS3-LED-HPSC, E1133
4-0 nylon sutures	Ethicon	8881H
8-0 nylon sutures	Ethicon	2775G
Isepamicin sulfate	Nichi-Iko	620005641
Disposable scalpel (No.10)	Kai medical	219ABBZX00073000
30-gauge needle	Nipro	1134
1-0 absorbable stitches	Ethicon	J347H
3-0 Nylon stitches	Ethicon	8872H
Neo Thermo	NEC Avio	TVS-700
Neuropack Σ	NIHON KOHDEN	MEB-5504
Toluidine Blue	Sigma-Aldrich	T3260-5G
Light microscope	Keyence	BZ-9000
Mouse anti-human neurofilament protein monoclonal antibody	DAKO	N1591
Polyclonal rabbit anti-S100 antibody	DAKO	Z0311
Transmission electron microscopy	Hitachi High Technologies	Hitachi H-7000
Dynamic cell count	Keyence	BZ-H1C

Comments/Description

Atelocollagen extracted from young porcine skin by enzyme treatment

Piezoelectric surgery for bone processing

Infrared thermography

Orthodromic recorder for electrophysiological recording

Software for morphological evaluation



1 Alewife Center #200
 Cambridge, MA 02140
 tel. 617.945.9051
www.jove.com

ARTICLE AND VIDEO LICENSE AGREEMENT

Title of Article:

Ethanol-induced cervical sympathetic ganglion block applications for promoting canine inferior alveolar nerve regeneration using an artificial nerve.

Author(s):

Yoshiki Shiono, Katsuhisa Sunada, Gentaro Tsujimoto, Keiji Shigeno, Tatsuo Nakamura

Item 1 (check one box): The Author elects to have the Materials be made available (as described at <http://www.jove.com/author>) via: ☒ Standard Access ☐ Open Access

Item 2 (check one box):

- ☒ The Author is NOT a United States government employee.
- ☐ The Author is a United States government employee and the Materials were prepared in the course of his or her duties as a United States government employee.
- ☐ The Author is a United States government employee but the Materials were NOT prepared in the course of his or her duties as a United States government employee.

ARTICLE AND VIDEO LICENSE AGREEMENT

1. **Defined Terms.** As used in this Article and Video License Agreement, the following terms shall have the following meanings: "**Agreement**" means this Article and Video License Agreement; "**Article**" means the article specified on the last page of this Agreement, including any associated materials such as texts, figures, tables, artwork, abstracts, or summaries contained therein; "**Author**" means the author who is a signatory to this Agreement; "**Collective Work**" means a work, such as a periodical issue, anthology or encyclopedia, in which the Materials in their entirety in unmodified form, along with a number of other contributions, constituting separate and independent works in themselves, are assembled into a collective whole; "**CRC License**" means the Creative Commons Attribution-Non Commercial-No Derivs 3.0 Unported Agreement, the terms and conditions of which can be found at: <http://creativecommons.org/licenses/by-nc-nd/3.0/legalcode>; "**Derivative Work**" means a work based upon the Materials or upon the Materials and other pre-existing works, such as a translation, musical arrangement, dramatization, fictionalization, motion picture version, sound recording, art reproduction, abridgment, condensation, or any other form in which the Materials may be recast, transformed, or adapted; "**Institution**" means the institution, listed on the last page of this Agreement, by which the Author was employed at the time of the creation of the Materials; "**JoVE**" means MyJoVE Corporation, a Massachusetts corporation and the publisher of *The Journal of Visualized Experiments*; "**Materials**" means the Article and / or the Video; "**Parties**" means the Author and JoVE; "**Video**" means any video(s) made by the Author, alone or in conjunction with any other parties, or by JoVE or its affiliates or agents, individually or in collaboration with the Author or any other parties, incorporating all or any portion of the Article, and in which the Author may or may not appear.

2. **Background.** The Author, who is the author of the Article, in order to ensure the dissemination and protection of the Article, desires to have the JoVE publish the Article and create and transmit videos based on the Article. In furtherance of such goals, the Parties desire to memorialize in this Agreement the respective rights of each Party in and to the Article and the Video.

3. **Grant of Rights in Article.** In consideration of JoVE agreeing to publish the Article, the Author hereby grants to JoVE, subject to **Sections 4 and 7** below, the exclusive, royalty-free, perpetual (for the full term of copyright in the Article, including any extensions thereto) license (a) to publish, reproduce, distribute, display and store the Article in all forms, formats and media whether now known or hereafter developed (including without limitation in print, digital and electronic form) throughout the world, (b) to translate the Article into other languages, create adaptations, summaries or extracts of the Article or other Derivative Works (including, without limitation, the Video) or Collective Works based on all or any portion of the Article and exercise all of the rights set forth in (a) above in such translations, adaptations, summaries, extracts, Derivative Works or Collective Works and (c) to license others to do any or all of the above. The foregoing rights may be exercised in all media and formats, whether now known or hereafter devised, and include the right to make such modifications as are technically necessary to exercise the rights in other media and formats. If the "Open Access" box has been checked in **Item 1** above, JoVE and the Author hereby grant to the public all such rights in the Article as provided in, but subject to all limitations and requirements set forth in, the CRC License.

ARTICLE AND VIDEO LICENSE AGREEMENT

4. **Retention of Rights in Article.** Notwithstanding the exclusive license granted to JoVE in **Section 3** above, the Author shall, with respect to the Article, retain the non-exclusive right to use all or part of the Article for the non-commercial purpose of giving lectures, presentations or teaching classes, and to post a copy of the Article on the Institution's website or the Author's personal website, in each case provided that a link to the Article on the JoVE website is provided and notice of JoVE's copyright in the Article is included. All non-copyright intellectual property rights in and to the Article, such as patent rights, shall remain with the Author.

5. **Grant of Rights in Video – Standard Access.** This **Section 5** applies if the "Standard Access" box has been checked in **Item 1** above or if no box has been checked in **Item 1** above. In consideration of JoVE agreeing to produce, display or otherwise assist with the Video, the Author hereby acknowledges and agrees that, Subject to **Section 7** below, JoVE is and shall be the sole and exclusive owner of all rights of any nature, including, without limitation, all copyrights, in and to the Video. To the extent that, by law, the Author is deemed, now or at any time in the future, to have any rights of any nature in or to the Video, the Author hereby disclaims all such rights and transfers all such rights to JoVE.

6. **Grant of Rights in Video – Open Access.** This **Section 6** applies only if the "Open Access" box has been checked in **Item 1** above. In consideration of JoVE agreeing to produce, display or otherwise assist with the Video, the Author hereby grants to JoVE, subject to **Section 7** below, the exclusive, royalty-free, perpetual (for the full term of copyright in the Article, including any extensions thereto) license (a) to publish, reproduce, distribute, display and store the Video in all forms, formats and media whether now known or hereafter developed (including without limitation in print, digital and electronic form) throughout the world, (b) to translate the Video into other languages, create adaptations, summaries or extracts of the Video or other Derivative Works or Collective Works based on all or any portion of the Video and exercise all of the rights set forth in (a) above in such translations, adaptations, summaries, extracts, Derivative Works or Collective Works and (c) to license others to do any or all of the above. The foregoing rights may be exercised in all media and formats, whether now known or hereafter devised, and include the right to make such modifications as are technically necessary to exercise the rights in other media and formats. For any Video to which this Section 6 is applicable, JoVE and the Author hereby grant to the public all such rights in the Video as provided in, but subject to all limitations and requirements set forth in, the CRC License.

7. **Government Employees.** If the Author is a United States government employee and the Article was prepared in the course of his or her duties as a United States government employee, as indicated in **Item 2** above, and any of the licenses or grants granted by the Author hereunder exceed the scope of the 17 U.S.C. 403, then the rights granted hereunder shall be limited to the maximum rights permitted under such

statute. In such case, all provisions contained herein that are not in conflict with such statute shall remain in full force and effect, and all provisions contained herein that do so conflict shall be deemed to be amended so as to provide to JoVE the maximum rights permissible within such statute.

8. **Likeness, Privacy, Personality.** The Author hereby grants JoVE the right to use the Author's name, voice, likeness, picture, photograph, image, biography and performance in any way, commercial or otherwise, in connection with the Materials and the sale, promotion and distribution thereof. The Author hereby waives any and all rights he or she may have, relating to his or her appearance in the Video or otherwise relating to the Materials, under all applicable privacy, likeness, personality or similar laws.

9. **Author Warranties.** The Author represents and warrants that the Article is original, that it has not been published, that the copyright interest is owned by the Author (or, if more than one author is listed at the beginning of this Agreement, by such authors collectively) and has not been assigned, licensed, or otherwise transferred to any other party. The Author represents and warrants that the author(s) listed at the top of this Agreement are the only authors of the Materials. If more than one author is listed at the top of this Agreement and if any such author has not entered into a separate Article and Video License Agreement with JoVE relating to the Materials, the Author represents and warrants that the Author has been authorized by each of the other such authors to execute this Agreement on his or her behalf and to bind him or her with respect to the terms of this Agreement as if each of them had been a party hereto as an Author. The Author warrants that the use, reproduction, distribution, public or private performance or display, and/or modification of all or any portion of the Materials does not and will not violate, infringe and/or misappropriate the patent, trademark, intellectual property or other rights of any third party. The Author represents and warrants that it has and will continue to comply with all government, institutional and other regulations, including, without limitation all institutional, laboratory, hospital, ethical, human and animal treatment, privacy, and all other rules, regulations, laws, procedures or guidelines, applicable to the Materials, and that all research involving human and animal subjects has been approved by the Author's relevant institutional review board.

10. **JoVE Discretion.** If the Author requests the assistance of JoVE in producing the Video in the Author's facility, the Author shall ensure that the presence of JoVE employees, agents or independent contractors is in accordance with the relevant regulations of the Author's institution. If more than one author is listed at the beginning of this Agreement, JoVE may, in its sole discretion, elect not take any action with respect to the Article until such time as it has received complete, executed Article and Video License Agreements from each such author. JoVE reserves the right, in its absolute and sole discretion and without giving any reason therefore, to accept or decline any work submitted to JoVE. JoVE and its employees, agents and independent contractors shall have

ARTICLE AND VIDEO LICENSE AGREEMENT

full, unfettered access to the facilities of the Author or of the Author's institution as necessary to make the Video, whether actually published or not. JoVE has sole discretion as to the method of making and publishing the Materials, including, without limitation, to all decisions regarding editing, lighting, filming, timing of publication, if any, length, quality, content and the like.

11. Indemnification. The Author agrees to indemnify JoVE and/or its successors and assigns from and against any and all claims, costs, and expenses, including attorney's fees, arising out of any breach of any warranty or other representations contained herein. The Author further agrees to indemnify and hold harmless JoVE from and against any and all claims, costs, and expenses, including attorney's fees, resulting from the breach by the Author of any representation or warranty contained herein or from allegations or instances of violation of intellectual property rights, damage to the Author's or the Author's institution's facilities, fraud, libel, defamation, research, equipment, experiments, property damage, personal injury, violations of institutional, laboratory, hospital, ethical, human and animal treatment, privacy or other rules, regulations, laws, procedures or guidelines, liabilities and other losses or damages related in any way to the submission of work to JoVE, making of videos by JoVE, or publication in JoVE or elsewhere by JoVE. The Author shall be responsible for, and shall hold JoVE harmless from, damages caused by lack of sterilization, lack of cleanliness or by contamination due to the making of a video by JoVE its employees, agents or independent contractors. All sterilization, cleanliness or decontamination procedures shall be solely the responsibility of the Author and shall be undertaken at the Author's

expense. All indemnifications provided herein shall include JoVE's attorney's fees and costs related to said losses or damages. Such indemnification and holding harmless shall include such losses or damages incurred by, or in connection with, acts or omissions of JoVE, its employees, agents or independent contractors.

12. Fees. To cover the cost incurred for publication, JoVE must receive payment before production and publication of the Materials. Payment is due in 21 days of invoice. Should the Materials not be published due to an editorial or production decision, these funds will be returned to the Author. Withdrawal by the Author of any submitted Materials after final peer review approval will result in a US\$1,200 fee to cover pre-production expenses incurred by JoVE. If payment is not received by the completion of filming, production and publication of the Materials will be suspended until payment is received.

13. Transfer, Governing Law. This Agreement may be assigned by JoVE and shall inure to the benefits of any of JoVE's successors and assignees. This Agreement shall be governed and construed by the internal laws of the Commonwealth of Massachusetts without giving effect to any conflict of law provision thereunder. This Agreement may be executed in counterparts, each of which shall be deemed an original, but all of which together shall be deemed to be one and the same agreement. A signed copy of this Agreement delivered by facsimile, e-mail or other means of electronic transmission shall be deemed to have the same legal effect as delivery of an original signed copy of this Agreement.

A signed copy of this document must be sent with all new submissions. Only one Agreement required per submission.

CORRESPONDING AUTHOR:

Name: Yoshiki Shionoya
Department: Department of Dental Anesthesia
Institution: Nippon Dental University Hospital at Tokyo.
Article Title: Ethanol-induced cervical sympathetic ganglion block applications for promoting canine inferior alveolar nerve regeneration using an artificial nerve
Signature: Yoshiki Shionoya Date: 2/20/2018

Please submit a signed and dated copy of this license by one of the following three methods:

- 1) Upload a scanned copy of the document as a pdf on the JoVE submission site;
- 2) Fax the document to +1.866.381.2236;
- 3) Mail the document to JoVE / Attn: JoVE Editorial / 1 Alewife Center #200 / Cambridge, MA 02139

For questions, please email submissions@jove.com or call +1.617.945.9051

May, 12, 2018

Dear Alisha DSouza, Ph.D.
JoVE Scientific Review Editor
JoVE

Dear Editor:

I wish to re-submit the manuscript titled “Ethanol-induced cervical sympathetic ganglion block applications for promoting canine inferior alveolar nerve regeneration using an artificial nerve.” The manuscript ID is JoVE58039.

We thank you and the reviewers for your thoughtful suggestions and insights. The manuscript has benefited from these insightful suggestions. I look forward to working with you and the reviewers to move this manuscript closer to publication in the *JoVE*.

The manuscript has been rechecked and the necessary changes have been made in accordance with yours and the reviewers’ suggestions. The responses to all comments have been prepared and are given below.

Thank you for your consideration. I look forward to hearing from you.

Sincerely,

Yoshiki Shionoya

Department of Dental Anesthesia, Nippon Dental University Hospital at Tokyo,
Tokyo, Japan

Tel: +81-3-3261-6083

Email: ysk.shionoya@gmail.com

Responses to Reviewers

Ethanol-induced cervical sympathetic ganglion block applications for promoting canine inferior alveolar nerve regeneration using an artificial nerve

Response to JoVE Scientific Review Editor: We wish to express our appreciation for your insightful comments, which have helped us to significantly improve our manuscript.

Changes recommended by the JoVE Scientific Review Editor:

• **Textual Overlap:** Significant portions show significant overlap with previously published work. Please re-write the text indicated in red in the attached document to avoid this overlap.

Response: We agree with your comment. In order to avoid duplication with previously published works, we have re-written the text as much as possible.

• **Protocol Detail:**

Comment 1): 1.1.1-1.1.6 should not be substeps of 1.1.

*Response: We agree with your comment and have revised lines 105–128 as follows.
“1.1.1-1.1.6” → “1.2.-1.5.”*

Comment 2): 1.1: Please reference Fig 1 here.

Response: We have revised line 103, according to your comment.

Comment 3): 1.1.2: Needs a reference for extraction. What is the atelocollagen concentration?

Response: We have added more information on atelocollagen concentration and preparation (paragraph 1.3, lines 107-113) and added reference 7.

Comment 4): Lines 116-117: Need a reference.

Response: We have added reference 7 and revised this information as follows (lines 109-113):

“Note: Atelocollagen is extracted from porcine skin via enzyme treatment and subjected

to a virus check. It mainly consists of type I (70–80 %) and type III collagen, the ratio of which is described in detail in reference 7. Prepare the collagen solution by dissolving 1 g collagen in 100 mL hydrochloride solution (pH = 3.0). Since the density of the hydrochloride solution is approximately 1.0, the w/w collagen concentration is almost 1 %.”

Comment 5): 1.1.3: what is the collagen hydrochloride concentration in M or mg/ml? Please specify how many times should you dip and for how long should the tube be submerged during each dip? Should you dry the tube between dippings? Is temperature important?

Response: We agree with your comment and have revised lines 115–121 as follows:

“1.4. Coat the tube with the collagen layers by repeatedly dipping it into the 1 % collagen hydrochloride solution for 5 seconds each time.

1.4.1. After dipping, dry the tube on a clean bench at room temperature. Perform next dipping after ensuring the tube is completely dry (about 6 hours for air-drying).

1.4.2. Repeat the coating process 10 times.”

Comment 6): 1.1.4: Air dry? How is the tube handled?

Response: The tube was air-dried on a clean bench at room temperature. We have added this information in paragraph 1.4.1. All processes were carefully performed under aseptic conditions. We have revised lines 124-125 as follows:

“Perform the entire process under aseptic conditions.”

Comment 7): unclear what is meant by alcoholic solution. Do you mean ethanol or isopropyl alcohol? Mention %.

Response: We agree with your comment and have revised paragraph 2.4. (lines 143–144) as follows:

“2.4. Wear sterilized gloves to disinfect all surfaces of the operating setting with an 80 % ethanol solution. Discard the used gloves.”

Comment 8): 3.2: Please describe the surgical steps in detail. Mention all tools used, incision site, depth and size. What is the tube diameter and length?

Response: We agree with your comment and have revised paragraph 3.2. (line 155) as

follows:

“3.2. Intubate by a tracheal tube with a diameter of 7.5 mm and length of 25 cm.”

Comment 9): 3.3., 4.10.1: Mention sevoflurane dosage, and oxygen flow rate.

Response: We have revised this according to your comment.

Lines 157-158: “3.3. Place the dog on the right lateral position and maintain general anesthesia with 1.5 % sevoflurane in oxygen (4 L/min) and air (6 L/min). ”

Lines 201-203: “4.10.1 Perform computed tomography (CT) imaging of the facial bone under anesthesia, achieved with a mixture of 5 mg/kg ketamine hydrochloride and 1 mg/kg xylazine”

Comment 10): 3.6: Please specify the surgical site.

Response: We have revised line 164 as follows.

“3.6. Carefully shave the surgical field (left side chest area) using surgical clippers.”

Comment 11): 4.1, 5.4: Where exactly is lidocaine delivered? Mention needle gauge, and injection volume ie. dose?

Response: We have revised this according to your comment.

Lines 171-172: “4.1. Inject 3 mL of 1 % lidocaine using a 27-gauge needle to the left mandibular gingiva as a local anesthetic and analgesic.”

Lines 217-218 “5.4. Inject 5 mL of 1 % lidocaine using a 21-gauge needle to the left side chest area as a local anesthetic and analgesic.”

Comment 12): 4.3: What is the vibration frequency and amplitude (should be available in the manufacturer's datasheet).

Response: As the numerical value varies depending on various conditions, the amplitude was not described in the manufacturer's data sheet. We have revised line 180 as follows:

“Note: The vibration frequency was 28-32 kHz.”

Comment 13): 4.4: How?

Response: We have revised lines 182–183 as follows:

“4.4. Remove the frontal part of the mandibular bone plate (dimensions, 3 cm × 8 mm) to expose the left IAN (Figure 2A) ¹⁸. ”

Comment 14): 4.7: mention magnification of the scope

Response: We have revised lines 192–193 as follows:

“4.7. Use 8-0 nylon sutures and a surgical microscope at 8 x magnification to suture the tube to the proximal and distal nerve ends (Figure 2B) ¹⁸.”

Comment 15): 4.10.2: Mention any CT parameters for imaging.

Response: We have included this information in 4.10.1. (line 203) as follows:

“Set CT parameters as follows: 120 kVp, 200 mAs, 0.5 mm/s, 0.5-mm slice thickness.”

Comment 16): 5.2: Mention anesthesia method.

Response: We have revised lines 211–212 as follows:

“5.2. Anesthetize the animal with 1.5 % sevoflurane in oxygen (4 L/min) and air (6 L/min) and shave and clean the intended surgical field, as described in paragraph 3.”

Comment 17) The above list is not exhaustive, please apply the ideas to all your steps. You are the best judge of the missing details in your protocol, and its reproducibility.

Response: We wish to express our appreciation for your insightful comments. According to all your comments we have revised our manuscript.

• **Protocol Highlight:** After you have made all of the recommended changes to your protocol (listed above), please re-evaluate the length of your protocol section. This should be <2.75 pages long.

- 1) The highlighted steps should form a cohesive narrative, that is, there must be a logical flow from one highlighted step to the next.
- 2) Please highlight complete sentences (not parts of sentences). Include sub-headings and spaces when calculating the final highlighted length.
- 3) Please do not highlight anesthesia and euthanasia as these will not be filmed.

Response: Thank you for your comment. We have re-evaluated the length of our protocol section.

• **Result:** Please mention the statistical tests performed and report sample sizes.

Response: Thank you for your comment. We have described all statistical tests and sample sizes in the results (lines 378-382).

• **Discussion:** JoVE articles are focused on the methods and the protocol, thus the

discussion should be similarly focused. Please ensure that the discussion covers the following in detail and in paragraph form: 1) modifications and troubleshooting, 2) limitations of the technique, 3) significance with respect to existing methods, 4) future applications and 5) critical steps within the protocol.

Response: Thank you for your comment. Accordingly, we have revised the discussion to focus on the methods and protocol.

Comments from Peer-Reviewers:

Reviewer #1:

Comment: Minor Concerns:

Conclusions of the manuscript have to be more clearly described

Response: We thank you for this pertinent comment. We have revised the discussion for greater clarity, according to your comment.

Reviewer #2:

Comment: Manuscript Summary:

This manuscript is well-organized and well written. The current status is almost ready for publication except the experimental procedures, especially the surgical part should accompany additional pictures/color photos/figures that would be beneficial for readers to understand this procedure.

Response: Thank you for your comments. We are considering of supplementing the detailed procedure of the surgical operation with a video file, characteristic of JoVE.

Reviewer #3:

Comment: Manuscript Summary:

The current paper is another version of the already published paper entitled "Can nerve regeneration on an artificial nerve conduit be enhanced by ethanol-induced cervical sympathetic ganglion block?" by the same authors, which exists as citation number 18 in the current review. I cannot find what new information adds the current paper in the already published data (the same material was used, same figures, similar citations). The authors should explain the reason of this submission. No mention is made about the same figures. Did the authors took a copy-editing from PLOS ONE? I suggest the paper's rejection.

Response: Thank you for your comments. JoVE is a methods-based journal. The reason of this submission is to introduce our new surgical method for patients with peripheral nerve injuries to the world. We do hope this method will be widely performed clinically and contribute to the recovery of several patients. Therefore, we introduce a detailed protocol for the procedure of cervical sympathetic ganglion block, as well as for nerve reconstruction using an atrial nerve.

With regard to the technique of cervical sympathetic ganglion block and inferior alveolar nerve reconstruction, our maneuvers are always improving. Therefore, the current manuscript differs from our previous report as it includes further descriptions and methodological details. Moreover, our protocol is supplemented with a video file so that it is visually easier for the reader to understand and reproduce the procedure.

We would like to add that we have already obtained permission from the editorial department of PLOS ONE to use our figures and table already published in PLOS ONE. In addition, we have also informed and received confirmation from JoVE's scientific editor about this in advance.