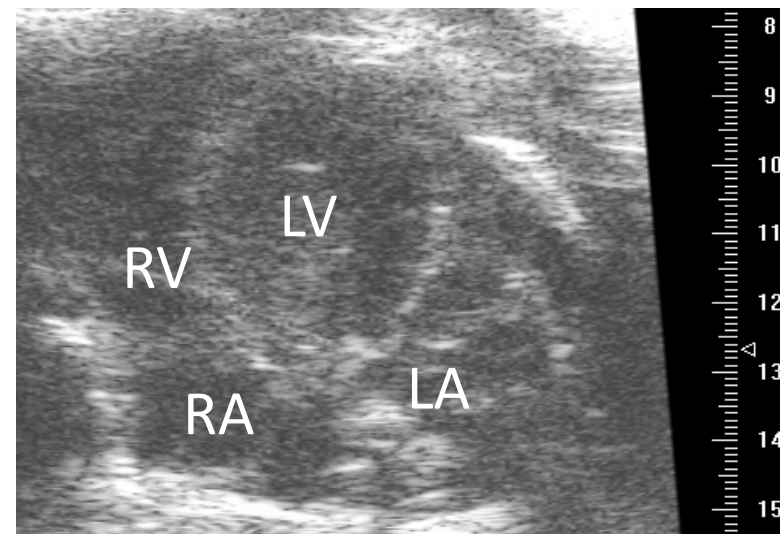
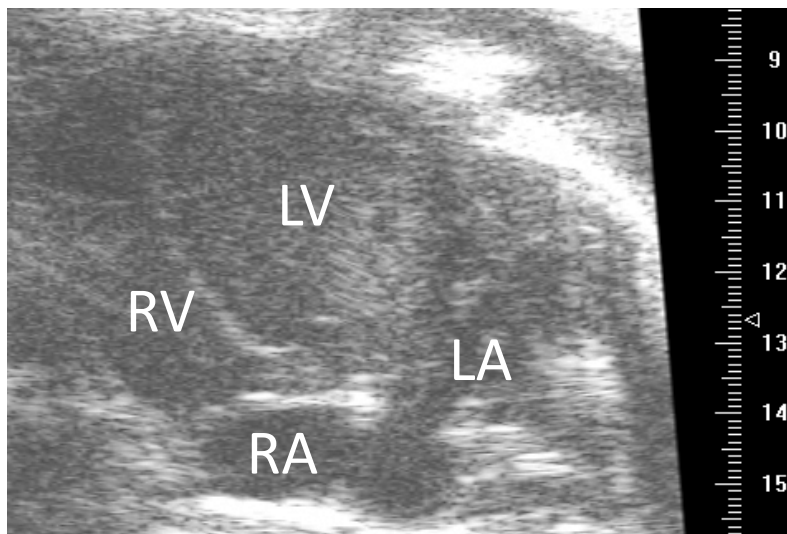


Left Caudal tilt

Right Cranial tilt

Sham



PAB

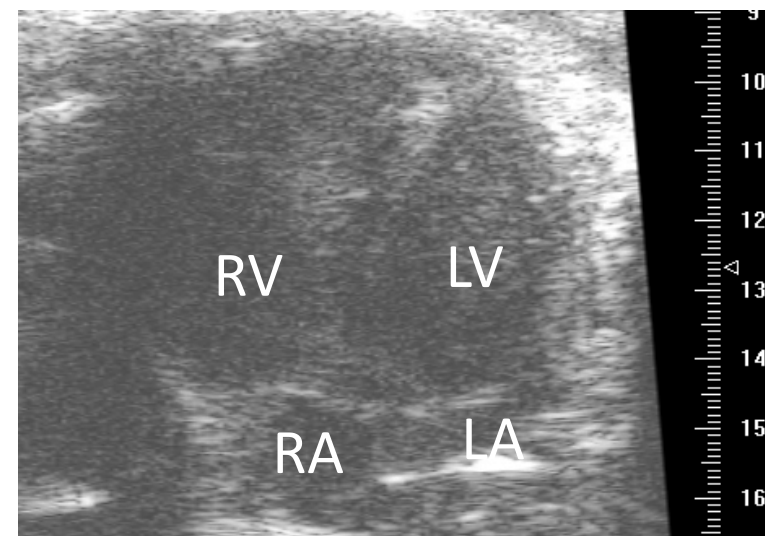
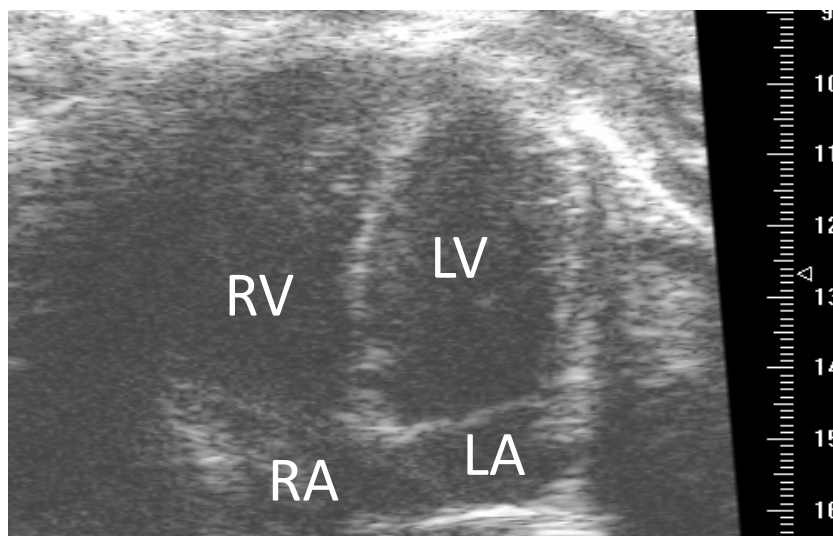


Fig. 1.