

Journal of Visualized Experiments

Cone Beam Intraoperative Computed Tomography-Based Image Guidance for Minimally Invasive Transforaminal Interbody Fusion --Manuscript Draft--

| | |
|--|--|
| Article Type: | Methods Article - JoVE Produced Video |
| Manuscript Number: | JoVE57830R2 |
| Full Title: | Cone Beam Intraoperative Computed Tomography-Based Image Guidance for Minimally Invasive Transforaminal Interbody Fusion |
| Keywords: | Image-guidance; minimally invasive; transforaminal lumbar interbody fusion; spinal surgery; intraoperative guidance; spinal fusion |
| Corresponding Author: | Michael Safaee University of California San Francisco San Francisco, CA UNITED STATES |
| Corresponding Author's Institution: | University of California San Francisco |
| Corresponding Author E-Mail: | michael.safaee@ucsf.edu |
| First Author: | Michael Safaee |
| Other Authors: | Taemin Oh |
| | Murat Pekmezci |
| | Aaron J. Clark |
| Author Comments: | |
| Additional Information: | |
| Question | Response |
| If this article needs to be "in-press" by a certain date, please indicate the date below and explain in your cover letter. | |

TITLE:

Cone Beam Intraoperative Computed Tomography-based Image Guidance for Minimally Invasive Transforaminal Interbody Fusion

AUTHORS & AFFILIATIONS:

Michael Safaee, M.D.¹, Taemin Oh, M.D.¹, Murat Pekmezci, M.D.², Aaron J. Clark, M.D., Ph.D.¹

¹Department of Neurological Surgery, UCSF, San Francisco, California, USA

²Department of Orthopedic Surgery, UCSF, San Francisco, California, USA

KEYWORDS:

Image-guidance, minimally invasive, transforaminal lumbar interbody fusion, spinal surgery, intraoperative guidance, spinal fusion

SHORT ABSTRACT:

The purpose of this article is to provide image-guidance for minimally invasive transforaminal interbody fusion.

LONG ABSTRACT:

Transforaminal lumbar interbody fusion (TLIF) is commonly used for the treatment of spinal stenosis, degenerative disc disease, and spondylolisthesis. Minimally invasive surgery (MIS) approaches have been applied to this technique with an associated decrease in estimated blood loss (EBL), length of hospital stay, and infection rates, while preserving outcomes with traditional open surgery. Previous MIS TLIF techniques involve significant fluoroscopy that subjects the patient, surgeon, and operating room staff to non-trivial levels of radiation exposure, particularly for complex multi-level procedures. We present a technique that utilizes an intraoperative computed tomography (CT) scan to aid in placement of pedicle screws, followed by traditional fluoroscopy for confirmation of cage placement. Patients are positioned in the standard fashion and a reference arc is placed in the posterior superior iliac spine (PSIS) followed by intraoperative CT scan. This allows for image-guidance-based placement of pedicle screws through a one-inch skin incision on each side. Unlike traditional MIS-TLIF that requires significant fluoroscopic imaging during this stage, the operation can now be performed without any additional radiation exposure to the patient or operating room staff. After completion of the facetectomy and discectomy, final TLIF cage placement is confirmed with fluoroscopy. This technique has the potential to decrease operative time and minimize total radiation exposure.

INTRODUCTION:

The TLIF is one of several options available when considering interbody fusion for degenerative disc disease and spondylolisthesis. The TLIF technique was initially developed in response to complications associated with the more traditional posterior lumbar interbody fusion (PLIF) approach. More specifically, the TLIF minimized retraction of neural elements, thereby reducing the risk of nerve root injury as well as the risk of dural tears, which can lead to persistent cerebrospinal fluid leak. As a unilateral approach, the TLIF technique also affords better preservation of the normal anatomy of the posterior elements¹. The TLIF can be performed either

open (O-TLIF) or minimally invasive (MIS-TLIF), and MIS-TLIF has proven to be a versatile and popular treatment for lumbar degenerative disease and spondylolisthesis²⁻⁴. Compared to the O-TLIF, the MIS-TLIF has been associated with decreased blood loss, shorter hospital stay, and less narcotic use; patient-reported and radiographic outcome measures are also similar between open and MIS approaches, thus suggesting the MIS-TLIF is an equally effective but potentially less morbid procedure⁵⁻¹¹.

However, a frequent limitation of the traditional MIS technique is the heavy reliance on fluoroscopy which exposes the patient, surgeon, and operating room staff to non-trivial radiation doses and fluoroscopy time ranging from 46–147 s¹². More recently, however, the use of intraoperative CT-guided navigation has been studied, with several different systems available and described in the literature including the O-arm/STEALTH, Airo Mobile, and Stryker Spinal Navigation Systems.^{13,14} This type of navigated technique has been shown to result in accurate pedicle screw placement while also minimizing the radiation risk to the surgeon¹⁵⁻¹⁹. In this article, we present a novel technique for MIS-TLIF that utilizes image-guidance-based pedicle screw placement followed by cage and rod placement with traditional fluoroscopy. This strategy has the potential to increase the speed and accuracy of the pedicle screw placement while minimizing the radiation exposure to both the patient and operating room staff.

PROTOCOL:

All procedures and research activities were performed with institutional review board approval (CHR #17-21909).

1. Pre-operative Preparation

1.1. Induce general anesthesia in the patient, and position the patient prone on the Jackson table with chest bolster and hip pads.

1.2. Prep and drape the patient's back in the usual sterile fashion.

2. Surgical Procedure

2.1. Make a small stab incision using a #15-blade over the PSIS contralateral to the side of the planned TLIF.

2.2. Place a biopsy needle through the stab incision into the ilium to harvest bone marrow aspirate (**Figure 1A**). Drive the navigation reference frame into the PSIS in a trajectory that places the reference arc inferior and medial, thereby avoiding interference with the standard trajectory of an S1 pedicle screw (**Figure 1B**).

2.3. Cover the wound with a sterile drape with the reference arc exposed and perform an intraoperative CT scan.

2.4. Plan pedicle screw trajectories using the navigation system (**Figure 1C**); they are generally

3.5 cm lateral to the midline through a one-inch incision on each side for single level fusion (1.5 inch for two levels, and 1.75 inch for three levels).

2.5. Use a navigated drill guide and 2–3 mm bit and high-speed drill to cannulate the pedicles and utilize K-wires to mark these trajectories.

2.6. Place the cannulated pedicle screws with reduction towers over the k-wires on the side opposite the TLIF.

2.7. Determine the trajectory along the disc space using the first tubular dilator which is oriented using the navigation system (**Figure 1D**). Place additional dilators followed by the TLIF retractor, which is connected to a self-retaining arm mounted to the bed.

2.8. Confirm the retractor positioning via navigation.

2.9. Perform the laminotomy, flavectomy, and facetectomy in standard fashion under the microscope.

2.9.1. Use a high-speed drill to perform the laminotomy and facetectomy; if just a laminotomy is desired, avoid drilling into the facet joint in order to preserve the structural integrity of the posterior column.

2.9.2. Ensure that the lateral border of the laminotomy is the medial aspect of the facet joint, while the medial border of the laminotomy should be the medial edge of the lamina. Utilize a Woodson elevator to dissect the ligamentum flavum off the dura. Once this is achieved, use a 2 or 3 mm Kerrison rongeur to remove the ligamentum flavum.

Note: Navigation allows for maximal safe decompression without violation of the pedicle (**Figure 1D, E**).

2.10. If contralateral decompression is needed, angle the retractor across the midline and remove the underside of the contralateral lamina, ligamentum flavum, and hypertrophic facet capsule using a 2 or 3 mm Kerrison rongeur.

2.11. Use the navigation again to identify the trajectory along the disc space to facilitate a safe and thorough discectomy.

2.12. Prepare the disc space with shavers and distractors.

2.13. Upon completing the discectomy, use intermittent fluoroscopy to visualize the degree of distraction required during the interbody cage trial placement to ensure preservation of the endplates (**Figure 2A**).

2.14. Mix the allograft cellular bone matrix with the autologous bone marrow aspirate harvested

at the beginning of the operation and carefully pack it into the disc space.

2.15. Insert the interbody cage (polyetheretherketone [PEEK]), and confirm its position via lateral and antero-posterior (AP) fluoroscopy (**Figure 2B**).

2.16. Once TLIF has been completed, place the remaining pedicle screws.

2.17. Carefully drive a pre-bent rod through the screw heads below the dorsal lumbar fascia. Use periodic fluoroscopy to confirm adequate rod length.

2.18. Gently compress the rods to induce lordosis before securing them with locking set screws.

2.19. Obtain a final fluoroscopy prior to closure.

2.20. Close the thoracodorsal fascia with an 0 polyglactin 910 suture, close the subcutaneous tissue with 3-0 polyglactin 910, and approximate the skin edges with skin closure strips. Apply a water tight dressing.

3. Post-surgical Care

3.1. Ambulate patients on postoperative day 1 with a soft lumbar brace, and obtain standing 36-inch X-rays prior to discharge (**Figure 2C**).

3.2. Prescribe antibiotics (cefazolin at 2 g intravenous at every 8 h) for 24 h.

3.3. Provide patients a patient-controlled analgesia (PCA) pump with morphine or hydromorphone overnight and ambulate on postoperative day 1.

3.4. Transition patients to oral pain medications on the first day and discharge on postoperative day 2 – 3 with follow-up in 6 weeks.

REPRESENTATIVE RESULTS:

Fifty patients underwent surgery with this technique under a single surgeon (AC). The average age was 53 years (range 29–84 years) with 30 women and 20 men. Patients presented with the following pathology: spinal stenosis (n=45), spondylolisthesis (n=29), facet cysts (n=5), degenerative scoliosis (n=3), and cauda equina syndrome (n=1). Symptoms were back and leg pain in 42 cases, back pain alone in 2 cases, and lower extremity radiculopathy in 6 cases. In 10 cases, patients had undergone previous surgery at the level of pathology. Results are summarized in **Table 1**.

A left-sided approach was used in 25 cases and right-sided in 25 cases. There were 33 single level fusions, 15 two level fusions, and 2 three level fusions. Fusion levels were as follows: L4-5 (n=35), L5-S1 (n=27), L3-4 (n=7), and L2-3 (n=2). The average cage height was 10.2 mm. The mean operative time was 240 min and the average EBL was 80 mL. There was a significant difference

in operative time when comparing the number of levels fused; 200 min for single level, 306 min for two levels, and 393 min for three levels ($p<0.001$). The average radiation dose was 62.0 mGy, with 35.3 mGy from the intraoperative CT scan and 26.2 mGy from fluoroscopy. The average duration of fluoroscopy was 42.2 s, with 5.2 s from intraoperative CT scan and 37.1 s from traditional fluoroscopy. The average length of stay after surgery was 3 days (range 1–7 days). The results are summarized in **Table 2**.

FIGURE AND TABLE LEGENDS:

Figure 1. CT-based navigation for MIS-TLIF. A bone marrow biopsy needle is placed through a stab incision into the ilium to harvest bone marrow aspirate (**A**). The navigation reference frame is placed in the posterior superior iliac spine in a trajectory that places the arc inferior and medial to avoid interference with the standard trajectory of S1 pedicle screws (**B**). Pedicle screw trajectories are visualized using the navigation system (**C**). The trajectory along the disc space is determined using the first tubular dilator by navigation (**D**). The use of intraoperative navigation allows for maximal safe decompression by identifying the location of the superior (**E**) and inferior (**F**) pedicles.

Figure 2. Intraoperative fluoroscopy for interbody cage placement. Fluoroscopy is used during the endplate preparation and distraction to ensure the appropriate height restoration and to avoid violation of the endplates (**A**). Imaging is used to confirm the appropriate final position (**B**). Standing 36-inch X-rays (lumbar region shown) are obtained on all patients prior to discharge (**C**).

Table 1. Patient demographics.

Table 2. Surgical characteristics.

DISCUSSION:

There are several critical steps to the procedure described. The first critical step is the process of registration. The reference arc must be placed in solid bone and should be oriented appropriately to avoid interfering with the S1 pedicle screw placement if needed. The second critical step is maintaining accuracy of the navigation after an intraoperative CT scan is performed, which can be done by identifying normal anatomic structures and confirming the correct positioning. The accuracy should be periodically verified. Perhaps one of the limitations of the described technique is that the navigation can be inadvertently altered in the middle of an operation. Registration is derived from a fixed patient position on the operating table. As a result, any translational movement of the patient or the reference frame itself can dramatically influence the accuracy of navigation. Great caution must particularly be taken when applying any downward forces (such as during the placement of pedicle screws)²⁰. Nevertheless, if there are any concerns regarding accuracy, the surgeon must not hesitate to repeat the registration to ensure high fidelity of the navigation.

Another critical step is the preparation of the disc endplates for interbody cage placement, as the endplates must not be violated, which can result in cage subsidence. The rates of PEEK cage

subsidence in MIS-TLIF can be as high as 15%²¹, thus optimizing the cage fit can dramatically reduce the risk of migration, subsidence, and collapse; the endplate preservation is critical to achieving this goal^{22,23}. Intermittent fluoroscopy can be helpful at this point to visualize the amount of distraction and end plate preservation. Final fluoroscopy can also be performed to confirm satisfactory cage positioning and placement²⁴. In that manner, fluoroscopy remains a critical tool for this technique, particularly during discectomy, distraction, and cage placement. While image-guidance navigation allows for pedicle screw placement, intermittent fluoroscopy provides a “real-time” view to evaluate endplate preservation during discectomy and confirm the appropriate cage trajectory and final placement.

Apart from navigation registration errors, another limitation to the proposed technique is that contemporary navigation protocols do not exist for guidewire navigation. This leads to a theoretical risk of threading the guidewire deep past the vertebral body and causing intraabdominal injury. In order to minimize this risk, we recommend pulling the guidewire back by several inches after cannulating the proximal pedicle²⁰.

There is a general consensus that MIS techniques are associated with increased radiation exposure when compared to traditional open techniques due to their reliance on fluoroscopy²⁵. Developing strategies to reduce radiation exposure and shorten operative time are critical to improving outcomes while minimizing the dangers of radiation overexposure²⁵. Incorporating the intraoperative CT scan for navigation allows for the placement of pedicle screws without the need for constant fluoroscopy. Villard *et al.* found that radiation exposure using freehand techniques was almost 10 times higher than with navigation-guided techniques in a cohort of patients who underwent standard open posterior lumbar instrumentation²⁶. Tabaree *et al.* demonstrated that the use of the O-arm resulted in similar breach rates as the C-arm, and radiation exposure was lowered for the surgeon but increased for the patient²⁷. In another cadaveric study for iliosacral screw placement, Theologis *et al.* confirmed that the use of the O-arm increases radiation exposure to the patient²⁸.

There are limited data on radiation exposure associated with the technique described in this manuscript; previous studies present radiation exposure as the total fluoroscopy time in seconds, while much of these data are generated from studies comparing traditional open TLIF to MIS-TLIF. Using image-guidance for pedicle screw placement, we found a reduction in the total fluoroscopic time compared to historical studies (42 s compared to 45–105 s). Furthermore, the average radiation dose in our study was 62.0 mGy with intraoperative CT scan accounting for 57% (35.4 mGy) of the radiation exposure; this compares favorably to a study performed by Mendelsohn *et al.*, where intraoperative CT for navigation during spinal instrumentation increased the total radiation dose to the patient by 8.74 times²⁹. However, the reduction in radiation was associated with an increase in operative time given that image acquisition can result in delays related to equipment transport and in some cases the need for multiple rounds of image acquisition. The results of this technique compare favorably to historical studies with respect to EBL and length of stay.

An advantage to our approach is that in certain cases, it eliminates the need for preoperative CT

scan since these images can be acquired in the operating room. There are limited data on patient BMI and associated radiation exposure. Larger body habitus often requires increased radiation dosage to penetrate the soft tissue and may require additional exposures as the dosage is optimized intraoperatively. Bivariate correlation statistics found a Pearson correlation of 0.358 between BMI and fluoroscopy dose ($p=0.013$), but a value of 0.003 between BMI and fluoroscopy time ($p=0.983$), confirming that increased radiation dose, not increased time, was correlated with BMI.

This study is limited by its retrospective design. Additionally, there is frequently a high demand for intraoperative CT scan and these machines are not always available, resulting in a “wait time” for this part of the operation. Coordinating intraoperative CT scan availability with the OR start time has the potential to shorten total operative time by decreasing the “wait time.” Radiation exposure associated with intraoperative CT scan is relatively fixed, however, fluoroscopy represents an area for further radiation exposure reduction. Use of low dose protocols can be utilized, but their viability in obese patients and multilevel MIS-TLIFs is not yet validated. We are encouraged that even in these preliminary data, the average fluoroscopy time of 41.6 s compares very favorably to historical reports; when considering that our study included two and three level fusions, these data are even more promising. Future studies will incorporate streamlined communication with operating room staff and radiation technologists as well as low-dose fluoroscopy protocols.

In conclusion, in this article, we describe a single-surgeon experience using a novel technique incorporating a mixture of intraoperative CT-guided navigation and traditional fluoroscopy when performing an MIS TLIF. Such a technique represents an intermediary in the transition towards exclusively using navigation in the future³⁰⁻³². One of the potential benefits of this technique is the reduction of radiation exposure to the patient as well as the surgeon. Preliminary results show promise, and future studies may prove further benefits with this technique.

ACKNOWLEDGMENTS:

We would like to acknowledge UCSF Medical Center and the Department of Neurosurgery for allowing us to pursue this endeavor.

DISCLOSURES:

Dr. Aaron Clark is a consultant for Nuvasive. Dr. Pekmezci, Safaee, and Oh have nothing to disclose.

REFERENCES:

- 1 Mobbs, R. J., Phan, K., Malham, G., Seex, K. & Rao, P. J. Lumbar interbody fusion: techniques, indications and comparison of interbody fusion options including PLIF, TLIF, MI-TLIF, OLIF/ATP, LLIF and ALIF. *J Spine Surg.* **1** (1), 2-18, doi:10.3978/j.issn.2414-469X.2015.10.05, (2015).
- 2 Foley, K. T., Holly, L. T. & Schwender, J. D. Minimally invasive lumbar fusion. *Spine (Phila Pa 1976)*. **28** (15 Suppl), S26-35, doi:10.1097/01.BRS.0000076895.52418.5E, (2003).
- 3 Foley, K. T. & Lefkowitz, M. A. Advances in minimally invasive spine surgery. *Clin*

309 *Neurosurg.* **49** 499-517 (2002).

310 4 Schwender, J. D., Holly, L. T., Rouben, D. P. & Foley, K. T. Minimally invasive transforaminal
311 lumbar interbody fusion (TLIF): technical feasibility and initial results. *J Spinal Disord Tech.*
312 **18 Suppl** S1-6 (2005).

313 5 Lee, K. H., Yue, W. M., Yeo, W., Soeharno, H. & Tan, S. B. Clinical and radiological outcomes
314 of open versus minimally invasive transforaminal lumbar interbody fusion. *Eur Spine J.* **21**
315 (11), 2265-2270, doi:10.1007/s00586-012-2281-4, (2012).

316 6 Peng, C. W., Yue, W. M., Poh, S. Y., Yeo, W. & Tan, S. B. Clinical and radiological outcomes
317 of minimally invasive versus open transforaminal lumbar interbody fusion. *Spine (Phila Pa*
318 *1976).* **34** (13), 1385-1389, doi:10.1097/BRS.0b013e3181a4e3be, (2009).

319 7 Schizas, C., Tzinieris, N., Tsiridis, E. & Kosmopoulos, V. Minimally invasive versus open
320 transforaminal lumbar interbody fusion: evaluating initial experience. *Int Orthop.* **33** (6),
321 1683-1688, doi:10.1007/s00264-008-0687-8, (2009).

322 8 Seng, C. *et al.* Five-year outcomes of minimally invasive versus open transforaminal
323 lumbar interbody fusion: a matched-pair comparison study. *Spine (Phila Pa 1976).* **38** (23),
324 2049-2055, doi:10.1097/BRS.0b013e3182a8212d, (2013).

325 9 Shunwu, F., Xing, Z., Fengdong, Z. & Xiangqian, F. Minimally invasive transforaminal
326 lumbar interbody fusion for the treatment of degenerative lumbar diseases. *Spine (Phila*
327 *Pa 1976).* **35** (17), 1615-1620, doi:10.1097/BRS.0b013e3181c70fe3, (2010).

328 10 Singh, K. *et al.* A perioperative cost analysis comparing single-level minimally invasive and
329 open transforaminal lumbar interbody fusion. *Spine J.* **14** (8), 1694-1701,
330 doi:10.1016/j.spinee.2013.10.053, (2014).

331 11 Wong, A. P. *et al.* Minimally invasive transforaminal lumbar interbody fusion (MI-TLIF):
332 surgical technique, long-term 4-year prospective outcomes, and complications compared
333 with an open TLIF cohort. *Neurosurg Clin N Am.* **25** (2), 279-304,
334 doi:10.1016/j.nec.2013.12.007, (2014).

335 12 Clark, J. C., Jasmer, G., Marciano, F. F. & Tumialan, L. M. Minimally invasive transforaminal
336 lumbar interbody fusions and fluoroscopy: a low-dose protocol to minimize ionizing
337 radiation. *Neurosurg Focus.* **35** (2), E8, doi:10.3171/2013.5.FOCUS13144, (2013).

338 13 Ringel, F., Villard, J., Ryang, Y. M. & Meyer, B. Navigation, robotics, and intraoperative
339 imaging in spinal surgery. *Adv Tech Stand Neurosurg.* **41** 3-22, doi:10.1007/978-3-319-
340 01830-0_1, (2014).

341 14 Overley, S. C., Cho, S. K., Mehta, A. I. & Arnold, P. M. Navigation and Robotics in Spinal
342 Surgery: Where Are We Now? *Neurosurgery.* **80** (3S), S86-S99,
343 doi:10.1093/neuros/nyw077, (2017).

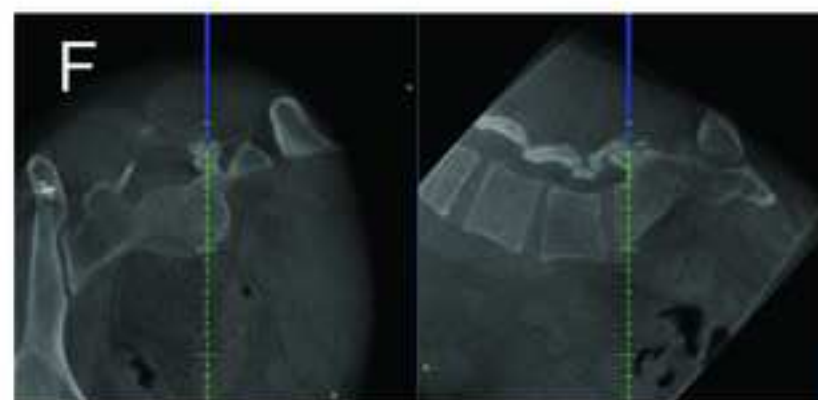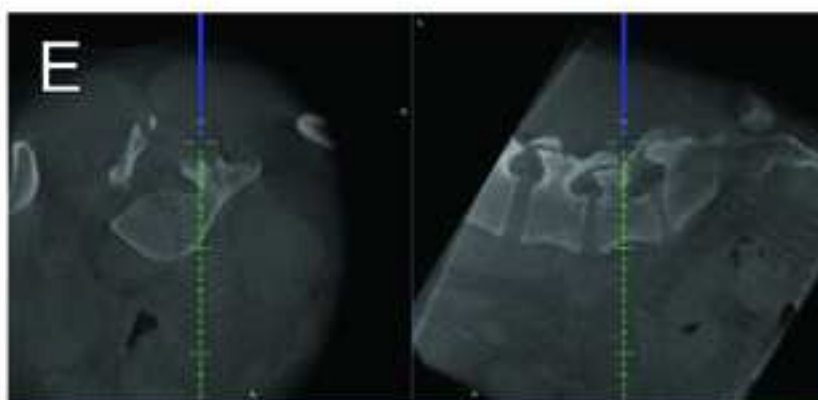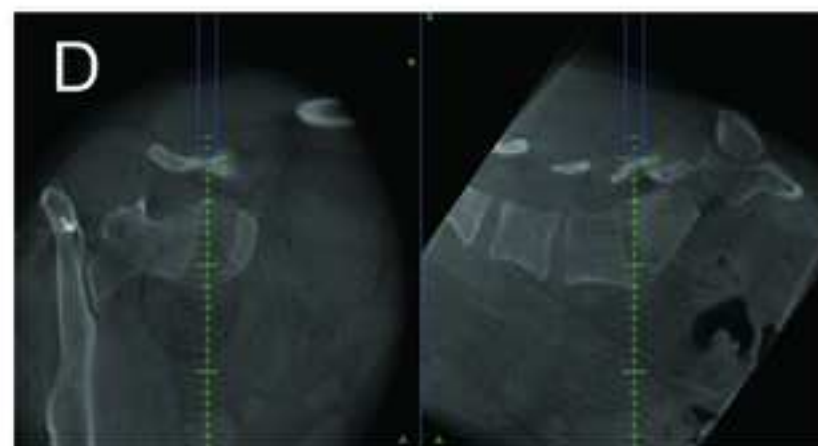
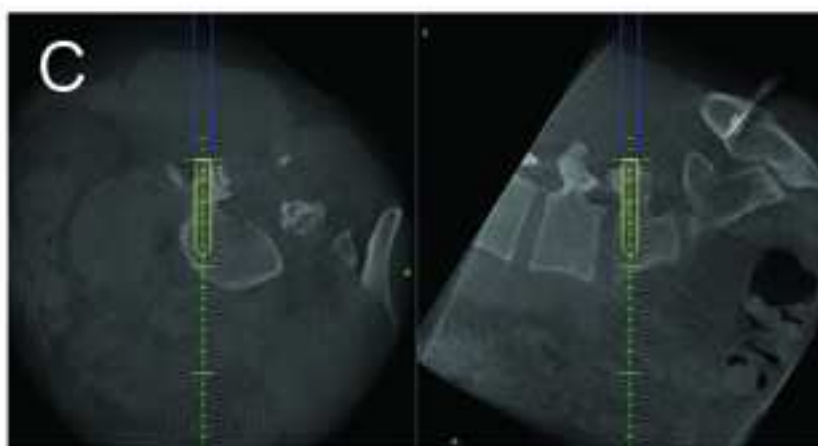
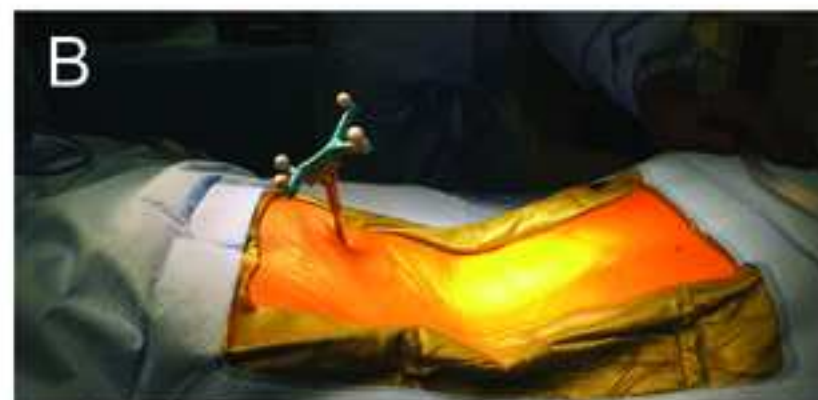344 15 Abdullah, K. G. *et al.* Radiation exposure to the spine surgeon in lumbar and
345 thoracolumbar fusions with the use of an intraoperative computed tomographic 3-
346 dimensional imaging system. *Spine (Phila Pa 1976).* **37** (17), E1074-1078,
347 doi:10.1097/BRS.0b013e31825786d8, (2012).

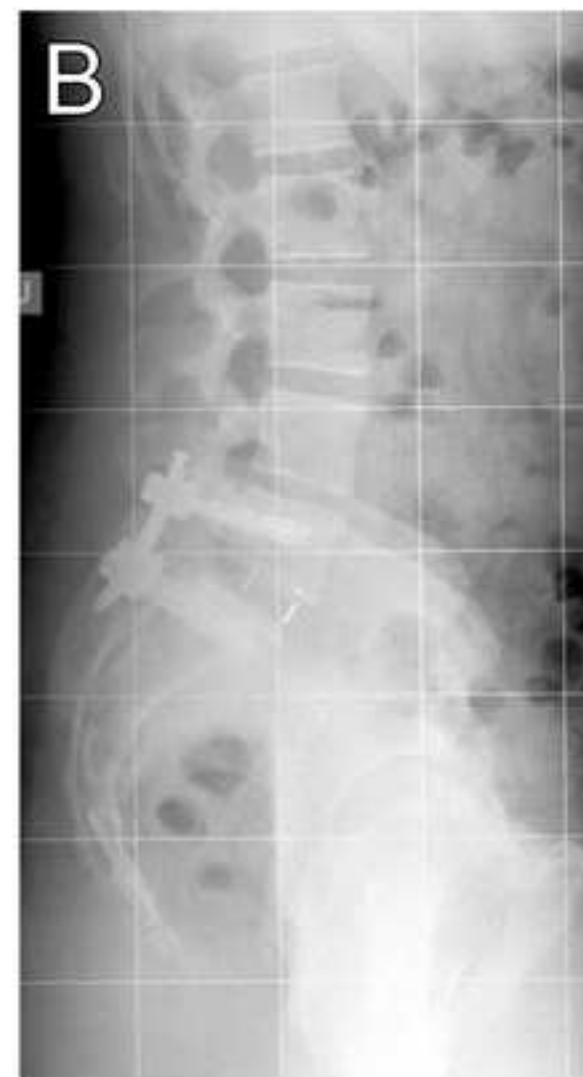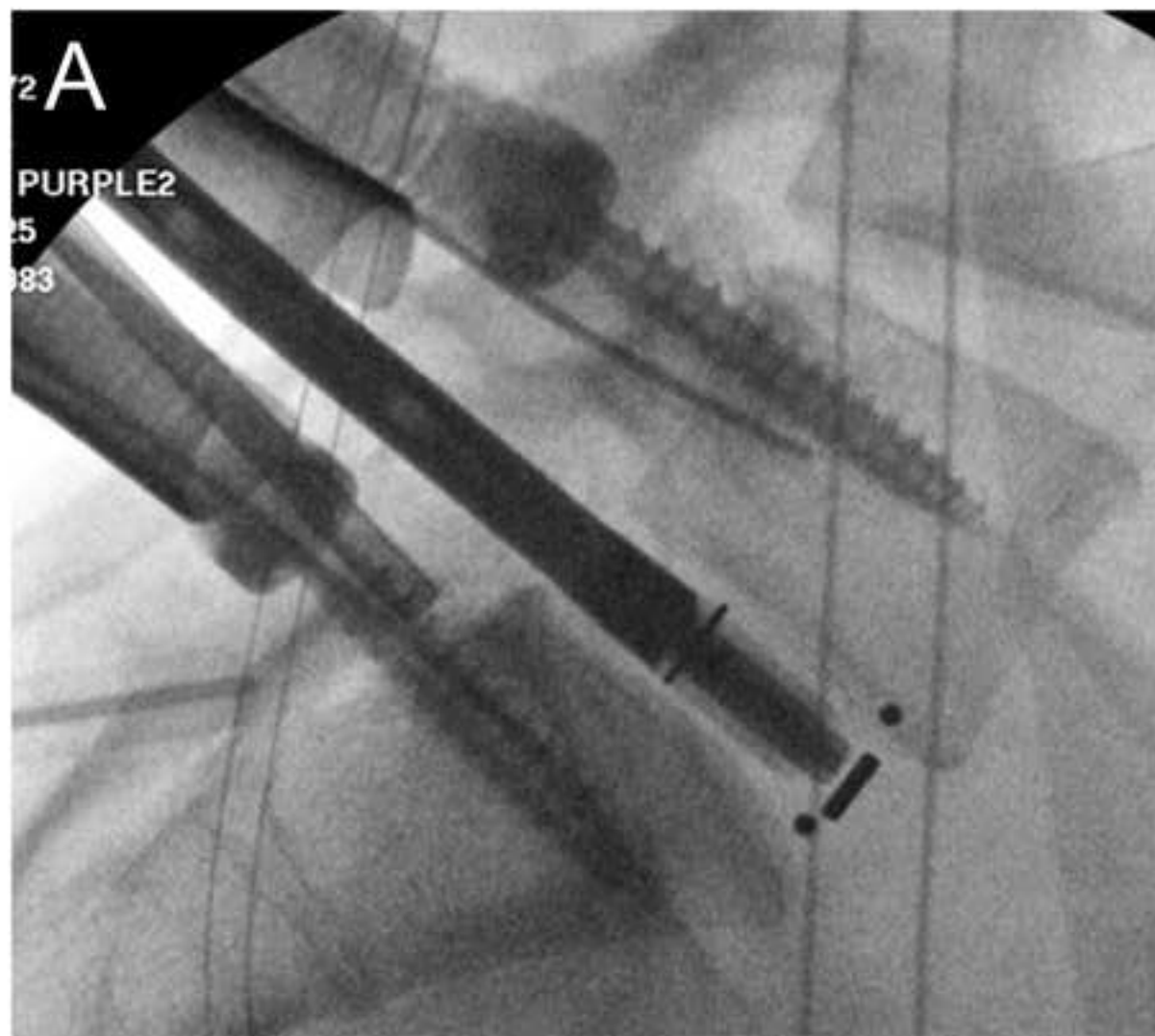
348 16 Gelalis, I. D. *et al.* Accuracy of pedicle screw placement: a systematic review of prospective
349 *in vivo* studies comparing free hand, fluoroscopy guidance and navigation techniques. *Eur*
350 *Spine J.* **21** (2), 247-255, doi:10.1007/s00586-011-2011-3, (2012).

351 17 Nottmeier, E. W., Bowman, C. & Nelson, K. L. Surgeon radiation exposure in cone beam
352 computed tomography-based, image-guided spinal surgery. *Int J Med Robot.* **8** (2), 196-

- 200, doi:10.1002/rcs.450, (2012).
- 18 Park, P., Foley, K. T., Cowan, J. A. & Marca, F. L. Minimally invasive pedicle screw fixation utilizing O-arm fluoroscopy with computer-assisted navigation: Feasibility, technique, and preliminary results. *Surg Neurol Int.* **1** 44, doi:10.4103/2152-7806.68705, (2010).
- 19 Van de Kelft, E., Costa, F., Van der Planken, D. & Schils, F. A prospective multicenter registry on the accuracy of pedicle screw placement in the thoracic, lumbar, and sacral levels with the use of the O-arm imaging system and StealthStation Navigation. *Spine (Phila Pa 1976)*. **37** (25), E1580-1587, doi:10.1097/BRS.0b013e318271b1fa, (2012).
- 20 Kim, T. T., Johnson, J. P., Pashman, R. & Drazin, D. Minimally Invasive Spinal Surgery with Intraoperative Image-Guided Navigation. *Biomed Res Int.* **2016** 5716235, doi:10.1155/2016/5716235, (2016).
- 21 Kim, M. C., Chung, H. T., Cho, J. L., Kim, D. J. & Chung, N. S. Subsidence of polyetheretherketone cage after minimally invasive transforaminal lumbar interbody fusion. *J Spinal Disord Tech.* **26** (2), 87-92, doi:10.1097/BSD.0b013e318237b9b1, (2013).
- 22 Kim, C. W. *et al.* Minimally Invasive Transforaminal Lumbar Interbody Fusion Using Expandable Technology: A Clinical and Radiographic Analysis of 50 Patients. *World Neurosurg.* **90** 228-235, doi:10.1016/j.wneu.2016.02.075, (2016).
- 23 Malham, G. M., Parker, R. M., Blecher, C. M. & Seex, K. A. Assessment and classification of subsidence after lateral interbody fusion using serial computed tomography. *J Neurosurg Spine.* 1-9, doi:10.3171/2015.1.SPINE14566, (2015).
- 24 Safaee, M. M., Oh, T., Pekmezci, M. & Clark, A. J. Radiation exposure with hybrid image-guidance-based minimally invasive transforaminal lumbar interbody fusion. *J Clin Neurosci.* doi:10.1016/j.jocn.2017.09.026, (2017).
- 25 Yu, E. & Khan, S. N. Does less invasive spine surgery result in increased radiation exposure? A systematic review. *Clin Orthop Relat Res.* **472** (6), 1738-1748, doi:10.1007/s11999-014-3503-3, (2014).
- 26 Villard, J. *et al.* Radiation exposure to the surgeon and the patient during posterior lumbar spinal instrumentation: a prospective randomized comparison of navigated versus non-navigated freehand techniques. *Spine (Phila Pa 1976)*. **39** (13), 1004-1009, doi:10.1097/BRS.0000000000000351, (2014).
- 27 Tabaraee, E. *et al.* Intraoperative cone beam-computed tomography with navigation (O-ARM) versus conventional fluoroscopy (C-ARM): a cadaveric study comparing accuracy, efficiency, and safety for spinal instrumentation. *Spine (Phila Pa 1976)*. **38** (22), 1953-1958, doi:10.1097/BRS.0b013e3182a51d1e, (2013).
- 28 Theologis, A. A., Burch, S. & Pekmezci, M. Placement of iliosacral screws using 3D image-guided (O-Arm) technology and Stealth Navigation: comparison with traditional fluoroscopy. *Bone Joint J.* **98-B** (5), 696-702, doi:10.1302/0301-620X.98B5.36287, (2016).
- 29 Mendelsohn, D. *et al.* Patient and surgeon radiation exposure during spinal instrumentation using intraoperative computed tomography-based navigation. *Spine J.* **16** (3), 343-354, doi:10.1016/j.spinee.2015.11.020, (2016).
- 30 Shin, B. J., Njoku, I. U., Tsiouris, A. J. & Hartl, R. Navigated guide tube for the placement of mini-open pedicle screws using stereotactic 3D navigation without the use of K-wires: technical note. *J Neurosurg Spine.* **18** (2), 178-183, doi:10.3171/2012.10.SPINE12569, (2013).

397 31 Lian, X. *et al.* Total 3D Airo(R) Navigation for Minimally Invasive Transforaminal Lumbar
398 Interbody Fusion. *Biomed Res Int.* **2016** 5027340, doi:10.1155/2016/5027340, (2016).
399 32 Navarro-Ramirez, R. *et al.* Total Navigation in Spine Surgery; A Concise Guide to Eliminate
400 Fluoroscopy Using a Portable Intraoperative Computed Tomography 3-Dimensional
401 Navigation System. *World Neurosurg.* **100** 325-335, doi:10.1016/j.wneu.2017.01.025,
402 (2017).
403





| Variable | N=50 |
|-------------------|-------------|
| Age | |
| Mean (range) | 53 (29-84) |
| Gender | |
| Male | 20 (40%) |
| Female | 30 (60%) |
| BMI | |
| Mean (range) | 30 (21-41) |
| Pathology | |
| Stenosis | 45 (90%) |
| Spondylolisthesis | 29 (58%) |
| Facet cyst | 5 (10%) |
| Scoliosis | 3 (6%) |
| Cauda equina | 1 (2%) |
| Symptom location | |
| Back | 2 (4%) |
| Leg | 6 (12%) |
| Both | 42 (84%) |
| Previous surgery | 10 (20%) |

| Variable | N=50 |
|---------------------------|-------------------|
| Approach | |
| Left | 25 (50%) |
| Right | 25 (50%) |
| Number of levels fused | |
| One | 33 (66%) |
| Two | 15 (30%) |
| Three | 2 (4%) |
| Levels fused | |
| L2/3 | 2 |
| L3/4 | 7 |
| L4/5 | 35 |
| L5/S1* | 27 |
| Cage height (mm) | 10.2 (7-14) |
| Estimated blood loss (ml) | 80 (10-550) |
| Operative time (min) | 240 (88-412) |
| Radiation dose (mGy) | |
| Intraoperative CT | 35.3 (21.5-68.7) |
| Fluoroscopy | 26.5 (4.3-64.3) |
| Total | 62.0 (28.9-120.7) |
| Radiation exposure (sec) | |
| Intraoperative CT | 5.2 (1.0-24.5) |
| Fluoroscopy | 37.1 (8.7-94.6) |
| Total | 42.2 (12.2-100.0) |
| Length of stay (days) | 3.1 (1-7) |

* One patient with L5/L6 interbody fusion

| Name of Material/ Equipment | Company | Catalog Number | Comments/Description |
|-----------------------------------|----------------------------|----------------|------------------------|
| O-arm intraoperative CT | Medtronic, Minneapolis, MN | | |
| Stealth Navigation System | Medtronic, Minneapolis, MN | | |
| Jamshidi Needles | | | for bone marrow biopsy |
| Cefazolin | | | antibiotic. |
| Vicryl Sutures | | | |
| Steri-Strips | | | for skin closure |
| telfa dressing | | | |
| tegaderm | | | for dressing |
| Jackson table | | | |
| 15-blade | | | |
| High-speed bone drill | | | |
| Tubular dilator | | | |
| K-wires | | | |
| Reduction towers | | | |
| TLIF retractor | | | |
| 2 or 3 mm Kerrison rongeur | | | |
| Woodson elevator | | | |
| Disc shaver and distractor | | | |
| Fluoroscopy | | | |
| Allograft cellular bone matrix | | | |
| Interbody cage | | | |
| Rod | | | |
| Soft lumbar brace | | | |
| X-ray | | | |
| Patient-controlled analgesia pump | | | |



1 Alewife Center #200
Cambridge, MA 02140
tel. 617.945.9051
www.jove.com

ARTICLE AND VIDEO LICENSE AGREEMENT

Title of Article:

Author(s):

Item 1 (check one box): The Author elects to have the Materials be made available (as described at <http://www.jove.com/author>) via: ☒ Standard Access ☐ Open Access

Item 2 (check one box):

- ☒ The Author is NOT a United States government employee.
- ☐ The Author is a United States government employee and the Materials were prepared in the course of his or her duties as a United States government employee.
- ☐ The Author is a United States government employee but the Materials were NOT prepared in the course of his or her duties as a United States government employee.

ARTICLE AND VIDEO LICENSE AGREEMENT

1. Defined Terms. As used in this Article and Video License Agreement, the following terms shall have the following meanings: “**Agreement**” means this Article and Video License Agreement; “**Article**” means the article specified on the last page of this Agreement, including any associated materials such as texts, figures, tables, artwork, abstracts, or summaries contained therein; “**Author**” means the author who is a signatory to this Agreement; “**Collective Work**” means a work, such as a periodical issue, anthology or encyclopedia, in which the Materials in their entirety in unmodified form, along with a number of other contributions, constituting separate and independent works in themselves, are assembled into a collective whole; “**CRC License**” means the Creative Commons Attribution-Non Commercial-No Derivs 3.0 Unported Agreement, the terms and conditions of which can be found at: <http://creativecommons.org/licenses/by-nc-nd/3.0/legalcode>; “**Derivative Work**” means a work based upon the Materials or upon the Materials and other pre-existing works, such as a translation, musical arrangement, dramatization, fictionalization, motion picture version, sound recording, art reproduction, abridgment, condensation, or any other form in which the Materials may be recast, transformed, or adapted; “**Institution**” means the institution, listed on the last page of this Agreement, by which the Author was employed at the time of the creation of the Materials; “**JoVE**” means MyJoVE Corporation, a Massachusetts corporation and the publisher of *The Journal of Visualized Experiments*; “**Materials**” means the Article and / or the Video; “**Parties**” means the Author and JoVE; “**Video**” means any video(s) made by the Author, alone or in conjunction with any other parties, or by JoVE or its affiliates or agents, individually or in collaboration with the Author or any other parties, incorporating all or any portion of the Article, and in which the Author may or may not appear.

2. Background. The Author, who is the author of the Article, in order to ensure the dissemination and protection of the Article, desires to have the JoVE publish the Article and create and transmit videos based on the Article. In furtherance of such goals, the Parties desire to memorialize in this Agreement the respective rights of each Party in and to the Article and the Video.

3. Grant of Rights in Article. In consideration of JoVE agreeing to publish the Article, the Author hereby grants to JoVE, subject to **Sections 4** and **7** below, the exclusive, royalty-free, perpetual (for the full term of copyright in the Article, including any extensions thereto) license (a) to publish, reproduce, distribute, display and store the Article in all forms, formats and media whether now known or hereafter developed (including without limitation in print, digital and electronic form) throughout the world, (b) to translate the Article into other languages, create adaptations, summaries or extracts of the Article or other Derivative Works (including, without limitation, the Video) or Collective Works based on all or any portion of the Article and exercise all of the rights set forth in (a) above in such translations, adaptations, summaries, extracts, Derivative Works or Collective Works and (c) to license others to do any or all of the above. The foregoing rights may be exercised in all media and formats, whether now known or hereafter devised, and include the right to make such modifications as are technically necessary to exercise the rights in other media and formats. If the “Open Access” box has been checked in **Item 1** above, JoVE and the Author hereby grant to the public all such rights in the Article as provided in, but subject to all limitations and requirements set forth in, the CRC License.

ARTICLE AND VIDEO LICENSE AGREEMENT

4. Retention of Rights in Article. Notwithstanding the exclusive license granted to JoVE in **Section 3** above, the Author shall, with respect to the Article, retain the non-exclusive right to use all or part of the Article for the non-commercial purpose of giving lectures, presentations or teaching classes, and to post a copy of the Article on the Institution's website or the Author's personal website, in each case provided that a link to the Article on the JoVE website is provided and notice of JoVE's copyright in the Article is included. All non-copyright intellectual property rights in and to the Article, such as patent rights, shall remain with the Author.

5. Grant of Rights in Video – Standard Access. This **Section 5** applies if the "Standard Access" box has been checked in **Item 1** above or if no box has been checked in **Item 1** above. In consideration of JoVE agreeing to produce, display or otherwise assist with the Video, the Author hereby acknowledges and agrees that, Subject to **Section 7** below, JoVE is and shall be the sole and exclusive owner of all rights of any nature, including, without limitation, all copyrights, in and to the Video. To the extent that, by law, the Author is deemed, now or at any time in the future, to have any rights of any nature in or to the Video, the Author hereby disclaims all such rights and transfers all such rights to JoVE.

6. Grant of Rights in Video – Open Access. This **Section 6** applies only if the "Open Access" box has been checked in **Item 1** above. In consideration of JoVE agreeing to produce, display or otherwise assist with the Video, the Author hereby grants to JoVE, subject to **Section 7** below, the exclusive, royalty-free, perpetual (for the full term of copyright in the Article, including any extensions thereto) license (a) to publish, reproduce, distribute, display and store the Video in all forms, formats and media whether now known or hereafter developed (including without limitation in print, digital and electronic form) throughout the world, (b) to translate the Video into other languages, create adaptations, summaries or extracts of the Video or other Derivative Works or Collective Works based on all or any portion of the Video and exercise all of the rights set forth in (a) above in such translations, adaptations, summaries, extracts, Derivative Works or Collective Works and (c) to license others to do any or all of the above. The foregoing rights may be exercised in all media and formats, whether now known or hereafter devised, and include the right to make such modifications as are technically necessary to exercise the rights in other media and formats. For any Video to which this Section 6 is applicable, JoVE and the Author hereby grant to the public all such rights in the Video as provided in, but subject to all limitations and requirements set forth in, the CRC License.

7. Government Employees. If the Author is a United States government employee and the Article was prepared in the course of his or her duties as a United States government employee, as indicated in **Item 2** above, and any of the licenses or grants granted by the Author hereunder exceed the scope of the 17 U.S.C. 403, then the rights granted hereunder shall be limited to the maximum rights permitted under such

statute. In such case, all provisions contained herein that are not in conflict with such statute shall remain in full force and effect, and all provisions contained herein that do so conflict shall be deemed to be amended so as to provide to JoVE the maximum rights permissible within such statute.

8. Likeness, Privacy, Personality. The Author hereby grants JoVE the right to use the Author's name, voice, likeness, picture, photograph, image, biography and performance in any way, commercial or otherwise, in connection with the Materials and the sale, promotion and distribution thereof. The Author hereby waives any and all rights he or she may have, relating to his or her appearance in the Video or otherwise relating to the Materials, under all applicable privacy, likeness, personality or similar laws.

9. Author Warranties. The Author represents and warrants that the Article is original, that it has not been published, that the copyright interest is owned by the Author (or, if more than one author is listed at the beginning of this Agreement, by such authors collectively) and has not been assigned, licensed, or otherwise transferred to any other party. The Author represents and warrants that the author(s) listed at the top of this Agreement are the only authors of the Materials. If more than one author is listed at the top of this Agreement and if any such author has not entered into a separate Article and Video License Agreement with JoVE relating to the Materials, the Author represents and warrants that the Author has been authorized by each of the other such authors to execute this Agreement on his or her behalf and to bind him or her with respect to the terms of this Agreement as if each of them had been a party hereto as an Author. The Author warrants that the use, reproduction, distribution, public or private performance or display, and/or modification of all or any portion of the Materials does not and will not violate, infringe and/or misappropriate the patent, trademark, intellectual property or other rights of any third party. The Author represents and warrants that it has and will continue to comply with all government, institutional and other regulations, including, without limitation all institutional, laboratory, hospital, ethical, human and animal treatment, privacy, and all other rules, regulations, laws, procedures or guidelines, applicable to the Materials, and that all research involving human and animal subjects has been approved by the Author's relevant institutional review board.

10. JoVE Discretion. If the Author requests the assistance of JoVE in producing the Video in the Author's facility, the Author shall ensure that the presence of JoVE employees, agents or independent contractors is in accordance with the relevant regulations of the Author's institution. If more than one author is listed at the beginning of this Agreement, JoVE may, in its sole discretion, elect not take any action with respect to the Article until such time as it has received complete, executed Article and Video License Agreements from each such author. JoVE reserves the right, in its absolute and sole discretion and without giving any reason therefore, to accept or decline any work submitted to JoVE. JoVE and its employees, agents and independent contractors shall have

ARTICLE AND VIDEO LICENSE AGREEMENT

full, unfettered access to the facilities of the Author or of the Author's institution as necessary to make the Video, whether actually published or not. JoVE has sole discretion as to the method of making and publishing the Materials, including, without limitation, to all decisions regarding editing, lighting, filming, timing of publication, if any, length, quality, content and the like.

11. **Indemnification.** The Author agrees to indemnify JoVE and/or its successors and assigns from and against any and all claims, costs, and expenses, including attorney's fees, arising out of any breach of any warranty or other representations contained herein. The Author further agrees to indemnify and hold harmless JoVE from and against any and all claims, costs, and expenses, including attorney's fees, resulting from the breach by the Author of any representation or warranty contained herein or from allegations or instances of violation of intellectual property rights, damage to the Author's or the Author's institution's facilities, fraud, libel, defamation, research, equipment, experiments, property damage, personal injury, violations of institutional, laboratory, hospital, ethical, human and animal treatment, privacy or other rules, regulations, laws, procedures or guidelines, liabilities and other losses or damages related in any way to the submission of work to JoVE, making of videos by JoVE, or publication in JoVE or elsewhere by JoVE. The Author shall be responsible for, and shall hold JoVE harmless from, damages caused by lack of sterilization, lack of cleanliness or by contamination due to the making of a video by JoVE its employees, agents or independent contractors. All sterilization, cleanliness or decontamination procedures shall be solely the responsibility of the Author and shall be undertaken at the Author's

expense. All indemnifications provided herein shall include JoVE's attorney's fees and costs related to said losses or damages. Such indemnification and holding harmless shall include such losses or damages incurred by, or in connection with, acts or omissions of JoVE, its employees, agents or independent contractors.

12. **Fees.** To cover the cost incurred for publication, JoVE must receive payment before production and publication the Materials. Payment is due in 21 days of invoice. Should the Materials not be published due to an editorial or production decision, these funds will be returned to the Author. Withdrawal by the Author of any submitted Materials after final peer review approval will result in a US\$1,200 fee to cover pre-production expenses incurred by JoVE. If payment is not received by the completion of filming, production and publication of the Materials will be suspended until payment is received.

13. **Transfer, Governing Law.** This Agreement may be assigned by JoVE and shall inure to the benefits of any of JoVE's successors and assignees. This Agreement shall be governed and construed by the internal laws of the Commonwealth of Massachusetts without giving effect to any conflict of law provision thereunder. This Agreement may be executed in counterparts, each of which shall be deemed an original, but all of which together shall be deemed to be one and the same agreement. A signed copy of this Agreement delivered by facsimile, e-mail or other means of electronic transmission shall be deemed to have the same legal effect as delivery of an original signed copy of this Agreement.

A signed copy of this document must be sent with all new submissions. Only one Agreement required per submission.

CORRESPONDING AUTHOR:

| | | | |
|----------------|--|-------|-----------|
| Name: | Michael Safaee | | |
| Department: | Neurological Surgery | | |
| Institution: | UCSF | | |
| Article Title: | Cone Beam Intraoperative Computed Tomography-Based Image Guidance for Minimally Invasive Transforaminal Interbody Fusion | | |
| Signature: | Michael Safaee | Date: | 3/15/2018 |

Please submit a signed and dated copy of this license by one of the following three methods:

- 1) Upload a scanned copy of the document as a pdf on the JoVE submission site;
- 2) Fax the document to +1.866.381.2236;
- 3) Mail the document to JoVE / Attn: JoVE Editorial / 1 Alewife Center #200 / Cambridge, MA 02139

For questions, please email submissions@jove.com or call +1.617.945.9051

Changes recommended by the JoVE Scientific Review Editor:

- Please take this opportunity to thoroughly proofread the manuscript to ensure that there are no spelling or grammatical errors.
- Please include at least six keywords/phrases.

Several keywords have now been added to meet the recommended number.

- **Introduction:** Please expand your Introduction to include the following: The advantages over alternative techniques with applicable references to previous studies; Description of the context of the technique in the wider body of literature; Information that can help readers to determine if the method is appropriate for their application.

Thank you for the helpful suggestion, the introduction has been accordingly revised to provide more context and background information to the reader

- **Protocol Language:** The JoVE protocol should be almost entirely composed of **numbered short steps** (2-3 related actions each) written in **the imperative voice/tense** (as if you are telling someone how to do the technique, i.e. "Do this", "Measure that" etc.). Any text that cannot be written in the imperative tense may be added as a brief "Note" at the end of the step (please limit notes). Please re-write your **ENTIRE** protocol section accordingly. Descriptive sections of the protocol can be moved to Representative Results or Discussion. The JoVE protocol should be a set of instructions rather a report of a study. Any reporting should be moved into the representative results.

The entire protocol has been revised to meet the standards that have been requested

- **Protocol Detail:** Please note that your protocol will be used to generate the script for the video, and must contain everything that you would like shown in the video. There should be enough detail in each step to supplement the actions seen in the video so that viewers can easily replicate the protocol.
- **Protocol Numbering:** Please add numbering to the protocol section to follow JoVE's instructions for authors, 1. should be followed by 1.1. and then 1.1.1. if necessary and all steps should be lined up at the left margin with no indentations. There must also be a one-line space between each protocol step.

The entire protocol has been revised to meet the standards that have been requested

- **Protocol Highlight:** After you have made all of the recommended changes to your protocol (listed above), please re-evaluate the length of your protocol section. There is a 10-page limit for the protocol text, and a 3- page limit for filmable content. If your protocol is longer than 3 pages, please highlight ~2.5 pages or less of text (which includes headings and spaces) in yellow, to identify which steps should be visualized to tell the most cohesive story of your protocol steps. Please see JoVE's instructions for authors for more clarification. Remember that the non-

highlighted protocol steps will remain in the manuscript and therefore will still be available to the reader.

Thank you for the suggestion, the protocol length should be within the limits that have been suggested

• **Results:** We require at least some results (figures/tables) that demonstrate the success of your technique, this can be an application of your method to a specific study or general results that validate the technique. These must be fully discussed in the Representative results. The current results do not sufficiently support and validate the technique you present. **You reference Table 1 and 2 but no Tables have been provided. Please add the tables and appropriate legends.**

Thank you for detecting this omission, we have now included the tables that were referenced. With respect to validation of our technique, there is currently limited data on how radiation exposure is reduced with use of CT-guided navigation. However, we do reference our results in comparison to historical results in our discussion.

• **Discussion:** JoVE articles are focused on the methods and the protocol, thus the discussion should be similarly focused. Please ensure that the discussion covers the following in detail and in paragraph form: 1) modifications and troubleshooting, 2) limitations of the technique, 3) significance with respect to existing methods, 4) future applications and 5) critical steps within the protocol.

Thank you for this comment. The discussion section has been revised

• **Figures:** Please add scale bars.

• **Table of Materials:** Please revise the table of the essential supplies, reagents, and equipment. The table should include the name, company, and catalog number of all relevant materials/software in separate columns in an xls/xlsx file. Please include items such as surgical tools, imagers, etc.

• Please define all abbreviations at first use.

• Please use standard abbreviations and symbols for SI Units such as μL , mL, L, etc., and abbreviations for non-SI units such as h, min, s for time units. Please use a single space between the numerical value and unit.

• If your figures and tables are original and not published previously or you have already obtained figure permissions, please ignore this comment. If you are re-using figures from a previous publication, you must obtain explicit permission to re-use the figure from the previous publisher (this can be in the form of a letter from an editor or a link to the editorial policies that allows you to re-publish the figure). Please upload the text of the re-print permission (may be copied and pasted from an email/website) as a Word document to the Editorial Manager site in the "Supplemental files (as requested by JoVE)" section. Please also cite the figure appropriately

in the figure legend, i.e. "This figure has been modified from [citation]."

Comments from Peer-Reviewers:

Reviewer #1:

Manuscript Summary:

The authors presented the method titled; Computed tomography-based image guidance for minimally invasive transforaminal interbody fusion.

The manuscript is written in proper English and friendly format. However, several things need to be fixed before been considered for publication as a "Method".

Major Concerns:

I will try to respond to the requirements stated by the Journal and their relationship with the findings in this manuscript.

Are the title and abstract appropriate for this methods article?

" No, This suggestion is more adequate: "Cone Beam Intraoperative Computed tomography-based image guidance for minimally invasive transforaminal interbody fusion"

Thank you for this suggestion, we have revised the title accordingly.

Are there any other potential applications for the method/protocol the authors could discuss?

" No, or at least NO to perform a MIS-TLIF in combination with a cone beam iCT (o-Arm) + Fluoroscopy. Without using navigated instruments

Are all the materials and equipment needed listed in the table? (Please note that any basic lab materials or equipment do not need to be listed, e.g. pipettes.)

" NO, there are no tables in this manuscript

" The tables are referenced inside the text but they are not available for peer review

We apologize for this omission, the tables have now been included in the final manuscript.

" Do you think the steps listed in the procedure would lead to the described outcome?

" No, the steps are not listed. It's all running text.

" If you are using the different pictures inside Figure 1 as steps then the following example should be stated E.g. Step 1. TEXT (Figure 1A)

Are the steps listed in the procedure clearly explained?

" No, the overall procedure is explained but the text needs to be split in "Steps"

Are any important steps missing from the procedure?

" Yes,

" What is the type of cage used

" What type of graft is used, if it is bone marrow then clarify.

" What screw system is used

The cage is a PEEK cage and the graft is a combination of allograft and autograft (bone marrow). Both are now in the body of the text. The screw system used is the RELINE MAS percutaneous screw; however, as this is vendor-specific, we have left it out of the text

Are appropriate controls suggested?

" NA

Are all the critical steps highlighted?

" NO

Thank you for this comment, we have revised our discussion section so the critical steps are more apparent.

Is there any additional information that would be useful to include?

" A brief conclusion

We have added our manuscript to include a brief conclusion.

Are the anticipated results reasonable, and if so, are they useful to readers?

" Yes,

Thank you for this comment, we appreciate your time and thoughtful feedback.

Are any important references missing and are the included references useful?

" Yes, that this method does not rely on "Navigated Instruments[1]

" This method is an intermediate step on the ladder while shifting towards a "Total Navigation" modality [2][3] and because of the previous 2 reasons fluoroscopy is still necessary.

1. Shin, B.J., et al., Navigated guide tube for the placement of mini-open pedicle screws using stereotactic 3D navigation without the use of K-wires: technical note. J Neurosurg Spine, 2013. 18(2): p. 178-83.
2. Lian, X., et al., Total 3D Airo(R) Navigation for Minimally Invasive Transforaminal Lumbar Interbody Fusion. Biomed Res Int, 2016. 2016: p. 5027340.
3. Navarro-Ramirez, R., et al.,. World Neurosurg, 2017.

Thank you for this comment, we have included this point and the references in the conclusion section

Minor Concerns:

Step wise format

Tables missing but described on the text

Reviewer #2:

Manuscript Summary:

The authors submit a retrospective case series (level IV study) of 50 patients who all underwent the same surgical procedure (MIS TLIF) using CT-based (O-arm) navigation at 1 to 3 levels in the lumbar spine. They describe process measures, including EBL, surgical time and hospital

stay, as well as radiation exposure (in mGy) and radiation time (in seconds). Although navigation was used mainly for pedicle screw placement, the authors also describe using navigated probes and dilators to help with retractor placement and guiding extent of decompression to avoid damaging the pedicles.

A strength of the paper is the very well-described surgical technique / protocol, which gives the reader a very clear idea of how the surgeries were actually performed.

Major Concerns:

A major limitation of the paper is the lack of outcomes and follow-up. Specifically, there was no mention of complications; no patient-reported outcome measures of any kind (ODI, Pain scores, etc); no radiographic alignment measures; and no assessment of fusion status. While the authors are not required to come up with all these, I would recommend adding at least one of these to their paper.

Thank you for this comment. We appreciate that long-term follow-up and outcomes data is an important component to explaining the benefits of our technique. However, as you have also noted, that data is unavailable at this current time. Our study does include preliminary results, and we plan to follow up this technique manuscript with a future study focusing on complications. We note this as a limitation in our discussion section.

Minor Concerns:

- Abstract, line 31: "without any additional radiation exposure to the patient or operating room staff". Even after reading the Discussion in their paper, it would seem to me that there is only good evidence to state that using CT/O-arm based navigation leads to decreased radiation exposure to the surgical team/OR staff, because they could step away from the field/room at the time of image acquisition, but the evidence regarding the patient is still conflicting/debatable.

This is an excellent point. However, our data showed that the overall radiation dose and fluoroscopic exposure was smaller when compared to historical reports. Thus, while the radiation exposure is not an absolute minimum, it can reasonably be concluded that exposure is reduced compared to purely fluoroscopic techniques.

- Protocol, line 61: "A navigated high-speed drill..." I believe it is actually the drill guide that is navigated; the drill itself is not.

We have added the line as suggested.

- Results, lines 99-101: May I ask the authors to explain in more detail how they acquired the radiation exposure measurements? I understand that exposure is different from radiation dose, and that the latter is harder to measure because it depends on many factors including body distance from the source, tissue thickness, etc. I am questioning the "5.2 seconds from intraoperative CT scan", as the O-arm takes 13 to 26 seconds of continuous fluoro to perform one 3D spin (depending on whether one is using low or high def mode). I believe the 5.2 seconds only represents the radiation time from the 2D (e.g. AP and lateral) images taken with the O-arm; if one wishes to add the time used on 3D spins, then one has to multiply the number of spins taken by 13 or 26 seconds.

- Lastly, it was not clear whether this was a single surgeon series, or how many surgeons were doing the cases. Please clarify.

Thank you for this comment, it was a single-surgeon experience (senior author AC). We have included this comment in our text