

# Journal of Visualized Experiments

## A simple two-dimensional X-ray angiographic method to examine fine vascular structure using a silicone rubber injection compound

--Manuscript Draft--

<b>Article Type:</b>	Invited Methods Article - JoVE Produced Video
<b>Manuscript Number:</b>	JoVE57732R2
<b>Full Title:</b>	A simple two-dimensional X-ray angiographic method to examine fine vascular structure using a silicone rubber injection compound
<b>Keywords:</b>	Angiography; silicone rubber injection compound; Lead oxide; Barium; Flap territory; Angiosome; Radiopaque material; Angiographic agent
<b>Corresponding Author:</b>	Seong Oh Park Hanyang University Medical Center Seoul, KOREA, REPUBLIC OF
<b>Corresponding Author's Institution:</b>	Hanyang University Medical Center
<b>Corresponding Author E-Mail:</b>	psopark950@gmail.com
<b>First Author:</b>	Hak Chang
<b>Other Authors:</b>	Hak Chang Jeong Hyun Ha
<b>Author Comments:</b>	<p>16th April, 2018</p> <p>Editorial Board Journal of Visualized Experiments</p> <p>Dear Editor:</p> <p>We wish to re-submit the manuscript titled "A simple two-dimensional X-ray angiographic method to examine fine vascular structure using silicone rubber injection compound." The manuscript ID is JoVE57732R2.</p> <p>We thank you for the thoughtful suggestions and insights. The manuscript has benefited from these insightful suggestions. We look forward to working with you and the reviewers to move this manuscript closer to publication in the Journal of Visualized Experiments.</p> <p>The manuscript has been rechecked and the necessary changes have been made in accordance with editorial comments. The responses to all comments have been prepared and attached herewith. Our changes to our manuscript are in red texts.</p> <p>Thank you for your consideration. I look forward to hearing from you.</p> <p>Sincerely,</p> <p>Seong Oh Park 222-1, Wangsimni-ro, Seongdong-gu, Seoul, Republic of Korea Fax: 82-2-741-3985 Telephone: 82-2-2072-2370 Email: psopark950@gmail.com</p>
<b>Additional Information:</b>	
<b>Question</b>	<b>Response</b>
If this article needs to be "in-press" by a certain date, please indicate the date below and explain in your cover letter.	

16<sup>th</sup> April, 2018

Editorial Board

*Journal of Visualized Experiments*

Dear Editor:

We wish to re-submit the manuscript titled “A simple two-dimensional X-ray angiographic method to examine fine vascular structure using silicone rubber injection compound.” The manuscript ID is JoVE57732R2.

We thank you for the thoughtful suggestions and insights. The manuscript has benefited from these insightful suggestions. We look forward to working with you and the reviewers to move this manuscript closer to publication in the *Journal of Visualized Experiments*.

The manuscript has been rechecked and the necessary changes have been made in accordance with editorial comments. The responses to all comments have been prepared and attached herewith. Our changes to our manuscript are in red texts.

Thank you for your consideration. I look forward to hearing from you.

Sincerely,

Seong Oh Park

222-1, Wangsimni-ro, Seongdong-gu, Seoul, Republic of Korea

Fax: 82-2-741-3985

Telephone: 82-2-2072-2370

Email: psopark950@gmail.com

**TITLE:**

Two-Dimensional X-Ray Angiography to Examine Fine Vascular Structure Using a Silicone Rubber Injection Compound

**AUTHORS & AFFILIATIONS:**

Hak Chang<sup>1</sup>, Jeong Hyun Ha<sup>1</sup>, Seong Oh Park<sup>2</sup>

<sup>1</sup>Department of Plastic and Reconstructive Surgery, Seoul National University College of Medicine, Seoul, Korea

<sup>2</sup>Department of Plastic and Reconstructive Surgery, Hanyang University Medical Center, Hanyang University College of Medicine, Seoul, Korea

**Corresponding Author:**

Seong Oh Park (psopark950@gmail.com)

Fax: 82-2-741-3985

Tel: 82-2-2290-8564

**Email Addresses of Co-authors:**

Hak Chang (hchang@snu.ac.kr)

Jeong Hyun Ha (jhhaha90@hanmail.net)

**KEYWORDS:**

Angiography, silicone rubber injection compound, lead oxide, barium, flap territory, angiosome, radiopaque material, angiographic agent

**SUMMARY:**

This study presents a simple two-dimensional angiographic method to examine fine vascular structures using a silicone rubber injection compound and soft tissue X-ray system.

**ABSTRACT:**

Angiography is an essential tool for the study of vascular structures in various research fields. The aim of this study is to introduce a simple angiographic method for examining the fine vascular structure of unfixed, fresh tissue using a silicone rubber injection compound and soft tissue X-ray system. This study is especially focused on flap territories used in reconstructive surgery. This study employs angiography with a silicone rubber injection compound in various experimental conditions using Sprague-Dawley rats. First, 15 mL of MV compound and 15 mL of diluent is mixed. Then, 1.5 mL of the curing agent is prepared, and a 24G catheter is cannulated in the common carotid artery of the rat. A three-way stopcock is then connected to a catheter, and the radiopaque agent, after being mixed with the prepared curing agent, is injected immediately without spillage. Finally, as the agent solidifies, the specimen is harvested, and an angiographic image is obtained using a soft tissue X-ray system. This method indicates that high-quality angiography showing fine vascular structures can be easily and simply obtained within a short period of time.

## INTRODUCTION:

Examining vascular structures such as arteries and veins is an important area of interest, particularly in reconstructive surgery. In this field, flap surgery is widely performed. Therefore, angiographic imaging is actively used to study the flap territory, angiosome, and vascular supply of fresh tissue<sup>1</sup>. Specifically, there have been continuous efforts to observe the fine vasculature, including fine vessels such as perforators (vessels emerging from deep vessels reaching the skin), and choke vessels (connecting vessels between adjacent angiosomes)<sup>2</sup>. These two types of vessels are important in the perforator flap reconstruction field and are the main focus of the research<sup>3,4</sup>.

Various materials are used in angiography. First, there is India ink, which is helpful in observing the gross anatomy of blood vessels. However, it is radiolucent, so angiographic images cannot be obtained. The more commonly-used radiopaque materials are lead oxide and barium. However, toxicity is a crucial drawback of lead oxide, and it is inconvenient to use when mixed with water because of its powdered form. Barium is free from toxicity; however, it is not very feasible, as it should be used after dilution. Both of these radiopaque materials cannot cross capillaries; therefore, if a whole vascular structure must be analyzed, it is necessary to inject them into the artery and vein separately<sup>5</sup>. In addition, the two materials cause dye leakage during anatomical dissection, so they should be combined with gelatin. Lead oxide-gelatin and barium-gelatin mixtures take at least one day to solidify<sup>1,6,7</sup>.

Computed tomography (CT) angiography is another widely-used method and can aid in viewing three-dimensional (3D) structures<sup>8</sup>. However, veins cannot be visualized effectively<sup>5</sup>. In this modality, clear visualization of the fine vasculature such as choke veins is difficult, except when using specific equipment. The need for more expensive equipment can be a disadvantage, so CT angiography cannot be utilized in all laboratories. By contrast, the soft tissue X-ray system is relatively cheap and can operate more easily. This system is optimal for viewing soft tissues and can provide higher quality soft tissue images than the simple X-ray system. Although the soft tissue X-ray system itself cannot show 3D images, it can help visualize fine vascular structures more clearly than CT angiography. Therefore, we have used the soft tissue X-ray system in many experiments, particularly in various flap models and basic anatomy<sup>2,9</sup>.

Finally, the use of silicone rubber injection compound angiography has numerous advantages. Because various color agents are prepared, it can be injected and display distinguishable colors such as India ink. Therefore, simultaneously studying the gross anatomy and angiography is possible. It can both pass through capillaries and allow veins to be visualized, making examinations of fine vascular structures possible. Unlike the gelatin mixture, the silicone rubber injection compound solidifies within a short time period, approximately 15 minutes, without any additional procedures. The entire process is summarized in the schematic image in **Figure 1**.

## PROTOCOL:

All procedures, including animal subjects, have been approved by the Institutional Animal Care and Use Committees of Seoul National University Hospital (IACUC No. 10-0184). This protocol is optimized for research on flap vasculature. This example is based on a four-territory flap model

in our previous reports.

## **1. Establishing a Flap Condition**

Note: It is important to generate a vascular change in a rat flap model 4 to 5 days before visible estimation<sup>6,7</sup>.

1.1. Use 7-week-old male Sprague-Dawley rats weighing 200 - 250 g.

1.2. Anesthetize the rats using isoflurane at 3 - 5% for induction and 2 - 2.5% for maintenance. Perform a toe pinch withdrawal reflection test to confirm that the depth of anesthesia is sufficient.

1.3. Shave the trunk using an animal hair clipper and hair removal cream (thioglycolic acid, 80%). Prepare a sterile surgical field with 10% povidone-iodine and a sterile drape to maintain a sterile condition throughout the procedures. Apply a vet ointment to the eyes to prevent dryness.

1.4. Establish the appropriate the flap condition.

1.4.1. Mark a circumferential skin flap design from the lower abdomen to the back, measuring 4 x 12 cm. Locate the center of the flap halfway between the xiphoid process and the penis (**Figure 1**).

1.4.2. Make the incision as marked using a surgical blade.

1.4.3. Dissect the flap using scissors, including the skin and panniculus carnosus.

1.4.4. Dissect around the vascular pedicle [bilateral deep circumflex iliac (DCI) vessels and bilateral superficial inferior epigastric (SIE) vessels] at the lower abdomen and expose the vascular pedicle using a surgical loupe and microsurgical instruments.

1.4.5. Maintain or ligate the vessels depending on the desired conditions.

1.4.6. Divide the flap along the dorsal midline using a surgical blade or scissors.

1.4.7. Lay the flap in its original position and fix it with a skin stapler.

1.4.8. Apply a topical ointment to the surgical wound for 3 days and provide postoperative analgesia by administering meloxicam at a dose of 5 mg/kg orally once per day for 3 days.

1.4.9. Confirm that the rat regains sufficient consciousness to maintain sternal recumbency. Return the rat into the cage and move it to the breeding area.

## **2. Preparation of the Instruments**

2.1. Prepare a 24G catheter and a three-way stopcock.

2.2. Prepare mosquito forceps, small scissors, a surgical scalpel, and a surgical blade.

2.3. Prepare the angiographic agent (silicone rubber injection compound).

2.3.1. Blend the color agent compound with the diluent in the sterile specimen collection cup. Ensure an equal quantity by weight: 15 mL of color agent compound and 15 mL of MV diluent in one rat (Sprague-Dawley rat, 200 - 250 g).

2.3.2. Add the curing agent per 5% weight or volume of the mixture solution immediately before injection: 1.5 mL of curing agent in one rat (Sprague-Dawley rat, 200 - 250 g).

### 3. Rat Artery Preparation

3.1. Use isoflurane to anesthetize the rats (3 - 5% for induction and 2 - 2.5% for maintenance).

3.2. Shave the neck using an animal hair clipper and hair removal cream (thioglycolic acid, 80%). Prepare a sterile surgical field with 10% povidone-iodine and a sterile drape to maintain a sterile condition throughout the procedures. Apply a vet ointment to the eyes to prevent dryness.

3.3. Expose the common carotid artery<sup>10</sup>.

3.3.1. Make a 2-cm midline incision between the scapulae.

3.3.2. Dissect more deeply using mosquito forceps and blunt scissors until the salivary gland complex is exposed.

3.3.3. Retract the salivary gland and bluntly dissect the omohyoid muscle longitudinally.

3.3.4. Dissect around the common carotid artery.

3.4. Hook the cephalic and caudal sides of the common carotid artery with black silk and affix it.

3.4.1. Keep traction to maintain engorgement of the artery.

3.4.2. Prepare one silk tie at the caudal side.

### 4. Cannulation

4.1. Cannulate the prepared carotid artery using a 24G catheter.

4.2. Tighten the pre-made tie in the caudal side and be careful to not remove the catheter during

injection.

4.3. Prepare the curing agent (step 1.3.2).

4.4. Connect the three-way stopcock securely to the inserted catheter.

4.4.1. Confirm regurgitated blood into the catheter by adding negative pressure using an empty syringe.

## 5. Injection

5.1. Inject the silicone rubber injection compound until the color of the eye and foot has changed.

Note: The color change should appear as the injected fluid progresses (injection amount is approximately 25 - 30 mL for each rat).

5.2. Lock the three-way stopcock and wait until the agent solidifies.

5.2.1. Be careful not to contaminate with the agent, especially when removing the syringe from the three-way stopcock. Use a protective barrier such as gauze or vinyl to separate the injection space from its surroundings.

CAUTION: Any contamination makes it difficult to analyze the angiographic image because the compound is radio-opaque.

5.2.2. Confirm the cessation of heartbeats and respiration. Stop the anesthesia.

5.2.3. Observe the rate of hardness with the remaining agent as a reference (approximately 15 min needed).

## 6. Harvesting of Specimen

6.1. Make an incision using a surgical blade to the panniculus carnosus 1 cm outside the flap to prevent damage to any vascular structure inside the flap.

6.2. Dissect along the previously dissected plane from step 1.4 (under the panniculus carnosus plane) and harvest the tissue including the flap and vascular pedicle using scissors (the vascular structure is included in the flap).

6.3. Ligate the pedicle of the flap using a 5-0 silk suture and separate the flap from the body. Be careful not to damage the vascular structure.

## 7. Capturing the Angiographic Image

7.1. Spread out the specimen, ensuring that it does not fold, and gently place it on the surgical drape using forceps.

7.2. Take a radiography image.

7.2.1. Transfer the specimen lying on the film cassette to the sample loading space.

7.2.2. Set the soft tissue X-ray system to 60 kVp, 5 mA, and 5 s exposure.

7.3. Develop the film in a darkroom using an automatic development machine.

7.4. Scan the film at the highest resolution possible.

## 8. Analyzing the Image<sup>6,7,11</sup>

8.1. Distinguish the arteries and veins based on the continuity of flow and diameter.

8.1.1. Start from the inflow of the pedicle artery and focus on the target vessel being examined.

8.1.2. Measure the diameters with software by first opening the image.

8.1.2.1. Click the **Straight** button and draw a line on the scale bar that is the same length.

8.1.2.2. Open the **Analyze | Set scale** menu and enter the value of the scale bar into **Known distance**.

8.1.2.3. Click the **Straight** button and draw a line onto the vessel of which the diameter needs to be measured.

8.1.2.4. Open the **Analyze | Measure** menu and confirm the **Length**.

8.2. Analyze the vascular pattern considering the flap survival area.

## REPRESENTATIVE RESULTS:

Through following this protocol, the flap vascularity of the Sprague-Dawley rat was examined. A circumferential skin flap from the lower abdomen to the back that measured 4 x 12 cm was marked based on our previous reports. Each specimen was in a different vascular condition.

All the flaps were elevated based on the deep circumflex iliac artery (DCIA) and vein and then supercharged with arteries from various locations. Group 1 was the control, group 2 was supercharged with the ipsilateral superficial inferior epigastric artery (SIEA), group 3 was supercharged with the contralateral SIEA, and group 4 was supercharged with the contralateral DCIA. As a result, angiographs of each flap showed different patterns. If the entire flap was divided into four zones as the standard with the main vessel charging the flap territory, the



angiographic agent has reached the main vessel that charges the next distal zone beyond the supercharging artery. The dilated choke vein was also observed, but not seen in normal skin angiography (**Figure 2**).

In other instances, silicone rubber injection angiography clearly showed fine vascular structures. Here, the method is advantageous because the rat vein is so thin and not easily visualized with angiography. High-quality angiographic images displayed dilated choke veins even in specific conditions looking at arterial supply and venous drainage from different sources (e.g., an artery such as the ipsilateral DCIA or vein such as the contralateral superficial inferior epigastric vein) (**Figure 3**).

#### FIGURE LEGENDS:

**Figure 1: Schema of the entire procedure.** This panel shows the preparation of the desired flap condition beforehand and the performance of angiography 4 - 5 days later, using the following process: angiographic agent preparation, injection, specimen harvesting, and image capturing.

**Figure 2: Typical angiography of flaps on postoperative day 4 in the rat skin flap.** The normal skin represents the original four vascular territory flaps in the lower trunk area. The flap includes four vascular territories, including the bilateral deep circumflex iliac (DCI) and superficial inferior epigastric (SIE) vessel territories (yellow square). All groups have a common vascular pedicle, the deep circumflex iliac artery and vein (DCIA&V). Additionally, each flap has a different supercharging artery. Group 2 is supercharged with the ipsilateral superficial inferior epigastric artery (SIEA), group 3 is supercharged with the contralateral SIEA, and group 4 is supercharged with the contralateral DCIA. Group 4 shows different survived flap areas and angiographic patterns. Because the supercharging artery is distal to the original vascular pedicle (DIEA&V), the more distally located major vessel is contrasted by the agent (yellow arrow). Finally, the dilated choke veins that connect the vascular territories are visible (white arrowhead). i = ipsilateral; c = contralateral. Scale bar = 1 cm.

**Figure 3: Other representative results.** The flap shown is supplied by the ipsilateral deep circumflex iliac artery (DCIA) and drained by the contralateral superficial inferior epigastric vein (SIEV). (Upper left) This panel shows the gross photography of the harvested flap. The ipsilateral side shows congestive change, but flap necrosis does not occur. The mid-portion and distal two-thirds of the flap show a complete survival. (Lower left) Angiography shows detailed fine vascular structure including the dilated choke vein, which connects the adjacent vascular territory. (Right) Magnified angiography distinguishes arteries (red arrowheads) and veins (blue arrowheads) by the continuity and diameter of vessels. In general, veins show larger diameters than arteries. DCIA = the deep circumflex iliac artery; SIEV = the superficial inferior epigastric vein; the white arrowhead = the dilated choke vein. Scale bar = 1 cm.

#### DISCUSSION:

Silicone rubber injection compound angiography can be performed easily, does not require expensive equipment, and offers many advantages. In contrast to the preoperative and

intraoperative evaluations of patients, experiments using animals and cadavers can provide details on specific conditions, enabling more diverse and in-depth studies. The flap model using rats is particularly valuable to clinicians because changes in various contexts can be observed before clinical applications<sup>6,7,11</sup>. For example, when supercharging or superdrainage is applied to a long flap, which can resolve distal ischemic necrosis, predicting the outcome in the flap territory is possible; hence, it is possible to increase the survival of flaps by applying these techniques to clinical practice (**Figure 2**). In the case of cadaver dissection, gross anatomic and angiographic evaluations can be performed simultaneously, maximizing the cadaver's use<sup>12</sup>.

The silicone rubber injection compound is easier to handle than other radiopaque materials. Mixing the silicone rubber injection compound and diluent beforehand and adding the curing agent directly before injection are the primary processes involved. As with other imaging methods, care should be taken to avoid spillage during injection. To avoid spillage, we recommend using a secure tie and a three-way stopcock with a catheter after cannulation. If there is spillage, the specimen may become contaminated with the radiopaque agent, lowering its quality as an angiographic image. As discussed, the silicone rubber injection compound is advantageous in that it solidifies quickly after mixing it in, after about 15 min. However, the experiment is typically finished within this time. Therefore, we recommend mixing in only the amount needed for one rat at a time, even when performing multiple experiments. Performance of X-ray imaging after compound solidification should be done before the denaturation of the fresh tissue.

The molecular size of the silicone rubber injection compound is small enough to pass through the capillaries; therefore, there is no need to inject the agent into the vein separately, which is another advantage. On the contrary, the lead oxide-gelatin mixture or barium-gelatin mixture must be injected into veins separately for venous visualization. However, they cannot pass through valves in the veins, so it is necessary to perform serial cannulations and injections. The physiologic antegrade flow from artery to vein can be observed when using silicone rubber injection compounds, yet this characteristic is not observed when using other contrast agents.

Both arteries and veins can be contrasted with the silicone rubber injection compound and can be distinguished according to the continuity of flow and diameter (**Figure 3**). In general, veins show a relatively larger diameter.

One of the disadvantages of performing a 3D analysis using the soft tissue X-ray system is that it is more difficult than using CT angiography<sup>8</sup>. Although stereoscopic radiography can be achieved using the soft tissue X-ray system, it does not produce the high-quality 3D images seen in CT angiography<sup>13</sup>. However, it is still superior for visualizing fine vascular structures. This is particularly noticeable when using the soft tissue X-ray system rather than the plain X-ray system (**Figure 3**). At present, real-time CT angiography is used to observe 3D changes with time flow<sup>14,15</sup>. 3D real-time images cannot be achieved using only the soft tissue X-ray system, but real-time angiography can be achieved through serial imaging using the mobile C-arm system during the injection. Although its image quality is weaker than that of the soft tissue X-ray system for visualizing fine vascular structures, it can enable evaluation of dynamic changes in real time. We

actively recommend this method to researchers who cannot utilize micro-CT or wish to conduct basic research on fine vascular structures such as small veins that are not effectively visualized by micro-CT.

#### **ACKNOWLEDGMENTS:**

This work (2017R1A2B1006403) was supported by the Mid-Career Researcher Program through a National Research Foundation grant funded by the Korean government (Ministry of Science and ICT).

#### **DISCLOSURES:**

The authors have nothing to disclose.

#### **REFERENCES:**

1. Taylor, G. I., Minabe, T. The Angiosomes of the Mammals and Other Vertebrates. *Plastic and Reconstructive Surgery*. **89** (2), 181-215 (1992).
2. Taylor, G. I., Palmer, J. H. The vascular territories (angiosomes) of the body: experimental study and clinical applications. *British Journal of Plastic Surgery*. **40** (2), 113-141 (1987).
3. Geddes, C. R., Morris, S. F., Neligan, P. C. Perforator flaps: evolution, classification, and applications. *Annals of Plastic Surgery*. **50** (1), 90-99 (2003).
4. Saint-Cyr, M., Schaverien, M. V., Rohrich, R. J. Perforator Flaps: History, Controversies, Physiology, Anatomy, and Use in Reconstruction. *Plastic and Reconstructive Surgery*. **123** (4), 132e-145e (2009).
5. Lie, K. H., Taylor, G. I., Ashton, M. W. Hydrogen peroxide priming of the venous architecture: a new technique that reveals the underlying anatomical basis for venous complications of DIEP, TRAM, and other abdominal flaps. *Plastic and Reconstructive Surgery*. **133** (6), 790e-804e (2014).
6. Chang, H., Nobuaki, I., Minabe, T., Nakajima, H. Comparison of Three Different Supercharging Procedures in a Rat Skin Flap Model. *Plastic and Reconstructive Surgery*. **113** (1), 277-283 (2004).
7. Chang, H., Minn, K. W., Imanishi, N., Minabe, T., Nakajima, H. Effect of Venous Superdrainage on a Four-Territory Skin Flap Survival in Rats. *Plastic and Reconstructive Surgery*. **119** (7), 2046-2051 (2007).
8. Rozen, W. M., Stella, D. L., Ashton, M. W., Phillips, T. J., Taylor, G. I. Three-dimensional CT angiography: a new technique for imaging microvascular anatomy. *Clinical Anatomy*. **20** (8), 1001-1003 (2007).
9. Taylor, G. I., Chubb, D. P., Ashton, M. W. True and "choke" anastomoses between perforator

angiosomes: part i. anatomical location. *Plastic and Reconstructive Surgery*. **132** (6), 1447-1456 (2013).

10. Feng, J., Fitz, Y., et al. Catheterization of the carotid artery and jugular vein to perform hemodynamic measures, infusions and blood sampling in a conscious rat model. *Journal of Visualized Experiments*. (95), e51881 (2015).

11. Park, S. O., Cho, J., Imanishi, N., Chang, H. Effect of distal venous drainage on the survival of four-territory flaps with no pedicle vein: Results from a rat model. *Journal of Plastic, Reconstructive & Aesthetic Surgery*. **71** (3), 410-415 (2018).

12. Park, S. O., Chang, H., Imanishi, N. The free serratus anterior artery perforator flap-A case report and anatomic study. *Microsurgery*. **36** (4), 339-344 (2016).

13. Imanishi, N., Nakajima, H., Minabe, T., Chang, H., Aiso, S. Anatomical relationship between arteries and veins in the paraumbilical region. *British Journal of Plastic Surgery*. **56** (6), 552-556 (2003).

14. Schaverien, M., Saint-Cyr, M., Arbique, G., Rohrich, R. J. Three- and four-dimensional arterial and venous anatomies of the thoracodorsal artery perforator flap. *Plastic and Reconstructive Surgery*. **121** (5), 1578-1587 (2008).

15. Schaverien, M., Saint-Cyr, M., Arbique, G., Hatef, D., Brown, S. A., Rohrich, R. J. Three- and Four-Dimensional Computed Tomographic Angiography and Venography of the Anterolateral Thigh Perforator Flap. *Plastic and Reconstructive Surgery*. **121** (5), 1685-1696 (2008).

Figure 1

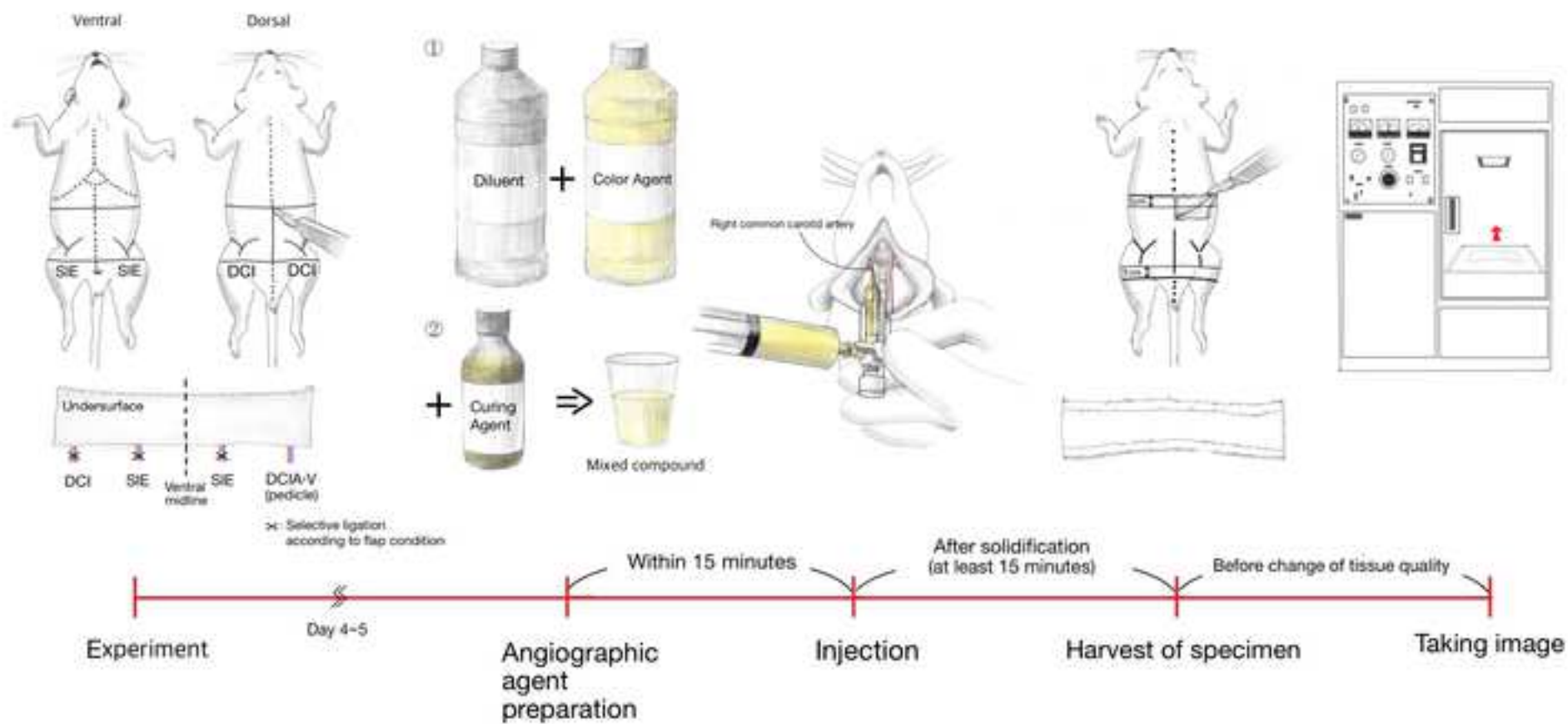


Figure 2

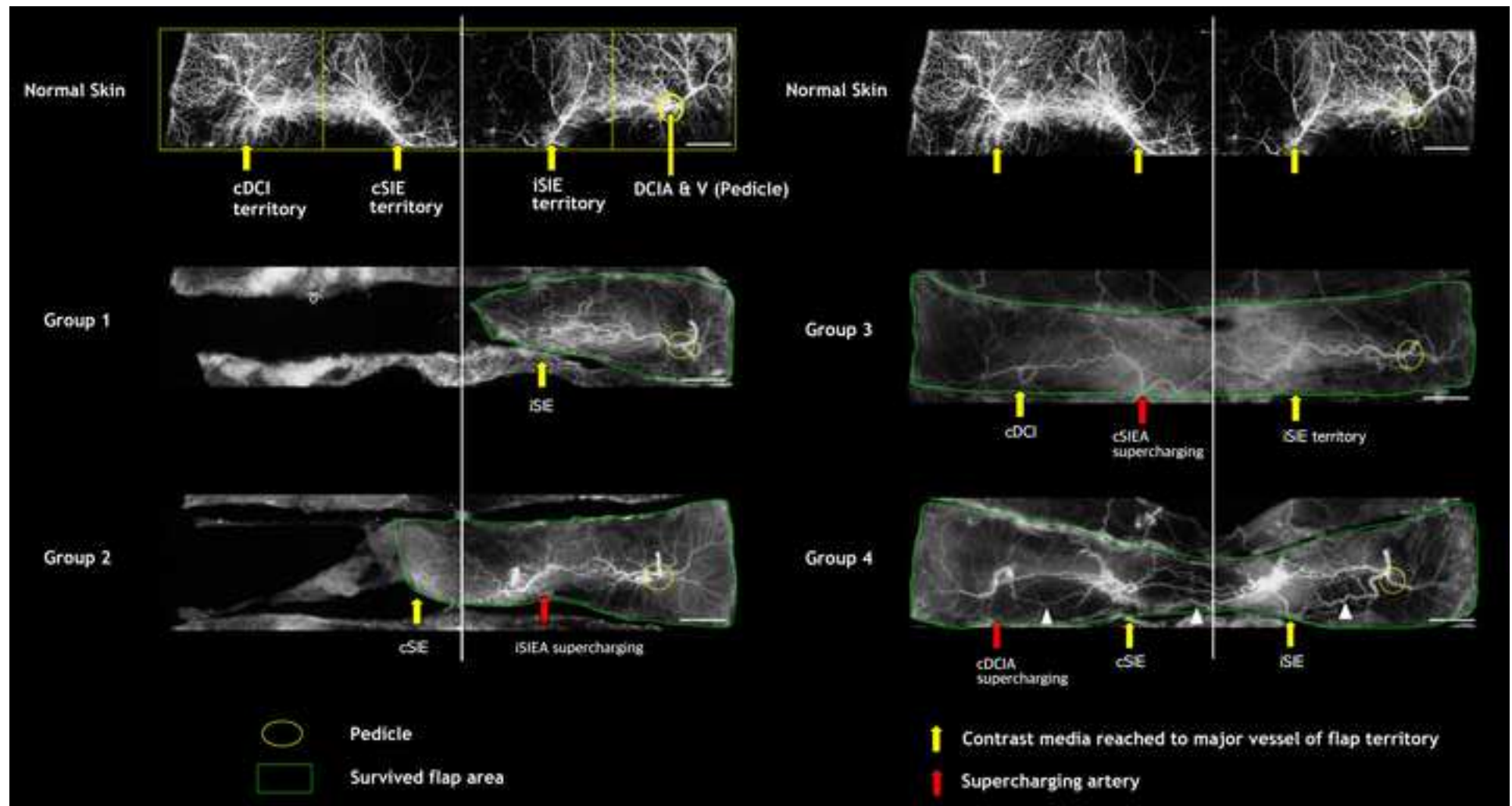
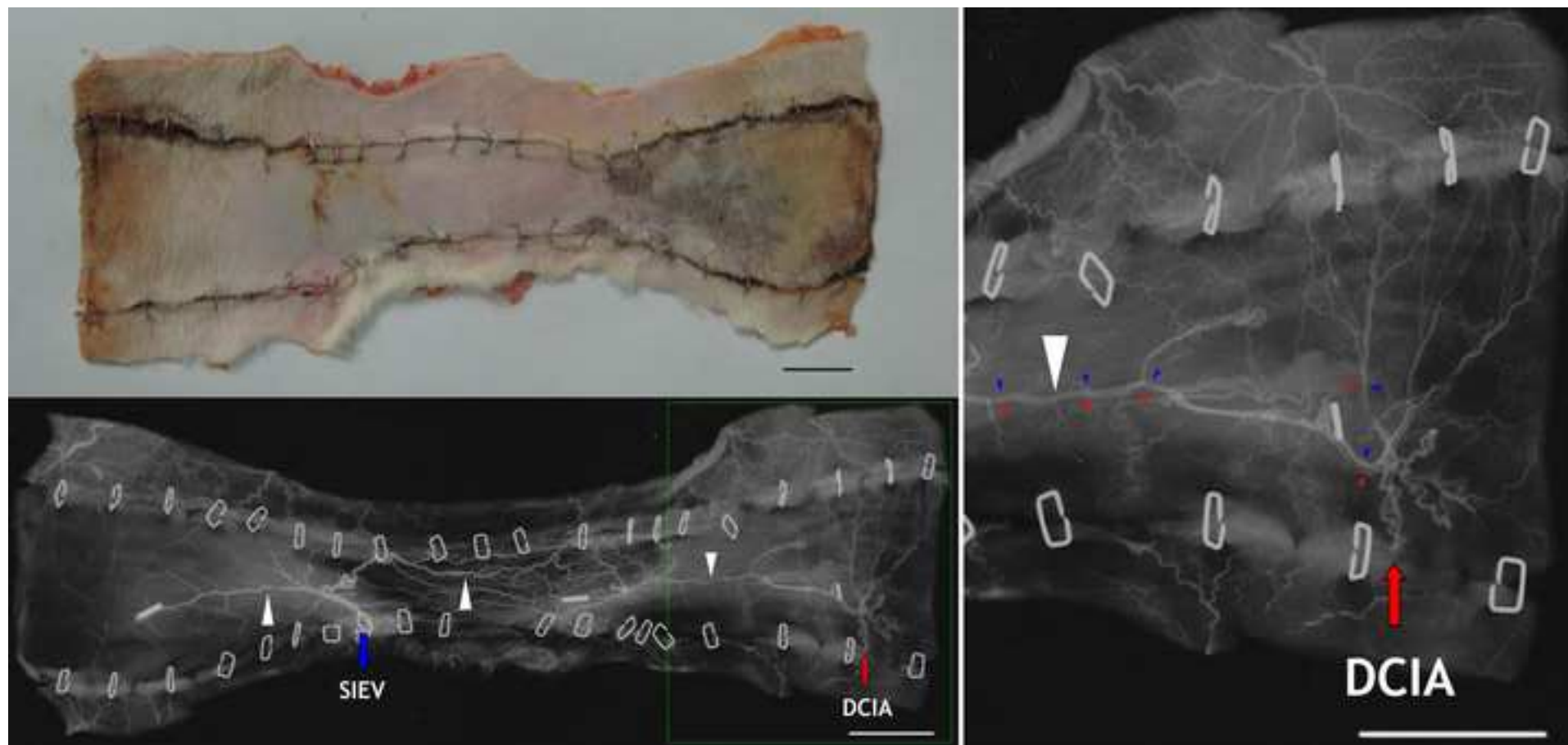


Figure 3



**Name of Material/ Equipment**

MICROFIL Silicone Rubber Injection Compounds
MICROFIL Silicone Rubber Injection Compounds
MICROFIL Silicone Rubber Injection Compounds
MICROFIL Silicone Rubber Injection Compounds
MICROFIL Silicone Rubber Injection Compounds
MICROFIL Silicone Rubber Injection Compounds
MICROFIL Silicone Rubber Injection Compounds
MICROFIL CP-101 For Cast Corrosion Preparations
SOFTEX X-ray film photographing inspection equipment
Film
Automatic Development Machine
Rat
Three-way stopcock
24-guage catheter
Image J



## **Company**

Flow Tech Inc.

Flow Tech Inc.

Flow Tech Inc.

Flow Tech Inc.

Flow Tech Inc.

Flow Tech Inc.

Flow Tech Inc.

Flow Tech Inc.

SOFTEX

Fujifilm

Fujifilm

National Institutes of Health

Catalog Number	Comments/Description
MV-112	White color agent
MV-117	Orange color agent
MV-120	Blue color agent
MV-122	Yellow color agent
MV-130	Red color agent
MV-132	Clear agent
MV-Diluent	Diluent
CP-101	Curing agent
CMB-2	Soft tissue x-ray system
Industrial X-ray Film (FR 12x16.5cm)	
FPM 2800	
	Sprague-Dawley rat weighing 200-250 g
	<a href="https://imagej.nih.gov/ij/">https://imagej.nih.gov/ij/</a>



1 Alewife Center #200  
 Cambridge, MA 02140  
 tel. 617.945.9051  
 www.jove.com

## ARTICLE AND VIDEO LICENSE AGREEMENT

Title of Article:

A simple angiographic method to examine fine vascular structure using Microfil®

Author(s):

Hak Chong, Jeong Hyun Ha, Seong Oh Park

Item 1 (check one box): The Author elects to have the Materials be made available (as described at <http://www.jove.com/author>) via: ☒ Standard Access ☐ Open Access

Item 2 (check one box):

- ☒ The Author is NOT a United States government employee.
- ☐ The Author is a United States government employee and the Materials were prepared in the course of his or her duties as a United States government employee.
- ☐ The Author is a United States government employee but the Materials were NOT prepared in the course of his or her duties as a United States government employee.

### ARTICLE AND VIDEO LICENSE AGREEMENT

1. **Defined Terms.** As used in this Article and Video License Agreement, the following terms shall have the following meanings: "**Agreement**" means this Article and Video License Agreement; "**Article**" means the article specified on the last page of this Agreement, including any associated materials such as texts, figures, tables, artwork, abstracts, or summaries contained therein; "**Author**" means the author who is a signatory to this Agreement; "**Collective Work**" means a work, such as a periodical issue, anthology or encyclopedia, in which the Materials in their entirety in unmodified form, along with a number of other contributions, constituting separate and independent works in themselves, are assembled into a collective whole; "**CRC License**" means the Creative Commons Attribution-Non Commercial-No Derivs 3.0 Unported Agreement, the terms and conditions of which can be found at: <http://creativecommons.org/licenses/by-nc-nd/3.0/legalcode>; "**Derivative Work**" means a work based upon the Materials or upon the Materials and other pre-existing works, such as a translation, musical arrangement, dramatization, fictionalization, motion picture version, sound recording, art reproduction, abridgment, condensation, or any other form in which the Materials may be recast, transformed, or adapted; "**Institution**" means the institution, listed on the last page of this Agreement, by which the Author was employed at the time of the creation of the Materials; "**JoVE**" means MyJoVE Corporation, a Massachusetts corporation and the publisher of *The Journal of Visualized Experiments*; "**Materials**" means the Article and / or the Video; "**Parties**" means the Author and JoVE; "**Video**" means any video(s) made by the Author, alone or in conjunction with any other parties, or by JoVE or its affiliates or agents, individually or in collaboration with the Author or any other parties, incorporating all or any portion of the Article, and in which the Author may or may not appear.

2. **Background.** The Author, who is the author of the Article, in order to ensure the dissemination and protection of the Article, desires to have the JoVE publish the Article and create and transmit videos based on the Article. In furtherance of such goals, the Parties desire to memorialize in this Agreement the respective rights of each Party in and to the Article and the Video.

3. **Grant of Rights in Article.** In consideration of JoVE agreeing to publish the Article, the Author hereby grants to JoVE, subject to **Sections 4 and 7** below, the exclusive, royalty-free, perpetual (for the full term of copyright in the Article, including any extensions thereto) license (a) to publish, reproduce, distribute, display and store the Article in all forms, formats and media whether now known or hereafter developed (including without limitation in print, digital and electronic form) throughout the world, (b) to translate the Article into other languages, create adaptations, summaries or extracts of the Article or other Derivative Works (including, without limitation, the Video) or Collective Works based on all or any portion of the Article and exercise all of the rights set forth in (a) above in such translations, adaptations, summaries, extracts, Derivative Works or Collective Works and (c) to license others to do any or all of the above. The foregoing rights may be exercised in all media and formats, whether now known or hereafter devised, and include the right to make such modifications as are technically necessary to exercise the rights in other media and formats. If the "Open Access" box has been checked in **Item 1** above, JoVE and the Author hereby grant to the public all such rights in the Article as provided in, but subject to all limitations and requirements set forth in, the CRC License.



## ARTICLE AND VIDEO LICENSE AGREEMENT

4. **Retention of Rights in Article.** Notwithstanding the exclusive license granted to JoVE in **Section 3** above, the Author shall, with respect to the Article, retain the non-exclusive right to use all or part of the Article for the non-commercial purpose of giving lectures, presentations or teaching classes, and to post a copy of the Article on the Institution's website or the Author's personal website, in each case provided that a link to the Article on the JoVE website is provided and notice of JoVE's copyright in the Article is included. All non-copyright intellectual property rights in and to the Article, such as patent rights, shall remain with the Author.

5. **Grant of Rights in Video – Standard Access.** This **Section 5** applies if the "Standard Access" box has been checked in **Item 1** above or if no box has been checked in **Item 1** above. In consideration of JoVE agreeing to produce, display or otherwise assist with the Video, the Author hereby acknowledges and agrees that, Subject to **Section 7** below, JoVE is and shall be the sole and exclusive owner of all rights of any nature, including, without limitation, all copyrights, in and to the Video. To the extent that, by law, the Author is deemed, now or at any time in the future, to have any rights of any nature in or to the Video, the Author hereby disclaims all such rights and transfers all such rights to JoVE.

6. **Grant of Rights in Video – Open Access.** This **Section 6** applies only if the "Open Access" box has been checked in **Item 1** above. In consideration of JoVE agreeing to produce, display or otherwise assist with the Video, the Author hereby grants to JoVE, subject to **Section 7** below, the exclusive, royalty-free, perpetual (for the full term of copyright in the Article, including any extensions thereto) license (a) to publish, reproduce, distribute, display and store the Video in all forms, formats and media whether now known or hereafter developed (including without limitation in print, digital and electronic form) throughout the world, (b) to translate the Video into other languages, create adaptations, summaries or extracts of the Video or other Derivative Works or Collective Works based on all or any portion of the Video and exercise all of the rights set forth in (a) above in such translations, adaptations, summaries, extracts, Derivative Works or Collective Works and (c) to license others to do any or all of the above. The foregoing rights may be exercised in all media and formats, whether now known or hereafter devised, and include the right to make such modifications as are technically necessary to exercise the rights in other media and formats. For any Video to which this Section 6 is applicable, JoVE and the Author hereby grant to the public all such rights in the Video as provided in, but subject to all limitations and requirements set forth in, the CRC License.

7. **Government Employees.** If the Author is a United States government employee and the Article was prepared in the course of his or her duties as a United States government employee, as indicated in **Item 2** above, and any of the licenses or grants granted by the Author hereunder exceed the scope of the 17 U.S.C. 403, then the rights granted hereunder shall be limited to the maximum rights permitted under such

statute. In such case, all provisions contained herein that are not in conflict with such statute shall remain in full force and effect, and all provisions contained herein that do so conflict shall be deemed to be amended so as to provide to JoVE the maximum rights permissible within such statute.

8. **Likeness, Privacy, Personality.** The Author hereby grants JoVE the right to use the Author's name, voice, likeness, picture, photograph, image, biography and performance in any way, commercial or otherwise, in connection with the Materials and the sale, promotion and distribution thereof. The Author hereby waives any and all rights he or she may have, relating to his or her appearance in the Video or otherwise relating to the Materials, under all applicable privacy, likeness, personality or similar laws.

9. **Author Warranties.** The Author represents and warrants that the Article is original, that it has not been published, that the copyright interest is owned by the Author (or, if more than one author is listed at the beginning of this Agreement, by such authors collectively) and has not been assigned, licensed, or otherwise transferred to any other party. The Author represents and warrants that the author(s) listed at the top of this Agreement are the only authors of the Materials. If more than one author is listed at the top of this Agreement and if any such author has not entered into a separate Article and Video License Agreement with JoVE relating to the Materials, the Author represents and warrants that the Author has been authorized by each of the other such authors to execute this Agreement on his or her behalf and to bind him or her with respect to the terms of this Agreement as if each of them had been a party hereto as an Author. The Author warrants that the use, reproduction, distribution, public or private performance or display, and/or modification of all or any portion of the Materials does not and will not violate, infringe and/or misappropriate the patent, trademark, intellectual property or other rights of any third party. The Author represents and warrants that it has and will continue to comply with all government, institutional and other regulations, including, without limitation all institutional, laboratory, hospital, ethical, human and animal treatment, privacy, and all other rules, regulations, laws, procedures or guidelines, applicable to the Materials, and that all research involving human and animal subjects has been approved by the Author's relevant institutional review board.

10. **JoVE Discretion.** If the Author requests the assistance of JoVE in producing the Video in the Author's facility, the Author shall ensure that the presence of JoVE employees, agents or independent contractors is in accordance with the relevant regulations of the Author's institution. If more than one author is listed at the beginning of this Agreement, JoVE may, in its sole discretion, elect not take any action with respect to the Article until such time as it has received complete, executed Article and Video License Agreements from each such author. JoVE reserves the right, in its absolute and sole discretion and without giving any reason therefore, to accept or decline any work submitted to JoVE. JoVE and its employees, agents and independent contractors shall have



## ARTICLE AND VIDEO LICENSE AGREEMENT

full, unfettered access to the facilities of the Author or of the Author's institution as necessary to make the Video, whether actually published or not. JoVE has sole discretion as to the method of making and publishing the Materials, including, without limitation, to all decisions regarding editing, lighting, filming, timing of publication, if any, length, quality, content and the like.

11. **Indemnification.** The Author agrees to indemnify JoVE and/or its successors and assigns from and against any and all claims, costs, and expenses, including attorney's fees, arising out of any breach of any warranty or other representations contained herein. The Author further agrees to indemnify and hold harmless JoVE from and against any and all claims, costs, and expenses, including attorney's fees, resulting from the breach by the Author of any representation or warranty contained herein or from allegations or instances of violation of intellectual property rights, damage to the Author's or the Author's institution's facilities, fraud, libel, defamation, research, equipment, experiments, property damage, personal injury, violations of institutional, laboratory, hospital, ethical, human and animal treatment, privacy or other rules, regulations, laws, procedures or guidelines, liabilities and other losses or damages related in any way to the submission of work to JoVE, making of videos by JoVE, or publication in JoVE or elsewhere by JoVE. The Author shall be responsible for, and shall hold JoVE harmless from, damages caused by lack of sterilization, lack of cleanliness or by contamination due to the making of a video by JoVE its employees, agents or independent contractors. All sterilization, cleanliness or decontamination procedures shall be solely the responsibility of the Author and shall be undertaken at the Author's

expense. All indemnifications provided herein shall include JoVE's attorney's fees and costs related to said losses or damages. Such indemnification and holding harmless shall include such losses or damages incurred by, or in connection with, acts or omissions of JoVE, its employees, agents or independent contractors.

12. **Fees.** To cover the cost incurred for publication, JoVE must receive payment before production and publication the Materials. Payment is due in 21 days of invoice. Should the Materials not be published due to an editorial or production decision, these funds will be returned to the Author. Withdrawal by the Author of any submitted Materials after final peer review approval will result in a US\$1,200 fee to cover pre-production expenses incurred by JoVE. If payment is not received by the completion of filming, production and publication of the Materials will be suspended until payment is received.

13. **Transfer, Governing Law.** This Agreement may be assigned by JoVE and shall inure to the benefits of any of JoVE's successors and assignees. This Agreement shall be governed and construed by the internal laws of the Commonwealth of Massachusetts without giving effect to any conflict of law provision thereunder. This Agreement may be executed in counterparts, each of which shall be deemed an original, but all of which together shall be deemed to be one and the same agreement. A signed copy of this Agreement delivered by facsimile, e-mail or other means of electronic transmission shall be deemed to have the same legal effect as delivery of an original signed copy of this Agreement.

A signed copy of this document must be sent with all new submissions. Only one Agreement required per submission.

### CORRESPONDING AUTHOR:

Name: Seong Oh Park  
Department: Department of Plastic and Reconstructive Surgery  
Institution: Seoul National University College of Medicine  
Article Title: A simple angiographic method to examine fine vascular structure using Microfil  
Signature: 박성오 Date: 14/DEC/2017

Please submit a signed and dated copy of this license by one of the following three methods:

- 1) Upload a scanned copy of the document as a pdf on the JoVE submission site;
- 2) Fax the document to +1.866.381.2236;
- 3) Mail the document to JoVE / Attn: JoVE Editorial / 1 Alewife Center #200 / Cambridge, MA 02139

For questions, please email [submissions@jove.com](mailto:submissions@jove.com) or call +1.617.945.9051

Editorial comments:

The manuscript has been modified and the updated manuscript, 57732\_R1.docx, is attached and located in your Editorial Manager account. Please use the updated version to make your revisions.

1. Please take this opportunity to thoroughly proofread the manuscript to ensure that there are no spelling or grammar issues.
2. JoVE cannot publish manuscripts containing commercial language. This includes company names before an instrument or reagent. Please remove all commercial language from your manuscript and use generic terms instead. All commercial products should be sufficiently referenced in the Table of Materials and Reagents. Examples of commercial language in your manuscript include Microfil, etc.
3. Step 1.1: How to generate the change? Please explain in detail.  
→ The detailed procedure is described in Protocol 1.4. We changed "step 1.1" to "Note."
4. 1.3: How to shave?  
→ We have added more detailed information in Protocol 1.3.
5. 1.4.2: How to dissect? Using what? Please specify the accurate location. What's the size of the incision? How deep is it?  
→ We have added more detailed information in Protocol 1.4.
6. 2.1: Please write this step in imperative tense.  
→ We have revised the sentence according to your advice.
7. 2.2: Please write this step in imperative tense.  
→ We have revised it according to your advice.

8. 3.2: How to expose the common carotid artery? Please explain in detail the surgery procedure.

→ We have added detailed information about the procedure with reference.

9. 4.1: Please write this step in imperative tense.

→ We have revised the sentences.

10. 6.1: How deep is the incision? What is used to make the incision?

→ We have added detailed information about the procedure.

11. 6.2: How to dissect? How to harvest? Please add more details.

→ We have added detailed information about the procedure.

12. 7.3: How to develop the film? What is the film?

→ The method used for developing the film in this study is similar to that used generally. In the past, films were developed manually; however, automatic developing machines have been introduced and are used.

13. Step 8: For steps that are done using software, a step-wise description of software usage must be included in the step. Please mention what button is clicked on in the software, or which menu items need to be selected to perform the step.

→ We have added detailed information about the procedure.

14. Being a video based journal, JoVE authors must be very specific when it comes to the humane treatment of animals. Regarding animal treatment in the protocol, please add the following information to the text:

a) Please specify the anesthesia or euthanasia method.

→ We performed isoflurane inhalation anesthesia and have described this in

the protocol (Protocol 1.2 and 3.1).

b) Please mention how animals are anesthetized and how proper anesthetization is confirmed.

→ We performed isoflurane inhalation anesthesia and have described this in the protocol (Protocol 1.2 and 3.1).

c) Please specify the use of vet ointment on eyes to prevent dryness while under anesthesia.

→ We have mentioned this in Protocol 1.3 and 3.2

d) For survival strategies, discuss post-surgical treatment of animal, including recovery conditions and treatment for post-surgical pain.

→ We have mentioned this in Protocol 1.4.8.

e) Discuss maintenance of sterile conditions during survival surgery.

→ We have mentioned this information in Protocol 1.3. and 3.2.

f) Please specify that the animal is not left unattended until it has regained sufficient consciousness to maintain sternal recumbency.

→ We have mentioned this in Protocol 1.4.9.

g) Please specify that the animal that has undergone surgery is not returned to the company of other animals until fully recovered.

→ We have mentioned this in Protocol 1.4.9.

15. After you make all changes, if the protocol steps are over 3 pages, please highlight less than 2.75 pages of protocol steps in yellow for filming. Please do not highlight any steps describing euthanasia or anesthesia.

→ We have marked it.



16. Figure 1: Please add a short description of the figure in addition to the figure title.

→ We have added a short description in the figure legend.