

Journal of Visualized Experiments

Case Series of Successful Abdominal Closure Utilizing Novel Technique Combining Mechanical Closure System with Biologic Xenograft --Manuscript Draft--

Article Type:	Invited Methods Article - JoVE Produced Video
Manuscript Number:	JoVE57154R4
Full Title:	Case Series of Successful Abdominal Closure Utilizing Novel Technique Combining Mechanical Closure System with Biologic Xenograft
Keywords:	abdominal, surgery, xenograft
Corresponding Author:	Yana Puckett Texas Technical University Health Sciences Center Lubbock, Tx UNITED STATES
Corresponding Author's Institution:	Texas Technical University Health Sciences Center
Corresponding Author E-Mail:	yana.puckett@ttuhsc.edu
First Author:	Yana Puckett
Other Authors:	Michelle Estrada Shirley McReynolds Catherine A Ronaghan Virginia Tran
Author Comments:	
Additional Information:	
Question	Response
If this article needs to be "in-press" by a certain date, please indicate the date below and explain in your cover letter.	

TITLE:

A Case Series of Successful Abdominal Closure Utilizing a Novel Technique Combining a Mechanical Closure System with a Biologic Xenograft that Accelerates Wound Healing

AUTHORS & AFFILIATIONS:

Yana Puckett¹, MD, MPH, MBA, MSc; Virginia Tran, MD¹; Michelle Estrada¹, MD; Shirley McReynolds, RN¹; Catherine A. Ronaghan¹, MD, FACS

¹*Department of Surgery, Texas Tech University Health Sciences Center, TX, USA*

yana.puckett@ttuhsc.edu

Virginia.tran@ttuhsc.edu

michelle.estrada@ttuhsc.edu

shirley.mcreeynolds@ttuhsc.edu

catherine.ronaghan@ttuhsc.edu

CORRESPONDING AUTHOR:

Yana Puckett, MD, MPH, MBA, MSc

Tel: (678)-643-5289

KEYWORDS:

ABRA, abdominal wall closure, biologic xenograft, abdominal compartment syndrome, open abdomen

SUMMARY:

Closure of catastrophic open abdominal wounds presents a challenge to the surgeon. We present a surgical technique utilizing a combination of mechanical and biologic xenograft closure systems in closing complex open abdominal wounds. This technique offers another option to the surgeon for definitive fascial closure and accelerated wound healing.

ABSTRACT:

In the acute setting, once intra-abdominal injuries have been addressed, the next great hurdle is restoring a functional and intact abdominal compartment. The short and long-term consequences of living with a chronically open abdominal compartment include pulmonary, musculoskeletal, gastrointestinal, and emotional disability. The closure of catastrophic open abdominal wounds presents a challenge to the surgeon. We present a technique utilizing a mechanical abdominal closure device in conjunction with biologic xenograft in closing complex open abdominal wounds. This technique offers another option for definitive fascial closure and accelerated wound healing in this difficult patient population. The dynamic tissue system (DTS) is installed after control of original intraabdominal pathology. A porcine urinary bladder matrix is then placed in the subcutaneous space once fascial closure is achieved. Overall, primary myofascial closure was achieved in 100% of patients at a mean of 9.36 days.

INTRODUCTION:

The increasing prevalence of abdominal compartment syndrome has led to an emergence of various temporary abdominal closure (TAC) techniques¹. TAC is performed to prevent evisceration, assist in the removal of unwanted intraperitoneal fluid, minimize intra-abdominal complications, and expedite the closure of the abdominal cavity². Closure of an open abdomen facilitates restoration of normal physiology in the patient³. Prolonged duration of an open abdomen results in complications such as fistula formation and an inability to close the abdomen⁴. There are several methods to achieve final closure of an open abdomen.

The simplest way to temporarily close an abdomen is by using towel clips to close the skin⁵. One of the most commonly used and studied abdominal closure techniques is negative pressure wound therapy (NPWT)⁵. For the NPWT, a nonadherent barrier to protect the intraabdominal contents is applied followed by a moisture-absorbing sponge-like material, and an outermost adhesive layer to secure the dressing in place, and a negative pressure mechanism⁶. A Bogota bag can also be used for temporary closure of an open abdomen. A Bogota bag is an empty intravenous fluid bag cut in half and sutured to the skin edges⁷. NPWT and the Bogota bag closure are two temporizing measures that facilitate delayed primary closure of the abdominal cavity⁷.

Once the abdomen is deemed ready for closure, different closure methods can be utilized. The simplest way is to apply a split-thickness graft over the omentum once it has formed healthy granulation tissue. If the wound is not contaminated, a nonabsorbable synthetic sheet may be used to bridge the fascial edges⁸. If the fascial gap is less than 14-20 cm in maximal diameter, component separation of the rectus sheath can be performed⁹.

Some abdominal closure techniques allow for gradual reapproximation of the fascial edges and eventual primary closure¹⁰. A Wittmann patch consists of two opposing Velcro sheets that are sutured to each fascial edge¹¹. The opposing sheets are then fastened together in the midline. This mechanism allows easy re-entry into the abdomen and adjustment for abdominal compartment pressures. Additionally, this can also provide midline traction on the fascial edges that can prevent retraction of the fascial edges and also facilitate primary closure of the fascia.

Alternatively, a dynamic tissue system (DTS) is available and is part of the technique described in this paper. The described DTS is composed of a silicone viscera protector that is applied over abdominal contents to prevent adhesions and adherence of viscera to the abdominal wall. Adjustable elastomers then penetrate the full abdominal wall thickness on each side and provide medial tension on the wound edges (**Figure 1**). A product composed of urinary porcine bladder extracellular matrix can be placed in the subcutaneous space once fascial closure is achieved (**Figure 2**). Matrix placement in the subcutaneous space augments and expedites wound healing through angiogenesis, innervation, modulation of the inflammatory response, and resistance to infection¹².

In this study, we describe a novel technique of primary abdominal closure following abdominal compartment syndrome utilizing a dynamic closure system and a biologic xenograft. At our level I trauma and acute care center, abdominal compartment syndrome is a common

diagnosis. Prior to utilization of this novel method, most catastrophic open abdomens were not amenable to primary closure and a skin graft was placed over the viscera or biologic mesh. Since the adoption of this method in May of 2016, we have closed 100% of open abdomens due to abdominal compartment syndrome in a high-risk patient population (average BMI 40.45, SD 9.83) (Table 1).

PROTOCOL:

Institutional approval was obtained. Participants and/or their surrogate medical decision maker signed consent, allowing pictures and inclusion of non-identifying patient information for educational purposes.

1. Installation of Dynamic Tissue System

1.1. Bring the patient to the operating room and induce general anesthesia. Drape and prepare the patient for the procedure according to hospital policy.

1.1.1. Exclude if there is hemodynamic instability, a need for further abdominal washouts, or a concern for intra-abdominal sepsis.

1.2. Apply antimicrobial incise drape to the skin of the abdomen widely, covering the operating field.

1.3. Wash the abdomen out with at least 2 L of 40.5 °C normal saline.

1.4. Measure and record the myofascial gap, visceral extrusion, and length of incision in centimeters for documentation of progress on the operative note.

1.5. Examine the ostomy site prior to application of the device.

1.6. Mark the skin of the anterior abdominal wall 5 cm laterally from medial fascial edge to create an ellipse around the midline wound.

1.7. Use the puncture device included in the dynamic tissue system kit to puncture through the abdominal wall at the 5 cm mark, taking care not to injure the abdominal viscera. Use the “yellow fish” visceral protector included in the kit in addition to the malleable protector.

1.8. Place the elastomer buttons side by side on the ellipse created in step 1.6 with the “U” of the elastomer at the 5 cm ellipse demarcation around the midline wound.

1.9. Pull the elastomer through the abdominal wall using the puncture device.

1.10. Repeat the same steps on the opposite side. This time, pull the elastomer across abdominal wall over the visceral protector and connect to the elastomer button on the

opposite side.

1.11. Loosely attach the elastomer bands to the elastomer buttons. Do not tighten elastomer bands.

1.12. Place elastomer adhesion stickers on the buttons.

1.13. Perform the osteopathic maneuver twice. This is performed with two people standing on either side of the patient. Apply bi-manual forces at the skin level, pushing towards the midline and creating circular motions synchronized with the other operator first towards the head and then creating circular motions in the opposite directions towards the feet.

2. Silicone Visceral Protector Inserted

2.1. Insert silicone visceral protector midline over abdominal viscera, taking care to protect any ostomies (**Figure 3**).

2.2. Envelop the abdominal viscera with silicone visceral protector down to each gutter of abdominal quadrants.

2.3. Create necessary cut outs in the visceral protector with scissors to protect the ostomies.

2.4. Fold the cut outs to avoid sharp edges next to the ostomy.

2.5. Place elastomer retainer in the midline on top of visceral protector and evenly space elastomer bands into the retainer.

2.6. Tighten elastomer bands.

2.7. Perform the osteopathic maneuver.

2.8. Record the myofascial gap with a ruler in centimeters (**Figure 4**).

3. Installation of Negative Pressure Wound Therapy Device

3.1. Make negative pressure wound therapy device sponge as thin as possible and place in the midline above the elastomer retainer (**Figure 5**).

3.2. Cover with vacuum drape tape and apply the negative pressure device with continuous suction at -100 mmHg.

3.3. Perform the osteopathic maneuver twice.

3.4. Record myofascial gap and visceral extrusion (**Figure 6**).

Note: The midline wound is left in the negative pressure wound therapy device.

4. Elastomer Adjustment

4.1. Bring the patient back to the operating room 48 hours after the initial installation of the DTS for elastomer adjustment.

4.2. Remove the negative pressure wound therapy device overlying the midline wound with scissors, taking care to leave the drapes on the skin intact.

4.3. Prep the abdomen widely including the elastomers in place with 4% chlorhexidine gluconate.

4.4. Perform osteopathic maneuvers twice. See step 1.13 for details.

4.5. Record the myofascial gap and the myofascial apposition (**Figure 6**).

4.6. Irrigate the midline wound with 2 L of 40.5 °C normal saline, taking care not to spill water on the DTS or antimicrobial incision drape.

4.7. Adjust elastomers by releasing the elastomer from the anchor and pulling each elastomer laterally, away from the midline.

4.8. Reapply the negative pressure wound therapy device.

5. Fascial Closure

5.1. Bring the patient back to the operating room.

5.2. Remove all of the elastomer buttons and elastomers.

5.3. Gently peel the antimicrobial incise drape off the skin, taking care not to injure the epidermis.

5.4. Remove the visceral protector and elastomer retainer and irrigate the abdominal cavity with 3 L of normal saline.

5.5. Close the fascia in an interrupted Smead-Jones fashion with No. 2 vicryl suture on a cutting needle.

5.6. Irrigate and dry the midline wound.

5.7. Apply wound matrix powder to the midline wound and evenly distribute the powder so

that every surface is covered with the powder.

5.8. Apply two-layer wound matrix sheet on top of the powder to cover the entire surface of midline wound (**Figure 7**).

5.9. Bring the midline wound together with vacuum drape tape (**Figure 8**).

REPRESENTATIVE RESULTS:

We have analyzed a total of 11 patients so far with catastrophic open abdomens. Primary myofascial closure was achieved at a mean of 9.36 days. We had 0% surgical site infections (SSI) and achieved 100% primary myofascial closure. No enteroatmospheric fistula resulted in this technique, unless present prior to this DTS and xenograft approach. Since May 2016, zero open abdomens were left open or covered with a skin graft (**Figure 9**).

The results of this study show that the use of mechanical closure device system with urinary bladder matrix achieved closure in 100% of the patients with catastrophic abdomens. The system provides dynamic, and therefore more physiologic, appositional traction from the fascial layer up to the skin using elastomers. A recent meta-analysis that included 251 studies and 13,650 patients showed that negative pressure wound therapy with continuous fascial traction (with either mesh or tension sutures) had the highest weighted rate of definitive fascial closure of 76% in 26 series¹²⁻¹⁴. The weighted definitive fascial closure rates were 75% with the Wittman patch (8 series), 73% with the dynamic retention sutures (5 series), 54% with negative pressure wound therapy alone (106 series), 50% with loose packing (25 series), 25% with zipper (14 series), 39% with mesh (43 series), and 37% with Bogota bag (24 series)¹².

Although our institution did not close septic patients with this technique, an 18-patient study evaluating the use of the DTS system in closing open abdomen in septic patients showed successful closure in 88% of the studied patients¹⁴. The mean number of days the DTS stayed in place until closure in the aforementioned studies ranged from 10 to 48 days¹²⁻¹⁵.

Our study only included 11 patients, three of whom had ostomies in place. Our technique achieved 100% closure rate with an average of 9.36 days from DTS application to fascial closure. The use of a xenograft matrix allowed closure of the cutaneous wound after fascial closure despite our study population having an average BMI of 40. The results of our study conclude that the use of the dynamic tissue system achieves excellent results in definitive closure of open abdomen.

Table 1. Review of 11 patients that underwent novel dynamic tissue system closure with biologic xenograft placement to midline wound at a single trauma I center.

Table 2: Reasons for open abdomens and abdominal compartment syndromes at our level I trauma center.

Figure 1: Dynamic Tissue System (DTS).

Figure 2. Urinary bladder extracellular matrix comes in wound sheet and wound powder. The powder and sheet are combined together to accelerate and expedite wound healing.

Figure 3: Abdominal visceral protector is in place, the elastomer holes have been made with puncture device, and then elastomer bands pulled through on each side. Hemostats are placed on elastomers to avoid pull through the abdominal wall. Note the abdominal wall markings of an ellipse. The elastomer bands are gathered loosely at midline ready to place an elastomer retainer.

Figure 4: The elastomer retainer is placed in midline above visceral protector. Elastomer bands are then placed in the elastomer retainer. Myofascial gap is then recorded.

Figure 5: Negative pressure wound therapy device is applied and connected to suction.

Figure 6: Elastomers are adjusted in 48 hours after initial DTS installation and myofascial gap is measured and recorded.

Figure 7. Fascia is closed and wound matrix powder and sheet is laid in midline.

Figure 8. Midline wound is brought together with vacuum drape tape that has been cut into 2 inch strips across abdominal wall. Ostomy appliance is then applied.

Figure 9. Same patient that survived severe necrotizing pancreatitis with abdominal compartment syndrome is shown above at her six weeks clinic follow-up appointment. Midline wound is completely healed. Fascia is intact and no hernia is palpable. Her fascia was closed after 10 days of having an open abdomen.

DISCUSSION:

The most critical step of the protocol for closing a complex abdominal wound is performing osteopathic maneuvers before elastomer placement, after elastomer placement, and before and after elastomer adjustments. In addition, we perform osteopathic maneuvers on these patients after surgery three times a day. Our approach describes the use of the osteopathic maneuver prior and after the elastomers tightening. The anecdotal observation has been that these maneuvers aid in fascial approximation. Although we did not record the fascial edges prior and after the osteopathic maneuvers, we do feel that this step is crucial. There are no studies available at the time of this paper on the benefit of osteopathic maneuvers and fascial approximation. A study using a mathematical model found that tangential and compressive forces on the skin are transmitted to the fascial layer¹⁵. This force allows approximation of the fascia.

Another critical step of the protocol is to adjust the elastomer only to twice its length and never to push the abdomen to close sooner than required. At times when abdominal closure was extremely difficult, we paralyzed patients in the intensive care unit with rocuronium and

sedatives to keep intraabdominal pressure low. The average time length of paralysis was 3.4 days.

The use of incision tape is a modification of our technique that keeps the surgical site clean and free of infection. This is one of the key reasons our surgical site infection rate was 0% in a patient population at high risk of surgical site infections.

At the present moment, we have not found any limitations to the technique. One limitation that may occur is the cost of dynamic closure system (USD\$5500) and porcine urinary bladder matrix (USD\$1000 per sheet, USD\$1000 per powder bottle). In addition, frequent take backs of patients to the operating room for adjustments and prolonged time in the intensive care unit stay for paralysis add on costs. However, a cost analysis needs to be performed into the quality of life post closure. In addition, our rate of hernia is 0%. Operation on recurrence of hernia, possibility of bowel obstruction, and the return to hospital may need to be factored into cost savings of our protocol.

Future applications of this technique include closure of extremity wounds, fasciotomy wounds, and large traumatic wounds. Future studies need to include cost-analysis of this technique.

ACKNOWLEDGMENTS:

The authors have no acknowledgements.

DISCLOSURES:

Dr. Catherine Ronaghan is an ACell cadaver lab proctor and speaker. The rest of the authors have nothing to disclose.

REFERENCES:

1. Kirkpatrick, A.W., *et al.* Update from the Abdominal Compartment Society (WSACS) on intra-abdominal hypertension and abdominal compartment syndrome: past, present, and future beyond Banff 2017. *Anaesthesiology Intensive Therapy*. **49** (2), 83-87, doi:10.5603/AIT.a2017.0019 (2017).
2. Yetisir, F., Sarer, A.E., Acar, H.Z. & Aygar, M. Delayed Closure of 61 Open Abdomen Patients Based on an Algorithm. *Indian Journal of Surgery*. **79** (1), 38-44, doi:10.1007/s12262-015-1422-5 (2017).
3. Ribeiro Junior, M.A., *et al.* Open abdomen in gastrointestinal surgery: Which technique is the best for temporary closure during damage control? *World Journal of Gastrointestinal Surgery*. **8** (8), 590-597, doi:10.4240/wjgs.v8.i8.590 (2016).
4. Karakose, O., *et al.* Bogota Bag Use in Planned Re-Laparotomies. *Medical Science Monitor*. **22**, 2900-2904 (2016).
5. Lassalle, S., Chechin, C. & de la Forge, D. A new cleansing technique for complex wounds. *Soins*. **62** (814), 12-15 (2017).
6. Strang, S.G., Van Lieshout, E.M., Van Waes, O.J. & Verhofstad, M.H. Prevalence and mortality of abdominal compartment syndrome in severely injured patients: A systematic review. *The*

- Journal of Trauma and Acute Care Surgery*. **81** (3), 585-592, doi:10.1097/TA.0000000000001133 (2016).
7. Bressan, A.K. & Ball, C.G. Intra-abdominal hypertension and abdominal compartment syndrome in acute pancreatitis, hepato-pancreato-biliary operations and liver transplantation. *Anesthesiology Intensive Therapy*. **49** (2), 159-166, doi:10.5603/AIT.a2017.0024 (2017).
8. Muresan, M., *et al*. How much does decompressive laparotomy reduce the mortality rate in primary abdominal compartment syndrome?: A single-center prospective study on 66 patients. *Medicine (Baltimore)*. **96** (5), e6006, doi:10.1097/MD.0000000000006006 (2017).
9. Coccolini, F., *et al*. IROA: International Register of Open Abdomen, preliminary results. *World Journal of Emergency Surgery*. **12**, 8, eCollection 2017, doi:10.1186/s13017-017-0123-8 (2017).
10. Lecheminant, J. & Field, C. Porcine urinary bladder matrix: a retrospective study and establishment of protocol. *Journal of Wound Care*. **21** (10), 80, 482, doi:10.12968/jowc.2012.21.10.476 (2012).
11. Coccolini, F., *et al*. IROA: International Register of Open Abdomen, preliminary results. *World Journal of Emergency Surgery*. **12**, 8, eCollection 2017, doi:10.1186/s13017-017-0123-8 (2017).
12. Muturi, A., Ndaguatha, P., Ojuka, D. & Kibet, A. Prevalence and predictors of intra-abdominal hypertension and compartment syndrome in surgical patients in critical care units at Kenyatta National Hospital. *BMC Emergency Medicine*. **17** (1), y, doi:10.1186/s12873-017-0120-y (2017).
13. Okullo, A., *et al*. The Abdominal Reapproximation Anchor Device. *Surgical Innovation*. **24** (1), 49-54, doi:10.1177/1553350616671640 (2017).
14. Yetisir, F., Sarer, A.E., Acar, H.Z. & Aygar, M. Delayed Closure of 61 Open Abdomen Patients Based on an Algorithm. *Indian Journal of Surgery*. **79** (1), 38-44, doi:10.1007/s12262-015-1422-5 (2017).
15. Chaudhry, H., Bukiet, B., Zhiming J., Stecco, A. & Findley T. Deformations experienced in the human skin, adipose tissue, and fascia in osteopathic manipulative medicine. *The Journal of the American Osteopathic Association*. **114** (1), 780-7, doi:10.7556/jaoa.2014.152 (2017).

Figure 1

[Click here to download Figure 1.jpg](#)

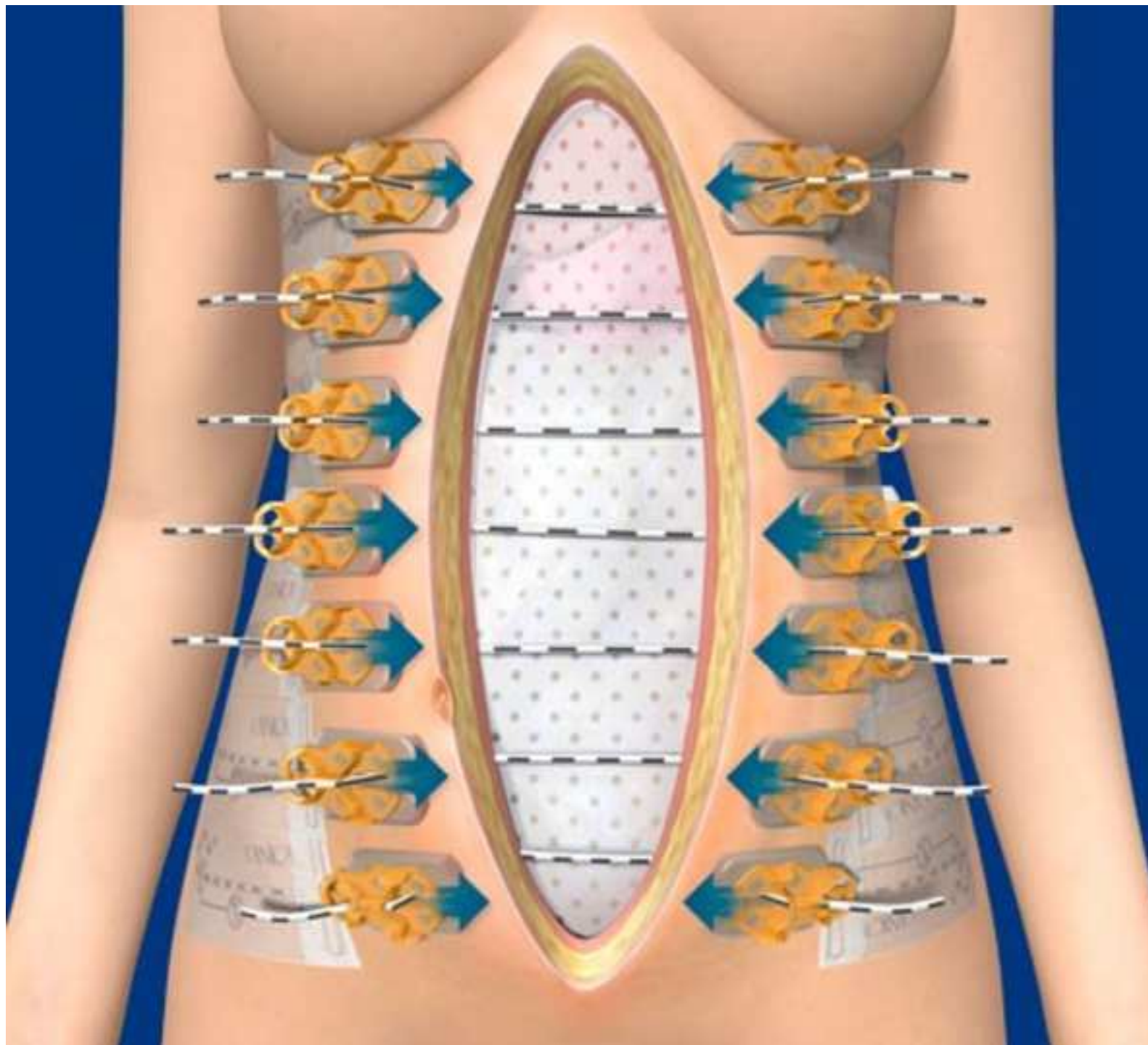




Figure 3

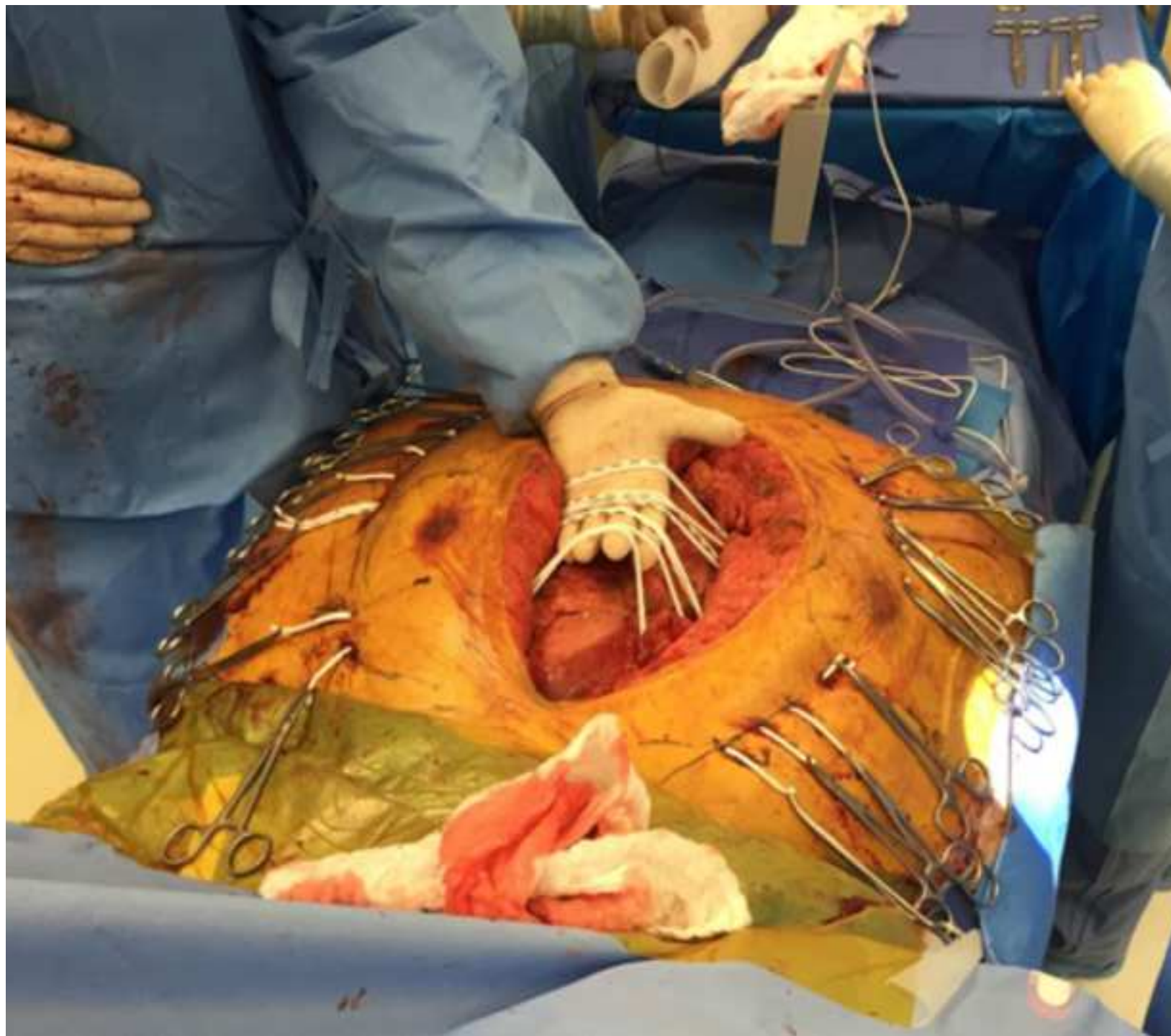


Figure 4

[Click here to download Figure 4.png](#)

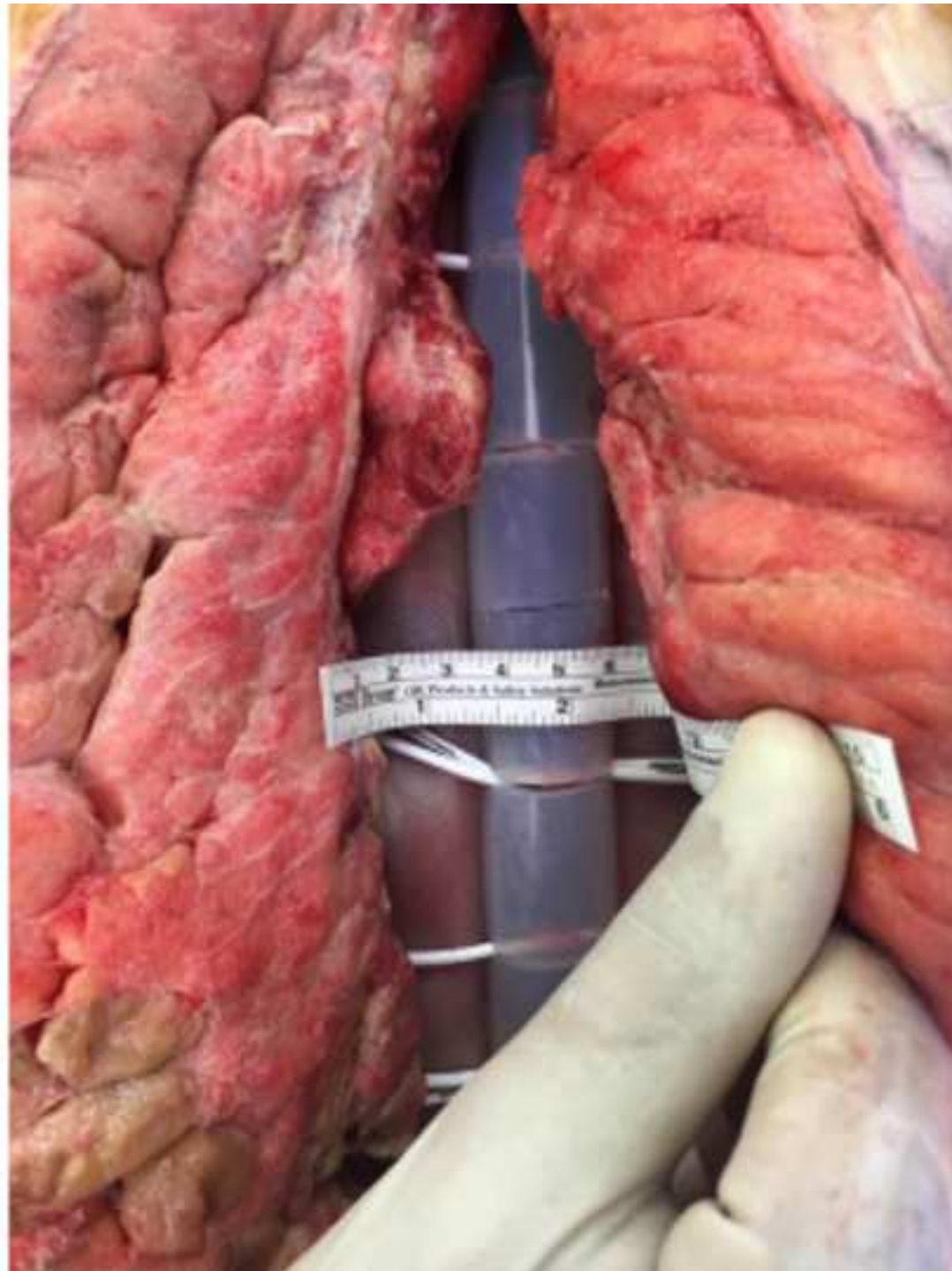


Figure 5

[Click here to download Figure 5.jpg](#)

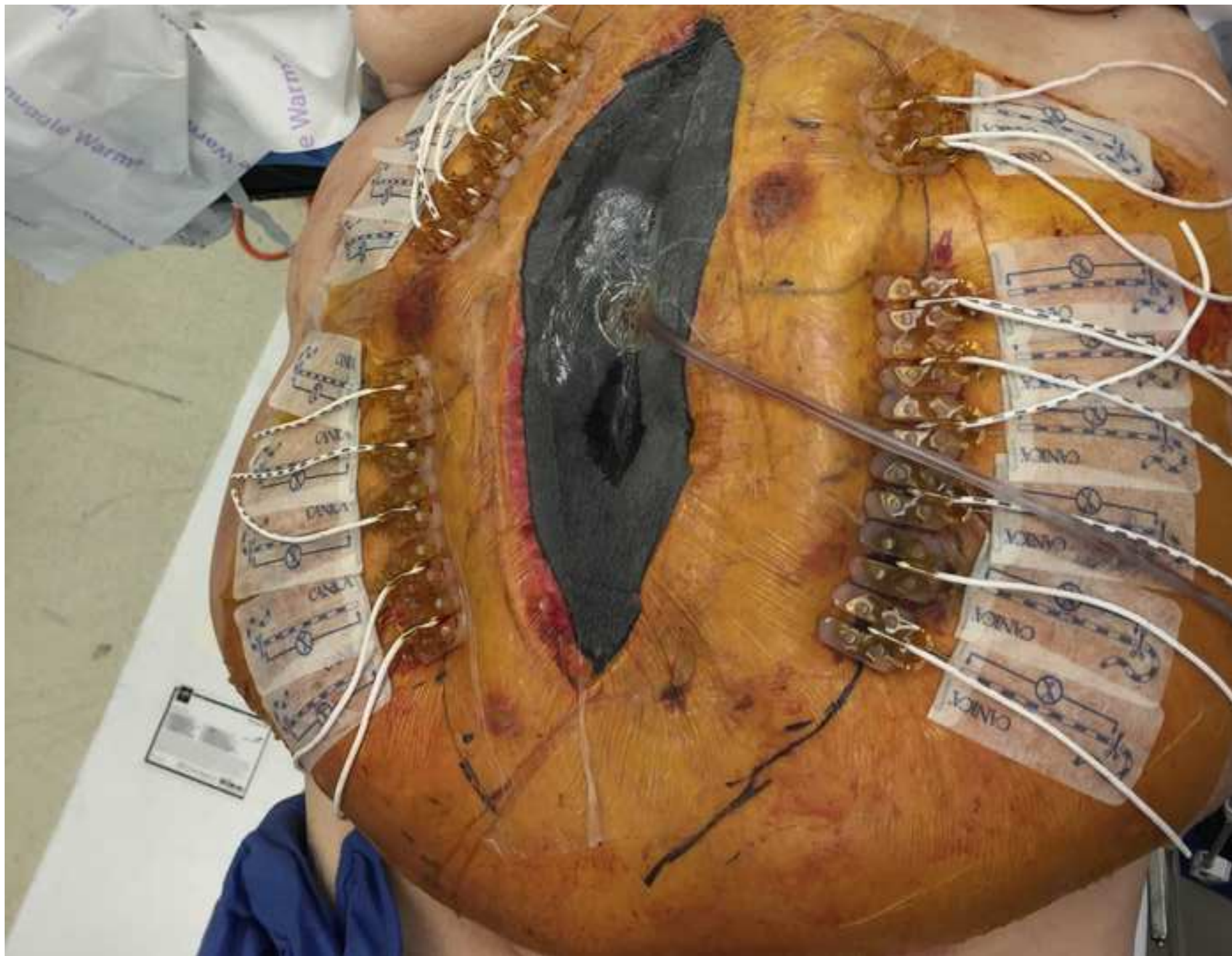


Figure 6

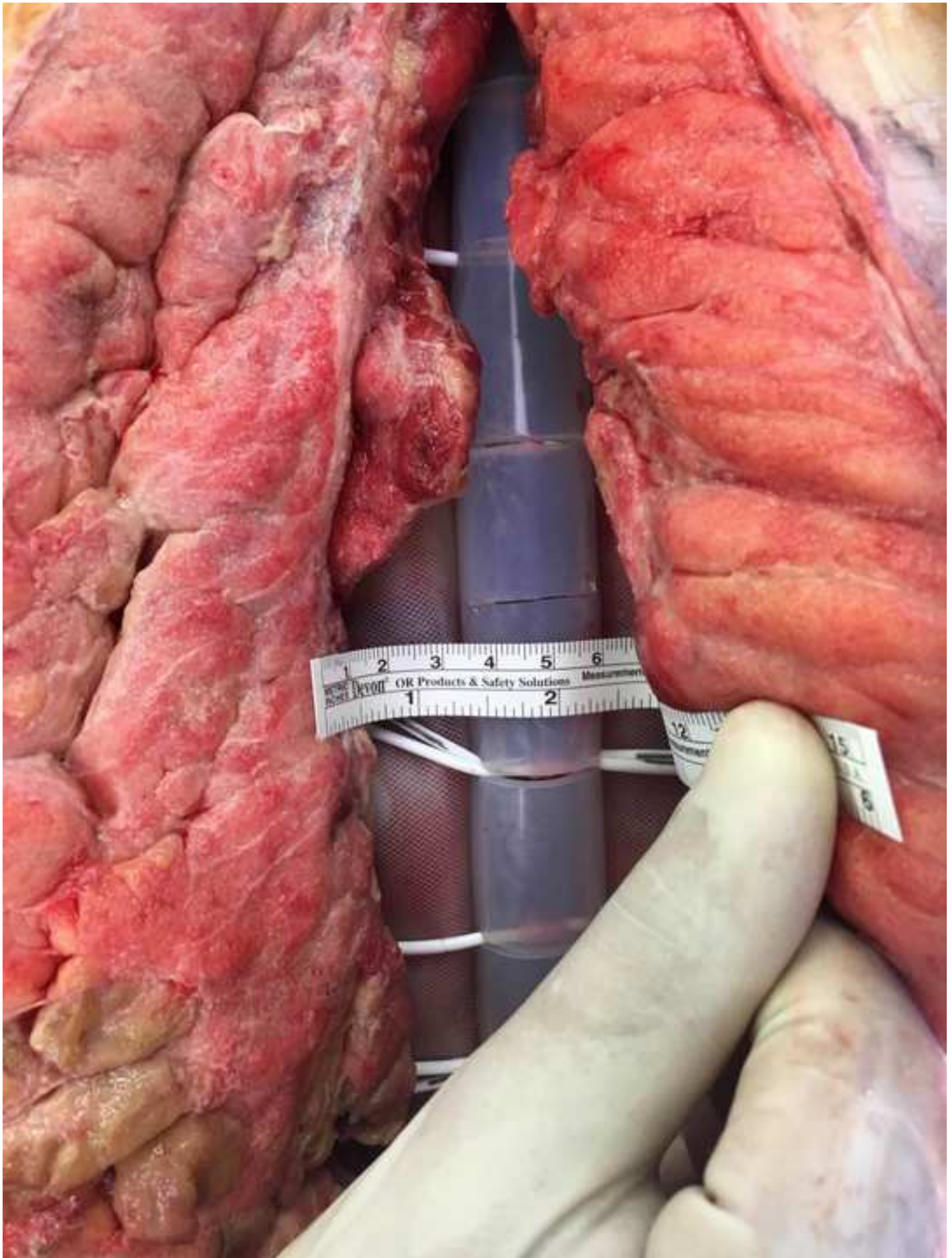


Figure 7

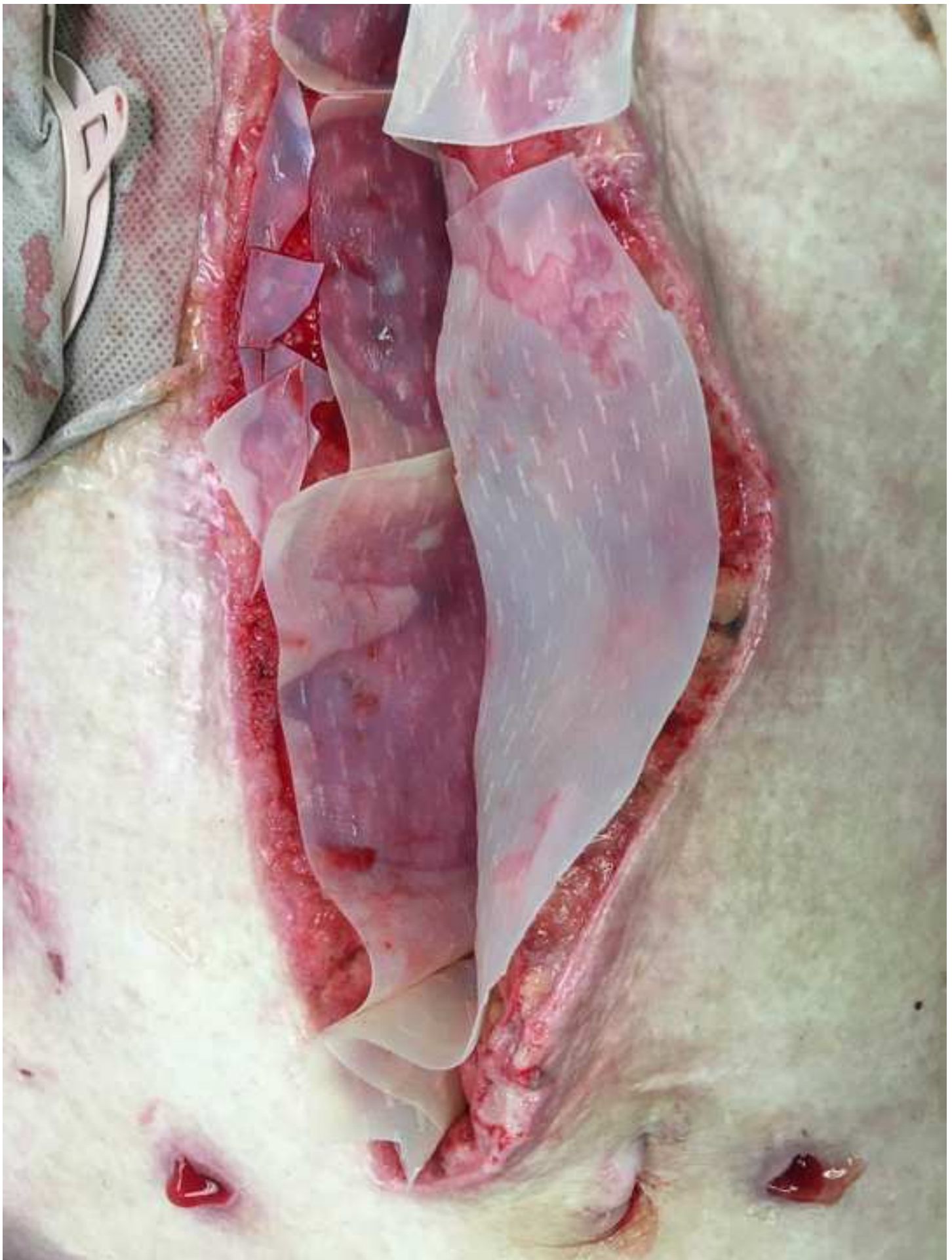


Figure 8

[Click here to download Figure 8.jpg](#)

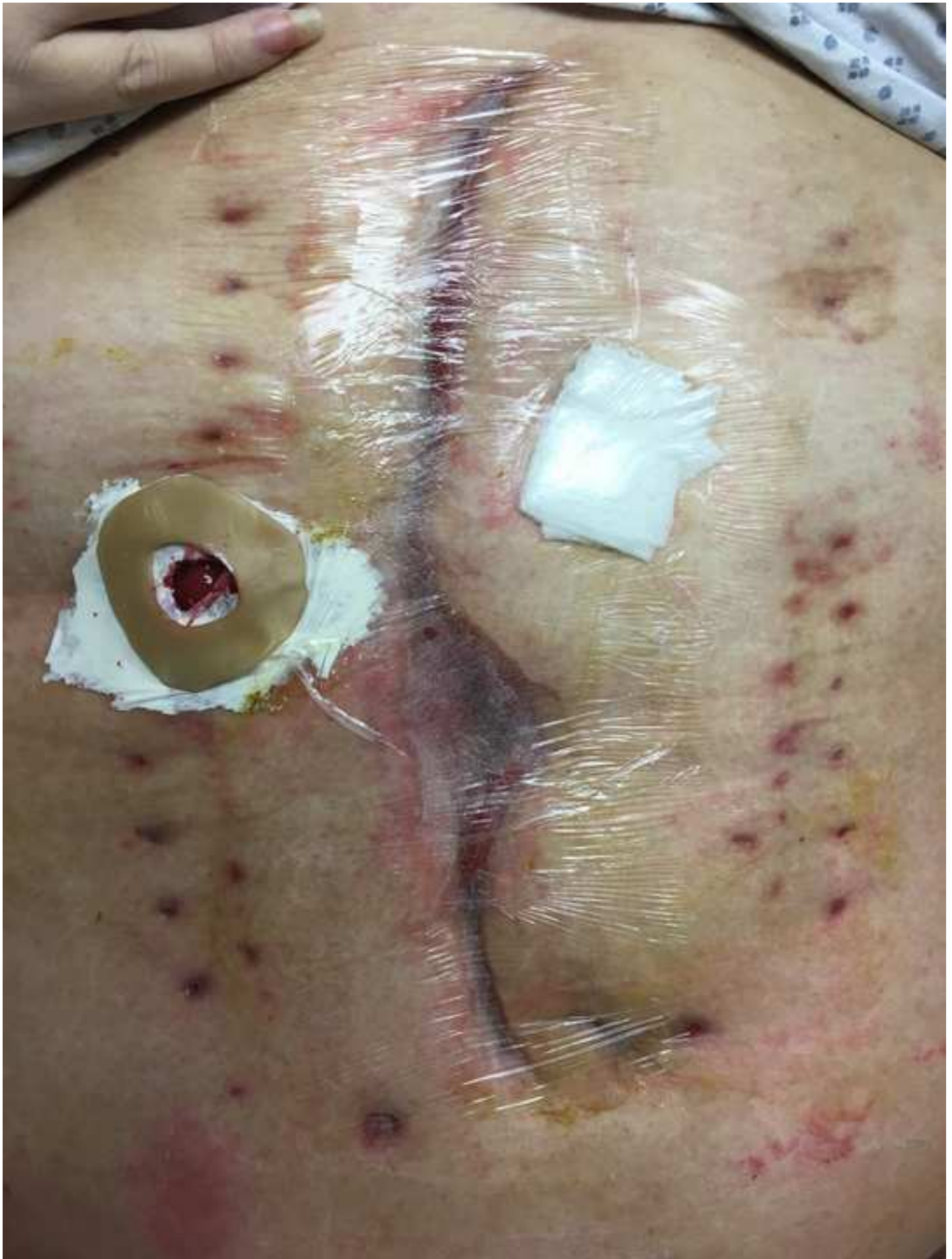
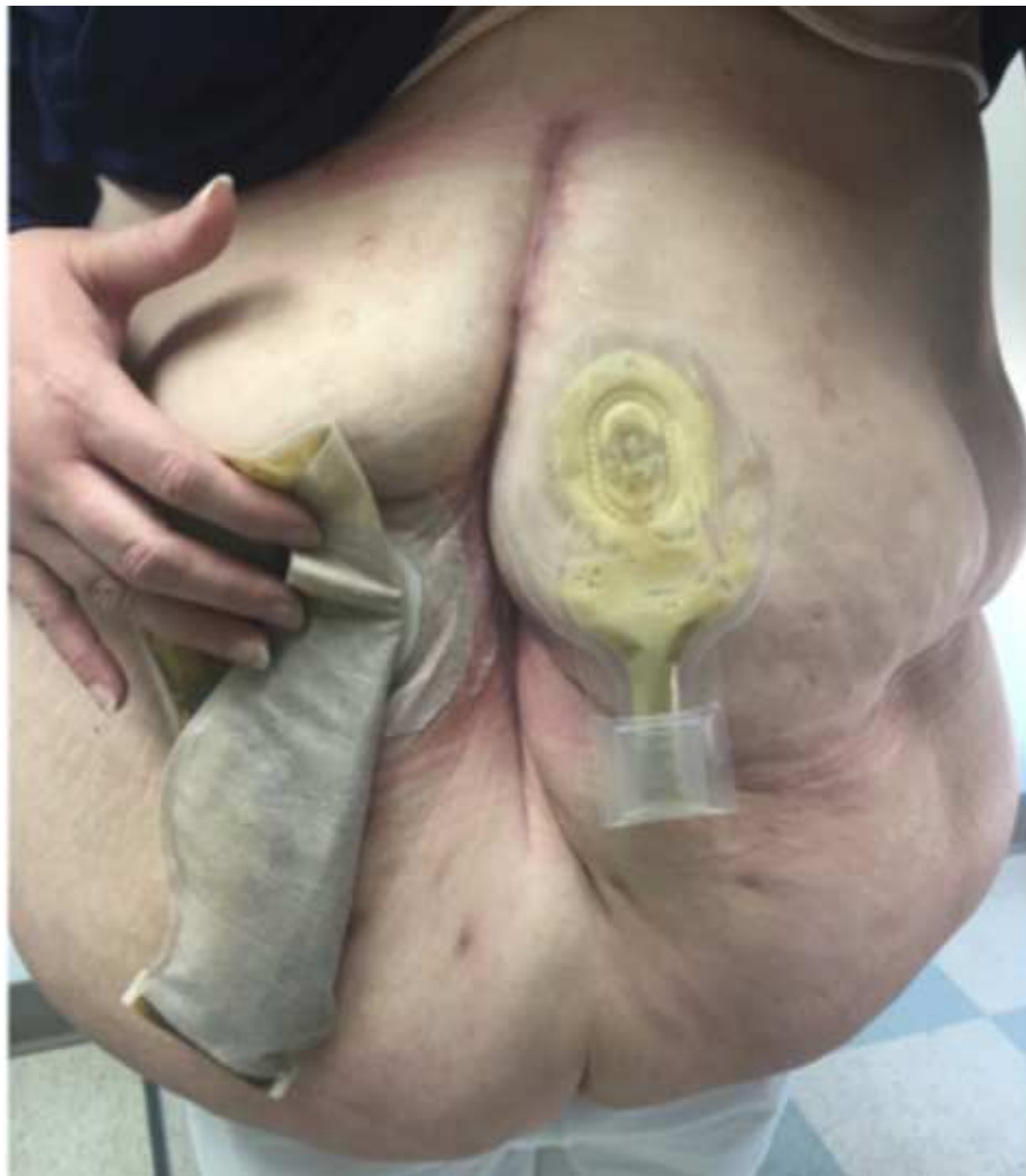
Figure 9



	Mean	Standard Deviation
Age (years)	48.11	10.03
BMI (kg/m ²)	40.45	9.83
Visceral Extrusion (cm)	6.8	1.57
Incision Length (cm)	26.55	10.13
Days to Closure of Fascia	9.36	4.18
Adjustments of DTS Prior to Closure (Days)	1.82	0.98
Days Abdomen Open Before DTS Application	8	9
Myofascial Gap Before DTS Application (cm)	18	6
Myofascial gap after DTS Application (cm)	9.06	2.04

Reasons for Open Abdomens at Our Institution	
1.	<i>Obstructing rectal cancer with gangrenous colon</i>
2.	<i>Exploratory laparotomy x2, Aortic dissection status post thoracic endovascular aortic repair, open gastrostomy, splenectomy, colectomy</i>
3.	<i>Severe Acute Hemorrhagic Pancreatitis with Colopancreatic Fistula</i>
4.	<i>Auto versus pedestrian, abdominal compartment syndrome, splenic Laceration, acetabular fracture, bladder injury with suprapubic cystostomy</i>
5.	<i>Incisional hernia, Crohn's disease, small bowel obstruction</i>
6.	<i>Enteroatmospheric fistula, skin grafted open abdomen after prostatectomy</i>
7.	<i>Motor vehicle crash, splenectomy, paraplegia from cervical spine Injury, small bowel obstruction, gastrojejunostomy, partial Abdominal Closure, pulmonary Embolus</i>
8.	<i>Abdominal compartment syndrome (due to excessive crystalloid resuscitation and delay in definitive management of massive upper gastrointestinal hemorrhage)</i>
9.	<i>Incisional hernia with loss of domain and obstructing jejunal adenocarcinoma</i>
10.	<i>Diverticulitis, attempted Hartmann's reversal, massive venous hemorrhage</i>

Name of Material/ Equipment	Company
ABRA Abdominal Wall Closure Set	Southmedic
3M Ioban 2 Antimicrobial Incise Drape	3M
MicroMatrix Micronized Particles 200 mg	AcELL
Cytal Wound Matrix 2-Layer 10 x 15 cm	AcELL
ABThera Open Abdomen Negative Pressure Therapy System	KCI

Catalog Number**Comments/Description**

CWK08 Abdominal

6651EZ

MM0200

WSM1015

09-03-193.ABT.IE



1 Alewife Center #200
 Cambridge, MA 02140
 tel. 617.945.9051
www.jove.com

ARTICLE AND VIDEO LICENSE AGREEMENT

Title of Article:

Case Series of Successful Abdominal Closure Utilizing Novel Technique Combining Mechanical Closure System with Biologic Xenograft

Author(s):

Yana Puckett¹, MD, MPH, MBA, MSc; Michelle Estrada¹, MD; Shriley McReynolds, RN¹; Catherine A. Ronaghan¹, MD; FACS

Item 1 (check one box): The Author elects to have the Materials be made available (as described at

<http://www.jove.com/author>) via: ☒ Standard Access ☐ Open Access

Item 2 (check one box):

- ☒ The Author is NOT a United States government employee.
- ☐ The Author is a United States government employee and the Materials were prepared in the course of his or her duties as a United States government employee.
- ☐ The Author is a United States government employee but the Materials were NOT prepared in the course of his or her duties as a United States government employee.

ARTICLE AND VIDEO LICENSE AGREEMENT

1. Defined Terms. As used in this Article and Video License Agreement, the following terms shall have the following meanings: “**Agreement**” means this Article and Video License Agreement; “**Article**” means the article specified on the last page of this Agreement, including any associated materials such as texts, figures, tables, artwork, abstracts, or summaries contained therein; “**Author**” means the author who is a signatory to this Agreement; “**Collective Work**” means a work, such as a periodical issue, anthology or encyclopedia, in which the Materials in their entirety in unmodified form, along with a number of other contributions, constituting separate and independent works in themselves, are assembled into a collective whole; “**CRC License**” means the Creative Commons Attribution-Non Commercial-No Derivs 3.0 Unported Agreement, the terms and conditions of which can be found at: <http://creativecommons.org/licenses/by-nc-nd/3.0/legalcode>; “**Derivative Work**” means a work based upon the Materials or upon the Materials and other pre-existing works, such as a translation, musical arrangement, dramatization, fictionalization, motion picture version, sound recording, art reproduction, abridgment, condensation, or any other form in which the Materials may be recast, transformed, or adapted; “**Institution**” means the institution, listed on the last page of this Agreement, by which the Author was employed at the time of the creation of the Materials; “**JoVE**” means MyJoVE Corporation, a Massachusetts corporation and the publisher of *The Journal of Visualized Experiments*; “**Materials**” means the Article and / or the Video; “**Parties**” means the Author and JoVE; “**Video**” means any video(s) made by the Author, alone or in conjunction with any other parties, or by JoVE or its affiliates or agents, individually or in collaboration with the Author or any other parties, incorporating all or any portion of the Article, and in which the Author may or may not appear.

2. Background. The Author, who is the author of the Article, in order to ensure the dissemination and protection of the Article, desires to have the JoVE publish the Article and create and transmit videos based on the Article. In furtherance of such goals, the Parties desire to memorialize in this Agreement the respective rights of each Party in and to the Article and the Video.

3. Grant of Rights in Article. In consideration of JoVE agreeing to publish the Article, the Author hereby grants to JoVE, subject to **Sections 4** and **7** below, the exclusive, royalty-free, perpetual (for the full term of copyright in the Article, including any extensions thereto) license (a) to publish, reproduce, distribute, display and store the Article in all forms, formats and media whether now known or hereafter developed (including without limitation in print, digital and electronic form) throughout the world, (b) to translate the Article into other languages, create adaptations, summaries or extracts of the Article or other Derivative Works (including, without limitation, the Video) or Collective Works based on all or any portion of the Article and exercise all of the rights set forth in (a) above in such translations, adaptations, summaries, extracts, Derivative Works or Collective Works and (c) to license others to do any or all of the above. The foregoing rights may be exercised in all media and formats, whether now known or hereafter devised, and include the right to make such modifications as are technically necessary to exercise the rights in other media and formats. If the “Open Access” box has been checked in **Item 1** above, JoVE and the Author hereby grant to the public all such rights in the Article as provided in, but subject to all limitations and requirements set forth in, the CRC License.

ARTICLE AND VIDEO LICENSE AGREEMENT

4. Retention of Rights in Article. Notwithstanding the exclusive license granted to JoVE in **Section 3** above, the Author shall, with respect to the Article, retain the non-exclusive right to use all or part of the Article for the non-commercial purpose of giving lectures, presentations or teaching classes, and to post a copy of the Article on the Institution's website or the Author's personal website, in each case provided that a link to the Article on the JoVE website is provided and notice of JoVE's copyright in the Article is included. All non-copyright intellectual property rights in and to the Article, such as patent rights, shall remain with the Author.

5. Grant of Rights in Video – Standard Access. This **Section 5** applies if the "Standard Access" box has been checked in **Item 1** above or if no box has been checked in **Item 1** above. In consideration of JoVE agreeing to produce, display or otherwise assist with the Video, the Author hereby acknowledges and agrees that, Subject to **Section 7** below, JoVE is and shall be the sole and exclusive owner of all rights of any nature, including, without limitation, all copyrights, in and to the Video. To the extent that, by law, the Author is deemed, now or at any time in the future, to have any rights of any nature in or to the Video, the Author hereby disclaims all such rights and transfers all such rights to JoVE.

6. Grant of Rights in Video – Open Access. This **Section 6** applies only if the "Open Access" box has been checked in **Item 1** above. In consideration of JoVE agreeing to produce, display or otherwise assist with the Video, the Author hereby grants to JoVE, subject to **Section 7** below, the exclusive, royalty-free, perpetual (for the full term of copyright in the Article, including any extensions thereto) license (a) to publish, reproduce, distribute, display and store the Video in all forms, formats and media whether now known or hereafter developed (including without limitation in print, digital and electronic form) throughout the world, (b) to translate the Video into other languages, create adaptations, summaries or extracts of the Video or other Derivative Works or Collective Works based on all or any portion of the Video and exercise all of the rights set forth in (a) above in such translations, adaptations, summaries, extracts, Derivative Works or Collective Works and (c) to license others to do any or all of the above. The foregoing rights may be exercised in all media and formats, whether now known or hereafter devised, and include the right to make such modifications as are technically necessary to exercise the rights in other media and formats. For any Video to which this Section 6 is applicable, JoVE and the Author hereby grant to the public all such rights in the Video as provided in, but subject to all limitations and requirements set forth in, the CRC License.

7. Government Employees. If the Author is a United States government employee and the Article was prepared in the course of his or her duties as a United States government employee, as indicated in **Item 2** above, and any of the licenses or grants granted by the Author hereunder exceed the scope of the 17 U.S.C. 403, then the rights granted hereunder shall be limited to the maximum rights permitted under such

statute. In such case, all provisions contained herein that are not in conflict with such statute shall remain in full force and effect, and all provisions contained herein that do so conflict shall be deemed to be amended so as to provide to JoVE the maximum rights permissible within such statute.

8. Likeness, Privacy, Personality. The Author hereby grants JoVE the right to use the Author's name, voice, likeness, picture, photograph, image, biography and performance in any way, commercial or otherwise, in connection with the Materials and the sale, promotion and distribution thereof. The Author hereby waives any and all rights he or she may have, relating to his or her appearance in the Video or otherwise relating to the Materials, under all applicable privacy, likeness, personality or similar laws.

9. Author Warranties. The Author represents and warrants that the Article is original, that it has not been published, that the copyright interest is owned by the Author (or, if more than one author is listed at the beginning of this Agreement, by such authors collectively) and has not been assigned, licensed, or otherwise transferred to any other party. The Author represents and warrants that the author(s) listed at the top of this Agreement are the only authors of the Materials. If more than one author is listed at the top of this Agreement and if any such author has not entered into a separate Article and Video License Agreement with JoVE relating to the Materials, the Author represents and warrants that the Author has been authorized by each of the other such authors to execute this Agreement on his or her behalf and to bind him or her with respect to the terms of this Agreement as if each of them had been a party hereto as an Author. The Author warrants that the use, reproduction, distribution, public or private performance or display, and/or modification of all or any portion of the Materials does not and will not violate, infringe and/or misappropriate the patent, trademark, intellectual property or other rights of any third party. The Author represents and warrants that it has and will continue to comply with all government, institutional and other regulations, including, without limitation all institutional, laboratory, hospital, ethical, human and animal treatment, privacy, and all other rules, regulations, laws, procedures or guidelines, applicable to the Materials, and that all research involving human and animal subjects has been approved by the Author's relevant institutional review board.

10. JoVE Discretion. If the Author requests the assistance of JoVE in producing the Video in the Author's facility, the Author shall ensure that the presence of JoVE employees, agents or independent contractors is in accordance with the relevant regulations of the Author's institution. If more than one author is listed at the beginning of this Agreement, JoVE may, in its sole discretion, elect not take any action with respect to the Article until such time as it has received complete, executed Article and Video License Agreements from each such author. JoVE reserves the right, in its absolute and sole discretion and without giving any reason therefore, to accept or decline any work submitted to JoVE. JoVE and its employees, agents and independent contractors shall have

ARTICLE AND VIDEO LICENSE AGREEMENT

full, unfettered access to the facilities of the Author or of the Author's institution as necessary to make the Video, whether actually published or not. JoVE has sole discretion as to the method of making and publishing the Materials, including, without limitation, to all decisions regarding editing, lighting, filming, timing of publication, if any, length, quality, content and the like.

11. **Indemnification.** The Author agrees to indemnify JoVE and/or its successors and assigns from and against any and all claims, costs, and expenses, including attorney's fees, arising out of any breach of any warranty or other representations contained herein. The Author further agrees to indemnify and hold harmless JoVE from and against any and all claims, costs, and expenses, including attorney's fees, resulting from the breach by the Author of any representation or warranty contained herein or from allegations or instances of violation of intellectual property rights, damage to the Author's or the Author's institution's facilities, fraud, libel, defamation, research, equipment, experiments, property damage, personal injury, violations of institutional, laboratory, hospital, ethical, human and animal treatment, privacy or other rules, regulations, laws, procedures or guidelines, liabilities and other losses or damages related in any way to the submission of work to JoVE, making of videos by JoVE, or publication in JoVE or elsewhere by JoVE. The Author shall be responsible for, and shall hold JoVE harmless from, damages caused by lack of sterilization, lack of cleanliness or by contamination due to the making of a video by JoVE its employees, agents or independent contractors. All sterilization, cleanliness or decontamination procedures shall be solely the responsibility of the Author and shall be undertaken at the Author's

expense. All indemnifications provided herein shall include JoVE's attorney's fees and costs related to said losses or damages. Such indemnification and holding harmless shall include such losses or damages incurred by, or in connection with, acts or omissions of JoVE, its employees, agents or independent contractors.

12. **Fees.** To cover the cost incurred for publication, JoVE must receive payment before production and publication the Materials. Payment is due in 21 days of invoice. Should the Materials not be published due to an editorial or production decision, these funds will be returned to the Author. Withdrawal by the Author of any submitted Materials after final peer review approval will result in a US\$1,200 fee to cover pre-production expenses incurred by JoVE. If payment is not received by the completion of filming, production and publication of the Materials will be suspended until payment is received.

13. **Transfer, Governing Law.** This Agreement may be assigned by JoVE and shall inure to the benefits of any of JoVE's successors and assignees. This Agreement shall be governed and construed by the internal laws of the Commonwealth of Massachusetts without giving effect to any conflict of law provision thereunder. This Agreement may be executed in counterparts, each of which shall be deemed an original, but all of which together shall be deemed to be one and the same agreement. A signed copy of this Agreement delivered by facsimile, e-mail or other means of electronic transmission shall be deemed to have the same legal effect as delivery of an original signed copy of this Agreement.

A signed copy of this document must be sent with all new submissions. Only one Agreement required per submission.

CORRESPONDING AUTHOR:

Name:	<input type="text" value="Yana Puckett"/>	
Department:	<input type="text" value="Surgery"/>	
Institution:	<input type="text" value="Texas Tech University Health Sciences Center"/>	
Article Title:	<input type="text" value="Case Series of Successful Abdominal Closure Utilizing Novel Technique Combining Mechanical Closure System with Biologic Xenograft"/>	
Signature:	<input type="text" value="Yana Puckett"/>	Date: <input type="text" value="08/14/2017"/>

Please submit a signed and dated copy of this license by one of the following three methods:

- 1) Upload a scanned copy of the document as a pdf on the JoVE submission site;
- 2) Fax the document to +1.866.381.2236;
- 3) Mail the document to JoVE / Attn: JoVE Editorial / 1 Alewife Center #200 / Cambridge, MA 02139

For questions, please email submissions@jove.com or call +1.617.945.9051

January 7, 2018

Nam Nguyen, Ph.D.
Manager of Review
JoVE

Dear Dr. Nguyen,

Thank you for the opportunity to revise our manuscript. We appreciate both reviewers for their time spent on reviewing our work and their insight. Reviewer comments are included below, with our response in italics.

Reviewers' comments:

Reviewer #1:

Manuscript Summary:

The authors introduced a novel and alternative technique of primary abdominal closure following ACS utilizing the ABRA abdominal system and a biologic xenograft, with a 100% closure rate with an average of 9.36 days from ABRA application to fascial closure.

Minor Concerns:

1. Besides SSIs, can this novel TAC technique decrease the rates of other complications, such as enteroatmospheric fistula?

Thank you for this comment. None of the 11 (10? On the "reasons for open abdomen" there are only 10 patients listed) patients in this cohort developed an enteroatmospheric fistula, hernia or surgical site infection. One of the major benefits of this technique is that it provided fascial closure within 9 days. Previous studies have shown that early fascial closure has significant improvement in survival in patients managed with open abdomens. Although our study is limited, the benefits of early fascial closure may be extrapolated from previous comparison studies.

Chen Y, Ye J, Song W, Chen J, Yuan Y, Ren J. Comparison of outcomes between early fascial closure and delayed abdominal closure in patients with open abdomen: a systematic review and meta-analysis. Gastroenterol Res Pract. 2014;2014:784056. vol. 2014, Article ID 784056, 8 pages, 2014. I added this reference just in case we wanted to add this to the manuscript because I think the 9 day closure is the benefit this approach

2. Is there any primary clinical data comparing the safety and efficacy of the novel TAC technique with other TAC techniques?

At this time, we have not collected data comparing our novel TAC with other TAC techniques. At our institution, a negative pressure wound therapy is used frequently. It is in fact used in conjunction with the described ABRA DTS and xenograft described here.

However, we do not have comparison of these two techniques at this time as separate TAC approaches.

Reviewer #2:

Manuscript Summary:

This is an interesting approach to abdominal wall reconstruction. I do not think using the progressive device to close the fascia is a novel idea, however the lack of skin closure is very concerning.

Major Concerns:

Using very expensive products and not taking cultures or closing the skin, allowing the skin to heal secondarily will lead to an unstable scar. There is no discussion for your cases that there was insufficient soft tissue to close the anterior abdominal wall. This does not make sense...There is a type in line 108, please address.

Thank you for this comment. We did not see the need to take cultures from the skin. Many of our patients (n = ?; I can't tell from the list how many) had an open abdomen because of abdominal sepsis. Most had started and/or finished a course of antibiotics prior to the application of the dynamic closure device. Because gross infection was not noted, we did not take culture from the skin.

In regards to the soft tissue defect, the measurements collected were of only the fascial defects. Although measurements were not made of the soft tissue defect, the biologic xenograft was used to accelerate secondary healing in the soft tissue defect.

Why does vac sponge need to be "as thin as possible" KCI has done tremendous research into the height of sponge and pore size, I did not see any rational for making the sponge thinner in your paper.

Thank you for this comment. You are indeed correct that the sponge does not need to be as thin as possible. We will consider leaving this step out in the future. (Not sure how to respond to this)

What is an osteopathic maneuver? How does that play a significant role in your project

The osteopathic maneuver is demonstrated in the video. Through tangential compression on the skin layer, the fascial layers are approximated. Although we did not measure the fascia distances before and after osteopathic maneuvers, we do believe it serves an important role. At the time of this paper, there are no studies available concerning fascial approximation and osteopathic maneuvers. However, a study using mathematical model found that tangential and compressive forces on the skin are transmitted to the fascial layer and in our experience this has helped approximate the fascial layers.

Chaudhry, H., Bukiet, B., Zhiming J., Stecco, A. & Findley T. Deformations experienced in the human skin, adipose tissue, and fascia in osteopathic manipulative medicine. J Am Osteopath Assoc. 114 (1), 780-7, doi: 10.7556/jaoa.2014.152 (Again, added this citation just in case we wanted to add it to the manuscript.)

What happens when water touches the device and why does the patient need to go back to the OR to change sponge if you are leaving silastic sheet in place, all of the tension devices can be tightened at the bedside. Are you all taking cultures to ensure that these wounds are not contaminated prior to closing?

We do not have experience on what happens when water touches the device.

The sponge is changed in the operating room to maintain sterility. Although this can be performed at the bedside, the utility of a full anesthesia staff and operating staff was useful in these critical patients.

No cultures are taken prior to abdominal closure. The abdomens were not grossly contaminated prior to closure, and patients were clinically stable without signs or symptoms of gross infection. If cultures came back positive, we would not have treated it because patients were otherwise stable and the culture would have been treated as a contamination.

Did you randomize closing with and without acell, this would add a lot more power to this study especially if you are going to let the skin heal secondarily... it might be helpful to also not use the vac in an acell patient, I anticipate that it would take some time to heal.

This is an excellent point. No we did not randomize closing with and without acell, this may be a project at our institution in the near future. It would provide with interesting comparison data.