

Journal of Visualized Experiments

The efficacy of a porcine collagen matrix in keratinized tissue augmentation: a 6 months follow-up study --Manuscript Draft--

Article Type:	Invited Methods Article - JoVE Produced Video
Manuscript Number:	JoVE57136R3
Full Title:	The efficacy of a porcine collagen matrix in keratinized tissue augmentation: a 6 months follow-up study
Keywords:	Peri implant tissue; Keratinized tissue; Soft tissue augmentation; Tissue grafting; Xenogeneic graft; Collagen matrix
Corresponding Author:	Luca Pivetti Ospedale Maggiore Policlinico Milan, Milan ITALY
Corresponding Author's Institution:	Ospedale Maggiore Policlinico
Corresponding Author E-Mail:	luca.pivetti.lp@gmail.com
First Author:	Carlo Maiorana
Other Authors:	Carlo Maiorana Fabrizio Signorino Giovanni Battista Grossi Mario Beretta Alan Scott Herford
Author Comments:	
Additional Information:	
Question	Response
If this article needs to be "in-press" by a certain date, please indicate the date below and explain in your cover letter.	

TITLE:

The Efficacy of a Porcine Collagen Matrix in Keratinized Tissue Augmentation: A 6-Month Follow-up Study

AUTHORS & AFFILIATIONS:

C. Maiorana¹, L. Pivetti¹, F. Signorino¹, G.B. Grossi¹, M. Beretta¹, A.S. Herford²

¹Implant Center for Edentulism and Jawbone Atrophies, Maxillofacial Surgery and Odontostomatology Unit, Fondazione IRCCS Cà Granda, Ospedale Maggiore Policlinico, Milan, Italy.

²Oral and Maxillofacial Surgery Department, Loma Linda University, Loma Linda, CA, USA

E-MAIL ADDRESSES:

C. Maiorana: carlo.maiorana@unimi.it

L. Pivetti: luca.pivetti.lp@gmail.com

F. Signorino: fabrizio.signorino@unimi.it

G.B. Grossi: giovanni.grossi@unimi.it

M. Beretta: mario.beretta@unimi.it

A.S. Herford: a.herford@llu.edu

CORRESPONDING AUTHOR:

Luca Pivetti

KEYWORDS:

Peri implant tissue, keratinized tissue, soft tissue augmentation, tissue grafting, xenogeneic graft, collagen matrix

SUMMARY:

The aim of this study was to evaluate the long-term stability of the results achieved in peri implant tissue grafting by means of a collagen matrix.

ABSTRACT:

When keratinized tissue width around dental implants is poorly represented, the clinician could resort to autogenous soft tissue grafting. Autogenous soft tissue grafting procedures are usually associated with a certain degree of morbidity. Collagen matrices could be used as an alternative to reduce morbidity and intra-operative times. The aim of this study was to evaluate the effectiveness of a xenogeneic collagen matrix when used as soft tissue grafting in the peri-implant area. Vestibuloplasty and keratinized tissue reconstruction around dental implants were performed in 15 patients using a porcine collagen matrix as the graft substitute. Then the obtained keratinized tissues were measured and evaluated after 6 months, 1 year, 4 years, and 5 years. The average gain of keratinized tissue was 5.7 mm. After 6 months, a resorption of 37% was observed. Secondary outcomes like hemostasis and morbidity were recorded as well. No complications were observed and minimal pain was reported in all the subjects. No bleeding or adverse reaction occurred in any patients. The present study suggests how the porcine collagen

matrix can be used in keratinized tissue augmentation, thus reducing morbidity and the need of a second surgical site with limited tissue availability.

INTRODUCTION:

The aim of the present research is to evaluate the efficacy in achieving keratinized tissue augmentation of a collagen matrix in a standard apically positioned flap (APF) procedure. Today, it is widely recognized that a sufficient amount of keratinized tissue is more than desirable around both teeth and dental implants: this type of tissue prevents gingival recession in association with the presence of plaque ¹.

A surgical technique based on an APF for vestibuloplasty associated with grafting materials (whether autologous or not) is considered the gold standard for soft tissue augmentation ². In the past few years collagen matrices have been studied as a valid substitute for free gingival grafts, in particular the porcine collagen matrix ^{3,4}.

The xenogeneic porcine collagen matrix used in this study is a class III medical device according to the Medical Device Directive 93/42 (EEC, European economic community, definitions: 1.1: long-term implant; 1.2: implantable; 8: resorbable and 17: porcine origin). It consists of a unique structure composed by two functional layers: a cell occlusive layer with a smooth surface made of collagen fibers in a compact texture, and an underlying porous face, specifically reconstituted from collagen fibers. The collagen is processed to favor immediate blood clot stabilization. This helps early vascularization phases^{5,6}, leading to a soft-tissue cell ingrowth⁵ and excellent integration of the 3D collagen matrix with surrounding tissues^{5,6}. Both the EU and US Food and Drug Administration cleared the product for regenerative therapy involving teeth and implants.

So far, a small number of studies have demonstrated that collagen matrices are reliable and comparable with free gingival grafts for keratinized tissue augmentation around both teeth or dental implants ^{7,9-11}. Additional advantages are a lower patient morbidity due to the absence of a donor site and the high aesthetic value, matching the texture and color of the adjacent mucosa ^{8,11,12}.

PROTOCOL:

The following protocol was approved by the institution's (Fondazione IRCCS Cà Granda) human research ethics committee

1. Patient Selection, Pre-Operative Instructions, and Preparation

1.1. Consider both male and female patients, older than 18 years old, with deficient keratinized mucosa < 2 mm surrounding one or more dental implants as valid candidates.

Note: Exclude the following: smokers or diabetic patients; patients with a history of tumor in the head or neck area and/or radiotherapy; immunodeficiency; Sjogren syndrome, patients

consuming bisphosphonates or drugs affecting the quality/quantity of soft and hard tissues in the oral cavity.

1.2. One week before surgery, send the patient's dental records to a dental laboratory to prepare a transparent acrylic stent that extends deep in the vestibule: this splint will be used after surgery.

1.3. Mount a 105 mm macro lens on a Digital Single-Lens Reflex (DSLR) camera. Set the digital camera as following: diaphragm aperture 32, International Organization of Standardization (ISO) 200, exposition 1/125. Take digital pictures of the area of interest using intraoral mirrors.

1.4. Instruct the patient to start mouth washes with 0.2% digluconate chlorhexidine twice a day, 1-day prior to surgery in order to disinfect the oral mucosa.

2. Surgery

2.1. Receiving site preparation

2.1.1. Infiltrate local anesthetic (articaine + adrenaline 1:100,000 in 1.8 mL cartridges, if no allergies are referred) with a syringe, equipped with a 30G 21 mm needle, in the area of interest.

2.1.2. With a surgical scalpel (No. 15C blade), perform a split thickness (deep enough to reach the periosteum) incision based on the length of the area in need of treatment.

Note: Make the incision in the residual keratinized mucosal band, in order to promote the invasion of keratinized epithelial cells in the collagen matrix; record the time.

2.1.3. With the same surgical scalpel (No. 15C blade), perform two release split thickness incisions (deep enough to reach the periosteum), mesial and distal to the first one.

2.1.4. Raise a split-thickness flap: while helping with surgical pliers and by using a #7 Goldman-Fox knife or a surgical scalpel (No. 15C blade), dissect the epidermal and connective tissue from the underlying periosteum.

2.1.5. With the same instruments, carefully dissect the muscle fibers and reduce them to the depth of the vestibule, to maintain results over time.

2.1.6. If present, remove fat tissue using a sharp surgical scissors to facilitate and achieve better healing.

2.1.7. Suture the split-thickness flap, by means of a 5/0 nylon suture and a Castroviejo needle-holder, to the surrounding mucosa and periosteum, with separate stitches.

2.1.8. Measure the length (between the two release incisions) and depth (to where the flap has been dissected apically) of the denuded area with a 15-mm North Carolina periodontal probe.

2.1.9. Take digital photographs (as in step 1.3).

2.2. Collagen matrix manipulation and application

2.2.1. Open the sterile box of collagen matrix.

2.2.2. With sharp surgical scissors, cut and shape the collagen matrix based on the measurements of the denuded area.

2.2.3. Apply the collagen matrix: the porous layer has to be in contact with the underlying periosteum, while the smooth surface will face the vestibule.

2.2.4. Suture the matrix with 5/0 nylon sutures to the surrounding tissue, being careful to have the coronal and apical portion of the matrix in contact with keratinized tissue; record the time (**Figure 1**).

2.2.5. Evaluate the post-operative bleeding and hemostatic effect of the matrix. To evaluate bleeding, monitor the wound for 10 min and observe if any bleeding develops; if not bleeding, the matrix has an excellent hemostatic effect.

2.2.6. Take digital photographs (as in step 1.3).

2.3. Acrylic splint application (**Figure 2**)

2.3.1. Make sure that the acrylic splint extends to the depth of the newly created vestibule: this will prevent muscle fibers to relapse, thus losing the initial height gain. The splint must be in close contact with the vestibular fornix, exercising a gentle pressure on it (the mucosa must not be stretched).

2.3.2. Make sure, visually, that the splint is not in contact with the wound (the transparent material will help). The splint must not compress the collagen matrix, or poor healing could occur.

2.3.3. Take digital photographs (as in step 1.3).

2.3.4. Show the patient how to position the splint and how to remove it. To position the splint, a slight pressure will fix it to the surrounding teeth, while to remove it, simply apply force in the opposite direction. Instruct the patient to keep the splint in position for 10 days after surgery and to remove it for eating and cleaning.

2.3.5. Instruct the patient to irrigate with a 10-mL syringe, the area twice a day for 10 days with a 0.9% NaCl solution and 0.2% digluconate chlorhexidine.

3. Follow-up

3.1. Visit the patient after 3 days post-surgery (**Figure 3**).

3.2. Assess post-operative pain the Mankoski's pain scale¹³ using as a reference, and assess bleeding (ask the patient if any bleeding was noticed in the two days after surgery).

3.3. After 10 days, remove the sutures and instruct the patient to no longer wear the splint. (**Figure 4**).

Note: Some sutures can be left in place to better measure the grafted area (if needed).

3.4. Evaluate healing after 2 weeks. Evaluate the new epithelization of the grafted area. Remove all the remaining sutures (**Figure 5**).

3.5. 1-Month Follow-up: Assess healing by visual examination (**Figure 6**).

3.6. 2-Month Follow-up: Assess healing by visual examination. Healing should be complete in 100% of patients (**Figure 7**).

3.7. 6-Month Follow-up: Assess tissue and color integration. The tissue must be indistinguishable from the adjacent mucosa (**Figure 8**).

3.8. Take digital photographs at each step (from steps 3.2 to 3.7).

REPRESENTATIVE RESULTS:

3 male and 12 female patients participated in the study, with 4 surgeries in the maxilla and 11 in the mandible. Depending on the size of the receiving area, measurements were taken from 3 to 5 points mesial to distal. The matrix's average size was approximately 22 mm in length per 8 mm in height. The pre-operative keratinized tissue mean value was 4.1 mm, whilst the post-operative value was 9.4 mm, leading to an initial mean gain of 5.3 mm. 6 months after surgery, a mean loss of 2.2 mm, corresponding to 39.5% height reduction of the original gain, occurred with a final result of 7.3 mm (**Figure 9**).

After 1 month, healing was complete in 14 out of 15 patients. After 6 months, the new tissue appeared fully matured and indistinguishable from the surrounding tissue. All data were elaborated with the Analysis of Variance (ANOVA) repeated measurements method. Genetical pre-determination of keratinized tissue height was confirmed as it was assessed clinically that this value was never lower than the adjacent sites. According to the post-operative experience described by the patients, there was no bleeding, and the level of pain felt after surgery was

very low to no pain at all (only 2 patients took a mild analgesic).

FIGURE AND TABLE LEGENDS:

Figure 1. Collagen matrix placement in the soft tissues defect requiring keratinized gingiva augmentation. The matrix is designed and placed based on the defect area shape and extension. The collagen matrix is sutured to the surrounding tissues with 5/0 nylon stitches.

Figure 2. Acrylic splint in position after surgery. The acrylic splint is placed over and not in contact with the collagen matrix to improve the new vestibule expansion. It will be kept for 10 days, and only removed during eating and cleaning.

Figure 3. 3 days post-operative check. It is evident how the fibrin covers the entire graft.

Figure 4. 10 days post-operative check. Healing is proceeding, and epithelization is starting.

Figure 5. 14 days post-operative check. Few sutures are left in place to facilitate measurements, and epithelization is almost complete.

Figure 6. Photograph taken at 1 month after surgery. Healing is complete and keratinized tissue is present.

Figure 7. 2-Month follow-up check. A good quantity of fully matured keratinized tissue is visible.

Figure 8. 6-Month follow-up check. The reduction of keratinized tissue is evident, but the residual amount is more than desirable for the final prosthetic rehabilitation.

Figure 9. Graft shrinkage over time. It can be observed the 2.2 mm reduction of keratinized gingival in the 6-month period. Considering the original gain of 9.4 mm, the shrinkage showed a rate of 39.5%.

DISCUSSION:

The study's aim was to evaluate the efficacy of a xenogeneic collagen matrix, used as a soft tissue graft substitute in the reconstruction of an adequate amount (at least 2 mm) of keratinized peri-implant tissue. The main parameters taken into consideration were: shrinkage, re-epithelization, hemostatic effect, post-operative morbidity, and aesthetic outcome.

The outcome of the present study can be compared with the results of other papers found in literature reporting the use of non-autologous grafting in soft tissue reconstruction techniques. The protocol showed the efficacy of the collagen matrix in obtaining a new keratinized mucosa; however, it is important to focus on the critical steps of the technique: the manipulation phase and the suture phase. Despite the successful results, the device presented limits during the manipulation and designing due to its

reduced thickness. For the same reason, despite the new level recorded of the keratinized tissue (7.3 mm), a reduced thickness compared to the areas surrounding the defects was observed clinically.

The suture phase required a significant amount of the procedure time due to the difficult manipulation and the higher number of sutures needed to stabilize the device. Sutures were placed with extreme precision all around the device's perimeter, in order to improve the contact area with the vascular bed and reduce possible movement in the early phases. The multiple single sutures around the entire border, the placement of the acrylic stent, and the post-operative instruction improved both the stability of the matrix and the healing during the first days, which represent the most critical phase of the healing period.

Wei and Laurell, in 2001, in a clinical and a histological study performed on 12 patients, compared the increment of adherent mucosa in two groups: the first composed of 6 patients receiving an autologous graft while the second, an allogeneic one ^{14,15}. They observed an increment of adherent mucosa in both groups, but they noticed how the gain was very poor using the allogeneic graft. This was caused by an excessive shrinkage of the graft in the post-operative period. The histological analysis showed that a tissue very similar to scar tissue and incapable of inducing cellular differentiation, characterized all grafted sites.

Shrinkage and thickness are two of the most important parameters concerning soft tissue regenerative techniques. One of the most important issues when using the allogeneic material is the fast resorption ^{14,15}, which leads to a disturbed healing. As for the connective tissue graft, the epithelialization of the acellular matrices starts from the surrounding tissue proliferation. To gain keratinized tissue, it is necessary to put the borders of the graft in contact with the host's keratinized mucosa ¹⁶. Sanz *et al.* in 2009 confirmed the reliability of xenogeneic collagen matrices, which provided predictable and satisfactory results. They evaluated, using a porcine derived collagen matrix, the efficacy in gaining keratinized tissue in comparison with an autologous graft. After 6 months, the data collected in both groups were nearly the same, showing an insignificant statistical variance (60% shrinkage for the autologous and 67% for the xenogeneic material) ¹⁷. The similarity of the results between the porcine and autograft groups suggest how this technique is not only comparable to the gold standard technique, but is also capable of reducing morbidity and intra-operative times, and avoiding the need of a donor site. This represents a significant point compared to the classic, existing method. In the present paper similar data were collected, even if the absence of a control group represented a limitation of the study.

The results presented here can be considered satisfactory for the set endpoints, according to the other authors. In all the mentioned studies here, including the present study, one factor is particularly highlighted concerning the post-operative course: the great decrease in morbidity^{16,17}. The xenogeneic material is very easy to use and handle.

The average time of surgery is about 30 minutes (excluding anesthesia)¹⁷. Furthermore, all grafted sites showed, once the healing was completed, an optimal integration with the surrounding area, and a good aesthetic profile, as compared to previous studies^{8,12,17}.

The present study suggests how this type of collagen matrix can be used in patients needing a keratinized tissue augmentation surrounding dental implants, results in a great aesthetic outcome and causes very little pain. Future studies should focus on the thickness of the collagen matrices, its long-term stability, and its application in similar techniques in the intraoral district for keratinized augmentation.

ACKNOWLEDGMENTS:

The authors have no acknowledgments.

DISCLOSURES:

The authors have nothing to disclose.

REFERENCES:

1. Pranskunas M, Poskevicius L, Juodzbals G, Kubilius R, Jimbo R. Influence of Peri-Implant Soft Tissue Condition and Plaque Accumulation on Peri-Implantitis: a Systematic Review. *J Oral Maxillofac Res.* **9**, 7 (3) (2016).
2. Costello, B.J., Betts, N.J., Barber, H.D., Fonseca, R.J. Preprosthetic surgery for the edentulous patients. *Dent Clin North Am.* **40** (1), 19-38 (1996).
3. Dragan IF, Hotlzman LP, Karimbux NY, Morin RA, Bassir SH. Clinical Outcomes of Comparing Soft Tissue Alternatives to Free Gingival Graft: A Systematic Review and Meta-Analysis. *J Evid Based Dent Pract.* **17** (4), 370-380 (2017).
4. Bassetti RG, Stähli A, Bassetti MA, Sculean A. Soft tissue augmentation around osseointegrated and uncovered dental implants: a systematic review. *Clin Oral Investig.* **21** (1), 53-70 (2017).
5. Ghanaati, S., et al. Evaluation of the tissue reaction to a new bilayered collagen matrix in vivo and its translation to the clinic. *Biomed Mater.* **6** (1), 015010 (2011).
6. Rocchietta, I., Schupbach, P., Ghezzi, C., Maschera, E., Simion, M. Soft tissue integration of a porcine collagen membrane: an experimental study in pigs. *Int J Periodontics Restorative Dent.* **32** (1), e34-e40 (2012).
7. Vignoletti, F., et al. Healing of a xenogeneic collagen matrix for keratinized tissue augmentation. *Clin Oral Implants Res.* **26** (5), 545-52 (2015).
8. Nevins, M., Nevins, M.L., Kim, S.W., Schupbach, P., Kim, D.M. The use of mucograft collagen matrix to augment the zone of keratinized tissue around teeth: a pilot study. *Int J Periodontics Restorative Dent.* **31** (4), 367-73 (2011).
9. Vignoletti, F., et al. Clinical and histological healing of a new collagen matrix in combination with the coronally advanced flap for the treatment of Miller class-I recession defects: an experimental study in the minipig. *J Clin Periodontol.* **38** (9), 847-55 (2011).

10. Jepsen, K., *et al.* Treatment of gingival recession defects with a coronally advanced flap and a xenogeneic collagen matrix: a multicenter randomized clinical trial. *J Clin Periodontol.* **40** (1), 82-9 (2013).
11. Schmitt, C.M., *et al.* Vestibuloplasty: porcine collagen matrix versus free gingival graft: a clinical and histologic study. *J Periodontol.* **84** (7), 914-23 (2013).
12. Sanz, M., Lorenzo, R., Aranda, J.J., Martin, C., Orsini, M. Clinical evaluation of a new collagen matrix (Mucograft prototype) to enhance the width of keratinized tissue in patients with fixed prosthetic restorations: a randomized prospective clinical trial. *J Clin Periodontol.* **36** (10), 868-76 (2009).
13. Mankoski A. Mankoski Pain Scale, *copyright* 1995, 1996
14. Wei, P.C., Laurell, L., Geivelis, M., Lingen, M.W., Maddalozzo, D. Acellular dermal matrix allografts to achieve increased attached gingiva. Part 1. *J Periodontol.* **71** (8), 1297-305 (2000).
15. Wei, P.C., Laurell, L., Lingen, M.W., Geivelis, M. Acellular dermal matrix allografts to achieve increased attached gingiva. Part 2. A histological comparative study. *J Periodontol.* **73** (3), 257-65 (2002).
16. Imberman, M. Gingival augmentation with an acellular dermal matrix revisited: surgical technique for gingival grafting. *Pract Proced Aesthet Dent.* **19** (2), 123-8 (2007).
17. Schmitt, C.M., *et al.* Vestibuloplasty: porcine collagen matrix versus free gingival graft: a clinical and histologic study. *J Periodontol.* **84** (7), 914-23 (2013)

Figure 1

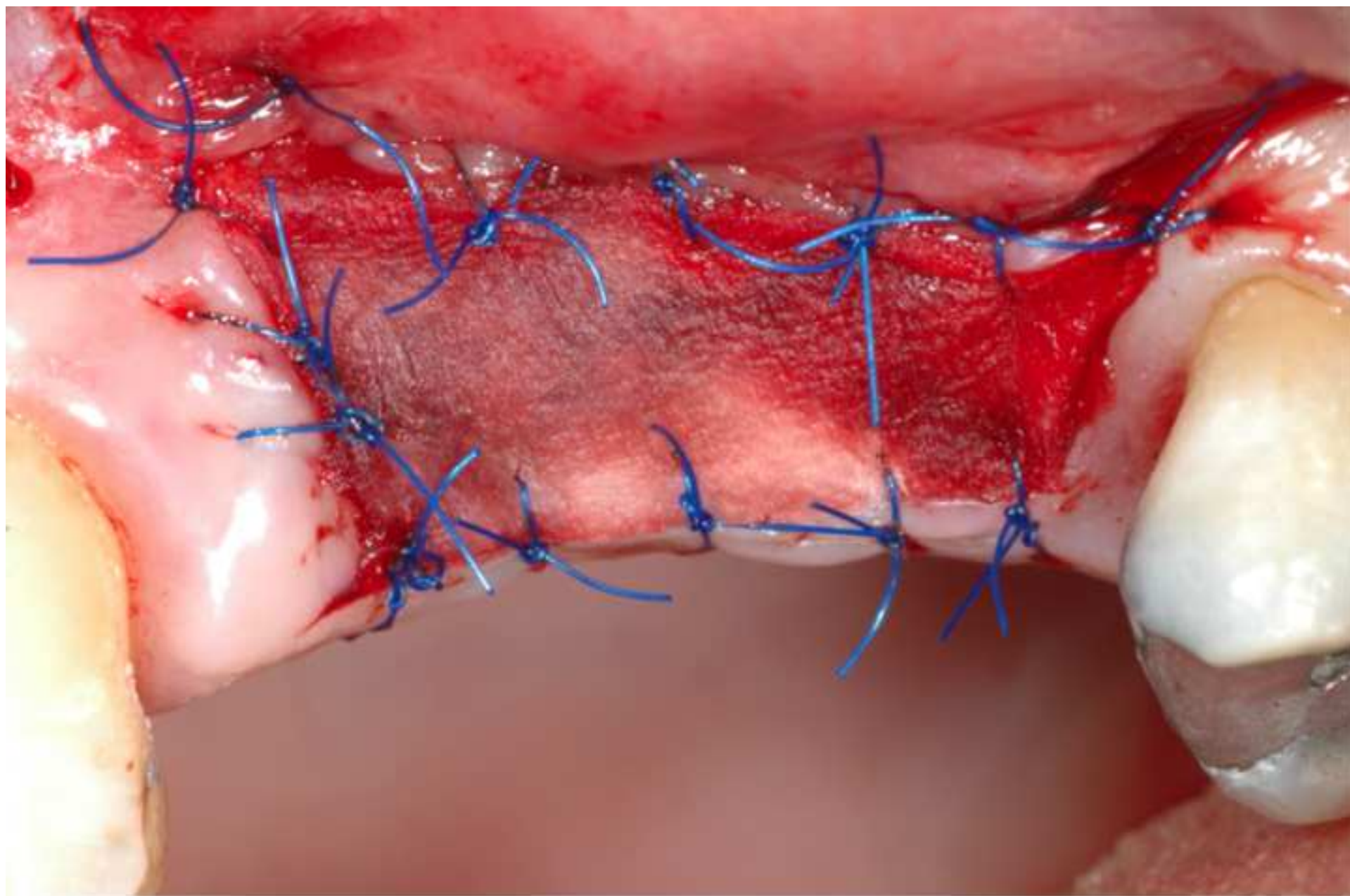


Figure 2

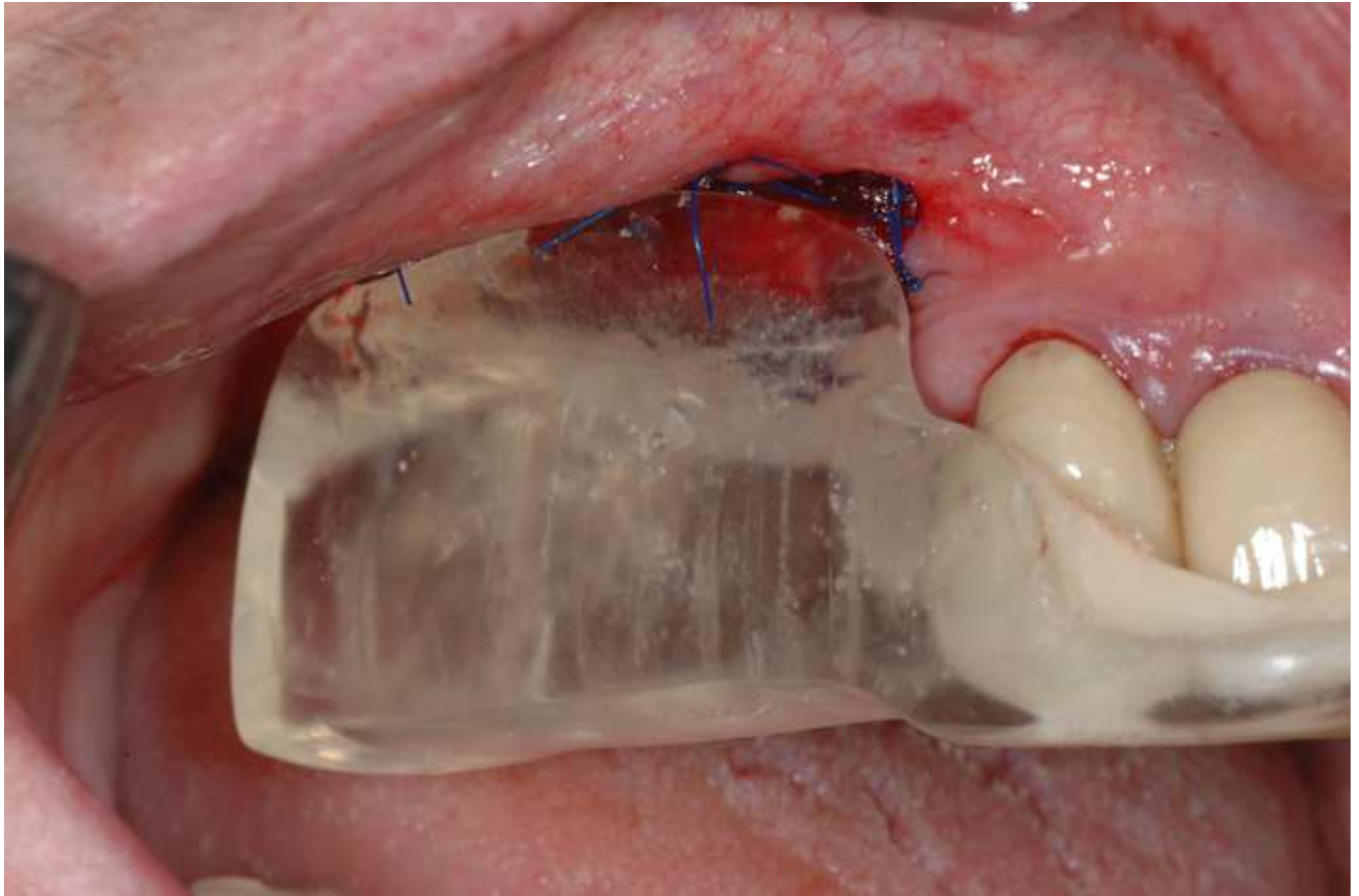

Figure 3

[Click here to download Figure fig. 3.tif](#)

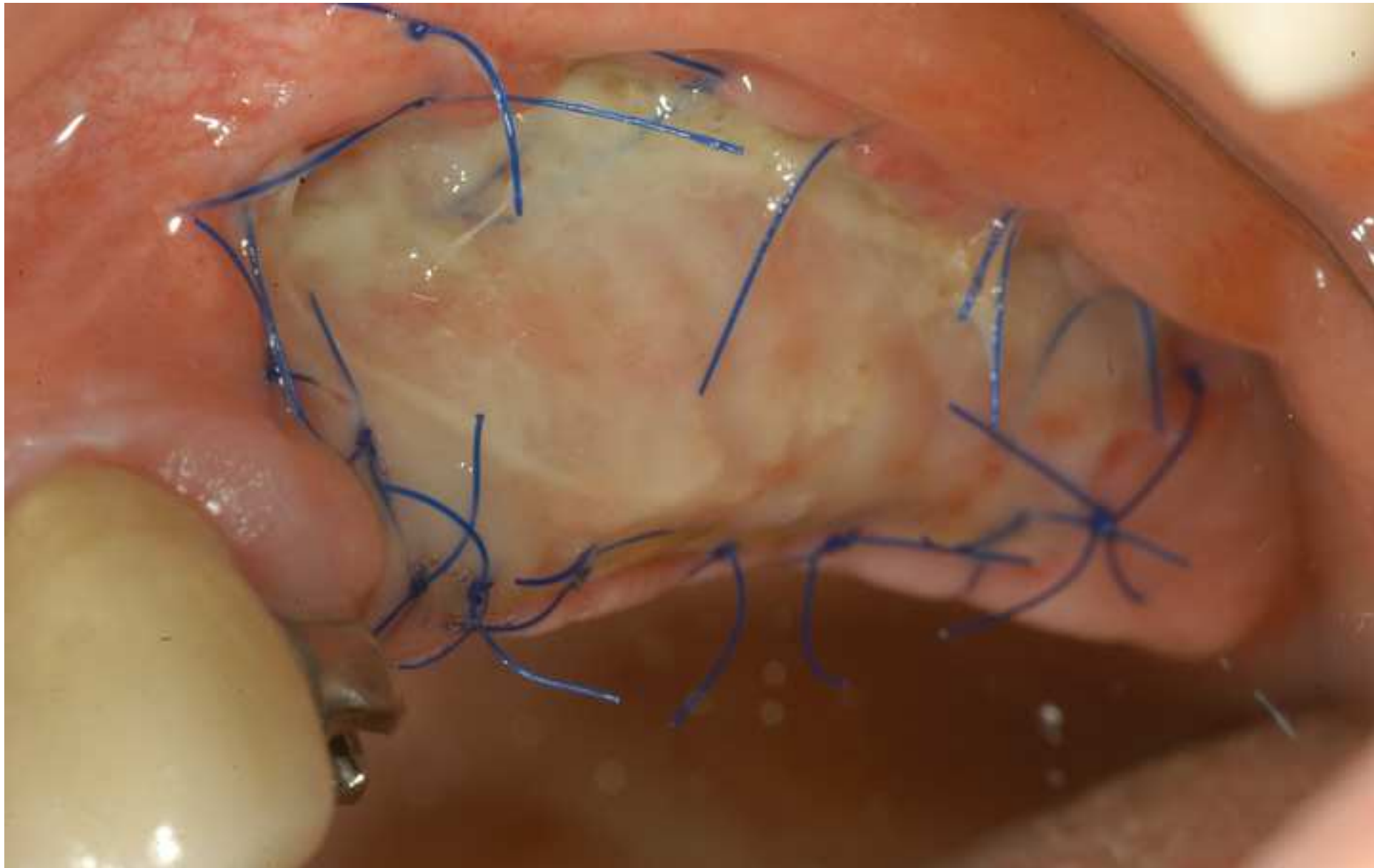


Figure 4

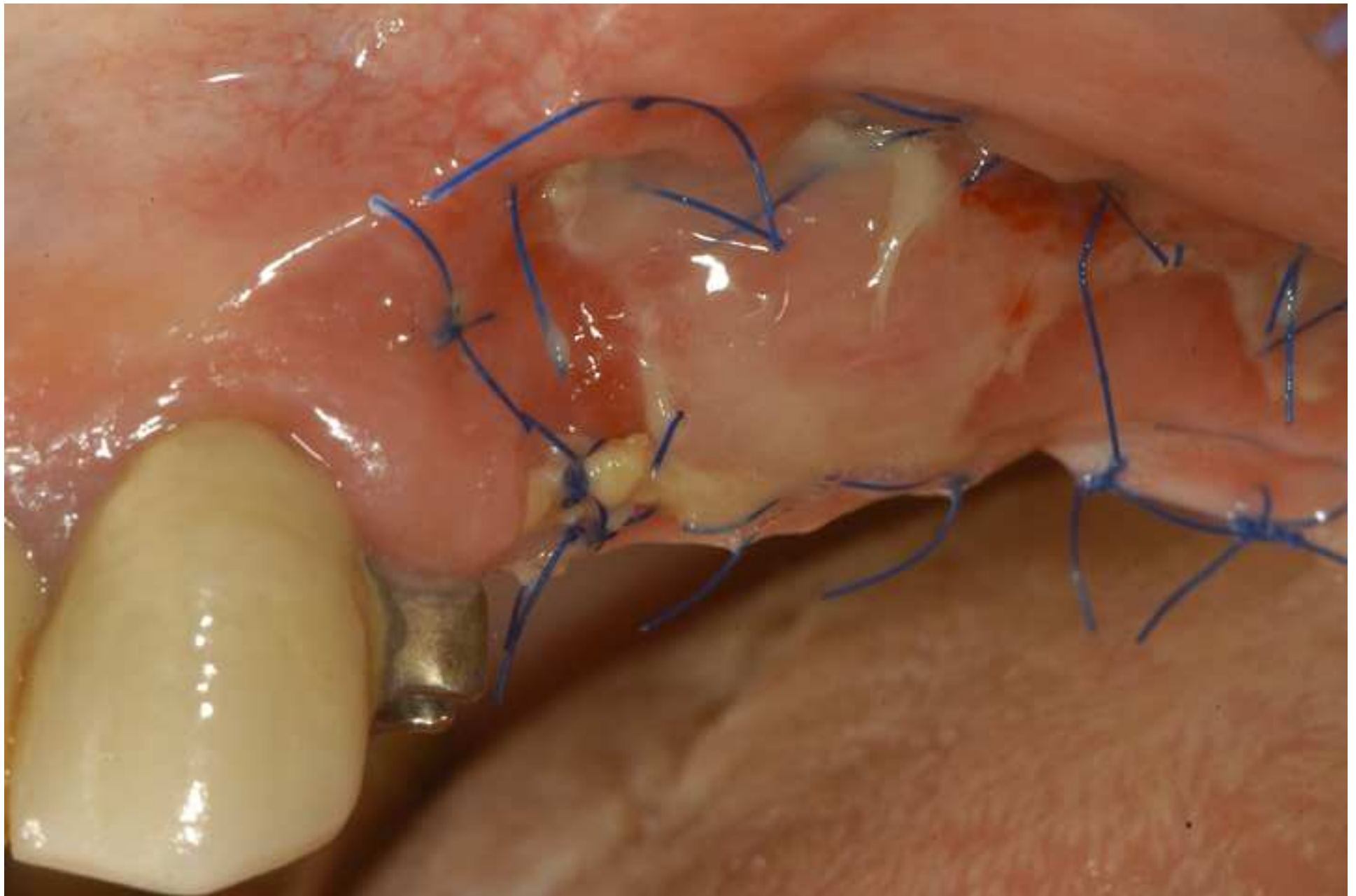

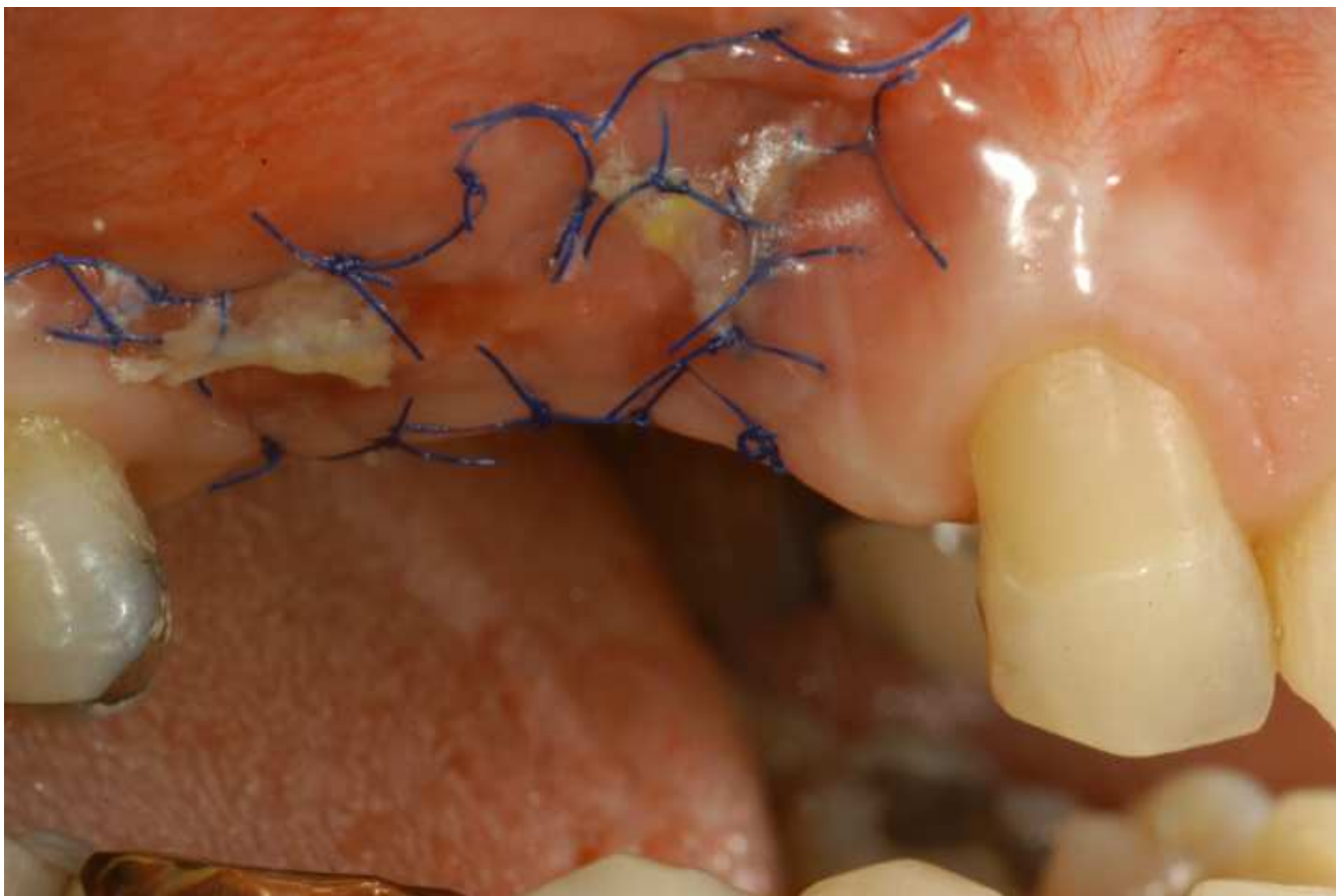


Figure 6

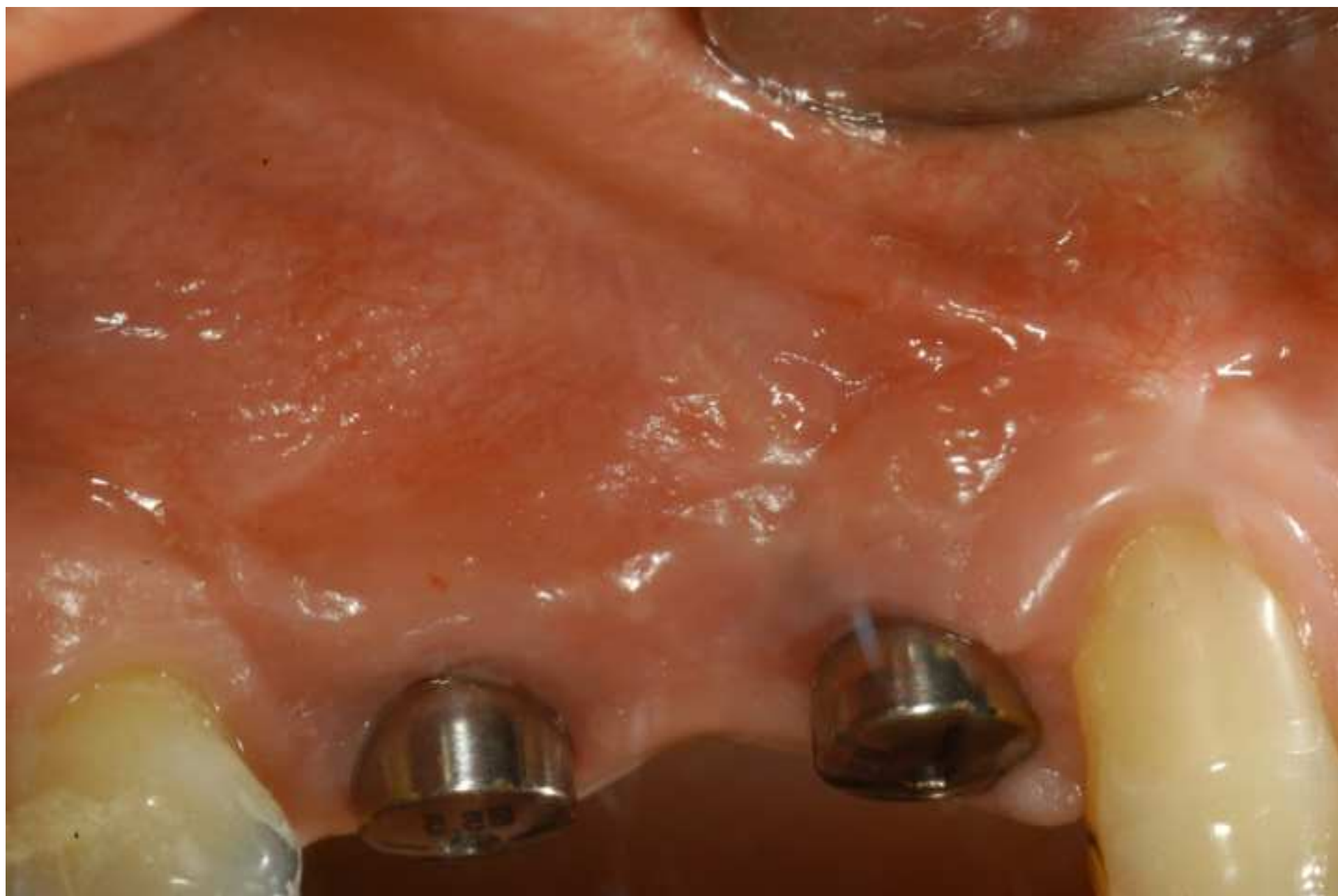
[Click here to download Figure fig. 6.tif](#)

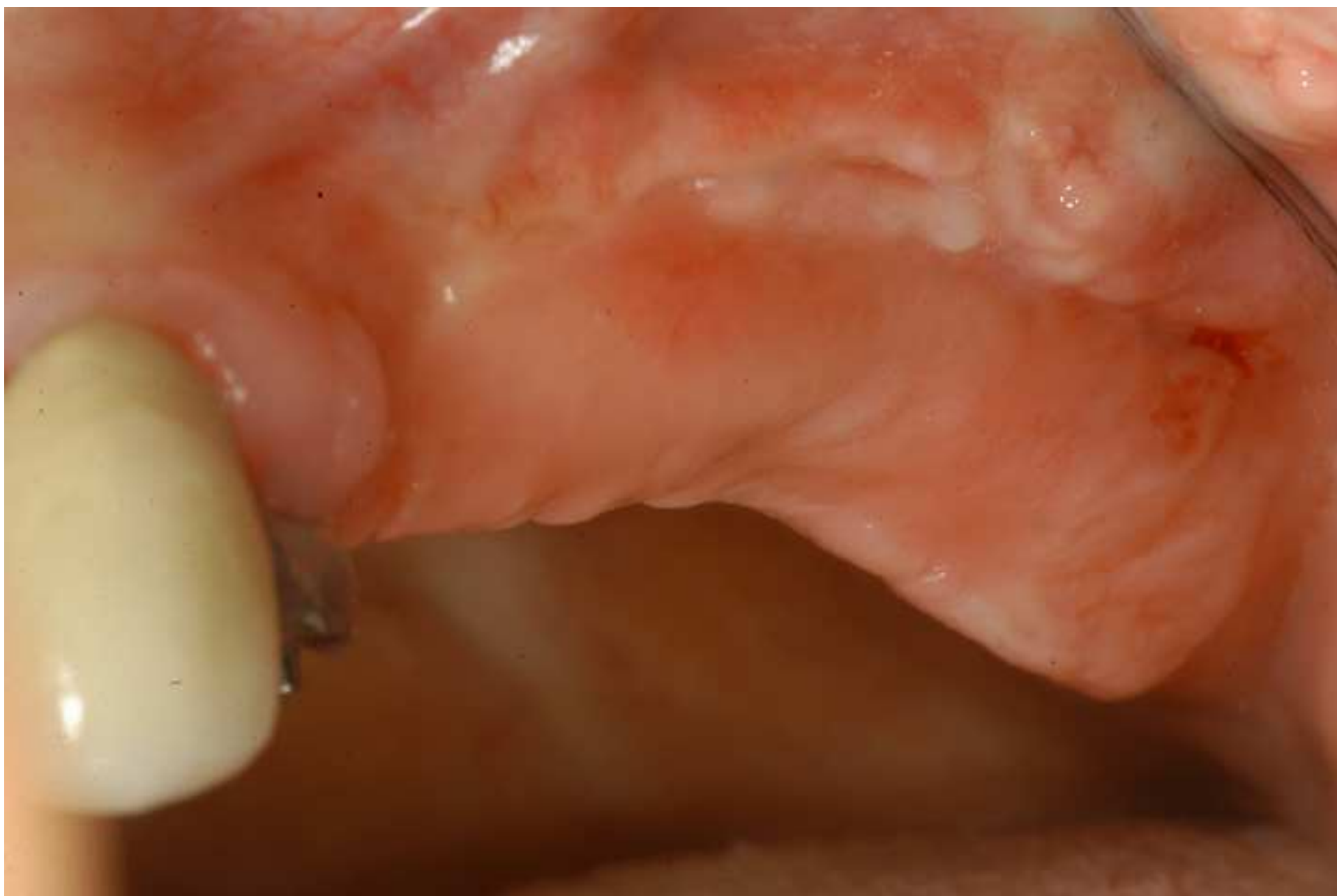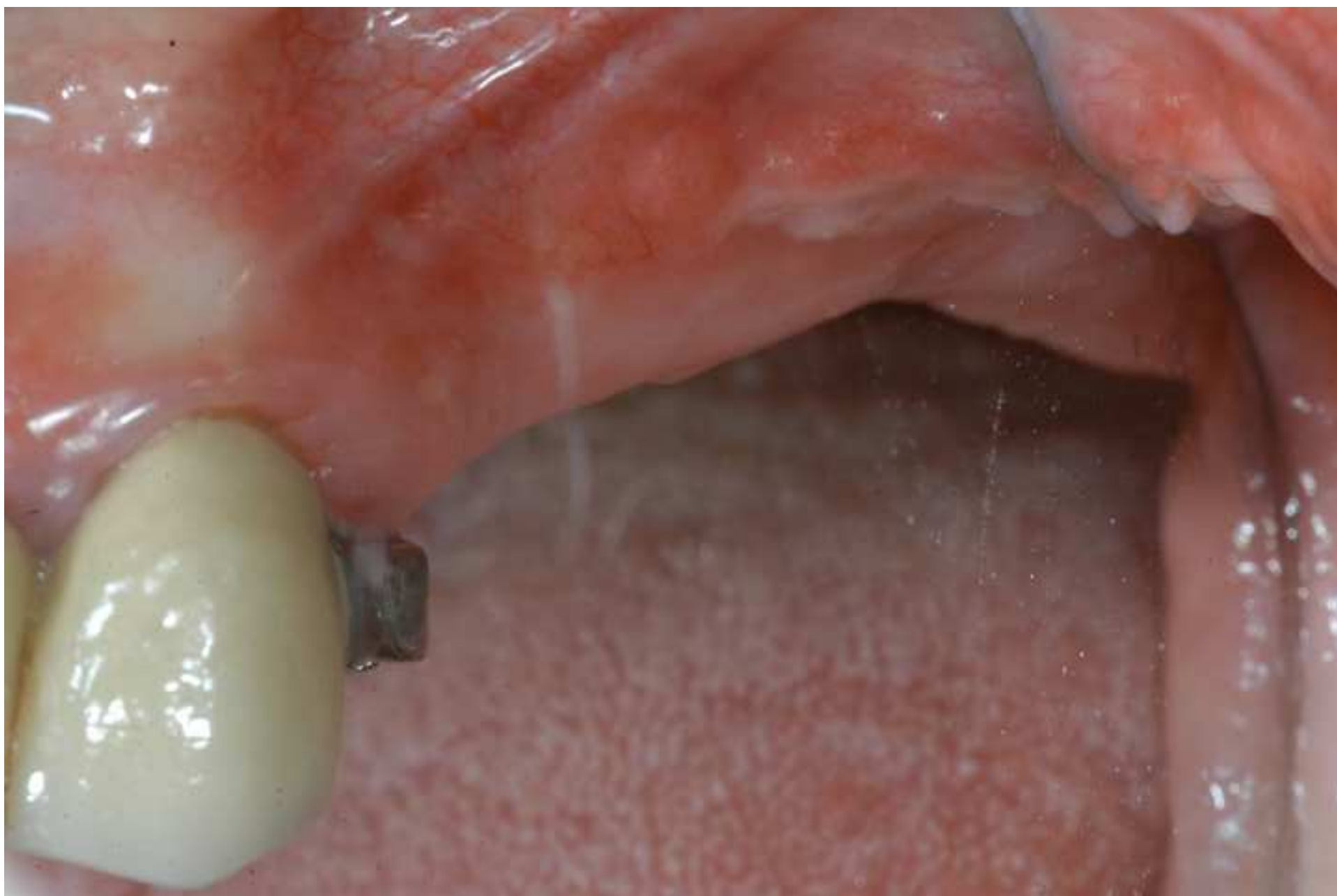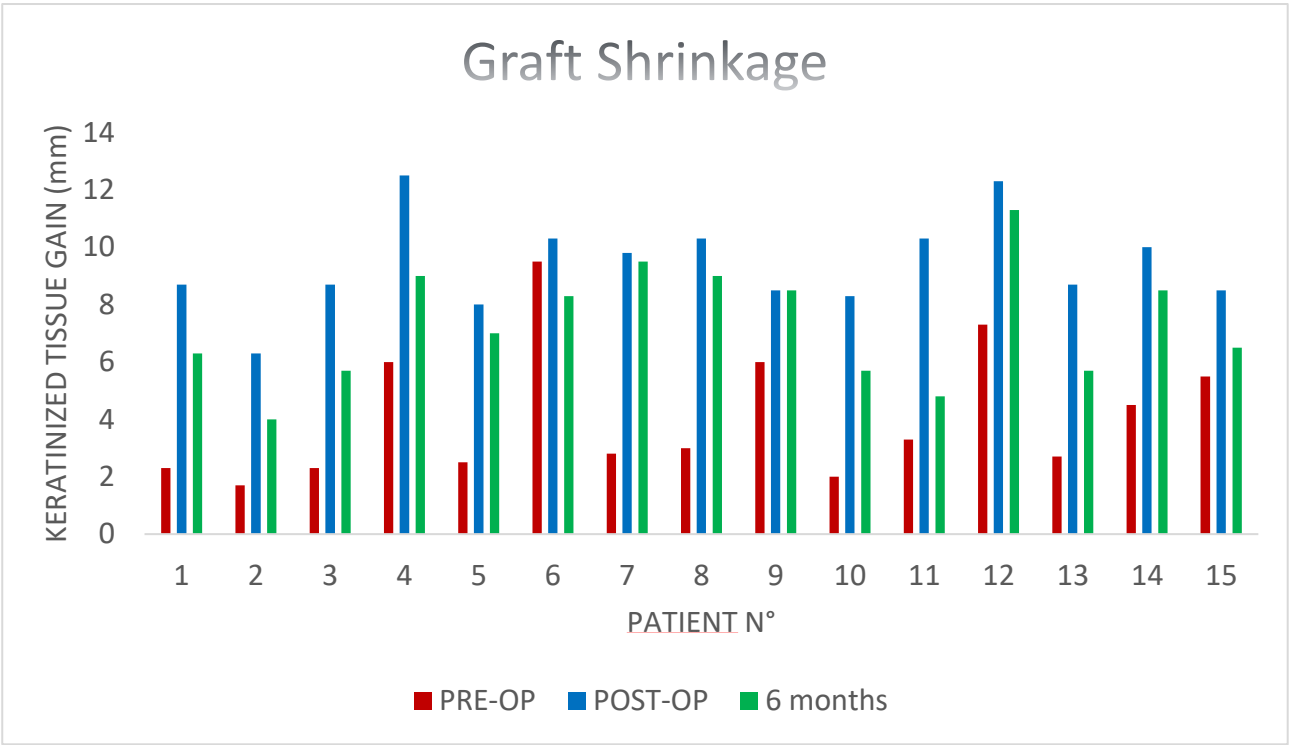


Figure 7

[Click here to download Figure fig.7.tif](#)







Name of Material/ Equipment	Company	Catalog Number	Comments/Description
Mucograft	Gesitlich Pharma AG		Xenogenic porcine collagen matrix
Ubistesin Articaine Hydrochloride 4% + epinephrine 1:200,000	3M	15035	Local Anesthetic
Curasept: Digluconate Chlorhexidine 0.2%	CURADEN HEALTHCARE S.p.A		Mouth wash
15c blade surgical scalpel	Henry-Schein / Krugg	10 58330	
Adson Surgical tissue pliers	Hu-Friedy	TP42	
Goldman Fox n°7	Hu-Friedy	KGF7CH	Surigcal knife
Straight Kelly scissors	Hu-Friedy	s2I	
Castroviejo	Hu-Friedy	NHCV	Needle-holder
Periodontal probe	Hu-Friedy	PCPUNC156	15mm North Carolina probe
5/0 Ethilon Nylon Suture	Ethicon	668h	Monofilament nylon suture
Protection splint	Technician Lab.		Methyl-methacrylate resin splint
SPSS Statistics	IBM		Statistic analysis software
Needle 30Gauge 21 mm	Heraeus	09 85900	
Nikon D90 DSLR camera	Nikon		Digital camera
Sigma 105mm f2.8	Sigma		Optical lens
Intraoral mirror	Smart Europe	32989	Lateral intraoral mirror

ARTICLE AND VIDEO LICENSE AGREEMENT

Title of Article: THE EFFICACY OF A POLYMER COAGULANT MATRIX IN KERATINIZED TISSUE
ADAPTATION : A 6 MONTHS FOLLOW-UP STUDY
Author(s): MAIORANA C, PIVETTI L, SIGMORINO F, GROSSI GB, BEGETTA M, HEALFORD AS

Item 1 (check one box): The Author elects to have the Materials be made available (as described at

http://www.jove.com/author) via: ☒ Standard Access ☐ Open Access

Item 2 (check one box):

☒ The Author is NOT a United States government employee.

☐ The Author is a United States government employee and the Materials were prepared in the

course of his or her duties as a United States government employee.

☐ The Author is a United States government employee but the Materials were NOT prepared in the course of his or her duties as a United States government employee.

ARTICLE AND VIDEO LICENSE AGREEMENT

2. Background. The Author, who is the author of the Article, in order to ensure the dissemination and protection of the Article, desires to have the JOVE publish the Article and create and transmit videos based on the Article. In furtherance of such goals, the Parties desire to memorialize in this Agreement the respective rights of each Party in and to the Article and the Video.

3. Grant of Rights in Article. In consideration of JOVE agreeing to publish the Article, the Author hereby grants to JOVE, subject to Sections 4 and 7 below, the exclusive, royalty-free, perpetual (for the full term of copyright in the Article, including any extensions thereof) license (a) to publish, reproduce, distribute, display and store the Article in all forms, formats and media whether now known or hereafter developed (including without limitation in print, digital and electronic form) throughout the world, (b) to translate the Article into other languages, create adaptations, summaries or extracts of the Article or other Derivative Works (including, without limitation, the Video) or Collective Works based on all or any portion of the Article and exercise all of the rights set forth in (a) above in such translations, adaptations, summaries, extracts, Derivative Works or Collective Works and (c) to license others to do any or all of the above. The foregoing rights may be exercised in all media and formats, whether now known or hereafter devised, and include the right to make such modifications as are technically necessary to exercise the rights in other media and formats. If the "Open Access" box has been checked in Item 1 above, JOVE and the Author hereby grant to the public all such rights in the Article as provided in, but subject to all limitations and requirements set forth in, the CRC License.

1. Defined Terms. As used in this Article and Video License Agreement, the following terms shall have the following meanings: "Agreement" means this Article and Video License Agreement; "Article" means the article specified on the last page of this Agreement, including any associated materials such as texts, figures, tables, artwork, abstracts, or summaries contained therein; "Author" means the author who is a signatory to this Agreement; "Collective Work" means a work, such as a periodical issue, anthology or encyclopedia, in which the Materials in their entirety in unmodified form, along with a number of other contributions, constituting separate and independent works in themselves, are assembled into a collective whole; "CRC License" means the Creative Commons Attribution-Non Commercial-No Derivs 3.0 Unported Agreement, the terms and conditions of which can be found at: <http://creativecommons.org/licenses/by-nc-nd/3.0/legalcode>; "Derivative Work" means a work based upon the Materials or upon the Materials and other pre-existing works, such as a translation, musical arrangement, dramatization, fictionalization, motion picture version, sound recording, art reproduction, abridgment, condensation, or any other form in which the Materials may be recast, transformed, or adapted; "Institution" means the institution, listed on the last page of this Agreement, by which the Author was employed at the time of the creation of the Materials; "JOVE" means MyJove Corporation, a Massachusetts corporation and the publisher of *The Journal of Visualized Experiments*; "Materials" means the Article and / or the Video; "Parties" means the Author and JOVE; "Video" means any video(s) made by the Author, alone or in conjunction with any other parties, or by JOVE or its affiliates or agents, individually or in collaboration with the Author or any other parties, incorporating all or any portion of the Article, and in which the Author may or may not appear.

ARTICLE AND VIDEO LICENSE AGREEMENT

statute. In such case, all provisions contained herein that are not in conflict with such statute shall remain in full force and effect, and all provisions contained herein that do so conflict shall be deemed to be amended so as to provide to JOVE the maximum rights permissible within such statute.

8. Likeness, Privacy, Personality. The Author hereby grants JOVE the right to use the Author's name, voice, likeness, picture, photograph, image, biography and performance in any way, commercial or otherwise, in connection with the Materials and the sale, promotion and distribution thereof. The Author hereby waives any and all rights he or she may have, relating to his or her appearance in the Video or otherwise relating to the Materials, under all applicable privacy, likeness, personality or similar laws.

9. Author Warranties. The Author represents and warrants that the Article is original, that it has not been published, that the copyright interest is owned by the Author (or, if more than one author is listed at the beginning of this Agreement, by such authors collectively) and has not been assigned, licensed, or otherwise transferred to any other party. The Author represents and warrants that the author(s) listed at the top of this Agreement are the only authors of the Materials. If more than one author is listed at the top of this Agreement and if any such author has not entered into a separate Article and Video License Agreement with JOVE relating to the Materials, the Author represents and warrants that the Author has been authorized by each of the other such authors to execute this Agreement on his or her behalf and to bind him or her with respect to the terms of this Agreement as if each of them had been a party hereto as an Author. The Author warrants that the use, reproduction, distribution, public or private performance or display, and/or modification of all or any portion of the Materials does not and will not violate, infringe and/or misappropriate the patent, trademark, intellectual property or other rights of any third party. The Author represents and warrants that it has and will continue to comply with all government, institutional and other regulations, including, without limitation all institutional, laboratory, hospital, ethical, human and animal treatment, guidelines, applicable to the Materials, and that all research involving human and animal subjects has been approved by the Author's relevant institutional review board.

10. JOVE Discretion. If the Author requests the assistance of JOVE in producing the Video in the Author's facility, the Author shall ensure that the presence of JOVE employees, agents or independent contractors is in accordance with the relevant regulations of the Author's institution. If more than one author is listed at the beginning of this Agreement, JOVE may, in its sole discretion, elect not take any action with respect to the Article until such time as it has received complete, executed Article and Video License Agreements from each such author. JOVE reserves the right, in its absolute and sole discretion and without giving any reason therefore, to accept or decline any work submitted to JOVE. JOVE and its employees, agents and independent contractors shall have

4. Retention of Rights in Article. Notwithstanding the exclusive license granted to JOVE in **Section 3** above, the Author shall, with respect to the Article, retain the non-exclusive right to use all or part of the Article for the non-commercial purpose of giving lectures, presentations or teaching classes, and to post a copy of the Article on the institution's website or the Author's personal website, in each case provided that a link to the Article on the JOVE website is included. All non-copyright intellectual property rights in and to the Article, such as patent rights, shall remain with the Author.

5. Grant of Rights in Video – Standard Access. This **Section 5** applies if the "Standard Access" box has been checked in **Item 1** above or if no box has been checked in **Item 1** above. In consideration of JOVE agreeing to produce, display or otherwise assist with the Video, the Author hereby acknowledges and agrees that, Subject to **Section 7** below, JOVE is and shall be the sole and exclusive owner of all rights of any nature, including, without limitation, all copyrights, in and to the Video. To the extent that, by law, the Author is deemed, now or at any time in the future, to have any rights of any nature in or to the Video, the Author hereby disclaims all such rights and transfers all such rights to JOVE.

6. Grant of Rights in Video – Open Access. This **Section 6** applies only if the "Open Access" box has been checked in **Item 1** above. In consideration of JOVE agreeing to produce, display or otherwise assist with the Video, the Author hereby grants to JOVE, subject to **Section 7** below, the exclusive, royalty-free, perpetual (for the full term of copyright in the Article, including any extensions thereof) license (a) to publish, reproduce, distribute, display and store the Video in all forms, formats and media whether now known or hereafter developed (including without limitation in print, digital and electronic form) throughout the world, (b) to translate the Video into other languages, create adaptations, summaries or extracts of the Video or other Derivative Works or Collective Works based on all or any portion of the Video and exercise all of the rights set forth in (a) above in such translations, adaptations, summaries, extracts, Derivative Works or Collective Works and (c) to license others to do any or all of the above. The foregoing rights may be exercised in all media and formats, whether now known or hereafter devised, and include the right to make such modifications as are technically necessary to exercise the rights in other media and formats. For any Video to which this Section 6 is applicable, JOVE and the Author hereby grant to the public all such rights in the Video as provided in, but subject to all limitations and requirements set forth in, the CRC License.

7. Government Employees. If the Author is a United States government employee and the Article was prepared in the course of his or her duties as a United States government employee, as indicated in **Item 2** above, and any of the licenses or grants granted by the Author hereunder exceed the scope of the 17 U.S.C. 403, then the rights granted hereunder shall be limited to the maximum rights permitted under such

ARTICLE AND VIDEO LICENSE AGREEMENT

expense. All indemnifications provided herein shall include JOVE's attorney's fees and costs related to said losses or damages. Such indemnification and holding harmless shall include such losses or damages incurred by, or in connection with, acts or omissions of JOVE, its employees, agents or independent contractors.

12. Fees. To cover the cost incurred for publication, JOVE must receive payment before production and publication the Materials. Payment is due in 21 days of invoice. Should the Materials not be published due to an editorial or production decision, these funds will be returned to the Author. Withdrawal by the Author of any submitted Materials after final peer review approval will result in a US\$1,200 fee to cover pre-production expenses incurred by JOVE. If payment is not received by the completion of filming, production and publication of the Materials will be suspended until payment is received.

13. Transfer, Governing Law. This Agreement may be assigned by JOVE and shall inure to the benefit of any of JOVE's successors and assigns. This Agreement shall be governed and construed by the internal laws of the Commonwealth of Massachusetts without giving effect to any conflict of law provision therein. This Agreement may be executed in counterparts, each of which shall be deemed an original, but all of which together shall be deemed to be one and the same agreement. A signed copy of this Agreement delivered by facsimile, e-mail or other means of electronic transmission shall be deemed to have the same legal effect as delivery of an original signed copy of this Agreement.

A signed copy of this document must be sent with all new submissions. Only one Agreement required per submission.

CORRESPONDING AUTHOR:

Name: LUCA PIVETTI

Department: IMPLANT CENTER FOR EDENTULISM AND JAWBONE ATROPHIES

Institution: ORFÈRE MAGGIORIS POLICLINICO

Article Title: THE EFFICACY OF A PORCINE COLLAGEN MATRIX IN REGENERATED TISSUE AUGMENTATION: A 6 MONTHS FOLLOW-UP STUDY

Signature:



Date:

08.08.2017

Please submit a signed and dated copy of this license by one of the following three methods:

- 1) Upload a scanned copy of the document as a pdf on the JOVE submission site;
- 2) Fax the document to +1.866.381.2236;
- 3) Mail the document to JOVE / Attn: JOVE Editorial / 1 Alewife Center #200 / Cambridge, MA 02139

For questions, please email submissions@jove.com or call +1.617.945.9051

Dear Editor and Reviewers,

We sincerely thank you for the time spent revising our manuscript and the comments about it.

We have modified the paper following your insight on the manuscript and hope that this revised version will please you.

EDITORIAL COMMENTS:

2. Please provide an email address for each author on the first page.

Emails provided for each author

3. Please define all abbreviations before use.

All abbreviations defined (EEC, ANOVA)

4. Please revise the Introduction to include all of the following:

- a) A clear statement of the overall goal of this method
- b) The rationale behind the development and/or use of this technique
- c) The advantages over alternative techniques with applicable references to previous studies
- d) A description of the context of the technique in the wider body of literature
- e) Information to help readers to determine whether the method is appropriate for their application

Introduction modified as requested. Points a-b-c-e were better defined and point c elaborated with references to systematic reviews

5. Please ensure that all text in the protocol section is written in the imperative tense as if telling someone how to do the technique (e.g., "Do this," "Ensure that," etc.). The actions should be described in the imperative tense in complete sentences wherever possible. Avoid usage of phrases such as "could be," "should be," and "would be" throughout the Protocol. Any text that cannot be written in the imperative tense may be added as a "Note." However, notes should be concise and used sparingly. Please include all safety procedures and use of hoods, etc.

Imperative tense corrected throughout the entire protocol

6. The Protocol should be made up almost entirely of discrete steps without large paragraphs of text between sections. The Protocol steps should contain only 2-3 actions per step and a maximum of 4 sentences per step.

Protocol sentences and steps were checked

7. Please ensure you answer the "how" question, i.e., how is the step performed? Alternatively, add references to published material specifying how to perform the protocol action.

Protocol modified as requested

8. Please include an ethics statement before the numbered protocol steps, indicating that the protocol follows the guidelines of your institution's human research ethics committee.

Ethics statement added

9. Please leave a blank line between all protocol steps as well as Notes.

Blank lines present

10. Please revise the protocol text to avoid the use of any personal pronouns (e.g., "we", "you", "our" etc.).

Personal pronouns were removed

11. Protocol: 1.1: Please use the imperative tense.

Imperative tense used

12. Protocol: 1.2: How to prepare the acrylic stent? Please describe the actions clearly or refer to appropriate references.

Acrylic stent is prepared by the dental laboratory, as better defined in the text. Each laboratory could use different techniques, as far as we know.

13. Protocol: 1.3: Please use the imperative tense. How are digital picture taken? Which technique?

Description on how to take intraoral pictures for the case given was added

14. Protocol: 1.4: Please use the imperative tense. How many time they should wash their mouths?

Twice a day added to text

15. Protocol: 2.1.1: Which instrument used? Please clearly describe the actions.

Instrument specified, actions better described

16. Protocol: 2.1.2: Please avoid the use of any personal pronouns.

Personal pronouns removed from text

17. Protocol: 2.1.3: How is that done? Using what?

Actions and materials better described

18. Protocol: 2.1.4: Please avoid the use of any personal pronouns.

Personal pronouns removed from text

19. Protocol: How to measure? Please describe clearly ore refer to an appropriate reference.

Description on how to measure added

20. Protocol: 2.1.9, 2.2.6, 2.3.3: How are digital picture taken? Which technique and device?

See point 13

21. Protocol: 2.2.3: Please use the imperative tense for all the actions.

Correction made

22. Protocol: 2.2.5: How is that done?

Description added

23. Protocol: 2.3.1: How to make sure? What should be checked?

Description added

24. Protocol: 2.3.2: How to check that is not compressing the collagen matrix.

Acrylic stent must not touch the membrane, as better specified in text

25. Protocol: 2.3.4: What is exactly the instruction? We need all the details for filming.

Instructions added

26. Protocol: 2.3.5: How much solution in needed for each so-called irrigation?

10ml NaCl, as added into text

27. Protocol: 3.2: How is that done? What is the protocol for that? Please explain or refer to an appropriate reference.

Reference added to mankowski's pain scale

28. Protocol: 3.4: How to evaluate? What should be checked?

New epithelization should be checked, as added into text

29. Protocol: 3.5, 3.6, 3.7: Please describe the actions clearly.

Actions better described

30. Protocol: 3.8: Each step? Do you mean steps 3.2-3.7?

Yes, we meant from 3.2 to 3.7, as added to text.

31. As we are a methods journal, please revise the Discussion to explicitly cover the following in detail in 3-6 paragraphs with citations:

- a) Critical steps within the protocol
- b) Any modifications and troubleshooting of the technique
- c) Any limitations of the technique
- d) The significance with respect to existing methods
- e) Any future applications of the technique

We explicitly addressed your requests. We described the critical steps and the limitation of the techniques. We compared the results with existing methods and described possible future study.

32. If you are reusing figures from a previous publication, you must obtain explicit permission to re-use the figure from the previous publisher (this can be in the form of a letter from an editor or a link to the editorial policies that allows you to re-publish the figure). Please upload the text of the re-print permission (may be copied and pasted from an email/website) as a Word document to the Editorial Manager site in the "Supplemental files (as requested by JoVE)" section. Please also cite the figure appropriately in the figure legend, i.e. "This figure has been modified from [AUTHOR] et al.[REFERENCE]".

Pictures from previous publication were changed with different ones.

33. Please revise the table of the essential supplies, reagents, and equipment. The table should include the name, company, and catalog number of all relevant materials in separate columns in an xls/xlsx file. Please list all the materials, equipment, instrument, and software used in your work.

Table completed with other material

Thank you again for your kind attention.

Best regards,

Dr. Luca Pivetti