

Journal of Visualized Experiments

Regenerative therapy by suprachoroidal cell autograft in dry age-related macular degeneration: preliminary in vivo report --Manuscript Draft--

Manuscript Number:	JoVE56469R4
Full Title:	Regenerative therapy by suprachoroidal cell autograft in dry age-related macular degeneration: preliminary in vivo report
Article Type:	Invited Methods Article - JoVE Produced Video
Keywords:	Age-related macular degeneration; Best corrected visual acuity (BCVA); Autologous Cell graft; Electroretinogram; Growth factor (GF); Limoli Retinal Restoration Technique (LRRT); Microperimetry; Regenerative therapy; Suprachoroidal autograft.
Manuscript Classifications:	3.11.768: Retinal Diseases; 3.11.966: Vision Disorders
Corresponding Author:	Paolo Giuseppe Limoli Low Vision Research Centre of Milan Milano, Milano ITALY
Corresponding Author Secondary Information:	
Corresponding Author E-Mail:	paololimoli@libero.it
Corresponding Author's Institution:	Low Vision Research Centre of Milan
Corresponding Author's Secondary Institution:	
First Author:	Paolo Giuseppe Limoli
First Author Secondary Information:	
Other Authors:	Enzo Maria Vingolo
	Celeste Limoli
	Sergio Zaccaria Scalinci
	Marcella Nebbioso
Order of Authors Secondary Information:	
Abstract:	<p>This study is aimed at to examining whether the suprachoroidal graft of autologous cells can improve best corrected visual acuity (BCVA) and responses to microperimetry (MY) in eyes affected by dry Age-related Macular Degeneration (AMD) over time through the production and secretion of growth factors (GFs) on surrounding tissue. The patients were randomly assigned to each group. All patients were diagnosed with dry AMD and with BCVA equal to or greater than 1 logarithm of the minimum angle of resolution (logMAR). Suprachoroidal autologous graft by Limoli Retinal Restoration Technique (LRRT) was carried out on group A, which included 11 eyes from 11 patients. The technique is performed by implanting adipocytes, adipose-derived stem cells obtained from the stromal vascular fraction and platelets from platelet-rich plasma in the suprachoroidal space. Conversely, group B, including 14 eyes of 14 patients, was used as a control variable. For each patient, diagnosis was verified by confocal scanning laser ophthalmoscope and spectral domain-optical coherence tomography (SD-OCT). In group A, BCVA improved by 0.581 to 0.504 at 90 days and to 0.376 logMAR at 180 days (+32.20%) postoperatively. Furthermore, MY test increased by 11.44 dB to 12.59 dB at 180 days. The different cell types grafted behind the choroid were able to ensure constant GF secretion in the choroidal flow. Consequently, the results indicate that visual acuity (VA) in the grafted group can increase more than in the control group after six months.</p>
Author Comments:	None

Additional Information:	
Question	Response
If this article needs to be "in-press" by a certain date, please indicate the date below and explain in your cover letter.	

TITLE:

Regenerative Therapy by Suprachoroidal Cell Autograft in Dry Age-Related Macular Degeneration: Preliminary *in Vivo* Report

AUTORS AND AFFILIATIONS:

Paolo Giuseppe Limoli¹, Enzo Maria Vingolo², Celeste Limoli¹, Sergio Zaccaria Scalinci³, Marcella Nebbioso⁴

¹Low Vision Research Centre of Milan, Milan, Italy.

²Department of Ophthalmology, A. Fiorini Hospital, Via Firenze, Terracina, Polo Pontino, Sapienza University of Rome.

³Glaucoma and Low Vision Study Center, Department of General Surgery and Organ Transplants, University of Bologna, Bologna, Italy.

⁴Department of Sense Organs, Faculty of Medicine and Odontology, Sapienza University of Rome, Rome, Italy.

AUTHOR EMAILS:

Paolo Giuseppe Limoli (paololimoli@libero.it)

Enzo Maria Vingolo (evingolo@libero.it)

Celeste Limoli (celeste.limoli@libero.it)

Sergio Zaccaria Scalinci (sergio.scalinci@unibo.it)

Marcella Nebbioso (marcella.nebbioso@uniroma1.it)

CORRESPONDING AUTHOR:

Marcella Nebbioso (marcella.nebbioso@uniroma1.it)

Phone: +39-06-49975422

Fax: +39-06-49975425

KEYWORDS:

Age-related macular degeneration, Best corrected visual acuity (BCVA), Autologous cell graft, Electroretinogram, Growth factor (GF), Limoli Retinal Restoration Technique (LRRT), Microperimetry, Regenerative therapy, Suprachoroidal autograft

SHORT ABSTRACT:

The goal of this study is to assess whether the suprachoroidal graft of adipose-derived stem cells included in the stromal vascular fraction and platelets derived from platelet-rich plasma by the Limoli Retinal Restoration Technique can improve visual acuity and retinal sensitivity responses in eyes affected by dry age-related macular degeneration.

LONG ABSTRACT:

This study is aimed at examining whether a suprachoroidal graft of autologous cells can improve best corrected visual acuity (BCVA) and responses to microperimetry (MY) in eyes affected by dry Age-related Macular Degeneration (AMD) over time through the production and secretion of growth factors (GFs) on surrounding tissue. Patients were randomly assigned to each study group. All patients were diagnosed with dry AMD and with BCVA equal to or greater than 1 logarithm of the minimum angle of resolution (logMAR). A suprachoroidal autologous graft by Limoli Retinal Restoration Technique (LRRT) was carried out on group A,

which included 11 eyes from 11 patients. The technique was performed by implanting adipocytes, adipose-derived stem cells obtained from the stromal vascular fraction, and platelets from platelet-rich plasma in the suprachoroidal space. Conversely, group B, including 14 eyes of 14 patients, was used as a control group. For each patient, diagnosis was verified by confocal scanning laser ophthalmoscope and spectral domain-optical coherence tomography (SD-OCT). In group A, BCVA improved by 0.581 to 0.504 at 90 days and to 0.376 logMAR at 180 days (+32.20%) postoperatively. Furthermore, MY test increased by 11.44 dB to 12.59 dB at 180 days. The different cell types grafted behind the choroid were able to ensure constant GF secretion in the choroidal flow. Consequently, the results indicate that visual acuity (VA) in the grafted group can increase more than in the control group after six months.

INTRODUCTION:

Cell therapy, consisting of the systemic or local injection of stem/progenitor cells in the injured area to treat multiple chronic disorders, has drawn close attention in the last decade¹. Since the 1990s, growth factors (GFs) have been studied for their potentially therapeutic role in retinal atrophy². In fact, many human cells can produce GFs, which are specific proteins that are able to block or slow down apoptosis, *i.e.*, the programmed death of cells³.

It is known that dry age-related macular degeneration (AMD) is an atrophic retinal disease where gradual and irreversible cell death involves injury to the photoreceptor layer and, consequently, the loss of central visual function⁴. AMD is the leading cause of blindness in people over 55 years of age in developed countries and accounts for 80% of all macular degenerations, which lack an effective treatment to date.

Several studies have shown that there are various sources from which autologous GFs can be obtained. These comprise different cell types, including adipose stromal cells derived from orbital fat, platelets derived from platelet-rich plasma (PRP), and adipose-derived stem cells (ADSCs) included in the stromal vascular fraction (SVF) of adipose tissue⁵⁻⁷. The current GF set ensures retinal neuroenhancement, and research conducted by Filatov, Meduri, Pelaez and Limoli has demonstrated that autologous fat transplantation (AFT) is effective⁸⁻¹⁰.

Moreover, a prior study showed significant improvements in electroretinogram (ERG) data, recorded post suprachoroidal autologous graft, in dry AMD-affected eyes¹¹. The surgically grafted tissue in the suprachoroidal space modulated the paracrine secretion of retinal cells, delaying their apoptosis^{6,7,12}. Considering outer nuclear layer thickness, the histological examination of the retina of guinea pigs has shown that GFs could have a trophic effect on the retina. Therefore, the direct or indirect use of GFs can potentially bring therapeutic benefits through a balanced relation between molecular inducers and inhibitors^{6,7,12}.

The purpose of this method is to assess whether the suprachoroidal graft of adipocytes, ADSCs in SVF and PRP can improve best corrected visual acuity (BCVA) and microperimetry (MY) responses in dry AMD-affected eyes. This study aims to demonstrate the therapeutic effect of autograft on the basis of its GF production, according to the cited literature^{6,7,12,13}.

PROTOCOL:

The study protocol was approved by the Ethics Committee of the Low Vision Academy and all subjects signed a written consent in accordance with the Helsinki Declaration. This research study has received ethical approval from both Loughborough and Sheffield Universities.

Note: The inclusion and exclusion criteria of dry age-related macular degeneration patients to receive suprachoroidal autologous graft by Limoli Retinal Restoration Technique (LRRT) is described in **Table 1**.

1. Diagnosis of Dry Age-Related Macular Degeneration Patients

1.1. Ascertain the diagnosis with confocal scanning laser ophthalmoscope, SD-OCT, and MY.

1.2. Evaluate each group's BCVA for far and near distance. Measure VA for near vision (close-up) in points (Pts). Measure BCVA at time 0 (T0), 90 (T90) and 180 days (T180) compared to early treatment diabetic retinopathy study (EDTRS) charts at 4 meters in logMAR.

1.3. Record electrical scotopic, mesopic, and photopic cell activity, or flash ERG, according to the standards set in 2009 by the International Society for Clinical Electrophysiology of Vision (ISCEV)¹¹.

2. Anesthetization

Note: The gold standard in anesthesia during LRRT is topical anesthesia, reinforced by sub-tenon's infiltration of anesthetic and sedation. In specific cases, general anesthesia is preferred.

2.1. Obtain corneal and conjunctival anesthesia by applying topical local anesthetics instilled dropwise 15-20 min before the surgery with lidocaine at 4% and ropivacaine at 1%.

2.2. Inject anesthesia by infiltration directly into sub-conjunctival and subtenon's spaces.

2.3. Use local infiltration both in the abdominal region, before the adipose tissue is extracted, and in the sub-conjunctival and sub-tenon's spaces, 12 mm from the limbus. Adopt local anesthetic of carbocaine or marcain mixed with 1,200 IU epinephrine.

2.4. Provide intraoperative sedation through the anesthetic, which can be performed properly by using fentanyl as a narcotic analgesic through repeated small boli. The dosage is generally 0.025 mg of fentanyl with 1 mg of midazolam per bolus.

3. Limoli Retinal Restoration Technique Preparation

Note: This technique represents a variant of Pelaez's intervention by which orbital autologous fat is transplanted in the subscleral space^{1,6,7,12}. Surgically grafted cells can produce many GFs with neurotrophic and angiogenic properties in the surrounding tissue, choroid, and retina^{18,19,20-25}. In LRRT, the distance between grafted autologous cells and choroid is reduced by means of deep sclerectomy, and the contact area between the stalk and choroid is expanded to promote the paracrine autologous cell secretion into the choroidal flow^{9,10,14}.

3.1. Perform proper disinfection of each eye before surgery with cellular grafting between the choroid and sclera, a procedure called Limoli Retinal Restoration Technique (LRRT)¹⁵⁻¹⁷.

3.2. Graft the ADSCs, obtained by Coleman *et al.* and Lawrence's technique (**Figure 1**) from abdominal fat, in the SVF in the suprachoroidal space¹⁵⁻¹⁷.

3.3. Infiltrate adipose pedicle with platelets derived from PRP gel obtained through the following steps.

3.4. Centrifuge blood^{6,12} and collect platelet-rich plasma (PRP). The stimulus to platelet degranulation causes GF release in the adipose pedicle^{6,12}.

4. Technical Specifications and Strategy

Note: Fat tissue is collected and purified from the abdominal subcutaneous layer of patients, according to the Lawrence and Coleman technique¹⁷(**Table of Materials**).

4.1. Manually harvest 10 mL of fat tissue from the abdominal subcutaneous layer of each patient, using a 3-mm blunt cannula connected to a locking syringe, according to the Lawrence and Coleman technique¹⁷ (**Figures 2A/2B**).

4.2. Separate pure SVF of fat tissue from blood, fat, oil, and liquid by centrifugation for 5 min at 1,500 x g at 20 °C (**Figure 2C**). The SVF is very rich of ADSCs¹⁷.

4.3. Collect 8 mL of human peripheral blood with a 22 G needle and in a separate tube for PRP preparation.

4.4. Centrifuge the collected blood for 5 min at 1,500 x g at 20 °C (**Figure 2D**). In LRRT, the ensuing changes result in better survival of the autologous fat graft, ADSC proliferation, which favors increased choroidal perfusion, and a more comprehensive modulation of the action of those factors that are secreted only by fat^{7,11,17}.

4.5. Build the suprachoroidal pocket (more details in step 4, in particular 4.4 and 4.5) to accommodate the graft obtained from orbital fat and saturate the residual volume of this pocket with a mixture of ADSCs from SVF and PRP, obtained according to the Lawrence and Coleman technique¹⁷.

5. Suprachoroidal Autograft by LRRT (Limoli Retinal Restoration Technique): Surgical Procedure and Technical Details

5.1. Anchor the sclera with 6-0 silk suture, near the inferior-temporal limbus.

5.2. Open the subconjunctival and subtenonian space at 11 mm from the inferior-temporal limbus, using 5.5" Westcott Tenotomy curved scissors.

5.3. Insert the Limoli-Basile conjunctival retractor in this space to make a scleral surgical field.

188
189 5.4. Using a 5-mm crescent knife angled bevel up, pre-cut a flap on the side in the sclera at 8
190 mm, from the limbus. The flap hinge is always radial and to the left of the surgeon.

191
192 5.5. In the inferior-temporal quadrant, at 8 mm from the limbus, open a deep scleral door of
193 about 5 mm on the side by radial hinge by using a crescent knife, angled bevel up. Carry out
194 sclerectomy at an adequate depth to view the slate color of the choroid.

195
196 5.6. Create a gap by removing a little operculum in the distal part of the flap, in order to
197 facilitate blood circulation in the subsequent suprachoroidal autograft.

198
199 5.7. Extract with ophthalmological forceps the orbital fat from a gap above the inferior
200 oblique muscle. Make sure the extracted fat is sufficiently vascularized to allow it to survive
201 after its implantation.

202
203 5.8. Gently place the autologous fat flap on the choroidal bed and suture with choroidal 6/0
204 polyglactin fiber at the proximal edge of the door.

205
206 5.9. Suture the scleral flap to avoid compression on the fat pedicle or on its nutrient vessels.

207
208 5.10. Infiltrate the stroma of the fat pedicle with 1 mL of PRP gel (obtained by centrifugation
209 of the blood material, separation of the component, and platelet degranulation²⁶) using a 30
210 G angled (30 °) cannula.

211
212 5.11. Prepare the sides of the conjunctiva for the suture. Then, remove the conjunctival
213 retractor.

214
215 5.12. Suture the conjunctiva, using 6/0 polyglactin fiber.

216
217 5.13. Before closing, leave a space to insert into the subsclearal space, between the flap, the
218 choroid, and the choroidal autograft, a small flexible plastic tube with the autologous fat graft.

219
220 5.14. Saturate the residual space between the autologous fat graft, choroid, and scleral flaps
221 with 0.5 cc of SVF (rich of ADSCs), previously prepared in step 3.2, by a small flexible plastic
222 tube, inserted into the scleral pocket.

223
224 5.15. After saturating the residual space, close the suture.

225
226 5.16. After surgery, administer three days of antibiotic therapy with 500 mg azithromycin.
227 Also, provide eye-drop therapy with an antibiotic and steroid combination, such as
228 Chloramphenicol and Betamethasone, for about 15-20 days.

229
230 Note: An autograft made up of fat cells, ADSCs from SVF, and PRP has now been obtained²⁶.
231 Reduce the distance between the grafted autologous cells and choroid by deep sclerectomy
232 to stimulate paracrine secretion of autologous cells into the choroidal flow. For the same
233 purpose, expand the area of contact between the stalk and choroid.

234

REPRESENTATIVE RESULTS:

Using the procedure presented here, two groups of dry AMD-affected patients, with BCVA equal to or greater than 1 logarithm of the minimum angle of resolution (logMAR), were enrolled in the study. Group A, including 11 eyes of 11 patients, received suprachoroidal autologous graft by Limoli Retinal Restoration Technique (LRRT), whereas group B, including 14 eyes of 14 patients, was used as a control group.

Student's t-test and the chi square test were used to compare, respectively, mean age and gender distribution between the two study groups (**Table 2**). Statistical analyses and data visualization were performed before and after LRRT surgery.

A Wilcoxon-Mann-Whitney signed rank test was carried out to determine whether the pre- and post-treatment differences were significant. This non-parametric statistical hypothesis test was applied to compare two dependent samples when the population cannot be assumed to be normally distributed, as in this case. VA values were measured at each step of the analysis. Statistical significance was set at a p value <0.05 .

Eleven eyes (6 right and 5 left eyes) of 11 patients (7 male and 4 female) with the clinical diagnosis of dry AMD were examined in this study. Patient age ranged from 62 to 84 years, with a mean age of 71.5 years (± 3.8 SD).

Table 2 provides an overview of the clinical profiles of the patients treated with LRRT, and the average values recorded at 0 (T0), 90 (T90), and 180 (T180) days after surgery. Adverse effects were always reported to guarantee maximum safety. Mean values of intraocular pressure recorded at 0 (T0), 90 (T90), and 180 (T180) days after surgery did not record any significant change.

Results after LRRT surgery were as follows:

In group A, BCVA changed from 0.581 (T0) preoperatively to 0.504 at 90 days (T90), and to 0.376 logMAR at 180 days (T180) with a significant increase of 35.20% ($p<0.01$). In control group B, including 14 eyes of 14 patients, 7 males and 7 females, with a mean age of 80.4 years, SD ± 2.3 , BCVA changed from 0.573 (T0) to 0.587 (T90), and to 0.601 logMAR (T180) with a non-significant mean decrease of 4.72% (**Table 2**) (**Figure 3**). In group A, MY test increased significantly from 11.44 dB (T0) to 12.59 dB (T180) (+9.58%) (**Figure 4**), whereas there was no significant improvement in postoperative values in group B.

FIGURE AND TABLE LEGENDS:

Figure 1: Representation of suprachoroidal autologous graft. Growth factors (GFs) produced by adipose cells, platelet-rich plasma (PRP), and adipose-derived stem cells (ADSCs) reach the choroidal and retinal tissues through the retinal pigment epithelium (RPE).

Figure 2: Technical Procedure. Cannula and subsequent withdrawal of adipose tissue from the abdominal area (Panel A). The cannula moves subcutaneous fat with mild aspiration by aspirating fat cells into its own lumen (Panel B). After centrifugation, there are three-layers of adipose tissue: oil (high layer), homogeneous fat (intermediate layer), and blood fluid (lower layer) (Panel C). Observe the tube with blood immediately after centrifugation. There

are three layers: platelets poor plasma (PPP), platelets rich plasma (PRP), and erythrocytes (Panel D).

Figure 3: Best corrected visual acuity (BCVA) in dry age-related macular degeneration (AMD). Change in group A after suprachoroidal autologous graft by Limoli Retinal Restoration Technique (LRRT), and in the control group (Check), measured at time 0 (T0), 90 (T90), and 180 (T180) days.

Figure 4: Microperimetry (MY) in a patient of group A. Dry age-related macular degeneration (AMD) six months after Limoli Retinal Restoration Technique (LRRT). MY increased from 11.44 dB (T0) to 12.59 dB (T180) (+9.58%). Color scale from 0 to 36 in dB. Fixation stability: stable, relatively unstable, unstable.

Table 1: Inclusion and exclusion criteria for dry age-related macular degeneration (AMD) patients.

Table 2: Clinical profiles of patients examined in the study. Average values recorded before (T0), 90 (T90), and 180 (T180) days after cell autograft by Limoli Retinal Restoration Technique (LRRT) in all patients.

DISCUSSION:

The primary purpose of this study was to evaluate whether the suprachoroidal graft of adipocytes, ADSCs in SVF, and PRP could improve VA and retinal sensitivity in dry AMD-affected eyes over time. Another main objective was to demonstrate possible therapeutic effects of these cells, based on the recent literature, since several preclinical studies have suggested that GF-based therapy could be useful for patient care in several diseases.

In fact, some studies have shown that autologous human induced pluripotent stem cells (iPSC) could represent a cellular source for the graft, aimed at retinal pigment epithelium (RPE) regeneration in tissue replacement therapy for AMD^{18,19}. These cell sheets are generated as a monolayer which could express typical RPE markers and exhibit polarized GF secretion, showing phagocytotic ability, as well as gene-expression patterns similar to those of native RPE^{18,19}. Upon transplantation, autologous non-human primate iPSC-RPE cell sheets showed neither immune rejection nor tumor formation^{18,19}.

The present study presents some different characteristics. We analyzed directly in dry AMD-affected human eyes whether the suprachoroidal autograft cell can improve visual performance.

Besides, sovachoroidal graft of autologous cells according to LRRT has always proven to be safe. We have never registered sub-retinal neovascularization, macular edema, retinal detachment, or other retinal problems in the first-year post intervention. On the other hand, inappropriate surgical procedures can theoretically lead to perforation of the choroid with subsequent bleeding, but in our research no eye was damaged. However, it is possible to have sub-conjunctival hemorrhage that is usually reabsorbed within a few days and does not present again as a complication.

Recent studies have provided ample evidence of a significant increase in scotopic ERG values, BCVA and MY, at 90 and 180 days post autologous graft. However, the increase was greater if the retinal thickness average (RTA) recorded by SD-OCT was higher^{11,26}. It is believed that the surgically grafted cells can produce GFs in the surrounding tissue, choroid, and retina, and that they have neurotrophic and angiogenic properties, such as basic fibroblast growth factor (bFGF), vascular endothelial growth factor (VEGF), pigment-epithelium-derived factor (PEDF), interleukin (IL), macrophage colony-stimulating factor (M-CSF), granulocyte-macrophage colony-stimulating factor (GM-CSF), and placental growth factor (PIGF), while platelets produce platelet-derived growth factor (PDGF), platelet-derived angiogenesis factor (PDAF), *etc.*^{6,7,12,13,21}

Graft placement near the choroid is believed to allow the produced GFs to enter the choroidal flow, to reach the endothelial cell receptors, RPEs, Muller cells, photoreceptors, and finally to interact with them. In LRRT, the autologous grafted elements are useful, each in their own way, for regeneration. The fat cells produce bFGF, epidermal growth factor (EGF), insulin-like growth factor-1 (IGF-1), IL, transforming growth factor β (TGF- β), PEDF, and adiponectin²¹. The ADSCs produce bFGF, VEGF, M-CSF, GM-CSF, PIGF, TGF- β , hepatocyte growth factor (HGF), IGF-1, IL, and angiogenin^{6,7}. The platelets produce PDGF, IGF-1, TGF- β , VEGF, bFGF, EGF, PDAF, and thrombospondin (TSP)^{6,12}.

Some factors promote endothelial regeneration, and some stimulate ADSC proliferation, thus favoring both autologous fat and adipocyte survival, while others inhibit neovascular processes²²⁻²⁴. PEDF and bFGF favor photoreceptor survival, while EGF exerts its action on Müller cells by triggering endogenous bFGF transcription and stimulating ADSCs to increase their secretory activity^{25,27}. Though GFs are normally secreted by RPEs, this does not occur in atrophic maculopathy as a result of the RPE/choriocapillaris complex. Paracrine GF secretion by graft cells contributes to favoring photoreceptor and choriocapillaris survival²⁸.

Moreover, M-CSF, GM-CSF, and IL have anti-inflammatory and chemotactic effects on macrophages, which are involved in the elimination of intraretinal cell debris, a function that is physiologically carried out by RPEs²⁹⁻³⁰.

The cell types grafted behind the choroid can ensure constant GF secretion in the choroidal flow. GFs can arrive from the choroid to the retinal cells, interact with their membrane receptors, and finally activate an intracellular pathway. The presented data suggest that LRRT can increase choroidal perfusion and photoreceptor trophism not only through bFGF-receptor interactions, but also through stimulation by Müller cells, RPEs, and retinal photoreceptors. As a result, gene expression changes and the final antiapoptotic effect could explain the neuroenhancement. This cellular mechanism underlies the ability to increase visual performance, as highlighted in the clinical findings in the grafted group. In summary, LRRT could be useful to preserve the visual function of dry AMD-affected patients in the long term.

However, as we have demonstrated in previous studies, cone-rod ERG and rod ERG show a highly significant correlation with RTA, while this is not the case of cone ERG. This can be explained by the fact that fovea function appears to be compromised, although the macular volumes in dry AMD continues to be regular, at least in the initial stages²⁶. In this pathology, residual retinal trophism measured by RTA can be a prognostic criterion for LRRT treatment,

since better outcomes are more frequent in patients with RTA equal to or greater than 250 μm^2 . The available GF set could result in neuroenhancement, the extent of which is proportional to the presence of areas with greater cellularity, as recorded by electrical activity²⁶. At a later stage, poor tissue cellularity would not give the therapeutic effect that is sought after with the procedure, due to the scarce GF-membrane receptor interactions.

The next steps of this research will require the recruitment of a larger number of subjects with greater VA and central fixation by statistically assessing all the indispensable tests needed to confirm that the technique is valid and to study the biochemical effects. It can be argued that the increase in cell trophism is reflected in the cell visual activity, measured objectively by ERG, BCVA, and MY¹¹. GF-based therapy could provide an up-to-date, selective, safe, and reasonable treatment in ophthalmologic diseases.

DISCLOSURES:

Presented at ARVO 2015, May 3-7 – Denver, CO – USA.

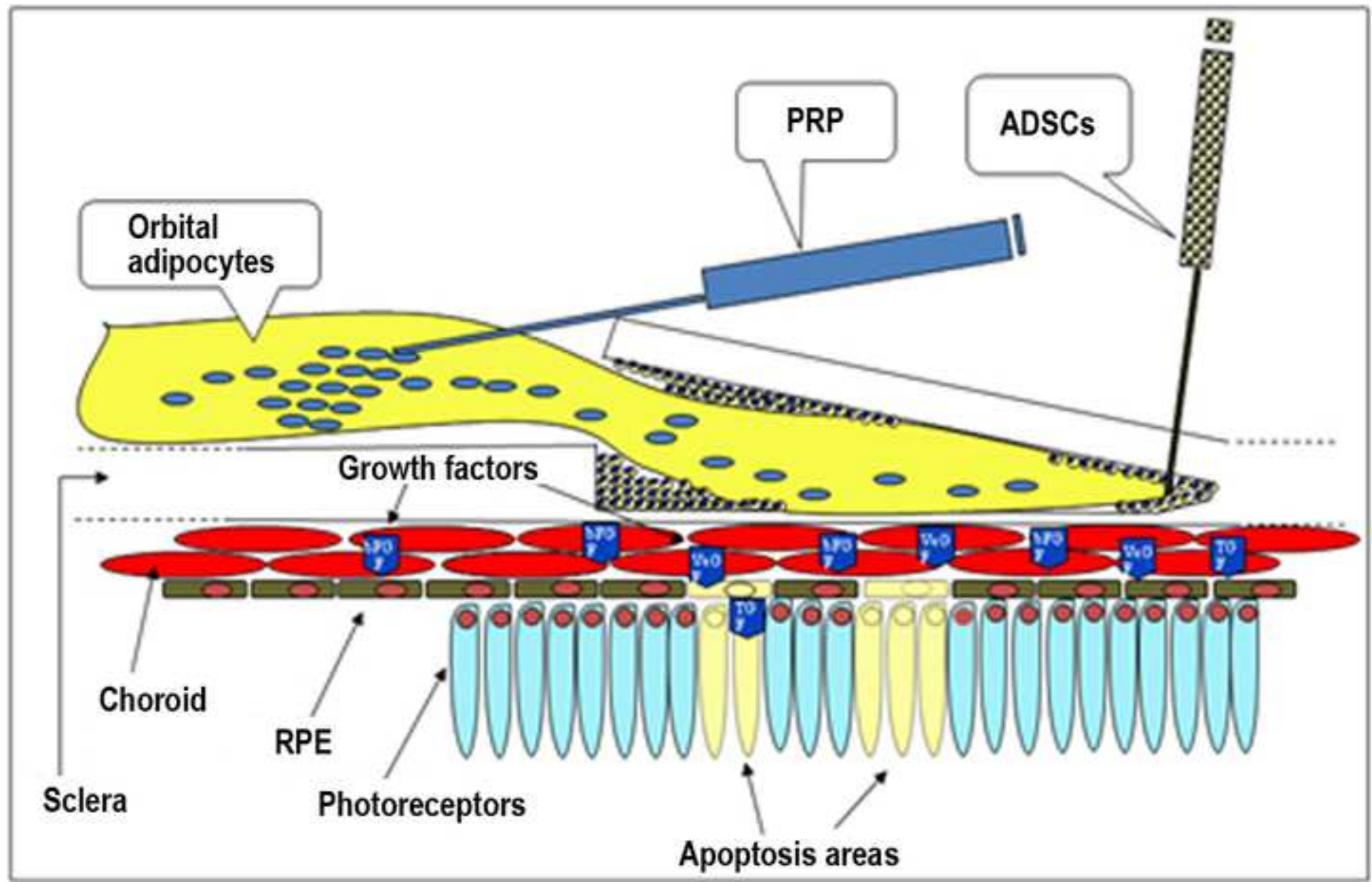
ACKNOWLEDGEMENTS:

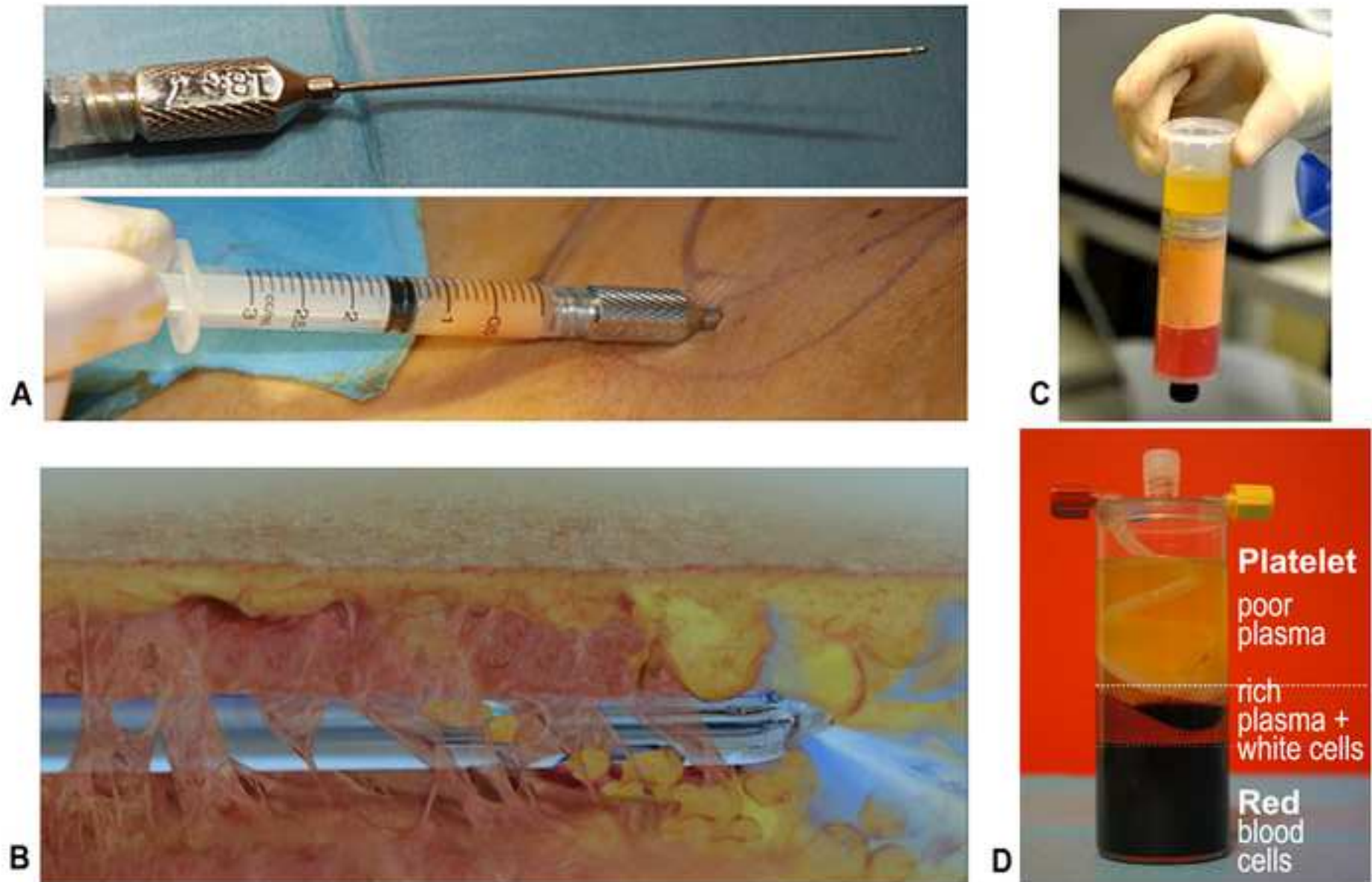
The authors have no acknowledgements.

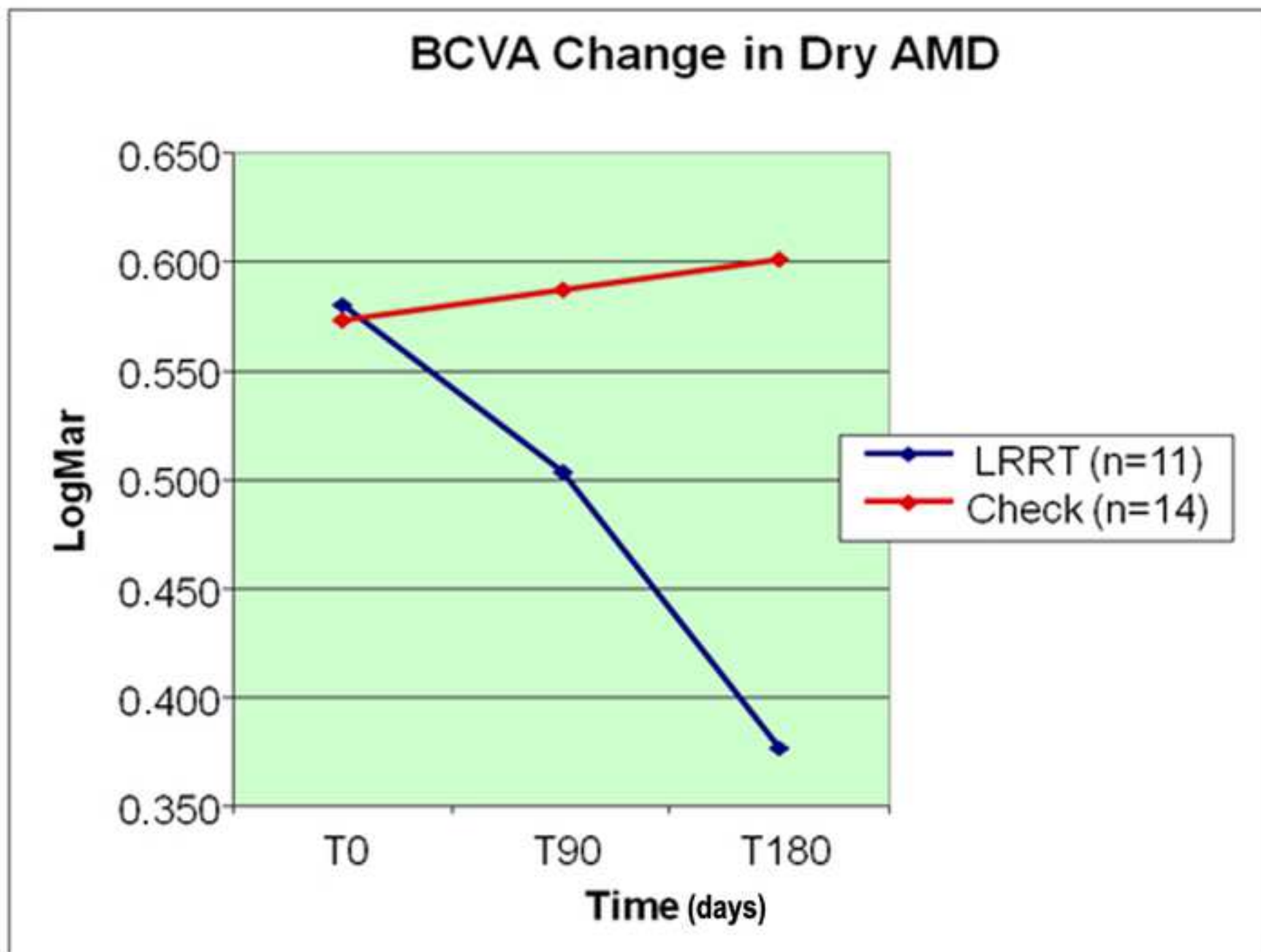
REFERENCES:

1. Daftarian, N., Kiani, S., Zahabi, A. Regenerative therapy for retinal disorders. *J. Ophthalmic Vis. Res.* **5**, 250–264 (2010).
2. Thanos, C., Emerich, D. Delivery of neurotrophic factors and therapeutic proteins for retinal diseases. *Expert. Opin. Biol. Ther.* **5**, 1443–1452, doi:10.1517/14712598.5.11.1443 (2005).
3. Cao, W., et al. *In vivo* protection of photoreceptors from light damage by pigment epithelium-derived factor. *Inv. Ophthalmol. Vis. Sci.* **42**, 1646–1652 (2001).
4. Bhutto, I., Lutty, G. Understanding age-related macular degeneration (AMD): Relationships between the photoreceptor/retinal pigment epithelium/Bruch's membrane/choriocapillaris complex. *Mol. Aspects Med.* **33** (4), 295–317, doi:10.1016/j.mam.2012.04.005 (2012).
5. McHarg, S., Brace, N., Bishop, P.N., Clark, S.J. Enrichment of Bruch's membrane from human donor eyes. *J. Vis. Exp* (105), doi:10.3791/53382 (2015).
6. Kevy, S.V., et al. Preparation of growth factor enriched autologous platelet gel. In: *Transactions of the Society for Biomaterials 27th Annual Meeting*. St. Paul, Minnesota, USA, April 24–29 (2001).
7. Schaffler, A., Buchler, C. Concise review: adipose tissue-derived stromal cells-basic and clinical implications for novel cell-based therapies. *Stem Cells.* **25**, 818–882, doi:10.1634/stemcells.2006-0589 (2007).
8. Filatov, V.P. Tissue therapy. *Med. Gen. Fr.* **11**, 3–5 (1951).
9. Pelaez, O. Retinitis pigmentosa. In: *Cuban experience. Editorial Científico Técnica*. La Habana, Cuba (1997).
10. Meduri, R., et al. Effect of basic fibroblast growth factor on the retinal degeneration of B6(A)-Rperd12/J (retinitis pigmentosa) mouse: a morphologic and ultrastructure study. *ARVO 2007 Annual Meeting*. Fort Lauderdale, May 6–10 (2007).
11. Limoli, P.G., Vingolo, E.M., Morales, M.U., Nebbioso, M., Limoli, C. Preliminary Study on Electrophysiological Changes After Cellular Autograft in Age-Related Macular Degeneration. *Medicine.* **93** (29), e355 December, doi:10.1097/MD.0000000000000355 (2014).

12. Tischler, M. Platelet rich plasma: The use of autologous growth factors to enhance bone and soft tissue grafts. *N. Y. State Dent. J.* **68**, 22 (2002).
13. Zuk, P.A., *et al.* Human adipose tissue is a source of multipotent stem cells. *Mol. Biol. Cell.* **13** (12), 4279–4295, doi:10.1091/mbc.E02-02-0105 (2002).
14. Lin, K.J., *et al.* Topical administration of orbital fat-derived stem cells promotes corneal tissue regeneration. *Stem Cell Res. Ther.* **4** (3), 72, doi:10.1186/scrt223 (2013).
15. Limoli, P. The retinal cell-neurorigeneration. Principles, applications and perspectives. In: *The growth factors*. FGE Reg. San Giovanni 40, Canelli (AT). 159-206 (2014).
16. Coleman, W.P., *et al.* Guidelines of care for liposuction. *J. Am. Acad. Dermatol.* **45**, 438–447, doi:10.1067/mjd.2001.117045 (2001).
17. Lawrence, N., Coleman, W.P. Liposuction. *J. Am. Acad. Dermatol.* **47**, 105-108 (2002).
18. Kamao, H., *et al.* Characterization of human induced pluripotent stem cell-derived retinal pigment epithelium cell sheets aiming for clinical application. *Stem Cell Reports.* **23** (2), 205-18, doi:10.1016/j.stemcr.2013.12.007 (2014).
19. Dang, Y., Zhang, C., Zhu, Y. Stem cell therapies for age-related macular degeneration: the past, present, and future. *Clin. Interv. Aging.* **10**, 255-264, doi:10.2147/CIA.S73705 (2015).
20. Nebbioso, M., Livani, M.L., Steigerwalt, R.D., Panetta, V., Rispoli, E. Retina in rheumatic diseases: Standard full field and multifocal electroretinography in hydroxychloroquine. *Clin. Exp. Optom.* **94** (3), 276–283, doi:10.1111/j.1444-0938.2010.00476.x (2011).
21. Wang, P., Mariman, E., Renes, J., Keijer, J. The secretory function of adipocytes in the physiology of white adipose tissue. *J. Cell. Physiol.* **216**, 3-13, doi:10.1002/jcp.21386 (2008).
22. Chen, G., *et al.* VEGF-Mediated Proliferation of Human Adipose Tissue-Derived Stem Cells. *PLoS One.* **8**, e73673, doi:10.1371/journal.pone.0073673 (2013).
23. Bagchi, M., *et al.* Vascular endothelial growth factor is important for brown adipose tissue development and maintenance. *FASEB J.* **27**, 3257-3271, doi:10.1096/fj.12-221812 (2013).
24. Carron, J.A., *et al.* Cultured human retinal pigment epithelial cells differentially express thrombospondin-1, -2, -3, and -4. *Int. J. Biochem. Cell. Biol.* **32**, 1137-1142 (2000).
25. Kim, S.Y., *et al.* Expression of pigment epithelium-derived factor (PEDF) and vascular endothelial growth factor (VEGF) in sickle cell retina and choroid. *Exp. Eye Res.* **77**, 433-445 (2003).
26. Limoli, P.G., Limoli, C., Vingolo, E.M., Scalinci, S.Z., Nebbioso, M. Cell surgery and growth factors in dry age-related macular degeneration: visual prognosis and morphological study. *Oncotarget.* **7** (30), 46913-46923, doi:10.18632/oncotarget.10442 (2016).
27. Ueki, Y., Reh, T.A. EGF stimulates Müller glial proliferation via a BMP-dependent mechanism. *Glia.* **61**, 778-789, doi:10.1002/glia.22472 (2013).
28. Kozlowski, M.R. RPE cell senescence: A key contributor to age-related macular degeneration. *Med. Hypotheses.* **78**, 505-510, doi:10.1016/j.mehy.2012.01.018 (2012).
29. Schneider, A., *et al.* The hematopoietic factor G-CSF is a neuronal ligand that counteracts programmed cell death and drives neurogenesis. *J. Clin. Invest.* **115**, 2083-2098, doi:10.1172/JCI23559 (2015).
30. Yin, Y., *et al.* Oncomodulin is a macrophage-derived signal for axon regeneration in retinal ganglion cells. *Nat. Neurosci.* **9**, 843-852, doi:10.1038/nn1701 (2006).







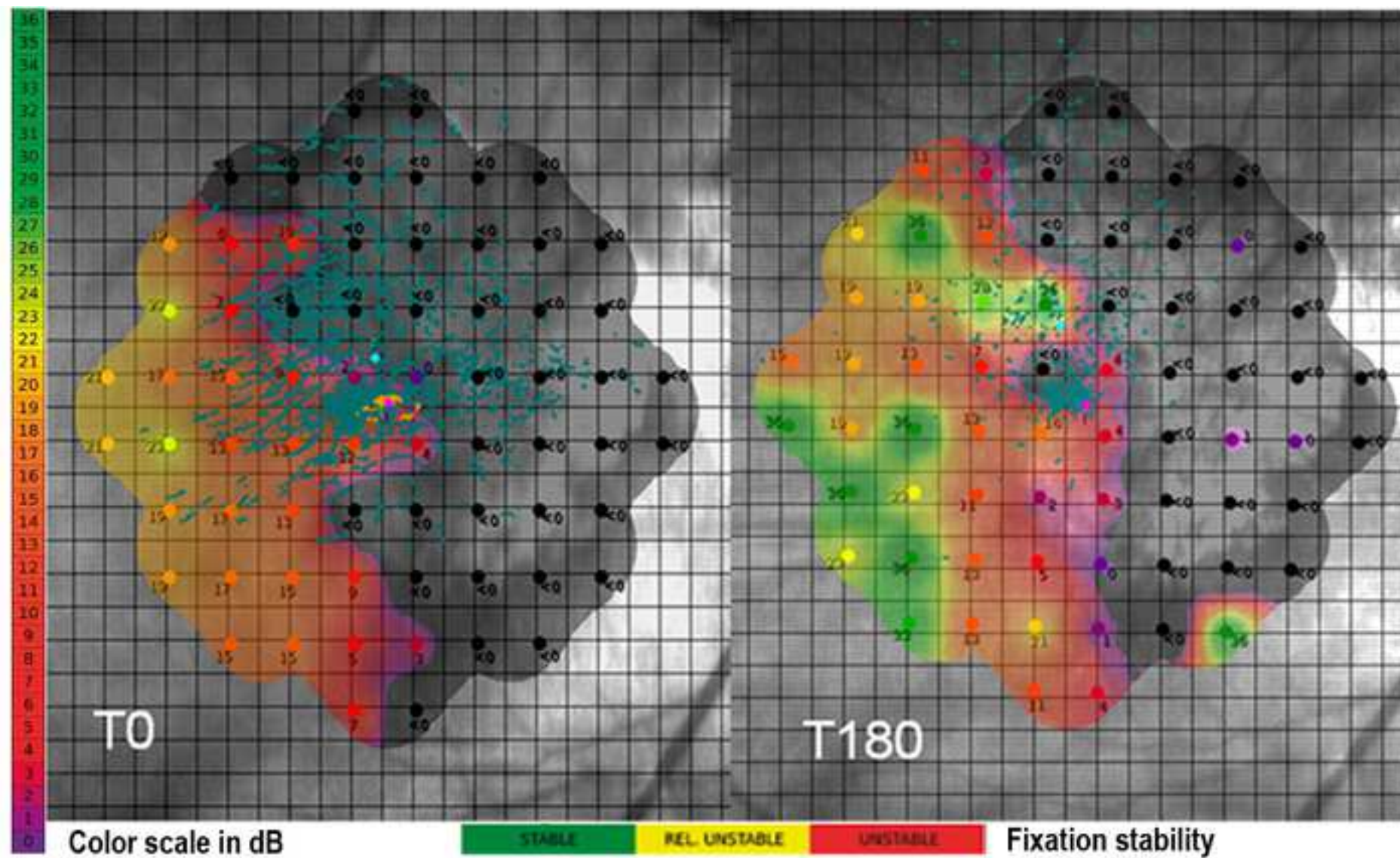


Table 1. Inclusion and exclusion criteria for dry age-related macular degeneration (AMD) patients.

Inclusion Criteria	Exclusion Criteria
Caucasian subjects	Refractive errors with spherical equivalent > 6 D
Well-nourished participants	Signs of exudative AMD by SD-OCT and FA
Diagnosis by SD-OCT, AFI, and FA	Ocular disorders: CT, GL, ON, MP, VM, CRD, <i>etc.</i>
Measurable VA	Ocular trauma
BCVA ≥ 1 logMAR	Systemic diseases: MS; PD; DM; RD; HD; vasculitis
Normal IOP	Hypertension, cancer, and other systemic diseases
Good storage extrafoveal areas	

LogMAR: logarithm of the minimum angle of resolution; SD-OCT: spectral domain-optical coherence tomography; AFI: autofluorescence imaging; FA: fluorescein angiography; VA: visual acuity; IOP: intraocular pressure; D: diopters; CT: cataract; GL: glaucoma; ON: optic neuritis; MP: macular pucker; VM: neovascular membranes; CRD: chorioretinal disease; MS: multiple sclerosis; PD: Parkinson disease; DM: diabetes mellitus; RD: renal diseases; HD: hepatic diseases.

Table 2. Clinical profiles of patients examined in the study.

Average values recorded before (T0), 90 (T90) and 180 (T180) days after cell autograft

PARAMETERS	LRRT (n=11)	Control (n=14)
Age (average)	71.5 ±3.8SD	80.4 ±2.3SD
Age (range)	62-84	73-9
Sex	F:4 M:7	F:7 M:7
BCVA T0	0.581 logMAR	0.573 logMAR
(average)		
BCVA T0 (range)	0.301-1.0	0.0-1.0
BCVA T90 (average)	0.504 logMAR	0.587 logMAR
BCVA T90 (range)	0.222-1	0.0-1
BCVA T180 (average)	0.376 logMAR	0.601 logMAR
BCVA T180 (range)	0.046-0.699	0.0-1.0
Percentage	35.19	4.72
change		
<i>p value</i>	<0.01	>0.5

Age in years; n=patients and controls; SD=standard deviation; F=female;

Table of Materials:			
Commercial products of materials, reagents, and statistical analysis in the treatment of dry age-related macular degeneration (AMD) patients.			
Name of Material/ Equipment	Company	Catalog Number	Comments/Description
Blunt cannula, 3 mm.	Mentor, Santa Barbara, CA.		
Luer-LokTM syringe.	BD Biosciences, Franklin Lakes, NJ.		
Regen-BCT tube.	RegenKit; RegenLab, Le Mont-sur-Lausanne, CH.		
Centrifuge	RegenPRP Centri. RegenLab, Le Mont-sur-Lausanne, CH.		
BD Venflon Pro Safety 22G x 1.00 inch (0.9 mm x 25 mm).	BD Biosciences, Franklin Lakes, NJ.		
SPSS Statistics Version 19.0	IBM Corp., Armonk, NY, USA.		
Confocal scanning laser ophthalmoscope	Nidek Inc, Fremont, CA	Nidek F10	
Cirrus 5000 Spectral Domain-Optical Coherence Tomography	Carl Zeiss Meditec AG, Jena, Germany	SD-OCT	
Maia 100809 Microperimetry	CenterVue S.p.A., Padua, Italy		
Ocular electrophysiology electromedical system,	C.S.O., S.r.l., Scandicci, Italy		Retimax for ERG



1 Alewife Center #200
Cambridge, MA 02140
tel. 617.945.9051
www.jove.com

ARTICLE AND VIDEO LICENSE AGREEMENT

Title of Article:

Regenerative therapy by cell suprachoroidal autograft in dry Age-related macular degeneration: preliminary report in vivo.

Author(s):

Limoli Giuseppe Paolo, Vingolo Enzo Maria, Limoli Celeste, Scalinci Sergio Zaccaria, Mele Luigi, Nebbioso Marcella.

Item 1 (check one box): The Author elects to have the Materials be made available (as described at <http://www.jove.com/author>) via: ☒ Standard Access ☐ Open Access

Item 2 (check one box):

- ☒ The Author is NOT a United States government employee.
- ☐ The Author is a United States government employee and the Materials were prepared in the course of his or her duties as a United States government employee.
- ☐ The Author is a United States government employee but the Materials were NOT prepared in the course of his or her duties as a United States government employee.

ARTICLE AND VIDEO LICENSE AGREEMENT

1. **Defined Terms.** As used in this Article and Video License Agreement, the following terms shall have the following meanings: “**Agreement**” means this Article and Video License Agreement; “**Article**” means the article specified on the last page of this Agreement, including any associated materials such as texts, figures, tables, artwork, abstracts, or summaries contained therein; “**Author**” means the author who is a signatory to this Agreement; “**Collective Work**” means a work, such as a periodical issue, anthology or encyclopedia, in which the Materials in their entirety in unmodified form, along with a number of other contributions, constituting separate and independent works in themselves, are assembled into a collective whole; “**CRC License**” means the Creative Commons Attribution-Non Commercial-No Derivs 3.0 Unported Agreement, the terms and conditions of which can be found at: <http://creativecommons.org/licenses/by-nc-nd/3.0/legalcode>; “**Derivative Work**” means a work based upon the Materials or upon the Materials and other pre-existing works, such as a translation, musical arrangement, dramatization, fictionalization, motion picture version, sound recording, art reproduction, abridgment, condensation, or any other form in which the Materials may be recast, transformed, or adapted; “**Institution**” means the institution, listed on the last page of this Agreement, by which the Author was employed at the time of the creation of the Materials; “**JoVE**” means MyJoVE Corporation, a Massachusetts corporation and the publisher of *The Journal of Visualized Experiments*; “**Materials**” means the Article and / or the Video; “**Parties**” means the Author and JoVE; “**Video**” means any video(s) made by the Author, alone or in conjunction with any other parties, or by JoVE or its affiliates or agents, individually or in collaboration with the Author or any other parties, incorporating all or any portion of the Article, and in which the Author may or may not appear.

2. **Background.** The Author, who is the author of the Article, in order to ensure the dissemination and protection of the Article, desires to have the JoVE publish the Article and create and transmit videos based on the Article. In furtherance of such goals, the Parties desire to memorialize in this Agreement the respective rights of each Party in and to the Article and the Video.

3. **Grant of Rights in Article.** In consideration of JoVE agreeing to publish the Article, the Author hereby grants to JoVE, subject to **Sections 4** and **7** below, the exclusive, royalty-free, perpetual (for the full term of copyright in the Article, including any extensions thereto) license (a) to publish, reproduce, distribute, display and store the Article in all forms, formats and media whether now known or hereafter developed (including without limitation in print, digital and electronic form) throughout the world, (b) to translate the Article into other languages, create adaptations, summaries or extracts of the Article or other Derivative Works (including, without limitation, the Video) or Collective Works based on all or any portion of the Article and exercise all of the rights set forth in (a) above in such translations, adaptations, summaries, extracts, Derivative Works or Collective Works and (c) to license others to do any or all of the above. The foregoing rights may be exercised in all media and formats, whether now known or hereafter devised, and include the right to make such modifications as are technically necessary to exercise the rights in other media and formats. If the “Open Access” box has been checked in **Item 1** above, JoVE and the Author hereby grant to the public all such rights in the Article as provided in, but subject to all limitations and requirements set forth in, the CRC License.

ARTICLE AND VIDEO LICENSE AGREEMENT

4. Retention of Rights in Article. Notwithstanding the exclusive license granted to JoVE in **Section 3** above, the Author shall, with respect to the Article, retain the non-exclusive right to use all or part of the Article for the non-commercial purpose of giving lectures, presentations or teaching classes, and to post a copy of the Article on the Institution's website or the Author's personal website, in each case provided that a link to the Article on the JoVE website is provided and notice of JoVE's copyright in the Article is included. All non-copyright intellectual property rights in and to the Article, such as patent rights, shall remain with the Author.

5. Grant of Rights in Video – Standard Access. This **Section 5** applies if the "Standard Access" box has been checked in **Item 1** above or if no box has been checked in **Item 1** above. In consideration of JoVE agreeing to produce, display or otherwise assist with the Video, the Author hereby acknowledges and agrees that, Subject to **Section 7** below, JoVE is and shall be the sole and exclusive owner of all rights of any nature, including, without limitation, all copyrights, in and to the Video. To the extent that, by law, the Author is deemed, now or at any time in the future, to have any rights of any nature in or to the Video, the Author hereby disclaims all such rights and transfers all such rights to JoVE.

6. Grant of Rights in Video – Open Access. This **Section 6** applies only if the "Open Access" box has been checked in **Item 1** above. In consideration of JoVE agreeing to produce, display or otherwise assist with the Video, the Author hereby grants to JoVE, subject to **Section 7** below, the exclusive, royalty-free, perpetual (for the full term of copyright in the Article, including any extensions thereto) license (a) to publish, reproduce, distribute, display and store the Video in all forms, formats and media whether now known or hereafter developed (including without limitation in print, digital and electronic form) throughout the world, (b) to translate the Video into other languages, create adaptations, summaries or extracts of the Video or other Derivative Works or Collective Works based on all or any portion of the Video and exercise all of the rights set forth in (a) above in such translations, adaptations, summaries, extracts, Derivative Works or Collective Works and (c) to license others to do any or all of the above. The foregoing rights may be exercised in all media and formats, whether now known or hereafter devised, and include the right to make such modifications as are technically necessary to exercise the rights in other media and formats. For any Video to which this Section 6 is applicable, JoVE and the Author hereby grant to the public all such rights in the Video as provided in, but subject to all limitations and requirements set forth in, the CRC License.

7. Government Employees. If the Author is a United States government employee and the Article was prepared in the course of his or her duties as a United States government employee, as indicated in **Item 2** above, and any of the licenses or grants granted by the Author hereunder exceed the scope of the 17 U.S.C. 403, then the rights granted hereunder shall be limited to the maximum rights permitted under such

statute. In such case, all provisions contained herein that are not in conflict with such statute shall remain in full force and effect, and all provisions contained herein that do so conflict shall be deemed to be amended so as to provide to JoVE the maximum rights permissible within such statute.

8. Likeness, Privacy, Personality. The Author hereby grants JoVE the right to use the Author's name, voice, likeness, picture, photograph, image, biography and performance in any way, commercial or otherwise, in connection with the Materials and the sale, promotion and distribution thereof. The Author hereby waives any and all rights he or she may have, relating to his or her appearance in the Video or otherwise relating to the Materials, under all applicable privacy, likeness, personality or similar laws.

9. Author Warranties. The Author represents and warrants that the Article is original, that it has not been published, that the copyright interest is owned by the Author (or, if more than one author is listed at the beginning of this Agreement, by such authors collectively) and has not been assigned, licensed, or otherwise transferred to any other party. The Author represents and warrants that the author(s) listed at the top of this Agreement are the only authors of the Materials. If more than one author is listed at the top of this Agreement and if any such author has not entered into a separate Article and Video License Agreement with JoVE relating to the Materials, the Author represents and warrants that the Author has been authorized by each of the other such authors to execute this Agreement on his or her behalf and to bind him or her with respect to the terms of this Agreement as if each of them had been a party hereto as an Author. The Author warrants that the use, reproduction, distribution, public or private performance or display, and/or modification of all or any portion of the Materials does not and will not violate, infringe and/or misappropriate the patent, trademark, intellectual property or other rights of any third party. The Author represents and warrants that it has and will continue to comply with all government, institutional and other regulations, including, without limitation all institutional, laboratory, hospital, ethical, human and animal treatment, privacy, and all other rules, regulations, laws, procedures or guidelines, applicable to the Materials, and that all research involving human and animal subjects has been approved by the Author's relevant institutional review board.

10. JoVE Discretion. If the Author requests the assistance of JoVE in producing the Video in the Author's facility, the Author shall ensure that the presence of JoVE employees, agents or independent contractors is in accordance with the relevant regulations of the Author's institution. If more than one author is listed at the beginning of this Agreement, JoVE may, in its sole discretion, elect not take any action with respect to the Article until such time as it has received complete, executed Article and Video License Agreements from each such author. JoVE reserves the right, in its absolute and sole discretion and without giving any reason therefore, to accept or decline any work submitted to JoVE. JoVE and its employees, agents and independent contractors shall have

ARTICLE AND VIDEO LICENSE AGREEMENT

full, unfettered access to the facilities of the Author or of the Author's institution as necessary to make the Video, whether actually published or not. JoVE has sole discretion as to the method of making and publishing the Materials, including, without limitation, to all decisions regarding editing, lighting, filming, timing of publication, if any, length, quality, content and the like.

11. **Indemnification.** The Author agrees to indemnify JoVE and/or its successors and assigns from and against any and all claims, costs, and expenses, including attorney's fees, arising out of any breach of any warranty or other representations contained herein. The Author further agrees to indemnify and hold harmless JoVE from and against any and all claims, costs, and expenses, including attorney's fees, resulting from the breach by the Author of any representation or warranty contained herein or from allegations or instances of violation of intellectual property rights, damage to the Author's or the Author's institution's facilities, fraud, libel, defamation, research, equipment, experiments, property damage, personal injury, violations of institutional, laboratory, hospital, ethical, human and animal treatment, privacy or other rules, regulations, laws, procedures or guidelines, liabilities and other losses or damages related in any way to the submission of work to JoVE, making of videos by JoVE, or publication in JoVE or elsewhere by JoVE. The Author shall be responsible for, and shall hold JoVE harmless from, damages caused by lack of sterilization, lack of cleanliness or by contamination due to the making of a video by JoVE its employees, agents or independent contractors. All sterilization, cleanliness or decontamination procedures shall be solely the responsibility of the Author and shall be undertaken at the Author's


expense. All indemnifications provided herein shall include JoVE's attorney's fees and costs related to said losses or damages. Such indemnification and holding harmless shall include such losses or damages incurred by, or in connection with, acts or omissions of JoVE, its employees, agents or independent contractors.

12. **Fees.** To cover the cost incurred for publication, JoVE must receive payment before production and publication the Materials. Payment is due in 21 days of invoice. Should the Materials not be published due to an editorial or production decision, these funds will be returned to the Author. Withdrawal by the Author of any submitted Materials after final peer review approval will result in a US\$1,200 fee to cover pre-production expenses incurred by JoVE. If payment is not received by the completion of filming, production and publication of the Materials will be suspended until payment is received.

13. **Transfer, Governing Law.** This Agreement may be assigned by JoVE and shall inure to the benefits of any of JoVE's successors and assignees. This Agreement shall be governed and construed by the internal laws of the Commonwealth of Massachusetts without giving effect to any conflict of law provision thereunder. This Agreement may be executed in counterparts, each of which shall be deemed an original, but all of which together shall be deemed to be one and the same agreement. A signed copy of this Agreement delivered by facsimile, e-mail or other means of electronic transmission shall be deemed to have the same legal effect as delivery of an original signed copy of this Agreement.

A signed copy of this document must be sent with all new submissions. Only one Agreement required per submission.

CORRESPONDING AUTHOR:

Name:	Nebbio Marcella	
Department:	Department of Sense Organs.	
Institution:	Sapienza University of Rome, Rome, Italy.	
Article Title:	Regenerative therapy by cell suprachoroidal autograft in dry Age-related macular degeneration: preliminary report in vivo.	
Signature:		Date: 24/04/2017

Please submit a signed and dated copy of this license by one of the following three methods:

- 1) Upload a scanned copy of the document as a pdf on the JoVE submission site;
- 2) Fax the document to +1.866.381.2236;
- 3) Mail the document to JoVE / Attn: JoVE Editorial / 1 Alewife Center #200 / Cambridge, MA 02139

For questions, please email submissions@jove.com or call +1.617.945.9051



Marcella Nebbioso, MD
Electrophysiology Ocular Center
Department of Sense Organs
Sapienza University of Rome, Italy



July 24, 2017

Dear Aditya Ambade,
Review Editor
[JoVE](#), 6176741888, PhD,
Journal of Visualized Experiments.

We are sending you the manuscript, 56469_R1_07102017, titled: ” **Regenerative therapy by suprachoroidal cell autograft in dry age-related macular degeneration: preliminary *in vivo* report**”, by Paolo Giuseppe Limoli, Enzo Maria Vingolo, Celeste Limoli, Sergio Zaccaria Scalinci, and Marcella Nebbioso that has been reviewed according to the Editor and Referees’ comments.

Changes made in response to comments of the reviewers are included at the bottom of this letter.

Many thanks and Best regards

Marcella Nebbioso & Co-Authors

[Address of Corresponding Authors](#)

Marcella Nebbioso, Department of Sense Organs, Ocular Electrophysiology Center, Policlinico Umberto I, Sapienza University of Rome, Rome, piazzale Aldo Moro 5, 00185, Italy.

e-mail: marcella.nebbioso@uniroma1.it Tel.: +39-06-49975422; Fax: +39-06-49975425.

COMMENTS TO AUTHORS

Editorial comments:

1) Editor modified the formatting of the manuscript and adjusted spacing of the protocol section. Please read the entire manuscript carefully and make changes if required. Do not change the formatting.

It was done.

2) Editor added track changes to the word document of your manuscript, attached to this email. Please approve/revise all track changes; however, do not accept the changes so that we can confirm the changes you made.

It was done.

3) Please add the information from Table 2 to Table of Materials and remove Table 2. Please use the attached Tables in .xlsx format.

It was done.