

JoVE: Science Education

Motor Exam Part I

--Manuscript Draft--

Manuscript Number:	10052
Full Title:	Motor Exam Part I
Article Type:	Manuscript
Section/Category:	Manuscript Submission
Corresponding Author:	Cynthia Brown UNITED STATES
Corresponding Author Secondary Information:	
Corresponding Author's Institution:	
Corresponding Author's Secondary Institution:	
First Author:	Cynthia Brown
First Author Secondary Information:	
Order of Authors:	Cynthia Brown
Order of Authors Secondary Information:	

Author Name: Cynthia Brown M.D.

Clinical Skills Education Title: Motor Exam Part I

Overview

Abnormalities in the motor function are associated with a wide range of diseases, from movement disorders to strokes. The motor assessment starts with observation of the patient. When the patient enters the examination area, the clinician observes their ability to walk unassisted and their speed and coordination while moving. Taking the patient's history provides an additional opportunity to observe for evidence of tremors or other abnormal movements, such as chorea or tardive dyskinesia. Such simple but important observations can yield valuable clues to the diagnosis and will help to focus the rest of the examination. The motor assessment continues in systematic fashion, including inspection for muscle atrophy and abnormal movements, assessment of muscle tone, muscle strength testing, and finally, the examination of the muscle reflexes and coordination. The careful systematic testing of the motor system and the integration of all the findings provide insight to the level at which the motor pathway is affected, and also help the clinician to formulate the differential diagnosis and to determine the course of the subsequent evaluation and treatment.

Procedure

1. Observation.

1.1 During the interview, observe the patient for any tremors or abnormal movements.

1.1.1 Are tremors occurring at rest, as is typical of Parkinson disease, or are they movements that might occur with essential tremor? Does the patient appear fidgety, or do they have choreiform movements? Is there a paucity of movement, as might be seen with Parkinsonian syndromes?

1.2 Evaluation of the muscle tone.

1.2.1 To test the muscle tone in the lower extremities, have the patient relax their legs while lying on the bed or examining table.

1.2.2 Place hands behind the patient's knee, lift their leg in a sudden motion, and observe if their heel drags along the bed. If there is an increased tone or spasticity, the foot may not make contact with the bed.

1.2.3 Another technique for assessing the muscle tone in the lower extremities is to support the patient's thigh with one hand, and while holding the foot with the other, alternately extend and flex the patient's knee and ankle.

1.2.4 To test for cogwheeling in the arms, tell the patient to relax. Distract the patient with questions or conversation, then place an index and middle finger over their biceps tendon, simultaneously extending and flexing the arm and rotating the wrist. A ratcheting sensation can be indicative of Parkinsonism.

2. Bulk and fasciculations.

2.1 Examine the patient's muscles for the signs of atrophy. Atrophy of the intrinsic hand muscles may be seen with normal aging. Atrophy of the intrinsic foot muscles, along with high arches and hammer toes, may be a sign of peripheral neuropathy.

2.2. Note the presence of fasciculations. Fasciculations can be elicited by either gently hitting the patient's muscles with finger pads or the small end of the reflex hammer.

3. Screening muscle testing.

There are two simple tests to help screen for motor weakness: observe the patient walking and test for pronator drift. These tests can help to determine any, even subtle, weakness.

3.1 To test for the pronator drift, tell the patient to raise their arms with palms up ("like catching raindrops or using your hands to hold out a tray"). In patients with true motor weakness, the weak arm is likely to pronate, flex at the elbow, and drift downwards. Cerebellar or parietal lesions can even result in an upwards or outwards drift, which may be confusing to an examiner. Non-physiologic weakness typically results in a "square drift" characterized by the arm falling perpendicularly down, usually occurring after a delay.

3.2 Observe the patient walking.

3.2.1 Ask the patient to walk back and forth.

3.2.2 Observe arm swinging for symmetry.

3.2.3 Watch stride for equal transit time and stride length, comparing sides.

3.2.4 Instruct the patient to walk on their heels which can demonstrate a foot drop.

3.2.5 Tell the patient to walk heel-to-toe ("like a tight-rope"), as tandem gait is a good test for cerebellar function.

4. Formal muscle testing.

When performing formal muscle testing, remember which spinal routes and nerves innervate each muscle (Figure 1). Standard muscle strength is measured on the scale from 0 to 5 (Table 1).

4.1 Examination of upper extremities. Test of strength in upper extremities is performed with the patient sitting.

4.1.1 Deltoid muscle is innervated by C5, the axillary nerve.

Starting with the deltoids, ask the patient to raise both their arms outward (abduction), while the examiner resists. Compare the two sides.

4.1.2 Biceps muscle is innervated by C5 and C6, the musculocutaneous nerve.

To test the biceps function (arm flexion at the elbow), tell the patient to flex their arm while the examiner resists.

4.1.3 Triceps muscle is innervated by C6 and C7, the radial nerve.

To test the triceps function (arm extension at the elbow), tell the patient to extend an arm, starting with a flexed position against the resistance of the examiner.

4.1.4 Wrist extensors are innervated by C6 and C7, the radial nerve.

To test wrist extensors, ask the patient to extend their right wrist while pushing down against the back of their hand. Repeat on the left side, and compare between the sides.

4.1.5 Finger grip is innervated by C7 and C8, median and ulnar nerves.

To test for grip strength, the patient should squeeze two of the examiner's fingers as hard as possible, while the examiner tries to remove their fingers from the patient's grasp. Test both sides simultaneously.

4.1.6 Finger abduction is innervated by C8 and T1, the ulnar nerve.

To test finger abduction, have the patient "fan out" (spread) all their fingers while the examiner tries to push them back together. Test both hands simultaneously, comparing between sides.

4.1.7 Thumb opposition is innervated by C8 and T1, the median nerve.

To test thumb opposition, have the patient touch the tip of their thumb to their pinky while the examiner attempts to pry their finger out with an index finger. The muscle controlling thumb opposition (opponens pollicis muscle) may be weak in patients with carpal tunnel syndrome.

4.2 Examination of the lower extremities. The lower extremities are tested in a supine position.

4.2.1 To test hip flexion (a function of the iliopsoas muscle innervated by L2, 3, 4, femoral nerve), ask the patient to raise their thigh while the examiner tries to push it down with their palm. Repeat on the other side and compare.

4.2.2 Hip adduction is innervated by L2, L3, L4, the obturator nerve.

To test hip adduction, tell patient to bring their knees together while the examiner has their hands between patient's knees and resists.

4.2.3 Hip abductors (gluteus medius and minimus muscles) are innervated by L4, L5, and S1, the superior gluteal nerve.

To test hip abduction, tell the patient to spread their knees apart while the examiner places their hands on the outside of the knees and resists the movement.

4.2.4 Hip extension (gluteus maximus) is innervated by L5, S1, S2, the inferior gluteal nerve.

Hip extension is tested as the patient lies on their back with a leg extended at the knee, with the examiner's hand under the lower leg. The patient then tries to press down against the examiner's hand.

4.2.5 Knee extension (quadriceps muscle) is innervated by L2, L3, L4, the femoral nerve.

Test knee extension by putting one hand under the patient's knee and the other on top of the patient's lower leg. Provide resistance while the patient attempts to extend the lower leg.

4.2.6 Knee flexion (hamstrings) is innervated by L5, S1, S2, the sciatic nerve.

Test knee flexion by placing one hand on the knee and the other under the ankle, and tell the patient to pull their leg in as hard as possible while resisting at the ankle.

4.2.7 Ankle dorsiflexion is innervated by L4, L5, the peroneal nerve.

To test ankle dorsiflexion, the examiner holds the top of the foot with their hand and tells the patient to pull their foot up toward their head as hard as possible, while the examiner resists to the movement.

4.2.8 Plantar flexion is innervated by S1, S2, the tibial nerve.

The examiner places a hand under the ball of the patient's foot and tells the patient to press down as hard as possible ("like stepping on the gas") against resistance.

Summary

Evaluation of the motor system starts with observation for abnormal movements, assessment of muscle bulk and tone, and the screening muscle exam prior to the systematic evaluation of

the muscle strength. The patient's history and the previous sections of the physical examination can provide the clinician with the diagnostic clues that help to look for specific findings on this part of the neurological exam. The presence of specific pathological signs, such as muscle atrophy, fasciculations, or abnormal muscle tone, also provides valuable diagnostic insight. Patterns of muscle weakness often help to formulate the differential diagnosis. Some examples include proximal muscle weakness that may suggest pathological process in muscles and specific distal distribution of weakness, which can be consistent with a stroke, a spinal cord lesion, or an injury to a peripheral nerve. Most importantly, to determine the level at which the pathological process has occurred, the clinician should remember which brain areas, nerve roots, and nerves control each muscle.

Figures and legends

Figure 1. Spinal nerves.

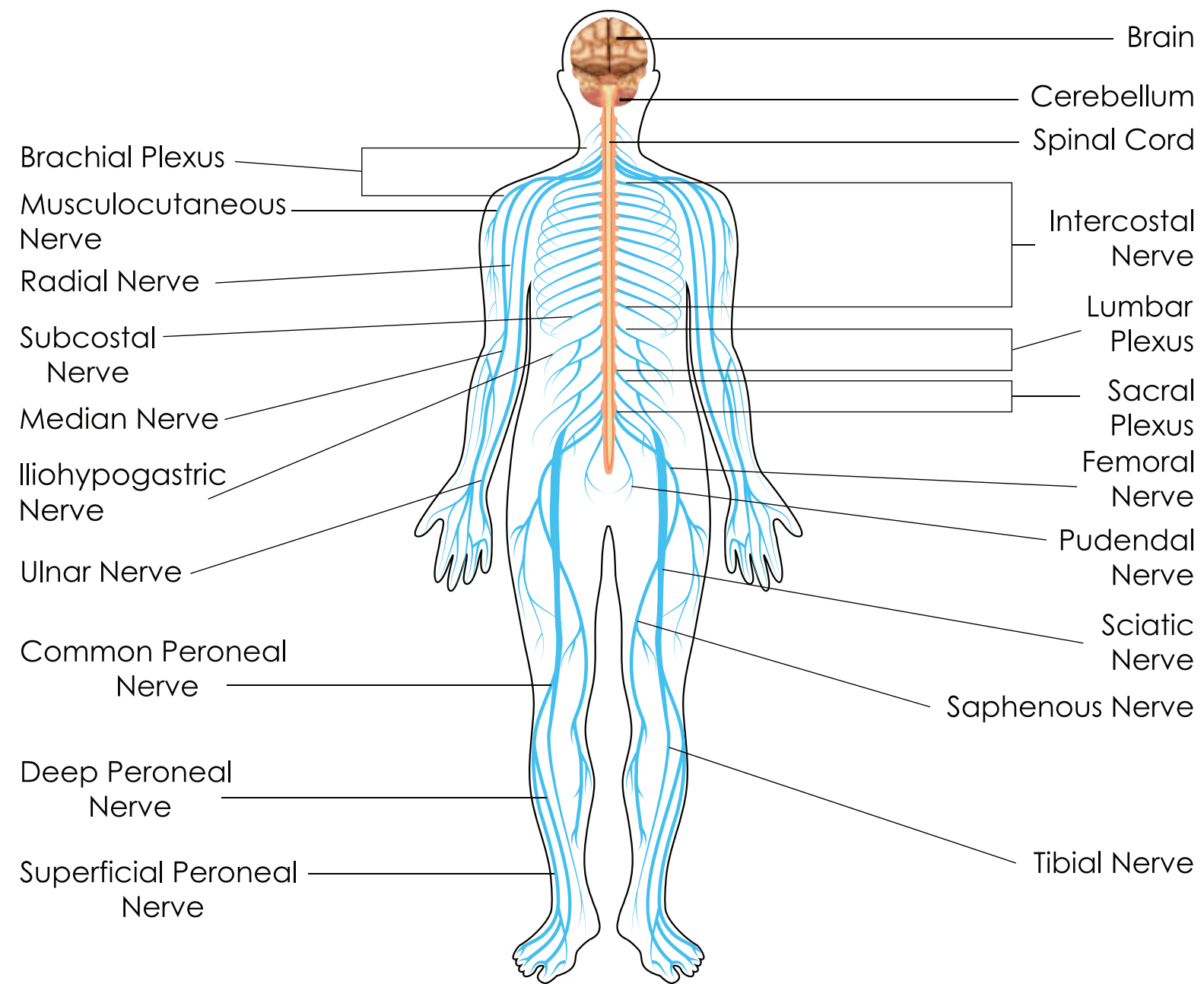
A drawing of the brain, spinal cord, and important spinal nerves.

Table 1. Muscle straight scale.

A table of the scoring system (from 0 to 5) used for describing muscle strength in clinical practice.

Table 1. Muscle strength scale

0	No contraction of muscles detected.
1	Trace contraction. May only be detected by palpation of muscle.
2	Muscle can actively be contracted and moved when gravity is eliminated.
3	Patient can overcome gravity but no resistance from examiner.
4	Patient has some strength against resistance from examiner.
5	Normal muscle strength with full resistance against examiner.



NERVOUS SYSTEM

Author Name: Cynthia Brown M.D.

Clinical Skills Education Title: Motor Exam Part I

Overview

Abnormalities in the motor function are associated with a wide range of diseases, from movement disorders to strokes. The motor assessment starts with observation of the patient. When the patient enters the examination area, the clinician observes their ability to walk unassisted and their speed and coordination while moving. Taking the patient’s history provides an additional opportunity to observe for evidence of tremors or other abnormal movements, such as chorea or tardive dyskinesia. Such simple but important observations can yield valuable clues to the diagnosis and helps to focus the rest of the examination. The motor assessment continues in the systematic fashion, including inspection for muscle atrophy and abnormal movements, assessment of muscle tone, muscle strength testing, and finally, the examination of the muscle reflexes and coordination. The careful systematic testing of the motor system and the integration of all the findings provide insight to the level at which the motor pathway is affected, and also help the clinician to formulate the differential diagnosis and to determine the course of the subsequent evaluation and treatment.

Procedure

1. Observation.

1.1 During the interview, observe the patient for any tremors or abnormal movements.

1.1.1 Are tremors occurring at rest, as is typical of Parkinson disease, or are they movements that might occur with essential tremor? Does the patient appear fidgety, or do they have choreiform movements? Is there a paucity of movement, as might be seen with Parkinsonian syndromes?

1.2 Evaluation of the muscle tone.

1.2.1 To test the muscle tone in the lower extremities, have the patient relax their legs while lying on the bed or examination table.

1.2.2 Place hands behind the patient’s knee, lift their leg in a sudden motion, and observe if their heel drags along the bed. If there is an increased tone or spasticity, the foot may not make contact with the bed.

Comment [JR1]: 10052 – Clinical Skills – Brown – Motor Exam

- In general, well written and great detail provided.
- Figure Usage/Clarity: The purpose of Fig. 1 is to highlight muscle innervations, although the main muscles examined are entirely unclear in the current reference (4.0). Perhaps it would be more helpful to include one figure for upper extremities and one for lower extremities?
 - Furthermore, the brief overview fails to mention the importance of the nervous system, i.e., top-down control to the muscle in order to assess the problem.
 - Table 1 provides a scale, but there is no mention of how the clinician records the information.
 - Procedure, Formatting of Protocol Text: Theory paragraphs are contained within protocol steps, especially in 4.1.
 - Writing style – Several instances lacking imperative tense, particularly in 4.1.

Comment [AS2]: As much as we would like to discuss the neuroanatomical aspects of the motor control, it is a big subject, so this is not possible due to the formatting limits and is beyond the scope of the project. Also, please note that this is just one manuscript in a big module on the neurological exam and the author feels that a general short sentence on importance of the nervous system in each manuscript wouldn’t enhance this content, however it is important to put the examination in the clinical context.

1.2.3 Another technique for assessing the muscle tone in the lower extremities is to support the patient's thigh with one hand, and while holding the foot with the other, alternately extend and flex the patient's knee and ankle.

1.2.4 To test for cogwheeling in the arms, tell the patient to relax. Distract the patient with questions or conversation, then place an index and middle finger over their biceps tendon, simultaneously extending and flexing the arm and rotating the wrist. A ratcheting sensation can be indicative of Parkinsonism.

2. Bulk and fasciculations.

2.1 Examine the patient's muscles for the signs of atrophy. Atrophy of the intrinsic hand muscles may be seen with normal aging. Atrophy of the intrinsic foot muscles, along with high arches and hammer toes, may be a sign of peripheral neuropathy.

2.2. Note the presence of fasciculations. Fasciculations can be elicited by either gently hitting the patient's muscles with finger pads or the small end of the reflex hammer.

3. Screening muscle testing.

There are two simple tests to help screen for motor weakness: observe the patient walking and test for pronator drift. These tests can help to determine any, even subtle, weakness.

3.1 To test for the pronator drift, tell the patient to raise their arms with palms up ("like catching raindrops or using your hands to hold out a tray"). In patients with true motor weakness, the weak arm is likely to pronate, flex at the elbow, and drift downwards. Cerebellar or parietal lesions can even result in an upwards or outwards drift, which may be confusing to an examiner. Non-physiologic weakness typically results in a "square drift" characterized by the arm falling perpendicularly down, usually occurring after a delay.

3.2 Observe the patient walking.

3.2.1 Ask the patient to walk back and forth.

3.2.2 Observe arm swinging for symmetry.

3.2.3 Watch stride for equal transit time and stride length, comparing sides.

3.2.4 Instruct the patient to walk on their heels, which can demonstrate a foot drop.

3.2.5 Tell the patient to walk heel-to-toe (“like a tight-rope”), as tandem gait is a good test for cerebellar function.

4. Formal muscle testing.

When performing formal muscle testing, remember which spinal routes and nerves innervate each muscle (Figure 1). During the examination, observe the patient performing the tests and assess the muscle strength on the scale from 0 to 5 (Table 1).

4.1 Examination of upper extremities. Perform the test of strength in upper extremities with the patient sitting.

4.1.1 Deltoid muscle is innervated by C5, the axillary nerve.

Starting with the deltoids, ask the patient to raise both their arms outward (abduction), while the examiner resists. Compare the two sides.

4.1.2 Biceps muscle is innervated by C5 and C6, the musculocutaneous nerve.

To test the biceps function (arm flexion at the elbow), tell the patient to flex their arm while the examiner resists.

4.1.3 Triceps muscle is innervated by C6 and C7, the radial nerve.

To test the triceps function (arm extension at the elbow), tell the patient to extend an arm, starting with a flexed position against the resistance of the examiner.

4.1.4 Wrist extensors are innervated by C6 and C7, the radial nerve.

To test wrist extensors, ask the patient to extend their right wrist while pushing down against the back of their hand. Repeat on the left side, and compare between the sides.

4.1.5 Finger grip is innervated by C7 and C8, median and ulnar nerves.

To test for grip strength, the patient should squeeze two of the examiner’s fingers as hard as possible, while the examiner tries to remove their fingers from the patient’s grasp. Test both sides simultaneously.

4.1.6 Finger abduction is innervated by C8 and T1, the ulnar nerve.

To test finger abduction, have the patient “fan out” (spread) all their fingers while the examiner tries to push them back together. Test both hands simultaneously, comparing between sides.

4.1.7 Thumb opposition is innervated by C8 and T1, the median nerve.

Formatted: Comment Text

Comment [AS3]: The reviewer suggest here to replace the figure 1 with two separate figures for the upper and lower extremities that show both the muscles and the nerves that innervates them. This is an excellent suggestion and a very valid point, but unfortunately we couldn’t find any figures that would meet those requirements. Figure 1 merely illustrates the basic anatomy of the nervous system.

Comment [AS4]: The muscle strength is recorded by the examiner in the patient’s records along with the other physical findings. We don’t discuss it here because patient’s write-up is beyond the scope of this project and we don’t discuss it in the videos.

Comment [AS5]: Changed to imperative tone

To test thumb opposition, have the patient touch the tip of their thumb to their pinky while the examiner attempts to pry their finger out with an index finger. The muscle controlling thumb opposition (opponens pollicis muscle) may be weak in patients with carpal tunnel syndrome.

4.2 Examination of the lower extremities. Test the lower extremities in a supine position.

4.2.1 To test hip flexion (a function of the iliopsoas muscle innervated by L2, 3, 4, femoral nerve), ask the patient to raise their thigh while the examiner tries to push it down with their palm. Repeat on the other side and compare.

4.2.2 Hip adduction is innervated by L2, L3, L4, the obturator nerve.

To test hip adduction, tell patient to bring their knees together while the examiner has their hands between patient's knees and resists.

4.2.3 Hip abductors (gluteus medius and minimus muscles) are innervated by L4, L5, and S1, the superior gluteal nerve.

To test hip abduction, tell the patient to spread their knees apart while the examiner places their hands on the outside of the knees and resists the movement.

4.2.4 Hip extension (gluteus maximus) is innervated by L5, S1, S2, the inferior gluteal nerve.

Test hip extension with the patient lying on their back with a leg extended at the knee, with the examiner's hand under the lower leg. The patient then tries to press down against the examiner's hand.

4.2.5 Knee extension (quadriceps muscle) is innervated by L2, L3, L4, the femoral nerve.

Test knee extension by putting one hand under the patient's knee and the other on top of the patient's lower leg. Provide resistance while the patient attempts to extend the lower leg.

4.2.6 Knee flexion (hamstrings) is innervated by L5, S1, S2, the sciatic nerve.

Test knee flexion by placing one hand on the knee and the other under the ankle, and tell the patient to pull their leg in as hard as possible while resisting at the ankle.

4.2.7 Ankle dorsiflexion is innervated by L4, L5, the peroneal nerve.

To test ankle dorsiflexion, hold the top of the patient's foot and tell the patient to pull their foot up toward their head as hard as possible, while the examiner resists to the movement.

4.2.8 Plantar flexion is innervated by S1, S2, the tibial nerve.

~~Place~~ The examiner places a hand under the ball of the patient's foot and tells the patient to press down as hard as possible ("like stepping on the gas") against resistance.

Comment [AS6]: Changed to imperative tone

Summary

Evaluation of the motor system starts with observation for abnormal movements, assessment of muscle bulk and tone, and the screening muscle exam prior to the systematic evaluation of the muscle strength. The patient's history and the previous sections of the physical examination can provide the clinician with the diagnostic clues that help to look for specific findings on this part of the neurological exam. The presence of specific pathological signs, such as muscle atrophy, fasciculations, or abnormal muscle tone, also provides valuable diagnostic insight. Patterns of muscle weakness often help to formulate the differential diagnosis. Some examples include proximal muscle weakness that may suggest pathological process in muscles and specific distal distribution of weakness, which can be consistent with a stroke, a spinal cord lesion, or an injury to a peripheral nerve. Most importantly, to determine the level at which the pathological process has occurred, the clinician should remember which brain areas, nerve roots, and nerves control each muscle.

Figures and legends

Figure 1. Spinal nerves.

A drawing of the brain, spinal cord, and important spinal nerves.

Table 1. Muscle straight scale.

A table of the scoring system (from 0 to 5) used for describing muscle strength in clinical practice.