

# Journal of Visualized Experiments

## Sequential Radial probe Endobronchial Ultrasound and Electromagnetic Navigation Bronchoscopy for the Diagnosis of Peripheral Pulmonary Lesions --Manuscript Draft--

<b>Manuscript Number:</b>	JoVE52608R3
<b>Full Title:</b>	Sequential Radial probe Endobronchial Ultrasound and Electromagnetic Navigation Bronchoscopy for the Diagnosis of Peripheral Pulmonary Lesions
<b>Article Type:</b>	Invited Methods Article - JoVE Produced Video
<b>Keywords:</b>	solitary pulmonary nodule; bronchoscopy; endobronchial ultrasound; electromagnetic navigation bronchoscopy; interventional pulmonology; peripheral pulmonary lesion
<b>Manuscript Classifications:</b>	3.4.588.894.797.520: Lung Neoplasms; 3.4.588.894.797.520.109: Bronchial Neoplasms; 5.1.370.386.105: Bronchoscopy; 5.1.370.388.250.100: Bronchoscopy; 5.4.800.250.100: Bronchoscopy; 5.4.928.600.80: Bronchoscopy
<b>Corresponding Author:</b>	Alex ChunMin Chee University of Calgary Calgary, Alberta CANADA
<b>Corresponding Author Secondary Information:</b>	
<b>Corresponding Author E-Mail:</b>	cheec@ucalgary.ca
<b>Corresponding Author's Institution:</b>	University of Calgary
<b>Corresponding Author's Secondary Institution:</b>	
<b>First Author:</b>	Alex ChunMin Chee
<b>First Author Secondary Information:</b>	
<b>Other Authors:</b>	Paul MacEachern Christopher Hergott Elaine Dumoulin Alain Tremblay
<b>Order of Authors Secondary Information:</b>	
<b>Abstract:</b>	Bronchoscopic diagnosis of peripheral pulmonary lesions remains a challenge for lung physicians. Advancements in ultrasound and electromagnetic guidance have improved the ability for clinicians to localize peripheral lesions despite the lack of direct visualization. Radial probe endobronchial ultrasound(pEBUS) and guide sheath aids the physician in confirming sampling tool placement. Electromagnetic navigation bronchoscopy (ENB) aids in peripheral lesion localization with a combination of electromagnetic tracking of navigation instruments and a steerable guidance probe. In patients who are not suitable candidates for surgical resection or percutaneous biopsy of peripheral lung lesions, endobronchial ultrasound and electromagnetic navigation bronchoscopy are useful tools in diagnosis. The localization rates of combined pEBUS and ENB are above 90% and the diagnostic yield is as high as 88%. We describe a technique for bronchoscopy using radial probe endobronchial ultrasound to localize and sample peripheral lung lesions with electromagnetic navigation bronchoscopy used as a navigation tool if necessary.
<b>Author Comments:</b>	
<b>Additional Information:</b>	
<b>Question</b>	<b>Response</b>
If this article needs to be "in-press" by a	

<p>certain date to satisfy grant requirements, please indicate the date below and explain in your cover letter.</p>	
<p>If this article needs to be filmed by a certain date to due to author/equipment/lab availability, please indicate the date below and explain in your cover letter.</p>	

**TITLE:**

Sequential Radial probe Endobronchial Ultrasound and Electromagnetic Navigation  
Bronchoscopy for the Diagnosis of Peripheral Pulmonary Lesions

**AUTHORS:**

Chee, Alex  
Division of Respiriology  
Department of Medicine  
University of Calgary  
Calgary, Canada  
[cheec@ucalgary.ca](mailto:cheec@ucalgary.ca)

MacEachern, Paul  
Division of Respiriology  
Department of Medicine  
University of Calgary  
Calgary, Canada  
[prmaceac@ucalgary.ca](mailto:prmaceac@ucalgary.ca)

Hergott, Christopher  
Division of Respiriology  
Department of Medicine  
University of Calgary  
Calgary, Canada  
[cah679@mail.usask.ca](mailto:cah679@mail.usask.ca)

Dumoulin, Elaine  
Division of Respiriology  
Department of Medicine  
University of Calgary  
Calgary, Canada  
[elaine.dumoulin@usherbrooke.ca](mailto:elaine.dumoulin@usherbrooke.ca)

Tremblay, Alain  
Division of Respiriology  
Department of Medicine  
University of Calgary  
Calgary, Canada  
[atrembla@ucalgary.ca](mailto:atrembla@ucalgary.ca)

**CORRESPONDING AUTHOR:**

Alex Chee, [cheec@ucalgary.ca](mailto:cheec@ucalgary.ca)

**KEYWORDS:**

solitary pulmonary nodule, bronchoscopy, endobronchial ultrasound, electromagnetic navigation bronchoscopy, interventional pulmonology, peripheral pulmonary lesion

#### **SHORT ABSTRACT:**

This protocol describes a technique for bronchoscopy using radial probe endobronchial ultrasound to localize and sample peripheral lung lesions with electromagnetic navigation bronchoscopy used as a navigation tool if needed.

#### **LONG ABSTRACT:**

Bronchoscopic diagnosis of peripheral pulmonary lesions remains a challenge for lung physicians. Advancements in ultrasound and electromagnetic guidance have improved the ability for clinicians to localize peripheral lesions despite the lack of direct visualization. Radial probe endobronchial ultrasound (pEBUS) and guide sheath aids the physician in confirming sampling tool placement. Electromagnetic navigation bronchoscopy (ENB) aids in peripheral lesion localization with a combination of electromagnetic tracking of navigation instruments and a steerable guidance probe. In patients who are not suitable candidates for surgical resection or percutaneous biopsy of peripheral lung lesions, endobronchial ultrasound and electromagnetic navigation bronchoscopy are useful tools in diagnosis. The localization rates of combined pEBUS and ENB have been reported above 90% and the diagnostic yield is as high as 88%. We describe a technique for bronchoscopy using radial probe endobronchial ultrasound to localize and sample peripheral lung lesions with electromagnetic navigation bronchoscopy used as a navigation tool if necessary.

#### **INTRODUCTION:**

Lung cancer is the greatest cause of cancer related death worldwide and early diagnosis has been shown to improve survival. Computed tomography(CT) screening has been shown to reduce lung-cancer mortality but in the discovery of peripheral lung nodules, there is a risk that patients with benign nodules are treated with unnecessary surgeries<sup>1</sup>. In patients where surgical resection of a nodule is high risk, alternative therapies are such as stereotactic body radiotherapy(SBRT)<sup>2</sup> are considered. However, biopsy of nodules is usually preferred prior to therapy<sup>3</sup>. Diagnostic biopsy of peripheral lung nodules remains a challenge for pulmonary physicians. Non-surgical biopsy options include transthoracic needle aspiration (TTNA), conventional bronchoscopy, or bronchoscopy with advanced imaging techniques such as radial probe endobronchial ultrasound (pEBUS) and electromagnetic navigation (ENB). TTNA has a high diagnostic sensitivity for lung cancer but when a lung nodule is separated from the pleural surface, there is an elevated risk of pneumothorax<sup>4</sup>. Conventional bronchoscopy has limited diagnostic yield for nodules < 2 cm<sup>5</sup>. Advanced bronchoscopic biopsy techniques have a higher diagnostic yield<sup>6</sup> but are limited to specialized centres with interventional pulmonology. Radial probe endobronchial ultrasound has an established record of success in confirming the location of peripheral pulmonary nodules. The radial probe, with a diameter of 1.7 mm, and guide sheath fit within the working channel of a bronchoscope. The probe emits a 20 MHz ultrasound pulse laterally and with rotation, is able to capture a 360° view around the ultrasound probe. This allows the bronchoscopist to interrogate peripheral airways and

differentiate normal lung tissue from a nodule. The guide sheath<sup>7</sup> allows the probe to be removed but the location preserved for lesion sampling.

Electromagnetic navigation bronchoscopy consists of three elements: A multi-planar reconstruction of Computed Tomography data, generation of an electromagnetic field around the patient, and a steerable electromagnetic navigation probe. Virtual bronchoscopy software is able to reconstruct a CT scan into multiple planar views and automatically perform airway segmentation to create a virtual airway for navigation. Electromagnetic tracking (EM) involves the generation of a low power electromagnetic field in a region of interest. Electromagnetic probes placed within this field detect EM field strength and are able to localize to the region of space specific to that field strength. The EM field is able to pass through objects, allowing probes to be localized within a patient. EM systems are able to identify the position of guidance probes within the thorax and, when combined with a steerable probe, can help the bronchoscopist navigate to peripheral lesions that are not visible under white light bronchoscopy.

Combined electromagnetic navigation bronchoscopy with radial probe endobronchial ultrasound has shown a diagnostic yield as high as 88%<sup>8</sup>. In the same study, pEBUS alone (69%) had a higher yield than ENB alone (59%) and the combination was higher than either alone. ENB is used to help localize the sampling instruments at the peripheral lung lesion and pEBUS is used to confirm guide sheath placement. Alternatively, the pEBUS probe can often be navigated to the peripheral lung lesion with careful CT pre-procedure planning with virtual bronchoscopy and still have a high diagnostic yield (80%)<sup>9</sup>. ENB can be used alone for the evaluation of nodules with a good sensitivity for malignancy<sup>10,11</sup>. One factor against the routine use of ENB for all peripheral lung lesions is the cost of the disposable ENB guidance catheter. Although ENB can be used prior to pEBUS, lesions can often be found using pEBUS alone and the cost of the disposable ENB probe can be spared. We have found that the pEBUS probe alone can localize peripheral lung lesions in up to 75% of cases and the addition of ENB after initial pEBUS attempts increases localization rates to over 90%<sup>6</sup>. Lung tissue can then be sampled through the extended working channel.

We aim to demonstrate bronchoscopy using radial probe EBUS and, if needed, electromagnetic navigation bronchoscopy to localize and biopsy peripheral lung lesions.

[Insert Table 1]

[Insert Table 2]

## **PROTOCOL:**

### **1) Pre-procedural Planning**

**1.1) Load the patient chest CT onto the ENB planning computer in digital imaging and communications in medicine (DICOM) format for virtual bronchoscopy procedure planning.**

1.2) Identify the lung lesion and using virtual bronchoscopy, plan the most direct route through airways to the lesion of interest.

1.2.1) Using the computer mouse, scroll through the axial, sagittal and coronal windows of the CT images to identify the lung lesion. Left-Click the crosshairs button in the left side of the screen then left-click the target lesion and select a name for the lesion in the upper right corner text box.

1.2.2) Using the mouse or other human interface device, steer the virtual bronchoscopy to the lesion from the trachea. The mouse scroll wheel will advance the virtual bronchoscopy image and the left-click will adjust the center of the image.

1.2.3) Starting from the trachea, attempt a virtual bronchoscopy to the lesion by following the airway segments in the most appropriate trajectory. If the lesion is not reached, then attempt different bifurcations of peripheral airways in an attempt to reach the lesion. Use the axial, sagittal and coronal views of the multi-planar CT for pathway correction.

Note: Alternatively, the ENB planning program will generate an automated pathway to the lung lesion to be followed. The virtual bronchoscopy map may be used in an attempt to navigate to the lung lesion with the pEBUS probe alone.

[Figure 1]

1.3) Once an ideal pathway is found to the lesion, save the planning file and export it to the ENB procedure system.

Note: Multiple pathways can be planned in the event that there are multiple airways leading to the lesion.

1.4) Use the ENB extended working channel as a guide sheath for the pEBUS probe and ENB probe. Measure and mark the biopsy tools to the length of the sheath prior to the procedure. Mark the biopsy forceps when it is extended through the sheath and able to open [Figure 2]. Mark the brush and needle when the hub is flush with the end of the guide sheath.

## 2) Bronchoscopy

2.1) On the day of the procedure, ensure that the patient remains a good candidate for bronchoscopy with transbronchial biopsy<sup>12</sup> under moderate sedation or general anesthesia. For moderate sedation, the patient should require no airway intervention, have adequate spontaneous breathing, maintain blood pressure and respond to verbal or tactile stimulation.<sup>13</sup>

2.2) Place a peripheral intravenous line and provide supplemental oxygen via nasal prongs or face mask.

2.3) Place the patient on a fluoroscopy bed with the electromagnetic field generator and monitor according to standard bronchoscopy guidelines<sup>12</sup> with pulse oximetry, cardiac telemetry and blood pressure monitoring.

2.4) Administer topical lidocaine to the nasopharynx and oropharynx. Achieve moderate sedation with intravenous medication. Give a combination of benzodiazepine and opiate in small aliquots (i.e. midazolam 1-2 mg IV, fentanyl 10-25 µg IV) and titrated to patient sedation. If general anesthesia is used, then defer to the anesthesiologist for sedation protocol.

2.5) After moderate intravenous sedation is administered, insert the bronchoscope through the nose or mouth into the trachea. Carry out standard visual inspection of the airways.

2.6) Using the pEBUS probe and extended working channel, attempt to localize the peripheral lung lesion with ultrasound image confirmation.

[Figure 3a/b].

2.6.1) Steer the bronchoscope into airway most suspected of containing the lung lesion.

2.6.2) Advance the EBUS probe through the bronchoscope working channel until it is in the area of interest.

2.6.3) On the EBUS module on the bronchoscopy cart, press the Ultrasound button to turn on EBUS. If the lesion is not visible in an airway, interrogate other airway subsegments with the EBUS probe by retracting the probe and inserting it into different airways. To prevent damage to the probe when moving from airway to airway, turn the Ultrasound off between airway segments.

2.6.4) If the lesion is identified with pEBUS, remove the probe (guide sheath kept in place) and sample the lesion using the pre-measured biopsy tools (see step 3). Obtain multiple passes from the same region by keeping the guide sheath in place while samples are taken.

2.7) If the lesion is not localized using pEBUS alone, then apply the ENB system. Place the three ENB registration markers on the patient torso, preferably one superiorly at the sternal notch or sternal angle and the others laterally at the level of the false ribs to measure maximal chest expansion with respiration.

Note: This can also be performed prior to the bronchoscopy and pEBUS procedure.

2.7.1) Turn the ENB system on and insert the USB key into the computer.

2.7.2) Select 'Procedure' on the main screen and enter the patient name, identification, and operator name, then click 'next'.

2.7.3) Verify that the three ENB registration markers are visible on the ENB screen as yellow dots within the square. If not, then move the markers so that they are spread out in the square but are still within the square. Click 'next' to start ENB probe registration.

2.8) Once the ENB probe is connected to the guidance system and placed through the working channel of the bronchoscope with the guide sheath, register the CT map to the position of the ENB probe within the patient.

2.8.1) Carry out registration by performing a repeat airway inspection, being careful to place the tip of the ENB probe into each visible airway segment. On the ENB system screen, the bronchoscope image will be projected with a yellow border. Once the system automatically registers the map, the border will turn green and a virtual bronchoscope image will appear next to the bronchoscope image.

Note: The ENB system matches the airway tree generated via airway inspection to the airway tree made from the CT airway segmentation.

2.8.2) Once the electromagnetic probe is registered with the CT planning file, commence nodule localization as described below. With the mouse, left-click the target name on the computer screen to select it as the ENB target.

Note: The ENB guidance system generates the airway route from the trachea to the peripheral lesion, though typically the first four generations of airways can be navigated using white-light bronchoscopy alone.

2.9) Once the electromagnetic probe and guide sheath are beyond the visibility of the bronchoscope, navigate the more peripheral airways using the guidance system and virtual bronchoscopy map.

Note: Virtual bronchoscopy is able to project an image of the airway subsegments that are not visible with regular bronchoscopy, and will improve the spatial orientation beyond the bronchoscope tip.

2.9.1) Use the instructions provided by the guidance system to choose the optimal airway to place or steer the ENB probe.

2.9.2) Use the information provided by the guidance system (such as current probe position in relation to the nodule and the distance from the probe tip to the nodule) to navigate to the nodule.

2.10) When the ENB system localizes within 1 cm of the nodule centre, verify the position with the radial EBUS probe.



2.10.1) Keep the guide sheath in place while the ENB probe is removed and replaced with the EBUS probe. Advance the EBUS probe to its pre-marked distance then turn the Ultrasound on.

Note: If localized, a nodule can be readily identified with the EBUS though ground glass opacities are more difficult to characterize(see step 2.6)<sup>14</sup>.

2.10.2) If the lesion is confirmed on EBUS, then remove the EBUS probe and commence biopsy. Otherwise, reinsert the ENB probe and redirect the sheath to an alternative location.

2.10.3) If the lesion cannot be confirmed on EBUS despite multiple attempts to adjust position with the steerable ENB probe, keep the guide sheath in place and perform a directed BAL(Step 3.4).

### 3) Biopsy Procedure

3.1) Remove the probe while the guide sheath is kept in place.

3.2) Pass the pre-measured biopsy forceps<sup>7,12</sup>, transbronchial needle, bronchial brush through the guide sheath to sample the lesion.

3.2.1) For biopsy forceps, insert the closed forceps into the sheath at the pre-measured depth.

3.2.1.1) Open the forceps, then retract the open forceps onto the sheath to ensure that they are open and outside the sheath.

3.2.1.2) Advance forceps about 1 cm until meeting resistance then close the forceps and pull them out of the sheath.

3.2.1.3) Open the forceps into a saline container to remove the sample, then repeat the step.

3.2.1.4) Once complete, transfer the biopsy samples from a saline container to formalin fixative with a syringe.

3.2.2) For a transbronchial needle, pass the needle to the pre-measured depth within the guide sheath.

3.2.2.1) Extend the needle then apply light suction on the syringe, confirming that there is resistance to suction.

3.2.2.2) Slowly move the needle several millimeters back and forth for several movements.

3.2.2.3) Discontinue syringe suction by letting go of the syringe plunger then retract the needle and remove the apparatus from the sheath.

3.2.2.4) To expel the sample, extend the needle onto a slide or liquid fixative and push 20cc of air from the syringe through the needle.

3.2.3) For a bronchial brush, insert the brush to the pre-measured depth within the guide sheath.

3.2.3.1) Extend the brush then slowly move the brush back and forth several millimeters for several passes.

3.2.3.2) Retract the brush then remove from the sheath.

3.2.3.3) To obtain the brush sample, either rub the brush onto a slide or cut the brush tip into liquid fixative for processing.

Note: If rapid on-site examination is not available, we recommend a minimum of four passes with the forceps and needle.

3.3) If there is suspicion of sheath movement during the sample procedure, reinsert the EBUS probe(see step 2.10.1) into the guide sheath to verify nodule visualization.

3.4) Perform a directed bronchoalveolar lavage (BAL) through the guide sheath using a 20 mL syringe with normal saline after the biopsies are obtained. Attached the syringe to the guide sheath, inject 20 mL of normal saline and then apply suction to the syringe in an attempt to retrieve the saline.

Note: If the directed BAL yields insufficient sample, then perform a conventional BAL<sup>12</sup> with 120 mL of normal saline through the working channel of the bronchoscope after the guide sheath is removed.

#### 4. Post-biopsy care

4.1) Use transthoracic ultrasound with a 12 MHz probe to rule out a pneumothorax immediately after the procedure<sup>15</sup>.

4.2) Carry out chest radiography one hour after the procedure if there is ongoing suspicion of a pneumothorax<sup>16</sup>.

4.3) Monitor the patient in a recovery area with nursing support for a minimum of two hours to ensure adequate alertness and return of the gag reflex prior to discharge.

#### **REPRESENTATIVE RESULTS:**

With the combined approach of pEBUS and ENB if needed, localisation rates of peripheral lung lesions is as high as 100%<sup>6</sup> with diagnostic yield as high as 88%<sup>8</sup>. There is a gap between localization rates and diagnostic yield that may be affected by sampling tools<sup>17</sup>. Pneumothorax

rates range between 0-10%<sup>8,17-20</sup>. Probe position relative to the nodule on pEBUS imaging<sup>21</sup> and the presence of an air bronchus sign on computed tomography increase diagnostic yield<sup>18</sup>. If the pEBUS probe is localized adjacent to the lesion, then there is a reduced diagnostic yield compared to the probe localizing within the lesion<sup>17</sup> [Table 2]. The risk of pulmonary hemorrhage is minimal and not significantly increased over conventional bronchoscopy.

**Figure 1:** Virtual Bronchoscopy screenshot. Axial (top left), sagittal (top right), coronal (bottom left) views of computed tomography with virtual bronchoscopic image of right mainstem bronchus (bottom right). The pathway with waypoints (blue dots) and target lesion (out of plane, green dot) are visible.

**Figure 2:** Measurement of biopsy forceps for guide sheath. The forceps are opened beyond the guide sheath and that length is marked on the shaft of the forceps probe.

**Figure 3.** Radial probe EBUS image of a) normal lung parenchyma and b) pulmonary nodule. Image courtesy of Dr. Alain Tremblay.

**Table 1:** Patient selection criteria for sequential radial probe endobronchial ultrasound and electromagnetic navigation bronchoscopy

**Table 2:** Representative results of technique<sup>17</sup>. EBUS – endobronchial ultrasound; ENB – electromagnetic navigation bronchoscopy; n.s. – not statistically significant.

## DISCUSSION:

The majority of peripheral pulmonary lesions can be localized with the sequential use of pEBUS and ENB if needed. The ENB system helps lesion localization even without the steerable probe. The virtual bronchoscopy system helps pre-procedural planning of airway navigation with the pEBUS probe and guide sheath. If the lesion is not identified with pEBUS alone, then the steerable EM probe increases the localization rate up to 18% over pEBUS alone<sup>17</sup>. There is a learning curve identified in the use of pEBUS and ENB<sup>22</sup>. Both modalities are considered interventional bronchoscopic techniques<sup>23</sup> and although there is no minimum number of procedures identified for competency in ENB, diagnostic success is likely to improve with experience. It is recommended that clinicians perform at least 40-50 supervised EBUS procedures prior to competency<sup>24</sup>.

A critical step within the protocol is the pre-bronchoscopy planning of navigation to the pulmonary lesion with virtual bronchoscopy. This will improve the ability to navigate to the lesion and confirm its position with EBUS<sup>9</sup>. Measurement and marking of the biopsy tools (forceps, needle, brush) in relation to the guide sheath length must be precise. If the biopsy forceps are measured too short, then the forceps will be opened inside the guide sheath and will not sample the lesion. If the tools are measured too long, then they may either sample tissue distal to the lesion or increase the risk of pneumothorax.

There are alternative methods when using pEBUS and ENB in lesion biopsy. ENB may be used prior to pEBUS for localization<sup>8</sup>. This order of technique may be considered when on pre-procedure virtual bronchoscopy it is noted that use of ENB is likely required. However this order of lesion sampling would increase the overall cost of the procedure since the disposable ENB probe is used for every case. Factors predicting the use of ENB include lack of air bronchus sign and nodule diameter. General anesthesia may limit patient movement during navigation and biopsy is associated with higher diagnostic yield<sup>6</sup>. Rapid on-site examination (ROSE), if available, may also improve diagnostic yield<sup>22,25,26</sup>. There is evidence that ROSE increases diagnostic yield both in conventional bronchoscopy as well as transbronchial needle aspiration of mediastinal lymph nodes<sup>27,28</sup>. The gap between localization rates and diagnosis rates is being approached with the investigation of newer sampling modalities. New sampling tools such as cryobiopsy<sup>29</sup> and optical frequency domain imaging<sup>30</sup> warrant further study.

For lesions that are non-diagnostic, clinical judgement must be used to determine the next course of action. Surgical biopsy, percutaneous CT-guided biopsy, repeat bronchoscopy and observation are all possible options that require careful consideration of patient factors and clinical suspicion.

#### **DISCLOSURES:**

The authors have no disclosures related to the content of this manuscript.

#### **ACKNOWLEDGEMENTS:**

The authors have no acknowledgements.

#### **REFERENCES:**

- 1 Aberle, D. R. *et al.* Reduced lung-cancer mortality with low-dose computed tomographic screening. *N Engl J Med* **365**, 395-409, doi: 10.1056/NEJMoa1102873 (2011).
- 2 Shirvani, S. M., Chang, J. Y. & Roth, J. A. Can stereotactic ablative radiotherapy in early stage lung cancers produce comparable success as surgery? *Thorac Surg Clin* **23**, 369-381, doi: 10.1016/j.thorsurg.2013.05.009 (2013).
- 3 Louie, A. V. *et al.* When is a Biopsy-proven Diagnosis Necessary before Stereotactic Ablative Radiotherapy for Lung Cancer? A Decision Analysis. *Chest*, doi: 10.1378/chest.13-2924 (2014).
- 4 Yeow, K. M. *et al.* Risk factors of pneumothorax and bleeding: multivariate analysis of 660 CT-guided coaxial cutting needle lung biopsies. *Chest* **126**, 748-754, doi: 10.1378/chest.126.3.748 (2004).
- 5 Gould, M. K. *et al.* Evaluation of patients with pulmonary nodules: when is it lung cancer?: ACCP evidence-based clinical practice guidelines (2nd edition). *Chest* **132**, 108S-130S, doi: 10.1378/chest.07-1353 (2007).
- 6 Gex, G. *et al.* Diagnostic yield and safety of electromagnetic navigation bronchoscopy for lung nodules: a systematic review and meta-analysis. *Respiration* **87**, 165-176, doi: 10.1159/000355710 (2014).

- 7 Kurimoto, N. *et al.* Endobronchial ultrasonography using a guide sheath increases the ability to diagnose peripheral pulmonary lesions endoscopically. *Chest* **126**, 959-965, doi: 10.1378/chest.126.3.959 (2004).
- 8 Eberhardt, R., Anantham, D., Ernst, A., Feller-Kopman, D. & Herth, F. Multimodality bronchoscopic diagnosis of peripheral lung lesions: a randomized controlled trial. *Am J Respir Crit Care Med* **176**, 36-41, doi: 10.1164/rccm.200612-1866OC (2007).
- 9 Ishida, T. *et al.* Virtual bronchoscopic navigation combined with endobronchial ultrasound to diagnose small peripheral pulmonary lesions: a randomised trial. *Thorax* **66**, 1072-1077, doi: 10.1136/thx.2010.145490 (2011).
- 10 Odrionic, S. I., Gildea, T. R. & Chute, D. J. Electromagnetic navigation bronchoscopy-guided fine needle aspiration for the diagnosis of lung lesions. *Diagn Cytopathol* **42**, 1045-1050, doi: 10.1002/dc.23164 (2014).
- 11 Loo, F. L., Halligan, A. M., Port, J. L. & Hoda, R. S. The emerging technique of electromagnetic navigation bronchoscopy-guided fine-needle aspiration of peripheral lung lesions: promising results in 50 lesions. *Cancer Cytopathol* **122**, 191-199, doi: 10.1002/cncy.21373 (2014).
- 12 Du Rand, I. A. *et al.* British Thoracic Society guideline for diagnostic flexible bronchoscopy in adults: accredited by NICE. *Thorax* **68 Suppl 1**, i1-i44, doi: 10.1136/thoraxjnl-2013-203618 (2013).
- 13 Non-Anesthesiologists., A. S. o. A. T. F. o. S. a. A. b. Practice guidelines for sedation and analgesia by non-anesthesiologists. **96**, 13 (2002).
- 14 Izumo, T., Sasada, S., Chavez, C. & Tsuchida, T. The diagnostic utility of endobronchial ultrasonography with a guide sheath and tomosynthesis images for ground glass opacity pulmonary lesions. *J Thorac Dis* **5**, 745-750, doi: 10.3978/j.issn.2072-1439.2013.11.30 (2013).
- 15 Lichtenstein, D., Mezière, G., Biderman, P. & Gepner, A. The "lung point": an ultrasound sign specific to pneumothorax. *Intensive Care Med* **26**, 1434-1440 (2000).
- 16 Izbicki, G. *et al.* Is routine chest radiography after transbronchial biopsy necessary?: A prospective study of 350 cases. *Chest* **129**, 1561-1564, doi: 10.1378/chest.129.6.1561 (2006).
- 17 Chee, A. *et al.* Diagnostic utility of peripheral endobronchial ultrasound with electromagnetic navigation bronchoscopy in peripheral lung nodules. *Respirology* **18**, 784-789, doi: 10.1111/resp.12085 (2013).
- 18 Seijo, L. M. *et al.* Diagnostic yield of electromagnetic navigation bronchoscopy is highly dependent on the presence of a Bronchus sign on CT imaging: results from a prospective study. *Chest* **138**, 1316-1321, doi: 10.1378/chest.09-2708 (2010).
- 19 Mahajan, A. K., Patel, S., Hogarth, D. K. & Wightman, R. Electromagnetic navigational bronchoscopy: an effective and safe approach to diagnose peripheral lung lesions unreachable by conventional bronchoscopy in high-risk patients. *J Bronchology Interv Pulmonol* **18**, 133-137, doi: 10.1097/LBR.0b013e318216cee6 (2011).
- 20 Huang, Y. *et al.* Transbronchial lung biopsy and pneumothorax. *J Thorac Dis* **6**, S443-447, doi: 10.3978/j.issn.2072-1439.2014.08.48 (2014).

- 21 Yamada, N. *et al.* Factors related to diagnostic yield of transbronchial biopsy using endobronchial ultrasonography with a guide sheath in small peripheral pulmonary lesions. *Chest* **132**, 603-608, doi: 10.1378/chest.07-0637 (2007).
- 22 Lamprecht, B. *et al.* Electromagnetic navigation bronchoscopy (ENB): Increasing diagnostic yield. *Respir Med* **106**, 710-715, doi: 10.1016/j.rmed.2012.02.002 (2012).
- 23 Du Rand, I. A. *et al.* British Thoracic Society guideline for advanced diagnostic and therapeutic flexible bronchoscopy in adults. *Thorax* **66 Suppl 3**, iii1-21, doi: 10.1136/thoraxjnl-2011-200713 (2011).
- 24 Bolliger, C. T. *et al.* ERS/ATS statement on interventional pulmonology. European Respiratory Society/American Thoracic Society. *Eur Respir J* **19**, 356-373 (2002).
- 25 Lamprecht, B., Porsch, P., Pirich, C. & Studnicka, M. Electromagnetic navigation bronchoscopy in combination with PET-CT and rapid on-site cytopathologic examination for diagnosis of peripheral lung lesions. *Lung* **187**, 55-59, doi: 10.1007/s00408-008-9120-8 (2009).
- 26 Karnak, D. *et al.* Rapid on-site evaluation and low registration error enhance the success of electromagnetic navigation bronchoscopy. *Ann Thorac Med* **8**, 28-32, doi: 10.4103/1817-1737.105716 (2013).
- 27 Uchida, J. *et al.* Improved diagnostic efficacy by rapid cytology test in fluoroscopy-guided bronchoscopy. *J Thorac Oncol* **1**, 314-318 (2006).
- 28 Bruno, P. *et al.* Efficacy and cost effectiveness of rapid on site examination (ROSE) in management of patients with mediastinal lymphadenopathies. *Eur Rev Med Pharmacol Sci* **17**, 1517-1522 (2013).
- 29 Schuhmann, M. *et al.* Endobronchial ultrasound-guided cryobiopsies in peripheral pulmonary lesions: a feasibility study. *Eur Respir J* **43**, 233-239, doi: 10.1183/09031936.00011313 (2014).
- 30 Tan, K. M. *et al.* Flexible transbronchial optical frequency domain imaging smart needle for biopsy guidance. *Biomed Opt Express* **3**, 1947-1954, doi: 10.1364/BOE.3.001947 (2012).

Figure1  
[Click here to download high resolution image](#)

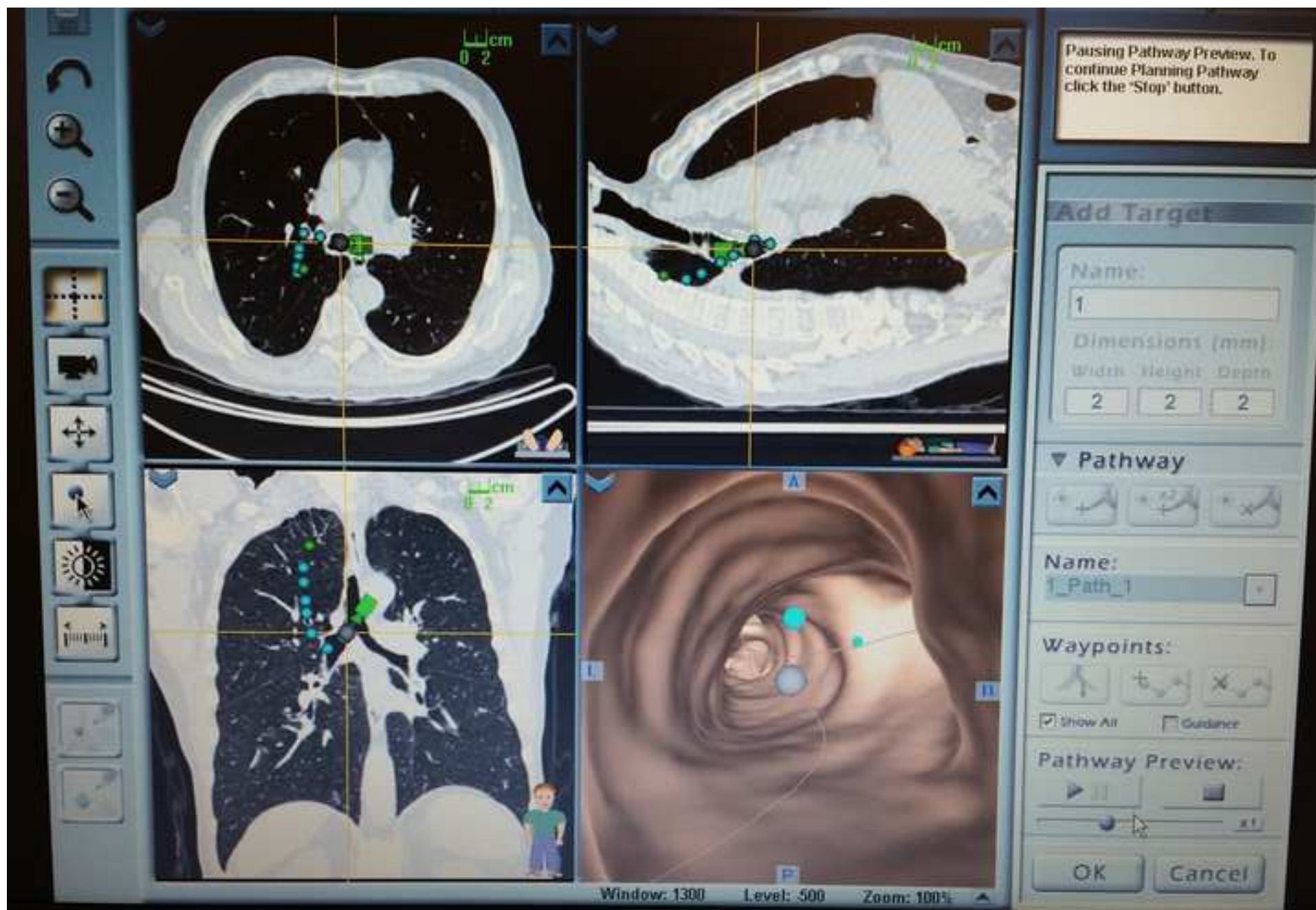



Figure2

[Click here to download high resolution image](#)

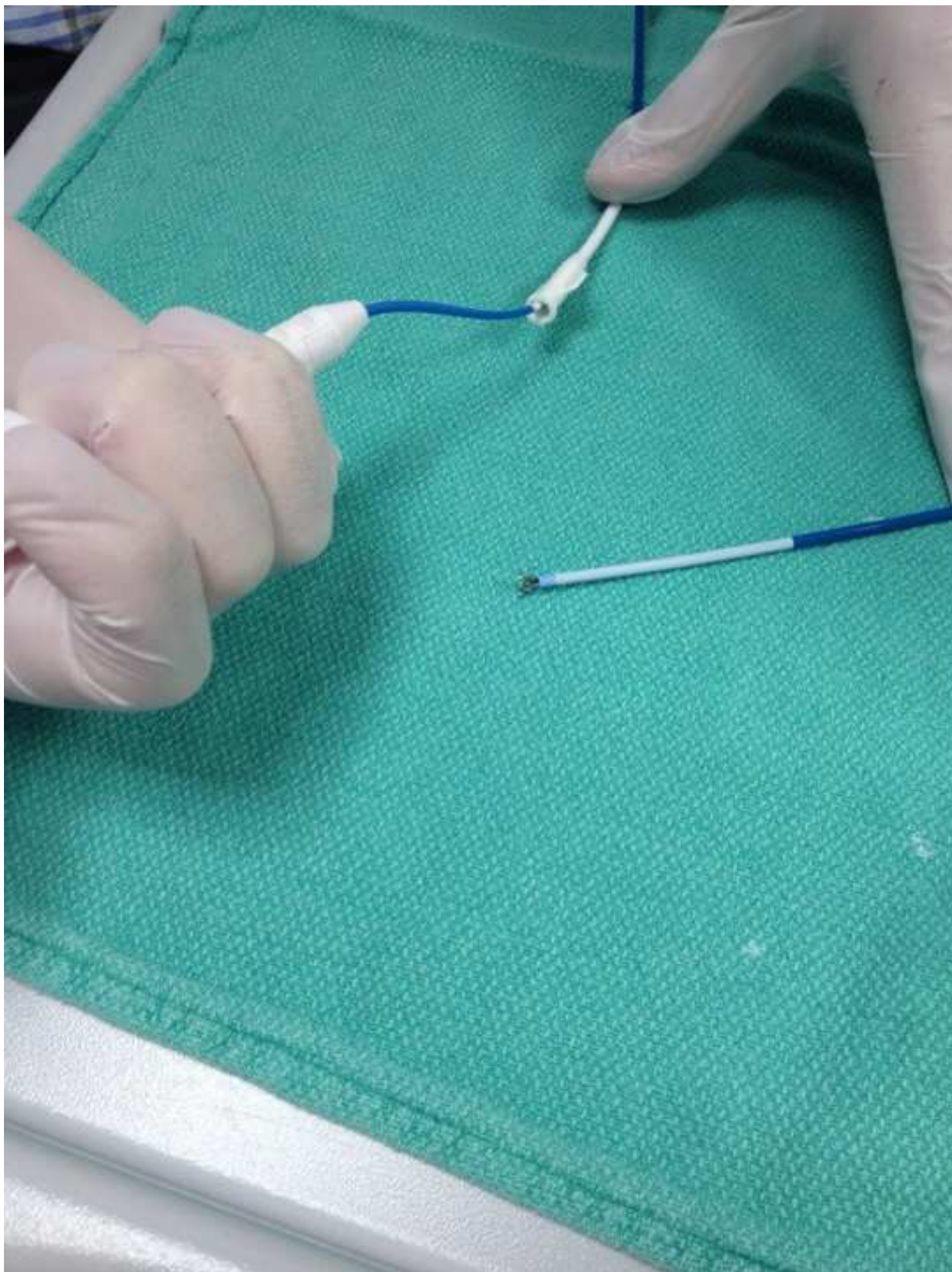



Figure3a  
[Click here to download high resolution image](#)

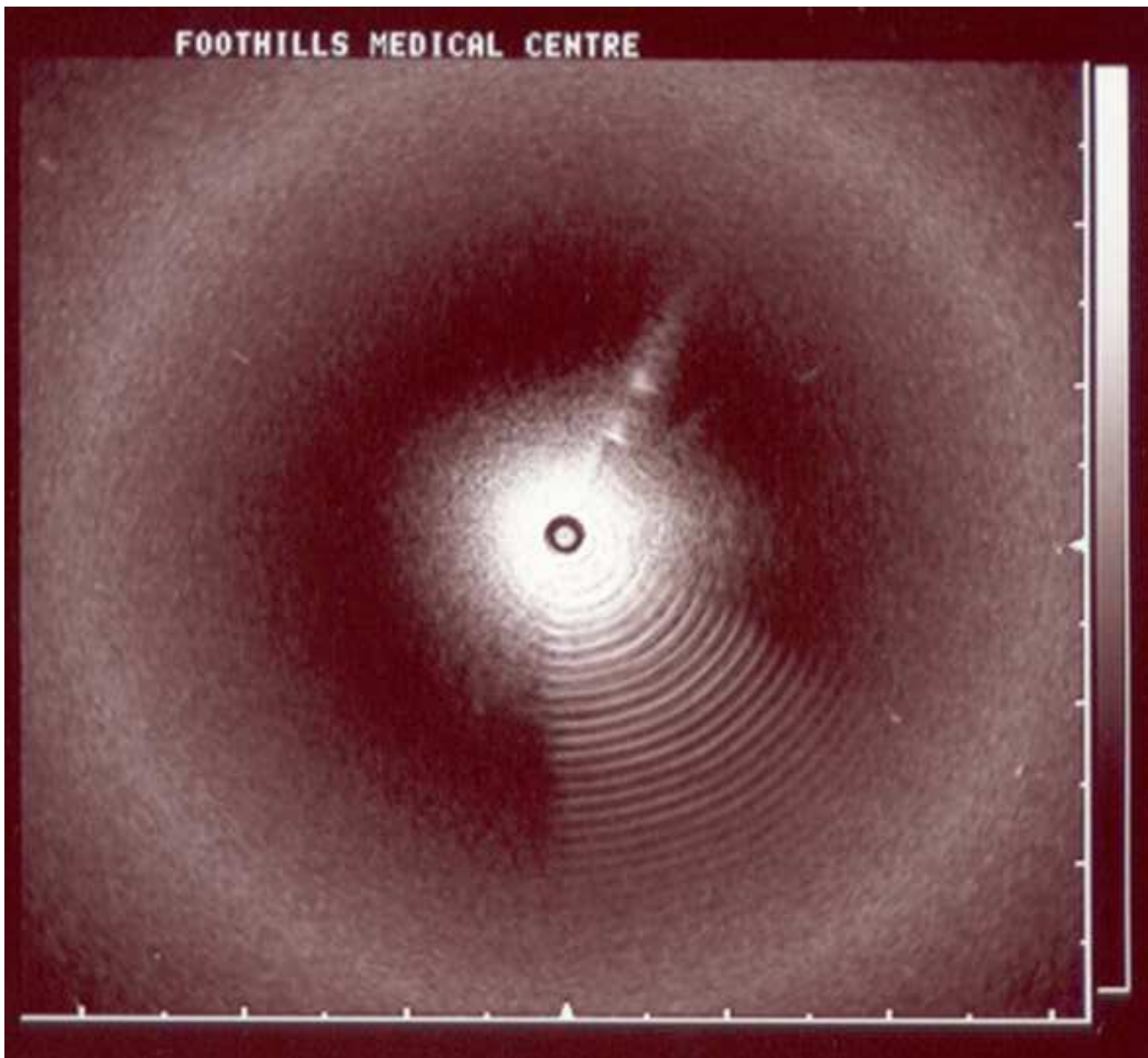


Figure3b  
[Click here to download high resolution image](#)

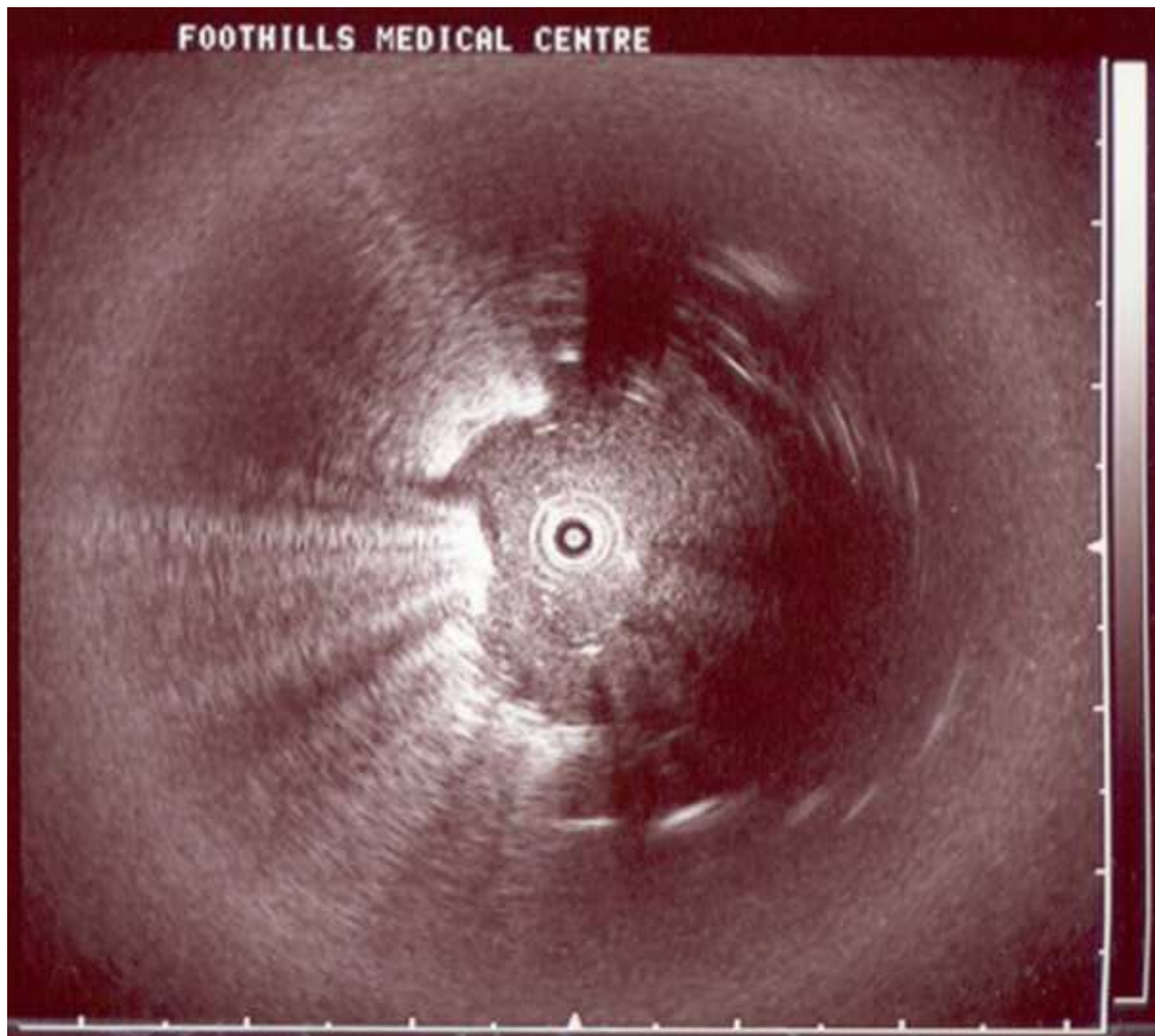

Table 1: Patient Selection

Inclusion Criteria
Age over 16 years Lung nodule(s) identified on Computed Tomography Clinical decision to obtain a tissue biopsy of lung lesion CT-guided biopsy not the preferred technique
Exclusion Criteria
Lack of informed consent for procedure Suggestion of an endobronchial lesion or centrally located lesion (peripheral ultrasound not necessary) Implanted electronic medical device Uncontrolled coagulopathy Medical contraindication to bronchoscopy

Table 2: Diagnostic Yield According to lesion characteristics

	Study cohort
Total	60
Lesion localized	56/60
Overall Yield: +result/total (%) Adjusted Yield (%) (n.s. vs. pEBUS ENB)	30/60 (50)
Tsuboi Classification: +result/total (%) 1 (air bronchus within lesion) 2 (air bronchus through lesion) 3 (air bronchus adjacent to lesion) No air bronchus visible Air Bronchus Sign – Tsuboi 1 & 2 (%)	14/25 (56) 7/14 (50) 7/14 (50) 2/7 (29) 21/39 (54)
EBUS image: +result/total (%) Within lesion Adjacent to lesion No lesion visualized	21/33 (64)* 9/23 (39) 0/4 (0)

pEBUS alone
45
45/60
26/45 (58)
26/60 (43)
13/22 (59)
7/12 (58)
4/8 (50)
2/3 (67)
20/34 (59)
20/31 (65)
6/14 (43)
N/A

pEBUS + ENB
15
15-Nov
4/15 (27)
1/3 (33) 0/2 (0) 3/6 (50) 0/4 (0) 1/5 (20)
1/2 (50) 3/9 (33) 0/4 (0)

Name of Material/Equipment
Electromagnetic Navigation Bronchoscopy system
Radial Probe Endobronchial Ultrasound System
1.9mm radial EBUS probe
Bronchoscopic biopsy tools[brush, forceps, transbronchial needle]
High Definition video Bronchoscope (minimum working channel diameter 2.8mm)
Intravenous catheter
Normal saline for IV flush
Sedation Medication
Topical Anesthesia (lidocaine hydrochloride)
Bronchoscopy suite with oxygen and cardiac monitoring and appropriate support staff
High-resolution CT chest (slice thickness <1.25mm, overlap 0.75mm)

Company	Comments
---------	----------

SuperDimension iLogic, Covidien, MN, USA	
--	--

Olympus, Tokyo, Japan	
-----------------------	--

Olympus, Tokyo, Japan	
-----------------------	--

Olympus, Tokyo, Japan	
-----------------------	--

Olympus, Tokyo, Japan	
-----------------------	--

Baxter Intern 20 guage or larger	
----------------------------------	--

Baxter International	
----------------------	--

Various	Generic drug, requires hospital approval for use
---------	--

	Generic drug, requires hospital approval for use
--	--

General Elect	There exist a number of equivalent CT scanners for use
---------------	--





1 Alewife Center #200  
Cambridge, MA 02140  
tel. 617.945.9051  
www.jove.com

## ARTICLE AND VIDEO LICENSE AGREEMENT

Manuscript #:

Title of Article:

Author(s):

Item 1 (check one box): The Author elects to have the Materials be made available (as described at

http://www.jove.com/publish ) via: ☒ Standard Access ☐ Open Access

Item 2 (check one box):

☒ The Author is NOT a United States government employee.

The Author is a United States government employee and the Materials were prepared in the course of his or her duties as a United States government employee.

The Author is a United States government employee but the Materials were NOT prepared in the course of his or her duties as a United States government employee.

### ARTICLE AND VIDEO LICENSE AGREEMENT

1. **Defined Terms.** As used in this Article and Video License Agreement, the following terms shall have the following meanings: "Agreement" means this Article and Video License Agreement; "Article" means the article specified on the last page of this Agreement, including any associated materials such as texts, figures, tables, artwork, abstracts, or summaries contained therein; "Author" means the author who is a signatory to this Agreement; "Collective Work" means a work, such as a periodical issue, anthology or encyclopedia, in which the Materials in their entirety in unmodified form, along with a number of other contributions, constituting separate and independent works in themselves, are assembled into a collective whole; "Creative Commons License" means the Creative Commons Attribution-Non Commercial-No Derivs 3.0 Unported Agreement, the terms and conditions of which can be found at:

<http://creativecommons.org/licenses/by-nc-nd/3.0/legalcode>; "Derivative Work" means a work based upon the Materials or upon the Materials and other pre-existing works, such as a translation, musical arrangement, dramatization, fictionalization, motion picture version, sound recording, art reproduction, abridgment, condensation, or any other form in which the Materials may be recast, transformed, or adapted; "Institution" means the institution, listed on the last page of this Agreement, by which the Author was employed at the time of the creation of the Materials; "JoVE" means MyJoVE Corporation, a Massachusetts corporation and the publisher of *The Journal of Visualized Experiments*; "Materials" means the Article and / or the Video; "Parties" means the Author and JoVE; "Video" means any video(s) made by the Author, alone or in conjunction with any other parties, or by JoVE or its affiliates or agents, individually or in collaboration with the Author or any other parties,

incorporating all or any portion of the Article, and in which the Author may or may not appear.

2. **Background.** The Author, who is the author of the Article, in order to ensure the dissemination and protection of the Article, desires to have the JoVE publish the Article and create and transmit videos based on the Article. In furtherance of such goals, the Parties desire to memorialize in this Agreement the respective rights of each Party in and to the Article and the Video.

3. **Grant of Rights in Article.** In consideration of JoVE agreeing to publish the Article, the Author hereby grants to JoVE, subject to Sections 4 and 7 below, the exclusive, royalty-free, perpetual (for the full term of copyright in the Article, including any extensions thereto) license (a) to publish, reproduce, distribute, display and store the Article in all forms, formats and media whether now known or hereafter developed (including without limitation in print, digital and electronic form) throughout the world, (b) to translate the Article into other languages, create adaptations, summaries or extracts of the Article or other Derivative Works (including, without limitation, the Video) or Collective Works based on all or any portion of the Article and exercise all of the rights set forth in (a) above in such translations, adaptations, summaries, extracts, Derivative Works or Collective Works and (c) to license others to do any or all of the above. The foregoing rights may be exercised in all media and formats, whether now known or hereafter devised, and include the right to make such modifications as are technically necessary to exercise the rights in other media and formats. If the "Open Access" box has been checked in Item 1 above, JoVE and the

## ARTICLE AND VIDEO LICENSE AGREEMENT

Author hereby grant to the public all such rights in the Article as provided in, but subject to all limitations and requirements set forth in, the CRC License.

**4. Retention of Rights in Article.** Notwithstanding the exclusive license granted to JoVE in Section 3 above, the Author shall, with respect to the Article, retain the non-exclusive right to use all or part of the Article for the non-commercial purpose of giving lectures, presentations or teaching classes, and to post a copy of the Article on the Institution's website or the Author's personal website, in each case provided that a link to the Article on the JoVE website is provided and notice of JoVE's copyright in the Article is included. All non-copyright intellectual property rights in and to the Article, such as patent rights, shall remain with the Author.

**5. Grant of Rights in Video – Standard Access.** This Section 5 applies if the "Standard Access" box has been checked in Item 1 above or if no box has been checked in Item 1 above. In consideration of JoVE agreeing to produce, display or otherwise assist with the Video, the Author hereby acknowledges and agrees that, Subject to Section 7 below, JoVE is and shall be the sole and exclusive owner of all rights of any nature, including, without limitation, all copyrights, in and to the Video. To the extent that, by law, the Author is deemed, now or at any time in the future, to have any rights of any nature in or to the Video, the Author hereby disclaims all such rights and transfers all such rights to JoVE.

**6. Grant of Rights in Video – Open Access.** This Section 6 applies only if the "Open Access" box has been checked in Item 1 above. In consideration of JoVE agreeing to produce, display or otherwise assist with the Video, the Author hereby grants to JoVE, subject to Section 7 below, the exclusive, royalty-free, perpetual (for the full term of copyright in the Article, including any extensions thereto) license (a) to publish, reproduce, distribute, display and store the Video in all forms, formats and media whether now known or hereafter developed (including without limitation in print, digital and electronic form) throughout the world, (b) to translate the Video into other languages, create adaptations, summaries or extracts of the Video or other Derivative Works or Collective Works based on all or any portion of the Video and exercise all of the rights set forth in (a) above in such translations, adaptations, summaries, extracts, Derivative Works or Collective Works and (c) to license others to do any or all of the above. The foregoing rights may be exercised in all media and formats, whether now known or hereafter devised, and include the right to make such modifications as are technically necessary to exercise the rights in other media and formats. For any Video to which this Section 6 is applicable, JoVE and the Author hereby grant to the public all such rights in the Video as provided in, but subject to all limitations and requirements set forth in, the CRC License.

**7. Government Employees.** If the Author is a United States government employee and the Article was prepared in the course of his or her duties as a United States government

employee, as indicated in Item 2 above, and any of the licenses or grants granted by the Author hereunder exceed the scope of the 17 U.S.C. 403, then the rights granted hereunder shall be limited to the maximum rights permitted under such statute. In such case, all provisions contained herein that are not in conflict with such statute shall remain in full force and effect, and all provisions contained herein that do so conflict shall be deemed to be amended so as to provide to JoVE the maximum rights permissible within such statute.

**8. Likeness, Privacy, Personality.** The Author hereby grants JoVE the right to use the Author's name, voice, likeness, picture, photograph, image, biography and performance in any way, commercial or otherwise, in connection with the Materials and the sale, promotion and distribution thereof. The Author hereby waives any and all rights he or she may have, relating to his or her appearance in the Video or otherwise relating to the Materials, under all applicable privacy, likeness, personality or similar laws.

**9. Author Warranties.** The Author represents and warrants that the Article is original, that it has not been published, that the copyright interest is owned by the Author (or, if more than one author is listed at the beginning of this Agreement, by such authors collectively) and has not been assigned, licensed, or otherwise transferred to any other party. The Author represents and warrants that the author(s) listed at the top of this Agreement are the only authors of the Materials. If more than one author is listed at the top of this Agreement and if any such author has not entered into a separate Article and Video License Agreement with JoVE relating to the Materials, the Author represents and warrants that the Author has been authorized by each of the other such authors to execute this Agreement on his or her behalf and to bind him or her with respect to the terms of this Agreement as if each of them had been a party hereto as an Author. The Author warrants that the use, reproduction, distribution, public or private performance or display, and/or modification of all or any portion of the Materials does not and will not violate, infringe and/or misappropriate the patent, trademark, intellectual property or other rights of any third party. The Author represents and warrants that it has and will continue to comply with all government, institutional and other regulations, including, without limitation all institutional, laboratory, hospital, ethical, human and animal treatment, privacy, and all other rules, regulations, laws, procedures or guidelines, applicable to the Materials, and that all research involving human and animal subjects has been approved by the Author's relevant institutional review board.

**10. JoVE Discretion.** If the Author requests the assistance of JoVE in producing the Video in the Author's facility, the Author shall ensure that the presence of JoVE employees, agents or independent contractors is in accordance with the relevant regulations of the Author's institution. If more than one author is listed at the beginning of this Agreement, JoVE may, in its sole discretion, elect not take any action with respect to the Article until such time as it has received complete, executed Article and Video License Agreements from each

## ARTICLE AND VIDEO LICENSE AGREEMENT

such author. JoVE reserves the right, in its absolute and sole discretion and without giving any reason therefore, to accept or decline any work submitted to JoVE. JoVE and its employees, agents and independent contractors shall have full, unfettered access to the facilities of the Author or of the Author's institution as necessary to make the Video, whether actually published or not. JoVE has sole discretion as to the method of making and publishing the Materials, including, without limitation, to all decisions regarding editing, lighting, filming, timing of publication, if any, length, quality, content and the like.

**11. Indemnification.** The Author agrees to indemnify JoVE and/or its successors and assigns from and against any and all claims, costs, and expenses, including attorney's fees, arising out of any breach of any warranty or other representations contained herein. The Author further agrees to indemnify and hold harmless JoVE from and against any and all claims, costs, and expenses, including attorney's fees, resulting from the breach by the Author of any representation or warranty contained herein or from allegations or instances of violation of intellectual property rights, damage to the Author's or the Author's institution's facilities, fraud, libel, defamation, research, equipment, experiments, property damage, personal injury, violations of institutional, laboratory, hospital, ethical, human and animal treatment, privacy or other rules, regulations, laws, procedures or guidelines, liabilities and other losses or damages related in any way to the submission of work to JoVE, making of videos by JoVE, or publication in JoVE or elsewhere by JoVE. The Author shall be responsible for, and shall hold JoVE harmless from, damages caused by lack of sterilization, lack of cleanliness or by contamination due to the making of a video by JoVE its employees, agents or independent contractors. All sterilization, cleanliness or

decontamination procedures shall be solely the responsibility of the Author and shall be undertaken at the Author's expense. All indemnifications provided herein shall include JoVE's attorney's fees and costs related to said losses or damages. Such indemnification and holding harmless shall include such losses or damages incurred by, or in connection with, acts or omissions of JoVE, its employees, agents or independent contractors.

**12. Fees.** To cover the cost incurred for publication, JoVE must receive payment before production and publication the Materials. Payment is due in 21 days of invoice. Should the Materials not be published due to an editorial or production decision, these funds will be returned to the Author. Withdrawal by the Author of any submitted Materials after final peer review approval will result in a US\$1,200 fee to cover pre-production expenses incurred by JoVE. If payment is not received by the completion of filming, production and publication of the Materials will be suspended until payment is received.

**13. Transfer, Governing Law.** This Agreement may be assigned by JoVE and shall inure to the benefits of any of JoVE's successors and assignees. This Agreement shall be governed and construed by the internal laws of the Commonwealth of Massachusetts without giving effect to any conflict of law provision thereunder. This Agreement may be executed in counterparts, each of which shall be deemed an original, but all of which together shall be deemed to be one and the same agreement. A signed copy of this Agreement delivered by facsimile, e-mail or other means of electronic transmission shall be deemed to have the same legal effect as delivery of an original signed copy of this Agreement.

A signed copy of this document must be sent with all new submissions. Only one Agreement required per submission.

### CORRESPONDING AUTHOR:

Name:

Alex Chae

Department:

Medicine

Institution:

University of Calgary

Article Title:

Sequential Radial Probe Endobronchial Ultrasound and Electromagnetic Navigation Bronchoscopy

Signature:

*[Handwritten Signature]*

Date:

Aug 8, 2017

Please submit a signed and dated copy of this license by one of the following three methods:

- 1) Upload a scanned copy of the document as a pdf on the JoVE submission site;
- 2) Fax the document to +1.866.381.2236;
- 3) Mail the document to JoVE / Attn: JoVE Editorial / 1 Alewife Center #200 / Cambridge, MA 02139

For questions, please email [submissions@jove.com](mailto:submissions@jove.com) or call +1.617.945.9051

Dear Dr. Nguyen, respectful reviews and the editorial team at JoVE,

Thank for your comments and suggestions regarding our manuscript titled “Sequential Radial probe Endobronchial Ultrasound and Electromagnetic Navigation Bronchoscopy for the Diagnosis of Peripheral Pulmonary Lesions”. I have carefully read all suggestions and have either incorporated changes into the manuscript or have a rationale for the lack of change.

Reviewer #1: Thank you for your comments

Reviewer #2: Thank you for your comments. I have added further studies in the background to address high yields achievable with EBUS alone. Additional data from the study showing a combined yield of 88% was added to show the lower yield of ENB alone (59%). The potential cost of consumables and the rationale for performing EBUS prior to ENB rather than the reverse order was also added. The exact cost of consumables was not added due to future price fluctuations and differences between regions. ROSE data was added to the discussion as well as instructions of a directed BAL if EBUS did not confirm the lesion after ENB.

Reviewer #3: Thank you for your comments. The manuscript is not intended to report new data, but to report data obtained from our previous study and now forms the protocol for our clinical technique (Chee, A., Stather, D. R., MacEachern, P., Martel, S., Delage, A., Simon, M., Dumoulin, E. and Tremblay, A. (2013), Diagnostic utility of peripheral endobronchial ultrasound with electromagnetic navigation bronchoscopy in peripheral lung nodules. *Respirology*, 18: 784–789. )

The aim of the study was to determine whether ENB could help localize a lesion when EBUS alone failed. Instructions were added to perform a directed BAL even if the lesion could not be identified. In the discussion, options were provided for subsequent biopsy or observation.

Reviewer #4. Thank you for your comments. We intended for the audience to be clinicians or bronchoscopists, not cytologists (similar to the bronchial thermoplasty video in 2010). Bronchoscopists can be either pulmonologists or surgeons and our method is for the bronchoscopy suite. Our center does not perform ROSE so we would be unable to advise on the optimal ROSE protocol, though we do mention then ROSE may be beneficial in the discussion. I have added comment on subsequent patient followup options (surgical biopsy, repeat bronchoscopy, CT-guided biopsy, observation) in the discussion. Thank you for the articles – they have now been cited.

I have attached an updated manuscript with the changes tracked. I appreciate your efforts in reading and considering our manuscript.

On behalf of the authors,

Alex Chee

