

Journal of Visualized Experiments

Upper Extremity Transplantation in Non-Human Primates: An Orthotopic Model for Translational Research --Manuscript Draft--

Manuscript Number:	JoVE52290R2
Full Title:	Upper Extremity Transplantation in Non-Human Primates: An Orthotopic Model for Translational Research
Article Type:	Methods Article - JoVE Produced Video
Keywords:	Vascularized composite allotransplantation, reconstructive transplantation, upper extremity transplantation, orthotopic model, non-human primate, translational research
Manuscript Classifications:	5.4.680: Reconstructive Surgical Procedures; 5.4.936.580: Tissue Transplantation; 5.4.936.580.700: Skin Transplantation; 7.12.425.901: Transplantation Immunology; 8.1.770.644.145.675: Translational Medical Research
Corresponding Author:	Curtis L Cetrulo, Jr, MD, FACS Massachusetts General Hospital Boston, MA UNITED STATES
Corresponding Author Secondary Information:	, FACS
Corresponding Author E-Mail:	ccetrulo@mgh.harvard.edu
Corresponding Author's Institution:	Massachusetts General Hospital
Corresponding Author's Secondary Institution:	
First Author:	David A Leonard, MBChB
First Author Secondary Information:	
Other Authors:	David A Leonard, MBChB Harrison Powell Alexander Albritton Kumaran Shanmugarajah Melissa Mastroianni Sarah Lofgren James Winter Josef M Kurtz
Order of Authors Secondary Information:	
Abstract:	Vascularized composite allotransplantation (VCA) is established as a treatment option in the management of complex musculoskeletal and soft tissue trauma and tissue loss. The utility of these procedures is particularly well illustrated by transplantation of specialized anatomical parts such as the upper extremity or craniofacial structures. However, despite encouraging early to medium term outcomes, the potential adverse effects of life-long immunosuppression, necessary to suppress graft rejection, remain a significant cause for concern. Furthermore, the impact and functional significance of chronic rejection in VCA has yet to become clear. Therefore, while the surgical techniques necessary for VCA have developed rapidly, based on decades of experience in autologous free tissue transfer, the immunological aspects of these procedures and the potential functional significance of immunological processes on vascularized composite allografts remain areas in which further research is required to

	<p>maximize clinical utilization and optimize the risk-benefit balance for patients.</p> <p>The functional complexity of these procedures, combined with the preclinical nature of many of the research questions, necessitates the use of large animal models to most effectively address some of the outstanding hypotheses. Cynomolgus macaques have become established as one of the premier large animal models for immunological research. This manuscript describes an orthotopic model of upper extremity transplantation in cynomolgus macaques, for translational research in transplant immunology and suitable for detailed study of the impact of immunologic processes on functional outcomes following VCA. The main focus of our laboratory is establishment of transplant tolerance, the specific absence of a destructive immune response against a vascularized composite allograft, in the absence of immunosuppression, and this model represents our most rigorous test of protocols under consideration for translation to the clinic.</p>
Author Comments:	Submission invited by Dr. Eric Liao to Dr. Curtis L. Cetrulo Jr.
Additional Information:	
Question	Response
If this article needs to be "in-press" by a certain date to satisfy grant requirements, please indicate the date below and explain in your cover letter.	
If this article needs to be filmed by a certain date to due to author/equipment/lab availability, please indicate the date below and explain in your cover letter.	



MASSACHUSETTS
GENERAL HOSPITAL



HARVARD
MEDICAL SCHOOL

Curtis L. Cetrulo, Jr., M.D., FACS

*Division of Plastic & Reconstructive Surgery
15 Parkman Street
Boston, MA 022214
(t) 617/726-4065;
ccetrulo@partners.org*

*Attending Plastic and Reconstructive Surgeon,
Massachusetts General Hospital,
Head, Vascularized Composite
Allotransplantation Laboratory,
Transplantation Biology Research Center,
Massachusetts General Hospital,
Harvard Medical School, Boston, Massachusetts*

May 2nd, 2014

Dear Editor

Please find enclosed a manuscript entitled "Upper Extremity Transplantation in Non-Human Primates: An Orthotopic Model for Translational Research" for consideration for publication in the *Journal of Visualized Experiments*. This submission was suggested by Dr. Eric Liao for consideration for inclusion in the upcoming issue focusing on techniques in Plastic and Reconstructive Surgery research.

This manuscript describes a rigorous non-human primate model, suitable for preclinical studies in the field of vascularized composite allotransplantation, at a level immediately preceding translation from the laboratory to clinical trial. We hope this protocol will be of interest to other researchers in this developing field, and look forward to your editorial decision.

Sincerely,

Curtis L. Cetrulo, Jr., M.D., FACS

TITLE:

Upper Extremity Transplantation in Non-Human Primates: An Orthotopic Model for Translational Research.

AUTHORS:

Leonard, David A^{1,2,3,}

¹ Transplantation Biology Research Center,
Massachusetts General Hospital,
Harvard Medical School,
Boston, USA

² Division of Plastic and Reconstructive Surgery,
Massachusetts General Hospital,
Harvard Medical School,
Boston, USA

³ Department of Plastic & Reconstructive Surgery Research,
University of Manchester,
Manchester, UK

Powell, Harrison^{1,}

¹ Transplantation Biology Research Center,
Massachusetts General Hospital,
Harvard Medical School,
Boston, USA

Albritton, Alexander^{1,}

¹ Transplantation Biology Research Center,
Massachusetts General Hospital,
Harvard Medical School,
Boston, USA

Shanmugarajah, Kumaran^{1,2,}

¹ Transplantation Biology Research Center,
Massachusetts General Hospital,
Harvard Medical School,
Boston, USA

² Division of Plastic and Reconstructive Surgery,
Massachusetts General Hospital,
Harvard Medical School,
Boston, USA

Mastroianni, Melissa^{1,2,}

¹ Transplantation Biology Research Center,
Massachusetts General Hospital,
Harvard Medical School,
Boston, USA

² Division of Plastic and Reconstructive Surgery,

Massachusetts General Hospital,
Harvard Medical School,
Boston, USA

Lofgren, Sarah¹,
¹ Transplantation Biology Research Center,
Massachusetts General Hospital,
Harvard Medical School,
Boston, USA

Winter, James¹,
¹ Transplantation Biology Research Center,
Massachusetts General Hospital,
Harvard Medical School,
Boston, USA

Kurtz, Josef M^{1,4},
¹ Transplantation Biology Research Center,
Massachusetts General Hospital,
Harvard Medical School,
Boston, USA
⁴ Department of Biology,
Emmanuel College,
Boston, USA

Cetrulo, Curtis L Jr^{1,2}
¹ Transplantation Biology Research Center,
Massachusetts General Hospital,
Harvard Medical School,
Boston, USA
² Division of Plastic and Reconstructive Surgery,
Massachusetts General Hospital,
Harvard Medical School,
Boston, USA

CORRESPONDING AUTHOR:

Curtis L. Cetrulo,
Clinical Director Reconstructive Transplantation Program,
Division of Plastic and Reconstructive Surgery,
15 Parkman Street,
Boston, MA, 02114.
Tel: 617-643-7294.
Email address: ccetrulo@mgh.harvard.edu

KEYWORDS:

Vascularized composite allotransplantation, reconstructive transplantation, upper extremity transplantation, orthotopic model, non-human primate, translational research

SHORT ABSTRACT:

Vascularized composite allotransplantation (VCA) offers unparalleled restoration of function and form following devastating musculoskeletal and soft tissue injury. Surgical techniques have developed rapidly, but immunological and functional outcomes require further study. We described a rigorous non-human primate model of orthotopic upper extremity transplantation for pre-clinical studies immediately preceding clinical translation.

LONG ABSTRACT:

Vascularized composite allotransplantation (VCA) is established as a treatment option in the management of complex musculoskeletal and soft tissue trauma and tissue loss. The utility of these procedures is particularly well illustrated by transplantation of specialized anatomical parts such as the upper extremity or craniofacial structures. However, despite encouraging early to medium term outcomes, the potential adverse effects of life-long immunosuppression, necessary to suppress graft rejection, remain a significant cause for concern. Furthermore, the impact and functional significance of chronic rejection in VCA has yet to become clear. Therefore, while the surgical techniques necessary for VCA have developed rapidly, based on decades of experience in autologous free tissue transfer, the immunological aspects of these procedures and the potential functional significance of immunological processes on vascularized composite allografts remain areas in which further research is required to maximize clinical utilization and optimize the risk-benefit balance for patients.

The functional complexity of these procedures, combined with the preclinical nature of many of the research questions, necessitates the use of large animal models to most effectively address some of the outstanding hypotheses. Cynomolgus macaques have become established as one of the premier large animal models for immunological research. This manuscript describes an orthotopic model of upper extremity transplantation in cynomolgus macaques, for translational research in transplant immunology and suitable for detailed study of the impact of immunologic processes on functional outcomes following VCA. The main focus of our laboratory is establishment of transplant tolerance, the specific absence of a destructive immune response against a vascularized composite allograft, in the absence of immunosuppression, and this model represents the most rigorous test of protocols under consideration for translation to the clinic.

INTRODUCTION:

Vascularized composite allotransplantation (VCA) is established as a treatment option in the management of complex musculoskeletal and soft tissue trauma and tissue loss. The utility of these procedures is particularly well illustrated by transplantation of specialized anatomical parts such as the upper extremity or those of the craniofacial region, where satisfactory replacement of like with like, consistent with Gillies' dictum¹, using

autologous tissue is extremely challenging and results often remain suboptimal.

Surgical development in VCA has been rapid, based on decades of experience in autologous free tissue transfer and microsurgery, and short to medium term results have been encouraging. Functional outcomes have been remarkable, particularly in the context of innervation, with hand transplant recipients appearing to benefit from a positive effect of calcineurin inhibition on peripheral nerve regeneration². Recipients of both upper extremity and face transplants have reported significant improvements in independence and quality of life post-transplant. VCA also maintains a 1-year graft survival rate close to 100%, far in excess of other branches of transplantation³. However this is offset by a high incidence of acute rejection episodes (up to 90% experience at least one episode within the first year) which most frequently target the skin^{3,4}. Aside from the immediate clinical burden of such episodes, necessitating that patients undergo biopsy and additional therapy, typically with corticosteroid bolus, evidence from a VCA study in rodents links repeated acute rejection episodes with later development of chronic rejection⁵. Clinically, chronic rejection has not yet been well characterized in VCA, but considering the impact of chronic rejection processes, chiefly chronic allograft vasculopathy, on long term outcomes following solid organ transplantation it remains a cause for concern. Taken together with the side effect profile of conventional immunosuppression regimens, the necessity for further research into the immunologic responses to vascularized composite allografts, and development of novel clinical protocols with reduced risk, improved efficacy, or both is clear. In this context, the overarching goal of our laboratory is the development of clinically applicable protocols for VCA tolerance.

Murine models have been used extensively to gain important insights into the basic mechanisms of immune system function and the establishment and maintenance of immune tolerance⁶. More recently, advances in microsurgical techniques have facilitated the introduction of murine VCA models, allowing specific study of skin and musculoskeletal tissues in the context of vascularized composites⁷. However, historically, the vast majority of protocols which successfully achieve tolerance of a transplanted organ or tissue in small animal models fail to translate to large animals or to humans⁸. In contrast, mixed chimerism-based tolerance protocols originating from murine studies, and validated in non-human primate models⁹ have been successfully introduced to clinical trials in kidney transplantation^{10,11}. Therefore, in addition to small animal studies, and porcine VCA models which we utilize extensively as a cost-effective large animal model uniquely well suited to the study of cutaneous immunobiology, we believe that rigorous non-human primate models are an important part of the translational research pathway in VCA.

Previous studies, performed prior to the introduction of clinical upper extremity transplantation, sought to investigate the technical feasibility of hand transplantation in baboons¹² and of partial hand transplants (composites of the first ray and radial forearm flap) in rhesus macaques¹³. More recently, the radial forearm flap has been described as a model for study of VCA in cynomolgus macaques¹⁴, although this model lacked any functional component. Similarly, Barth and colleagues have described a model of

heterotopic transplantation of partial facial allografts¹⁵ which they have utilized in a number of studies of novel immunosuppressive regimens and the role of donor bone marrow in this context^{16,17}.

This manuscript describes the methodology used for orthotopic upper extremity transplantation in cynomolgus macaques. This model permits detailed study of the immune status of recipients using the wide variety of validated immunologic techniques and reagents available for this species, including many cross-reactive human reagents. In addition the orthotopic transplantation of an upper extremity, with careful coaptation of nerves and tendons in a manner comparable to hand transplants in the clinical setting, offers the possibility of functional studies, including analysis of peripheral nerve testing and functional neuroimaging studies, which would not be possible in other model systems.

In this model, recipient amputation and procurement of the donor hand, at the level of the distal third of the forearm, proceed in parallel to the point of recipient amputation. The donor hand remains perfused on radial artery and cephalic vein, and the donor is systemically heparinized prior to ligation of the pedicle and radial and ulnar osteotomies. The donor hand is placed on ice, and flushed with heparin-saline and perfusion solution prior to transplantation which proceeds with osteosynthesis, tenorrhaphy of the wrist extensors and flexors for stability, followed by reperfusion via the radial artery, with drainage via anastomosis of the cephalic vein. Additional arterial or venous anastomoses maybe performed if required to achieve optimal circulation. Following reperfusion, transplantation is completed with tenorrhaphy of the digital flexor and extensor tendons, median and ulnar neurorrhaphies, and closure of the skin flaps. The limb is protected in a lightweight fiberglass cast postoperatively. Following intraoperative induction of immunosuppression via the intravenous route, maintenance immunosuppression may be provided intramuscularly or orally, disguised in food. This protocol may be modified to perform autologous replantation as an experimental control.

Typically we observe satisfactory perfusion of the transplanted hand following anastomosis of radial artery and cephalic vein alone. In two cases we have performed secondary arterial anastomoses using branches of the radial artery, which interestingly, appears bifid in these animals. Venous drainage via the cephalic vein has been sufficient in all cases, with the exception of one case in which kinking and occlusion of the vein resulted in thrombosis, congestion and no-reflow phenomenon. Maintenance immunosuppression with tacrolimus, mycophenolate mofetil and methylprednisolone has been sufficient to prevent graft loss to rejection post-transplant. Further studies are underway utilizing this model for investigation of clinically applicable tolerance strategies.

PROTOCOL:

All animal procedures described and demonstrated in this publication were conducted in accordance with protocols approved by the Massachusetts General Hospital Institutional Animal Care and Use Committee (IACUC), in accordance with the Guide for the Care and Use of Laboratory Animals and under strict veterinary supervision.

1. Preoperative Planning and Preparation

- 1.1 Use cynomolgus macaques, purchased from approved vendors, with body weight greater than 6 kg. Animals should undergo thorough veterinary evaluation and quarantine prior to surgery. Select donor-recipient pairs on basis of size match, ABO blood group, and additional parameters as necessary for the experiment planned, including major histocompatibility complex (MHC) genotyping and expression of donor-specific markers for chimerism analysis.
- 1.2 In order to minimize ischemic time, procurement of the donor limb and recipient amputation should proceed in parallel. Plan surgery to ensure coordination of the surgical and anesthetic teams.
- 1.3 Confirm donor and recipient weights with anesthetic team 24 hours prior to transplant, and finalize orders for any non-anesthetic medications, such as induction immunosuppression, to be administered intraoperatively as required by the experimental protocol.
- 1.4 Check operating room equipment (critical equipment such as operating microscope and pneumatic tourniquet should be tested frequently and undergo routine preventative maintenance) and set up to facilitate work flow.
- 1.5 Ensure instruments are available and sterilized (autoclaved or gas sterilized) including reciprocating saw, drill, titanium plating set, microsurgical set, microvascular clamps and general dissecting instruments. In addition to donor and recipient operating tables with arm tables, back tables will be required for each animal, and for the sterile orthopedic equipment.
- 1.6 Withhold solid food for at least 12 hours prior to surgery for both donor and recipient. Water should be allowed ad libitum at all times.

2. Induction of Anesthesia and Intraoperative Monitoring

- 2.1 On the day of surgery administer premedication (Glycopyrolate 0.01 mg/kg) and sedative (Ketamine 20mg/kg) drugs IM.
- 2.2 Confirm adequate sedation by observation, remove animals from the cage and transfer to the OR. Remove hair from the surgical site (left arm) and additional sites for vascular access (contralateral arm, lower legs, tail) using clippers.
- 2.3 Place an appropriately size cuffed endotracheal tube and connect to anesthesia and ventilator circuit. Maintain anesthesia with isoflurane 0.5-3% and, for recipient animals, a continuous infusion of Ketamine 1mg/ml at a rate of 5-10ml/hr.
- 2.4 Position animals on operating table with left arm extended on arm table, and

pneumatic tourniquet in place. Place Bear Hugger forced air warmer to maintain body temperature under anesthesia. Lubricate eyes with veterinary eye ointment to prevent dryness under anesthesia.

- 2.5 Establish peripheral IV access in short saphenous veins and/or contralateral basilic veins. Administer maintenance fluids (0.9% normal saline, 10ml/kg/hr) and medications intraoperatively.
- 2.6 Place a percutaneous arterial line in the ventral artery of the tail of recipient animals for continual invasive blood pressure monitoring.
- 2.7 Insert a self-retaining Foley urinary catheter (5 Fr) and connect to urometer to facilitate strict monitoring of fluid balance.
- 2.8 Establish monitoring of pulse, blood pressure, respiratory rate, pulse oximetry, capnography, EKG and temperature. In addition assess depth of anesthesia by assessment of jaw tone. Monitor and record these parameters throughout the period of anesthesia.
- 2.9 Administer preoperative analgesics (Buprenorphine 0.01 mg/kg IV, Banamine 1mg/kg IM) and prophylactic antibiotics (Cefazolin 25mg/kg IM).
- 2.10 Perform disinfectant skin preparation with solutions of chlorhexidine, povidone-iodine and alcohol and drape the surgical field.

3. Recipient Preparation

Induction immunosuppression may be administered intravenously to the recipient during the transplant procedure, however the details of immunosuppressive protocols are expected to be the focus of experimental studies using this model, and to therefore vary considerably. For this reason we have not included specific steps describing the administration of immunosuppressive reagents in this protocol.

- 3.1 Mark course of cephalic vein and other substantial cutaneous veins with surgical ink. Design and mark skin flaps to interdigitate with donor skin flaps approximately 4cm proximal to radiocarpal joint.
- 3.2 Elevate and compress arm to exsanguinate, inflate tourniquet to 200 mmHg.
- 3.3 Incise skin and elevate skin flaps, taking care to preserve cephalic and other cutaneous veins. Ensure hemostasis with bipolar diathermy.
- 3.4 Open investing fascia and dissect out radial artery and venae comitantes (VCs). Note that the radial artery may be bifid at this level in cynomolgus macaques with each branch accompanied by VCs.

- 3.5 Protecting cephalic vein and radial vascular bundle, divide the superficial digital flexors. Note that the musculotendinous junction extends further distally in comparison to human anatomy and division of muscle is likely at this level.
- 3.6 Identify, isolate and divide the median nerve. Section as far distal as possible and mark for later identification.
- 3.7 Isolate and protect the ulnar nerve and ulnar artery deep to flexor carpi ulnaris, which should be divided. Ligate the ulnar artery with clips and divide; this should be handled carefully as it may be required for secondary arterial anastomosis later. Divide ulnar nerve distally and mark for identification.
- 3.8 Divide the flexor digitorum profundus and the wrist flexors.
- 3.9 Divide the digital and wrist extensors.
- 3.10 Divide pronator quadratus and perform minimal periosteal stripping to prepare the osteotomy sites, which should be measured at 4cm from the radiocarpal joint.
- 3.11 Ligate and divide radial artery and cephalic vein. Amputate hand with reciprocating saw, taking care to perform well aligned, transverse osteotomies of radius and ulna.
- 3.12 Deflate tourniquet, ensure hemostasis with bipolar diathermy, ligature-clips and bone wax as necessary. Wrap stump in saline-soaked gauze and monitor recipient condition while awaiting donor hand.

[Place Figure 1 here]

4. Donor Operation – Allograft Procurement

Procurement of the donor hand proceeds in a similar manner to recipient amputation, with the exception that neurovascular structures sectioned distally in the recipient should be dissected proximally in the donor prior to division, to ensure sufficient length is available for tension-free anastomoses.

- 4.1 Mark course of cephalic vein and other substantial cutaneous veins with surgical ink. Design and mark skin flaps to interdigitate with donor skin flaps approximately 4cm proximal to radiocarpal joint (Figure 1 A).
- 4.2 Elevate and compress arm to exsanguinate, and inflate tourniquet to 200 mmHg.
- 4.3 Incise skin and elevate skin flaps, taking care to preserve cephalic and other cutaneous veins. Ensure hemostasis with bipolar diathermy.
- 4.4 Open investing fascia and dissect out radial artery and venae comitantes

(Figure 1 B).

- 4.5 Protecting cephalic vein and radial vascular bundle, divide the superficial digital flexors.
- 4.6 Identify, isolate and dissection out the median nerve, dividing it 1-2cm proximal to the level of the skin incision.
- 4.7 Divide flexor carpi ulnaris, taking care to protect ulnar nerve and artery lying along its deep margin. Divide ulnar artery and nerve proximally, and mark for identification.
- 4.8 Divide the flexor digitorum profundus and the wrist flexors.
- 4.9 Divide the digital and wrist extensors.
- 4.10 Divide pronator quadratus and perform minimal periosteal stripping to prepare the osteotomy sites, which should be measured at 4cm from the radiocarpal joint.
- 4.11 Deflate tourniquet, allowing hand to reperfuse via radial artery and cephalic vein (Figure 2 A). Ensure hemostasis. Administer heparin 200 U/kg intravenously.
- 4.12 Allow hand to perfuse for 20-30 minutes, during which time a tray of sterile ice should be crushed and heparin-saline (100 U/ml) and perfusion solution prepared.
- 4.13 Ligate and divide radial artery and cephalic vein. The start of ischemic time should be noted.
- 4.14 Perform radial and ulnar osteotomies with reciprocating saw and remove hand to back table on ice (Figure 2 B).
- 4.15 Humanely euthanize the donor animal and collect additional tissues as necessitated by your experimental plan.

Note 1: Two options are available for humane euthanasia; an intravenous overdose (200mg/kg) of sodium pentobarbital (Fatal Plus) administered under sedation, or exsanguination under deep anesthesia. Use the later only in experimental circumstances where vital bone marrow or other tissues to which sodium pentobarbital may be toxic must be collected.

Note 2: We routinely collect whole blood volume for isolation of leukocytes for in vitro assays and preparation of packed red cells for transfusion support of anemic animals, bone marrow for transplantation and induction of mixed chimerism, and split thickness skin grafts for later testing of tolerance.

[Place Figure 2 here]

5. Transplantation

- 5.1 With the hand on ice, cannulate the radial artery using an anterior chamber needle and 10ml syringe and flush with heparin-saline 100U/ml followed by perfusion solution (University of Wisconsin, or Euro-Collins) until venous effluent is clear.
- 5.2 Transfer hand to recipient table and ensure donor and recipient osteotomies are parallel and will permit well aligned rigid fixation.
- 5.3 Perform osteosynthesis with appropriately sized, titanium limited contact dynamic compression plates (LCDCP) and titanium screws. Use 2.0 mm plates for animals between 6 – 10kg. Fix ulna first with a 4-hole plate, followed by radius with a 6-hole plate, 8mm and 10mm screws respectively are appropriate in the majority of cases. Follow AO principles and ensure rigid fixation to minimize risk of nonunion (Figure 3).
- 5.4 Repair wrist flexors and extensors to stabilize wrist in a neutral position using 3/0 prolene or ethibond suture.
- 5.5 Repair deep digital flexor tendons to mimic natural digital cascade using 3/0 prolene or ethibond suture.
- 5.6 Bring in operating microscope and perform microvascular anastomoses of radial artery followed by cephalic vein. The artery can be expected to have a diameter of <1mm and the vein 1-1.5mm, 10/0 nylon suture is appropriate (Figure 4).
- 5.7 Remove microvascular clamps and allow hand to reperfuse. Note end of ischemic time. Apply lidocaine 1% to vessels to relieve vasospasm, ensure recipient is well hydrated with adequate blood pressure and body temperature, and apply warm saline soaked gauze wraps to the hand. Allow hand to reperfuse for 20-30 minutes during which time the surgical team may rotate or take a short rest.
- 5.8 Assess perfusion. If adequate (hand warm, bright red bleeding from fingertip following needle prick) proceed with subsequent steps. If inadequate examine anastomoses under microscope for patency, ensure vessel lengths are appropriate to exclude both excess tension and kinking, and if necessary perform additional anastomoses to enhance perfusion. A secondary branch of the radial artery, or the ulnar artery are available, additional dorsal veins may be identified. The venae comitantes of the arteries are of insufficient caliber for reliable anastomosis.
- 5.9 Perform median and ulnar neurorrhaphies, aiming to do so as far distal as possible, using 8/0 or 9/0 nylon suture.

- 5.10 Repair superficial digital flexor tendons with 3/0 prolene or ethibond using low-profile side-to-side technique¹⁸.
- 5.11 Perform extensor tenorrhaphies using 3/0 prolene or ethibond, setting tension to allow full range of motion and maintaining digital cascade.
- 5.12 Interdigitate and close skin flaps using 3/0 nylon simple interrupted sutures, taking care to avoid damage to the cephalic vein or arterial anastomoses (Figure 5 A, B).
- 5.13 Check perfusion adequate (Figure 5 C) before applying dressings and cast and recovering the animal to its cage.

Note that this protocol may be adapted to perform amputation and autologous replantation if required to address specific experimental aims, by following the procedures for donor procurement and transplantation on a single animal. Shortening osteotomies of 5-10mm to radius and ulna may be necessary to relieve tension on neurovascular structures and facilitate anastomoses.

[Place Figure 3 here]

[Place Figure 4 here]

6. Postoperative Care

- 6.1 Dress hand and wound with gauze and bulky wool, and apply a full-length fiberglass cast to the arm with the wrist slightly extended, and the metacarpophalangeal and interphalangeal joints loosely flexed in a natural cascade position.

Note: The elbow should be slightly flexed to prevent effortless removal of the cast, while simultaneously avoiding vascular constriction at the antecubital fossa.

- 6.2 Place animal in a cotton jacket. Secure cast to front of jacket to achieve relief from dependent position.

Note: Animals must be acclimated to wearing of jackets and casts prior to commencing study.

- 6.3 Ensure adequate hydration and analgesia. If placed in protective jacket, a fentanyl patch 1-4 µg/kg/hr may be placed to provide postoperative analgesia. Alternatively buprenorphine 0.01mg/kg IM must be administered twice daily for 72 hours, more frequently if clinical signs of pain are observed.
- 6.4 Wean from anesthesia, discontinue monitoring.
- 6.5 Return to cage, which should be warmed with a heat lamp, and monitor

continually until fully alert and recovered from anesthesia.

- 6.6 Perform examination of the transplanted hand daily or twice daily for the first 72 hours postoperatively to ensure adequate perfusion and facilitate rapid intervention if necessary to revise anastomoses etc. Short duration sedation for these procedures may be induced with intramuscular injection of ketamine (1-4 mg/kg) and dexmedetomidine (5-10 μ g/kg), followed by atipamezole reversal. The frequency of checks can be reduced to twice weekly after the immediate postoperative period.
- 6.7 Perform two-view radiographs on post-operative day 1 to ensure fixation is appropriate and the position acceptable.
- 6.8 Administer immunosuppressive medications according to individual experimental protocols. Details of immunosuppressive regimens vary, but conventional immunosuppression may be administered daily via a combination of IM and oral routes. Draw blood twice weekly to monitor drug levels.

[Place Figure 5 here]

REPRESENTATIVE RESULTS:

Following a series of post-mortem dissections to confirm the anatomy of the cynomolgus monkey forearm and to determine the feasibility of transplantation and revascularization, we have performed a series of two autologous replantations and four allotransplants across full MHC barriers. Total operating time averaged 11-12 hours. Mean ischemic time in both groups was 3 hours. All microvascular anastomoses were performed using conventional suture techniques for both artery and vein, which had diameters of 0.75-1mm and 1-1.5mm respectively. All anastomoses were demonstrably patent with no primary failures.

In the autologous replantation group, one animal unfortunately developed respiratory complications under anesthesia, secondary to endotracheal tube trauma, from which resuscitation could not be achieved. The second animal in this group tolerated the procedure well, made impressive functional recovery, including use of the hand in locomotion, grooming and as an assist hand while feeding and manipulating objects. This animal remains under follow up over 1 year post-operatively.

Outcomes following allotransplantation have highlighted the critical importance of precise microsurgical technique, and highlighted the challenges of microvascular procedures on this small scale. Two animals unfortunately required early euthanasia due to microvascular compromise; in one case excess length following venous anastomosis permitted the development of kinking and venous thrombosis on POD2. Despite emergency revision a no-reflow state had developed and the hand could not be reperfused. In another case, despite patent anastomoses, and treatment with topical lidocaine 1% for relief of vasospasm, perfusion of the hand was poor postoperatively and despite medical optimization, warming, and anticoagulation perfusion remained poor.

Persisting ischemia declared over the first postoperative week and the animal was euthanized on POD7.

The remaining two animals in the initial allotransplant group had smooth operative courses, and made excellent post-operative recoveries (Figure 6A, B). The first was followed to an experimental end point 4 months post-transplant, during which period immunosuppression induced with three doses of anti-thymocyte globulin (ATGAM) 50mg/kg and maintained with FK506 0.1mg/kg/day, MMF 300mg/day and methylprednisolone tapered from over the first two weeks from 40mg/day to a maintenance dose of 1mg/day. This regimen resulted in rejection-free survival (Figure 6C), with the exception of 1 episode of acute rejection of skin which followed tapering of MMF to 100mg/day due to a period of inappetence. Signs of rejection resolved rapidly in response to steroid bolus and return to standard MMF dosing. The final animal in this group is currently 3 weeks post-transplant, remains clinically well, and shows no signs of rejection.

[Place Figure 6 here]

FIGURE LEGENDS:

Figure 1: Marking and dissection for procurement of NHP donor hand.

A) Skin flaps are marked approximately 4cm from wrist on both recipient and donor to ensure skin flaps interdigitate properly following transplantation. Note that the course of the cephalic vein is also marked. B) Dissecting proximally along the radial vascular bundle to procure additional length facilitates tension-free anastomosis.

Figure 2: Isolation and amputation of the donor hand.

A) Following dissection and transection of all major structures except the radius, ulna, radial artery and cephalic vein the tourniquet is released, the donor heparinized and the hand reperfused for 20-30 minutes prior to procurement. B) Following ligation and division of the radial artery and cephalic vein osteotomies are performed with a reciprocating saw.

Figure 3: NHP hand transplantation: Osteosynthesis.

A) Osteosynthesis of ulna and radius is performed using titanium LC-DCPs according to AO principles. Note microvascular clamps on proximal vessels in preparation for anastomosis. B) AP and C) Lateral radiographs demonstrating close approximation and good alignment of radius and ulna post-transplant.

Figure 4: NHP hand transplantation: Reperfusion.

Following anastomoses of radial artery and cephalic vein, visible above plates in this photograph, the hand is reperfused for 20-30 minutes and perfusion assessed prior to continuing with repair of flexor and extensor tendons, median and ulnar nerves and closure of skin flaps.

Figure 5: Post-transplant appearance:

A) Radial-oblique and B) ulnar-oblique views immediately following closure of skin flaps.

C) Bright red bleeding from fingertip following needle-prick confirms the hand is well perfused prior to application of dressings and protective cast.

Figure 6: Representative result:

A) Radial and B) Palmar views demonstrating status 3 months post hand transplantation. Note sutures following protocol biopsy, which confirmed rejection-free status. C) Hand transplant biopsy specimen demonstrating absence of rejection. Immunosuppression was maintained with FK506 0.1mg/kg/day, MMF 300mg/day and Methylprednisolone 1mg/day.

DISCUSSION:

Non-human primate models are widely considered the final step on the translational research pathway prior to clinical trial. Positive results in such models are viewed with particular importance in fields, such as VCA, where results of current therapies are acceptable, albeit not always optimal, and where patient survival is expected to be high without intervention – thus establishing that the ethical standard for any new therapy should be beneficence rather than non-maleficence.

Previously described non-human primate models of VCA have achieved transplantation of the necessary tissue types, and have provided insights into the immune response to these tissues under conventional immunosuppression^{14,15} and some novel protocols¹⁶. However, these models include no functional component by which to assess this important aspect of VCA. This orthotopic upper extremity transplantation model, in contrast, is closely analogous to clinical hand transplant procedures, and provides a unique opportunity to study not only the immune response to the transplanted tissues, but to investigate in detail the impact of rejection, or aspects of novel tolerance or immunomodulatory protocols on functional outcome. Representative results from such studies are not yet available, but investigation of peripheral nerve recovery, functional testing, and advanced imaging studies are planned.

This model is technically challenging, and presents a steep learning curve as illustrated by the representative results presented. High quality, rigid boney fixation is critical in avoiding non-union. Precise microvascular technique is also imperative, as we have found this model highly sensitive to even minor excess vessel length, particularly following venous anastomosis. It is also resource intensive, requiring an appropriate non-human primate research facility, expert veterinary anesthetic support and a team of experienced reconstructive microsurgeons. Clearly structured rehabilitation to maximize functional outcomes is not possible in NHPs as it is in patients, and this could represent a limitation of this model when it comes to future functional studies. However we have been impressed by the considerable degree of function which animals recovery spontaneously, including use of the hand in grooming, as an assist hand in feeding, and for locomotion. We believe this model represents a valuable tool in the effort to develop and validate novel protocols to improve the immunologic management of VCA, and we hope, ultimately to facilitate the introduction of a safe and effective protocol for induction of VCA tolerance to clinical trial.

ACKNOWLEDGMENTS:

The authors wish to acknowledge funding from the Massachusetts General Hospital Division of Plastic and Reconstructive Surgery and the US Department of Defense Reconstructive Transplantation Research Consortium (W81XWH-13-2-0062). David Leonard was supported by a Novartis Scientist Scholarship from the American Society of Transplant Surgeons. We wish to thank Betsy Neylon and Elena Shubina for expert operating room support.

DISCLOSURES:

The authors have nothing to disclose.

REFERENCES

1. Millard, D.R. & Gillies, H.D. *The Principles and Art of Plastic Surgery*. Little & Brown, (1957).
2. Doolabh, V.B. & Mackinnon, S.E. FK506 accelerates functional recovery following nerve grafting in a rat model. *Plast.Reconstr.Surg.* **103** (7), 1928-1936, (1999).
3. Petruzzo, P. *et al.* The International Registry on Hand and Composite Tissue Transplantation. *Transplantation.* **90** (12), 1590-1594, doi:10.1097/TP.0b013e3181ff1472 [doi] (2010).
4. Hautz, T. *et al.* Standardizing skin biopsy sampling to assess rejection in vascularized composite allotransplantation. *Clin Transplant.* **27** (2), E81-E90, doi:10.1111/ctr.12086 [doi] (2013).
5. Unadkat, J.V. *et al.* Composite tissue vasculopathy and degeneration following multiple episodes of acute rejection in reconstructive transplantation. *Am.J Transplant.* **10** (2), 251-261, doi:AJT2941 [pii];10.1111/j.1600-6143.2009.02941.x [doi] (2010).
6. Sykes, M. Mechanisms of tolerance induced via mixed chimerism. *Front Biosci.* **12** 2922-2934, doi:2282 [pii] (2007).
7. Sucher, R. *et al.* Mouse hind limb transplantation: a new composite tissue allotransplantation model using nonsuture supermicrosurgery. *Transplantation.* **90** (12), 1374-1380, doi:10.1097/TP.0b013e3181ff4fc3 [doi] (2010).
8. Sachs, D.H. Tolerance: of mice and men. *J Clin Invest.* **111** (12), 1819-1821, (2003).
9. Kawai, T. *et al.* Mixed allogeneic chimerism and renal allograft tolerance in cynomolgus monkeys. *Transplantation.* **59** (2), 256-262, (1995).
10. Kawai, T. *et al.* HLA-mismatched renal transplantation without maintenance immunosuppression. *N Engl J Med.* **358** (4), 353-361, (2008).
11. Kawai, T., Sachs, D.H., Sykes, M., & Cosimi, A.B. HLA-mismatched renal transplantation without maintenance immunosuppression. *N.Engl.J Med.* **368** (19), 1850-1852, doi:10.1056/NEJMc1213779 [doi] (2013).
12. Daniel, R.K. *et al.* Tissue transplants in primates for upper extremity reconstruction: a preliminary report. *J Hand Surg.Am.* **11** (1), 1-8, (1986).
13. Hovius, S.E. *et al.* Replantation of the radial side of the hand in the rhesus monkey: anatomical and functional aspects. A preliminary study to composite tissue allografting. *J Hand Surg.Br.* **17** (6), 651-656, (1992).
14. Cendales, L.C. *et al.* Composite tissue allotransplantation: development of a

preclinical model in nonhuman primates. *Transplantation*. **80** (10), 1447-1454, doi:00007890-200511270-00016 [pii] (2005).

15. Barth, R.N. *et al.* Facial subunit composite tissue allografts in nonhuman primates: I. Technical and immunosuppressive requirements for prolonged graft survival. *Plast.Reconstr.Surg.* **123** (2), 493-501, doi:10.1097/PRS.0b013e3181954edd [doi];00006534-200902000-00008 [pii] (2009).

16. Barth, R.N. *et al.* Vascularized bone marrow-based immunosuppression inhibits rejection of vascularized composite allografts in nonhuman primates. *Am.J Transplant.* **11** (7), 1407-1416, doi:10.1111/j.1600-6143.2011.03551.x [doi] (2011).

17. Barth, R.N. *et al.* Prolonged survival of composite facial allografts in non-human primates associated with posttransplant lymphoproliferative disorder. *Transplantation*. **88** (11), 1242-1250, doi:10.1097/TP.0b013e3181c1b6d0 [doi];00007890-200912150-00004 [pii] (2009).

18. Brown, S.H. *et al.* Mechanical strength of the side-to-side versus Pulvertaft weave tendon repair. *J Hand Surg.Am.* **35** (4), 540-545, doi:S0363-5023(10)00050-X [pii];10.1016/j.jhsa.2010.01.009 [doi] (2010).

Figure
[Click here to download high resolution image](#)

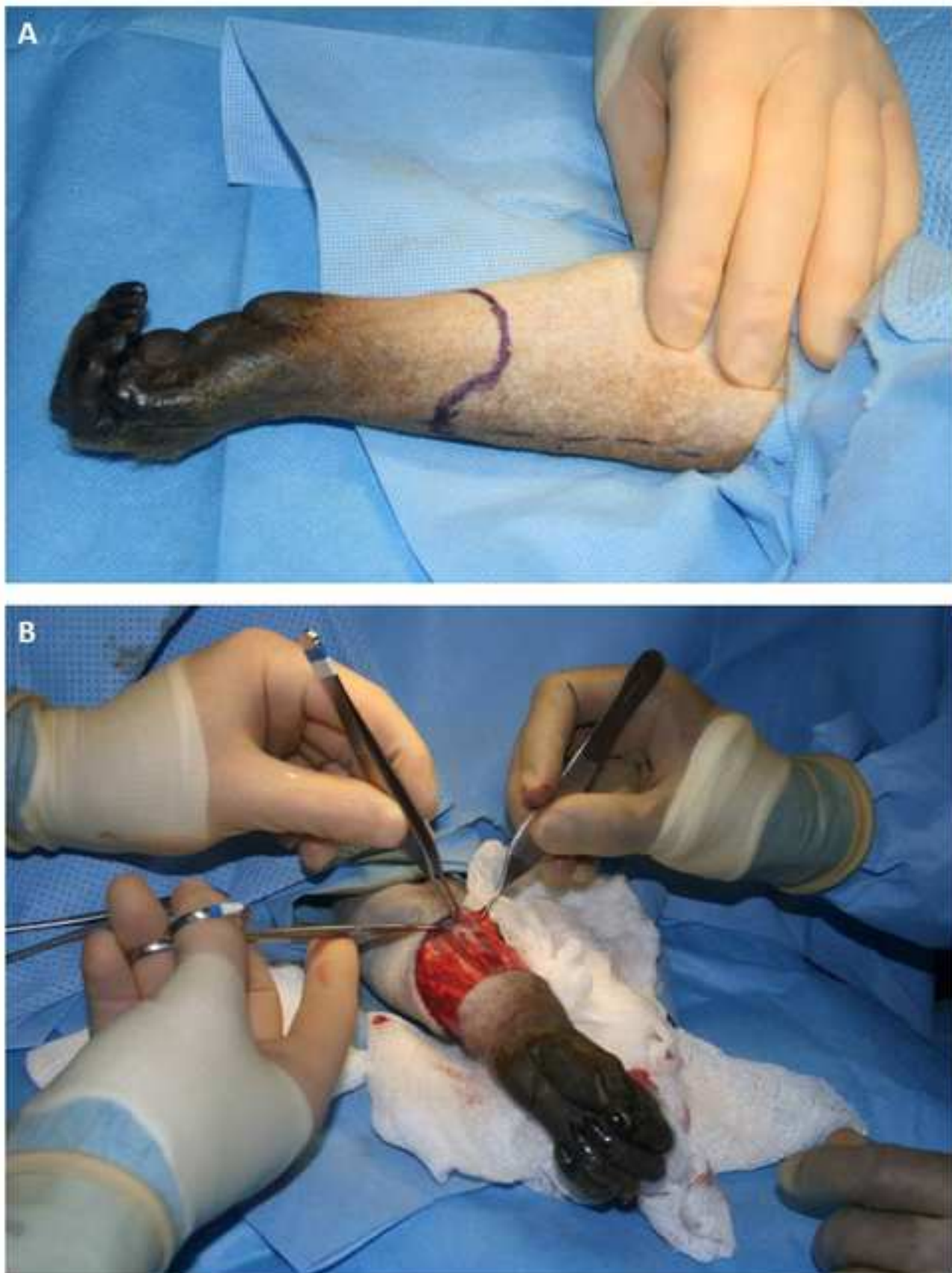

Figure
[Click here to download high resolution image](#)

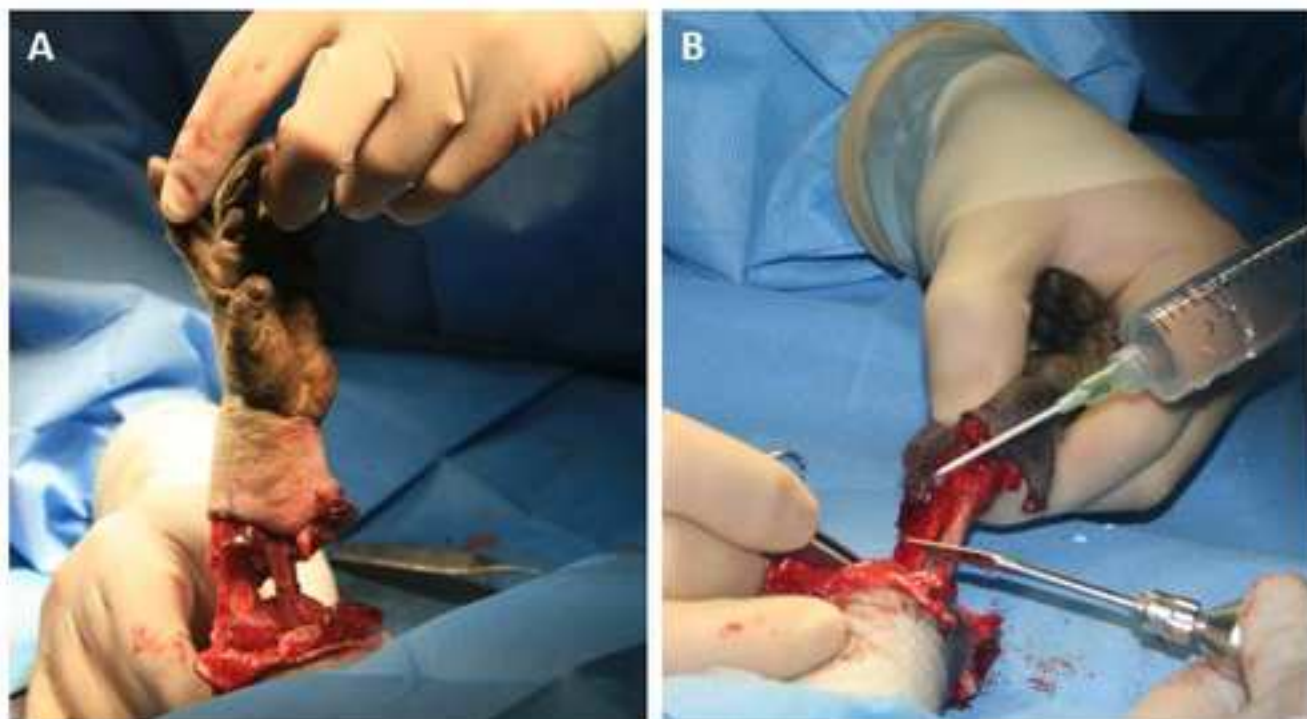


Figure
[Click here to download high resolution image](#)

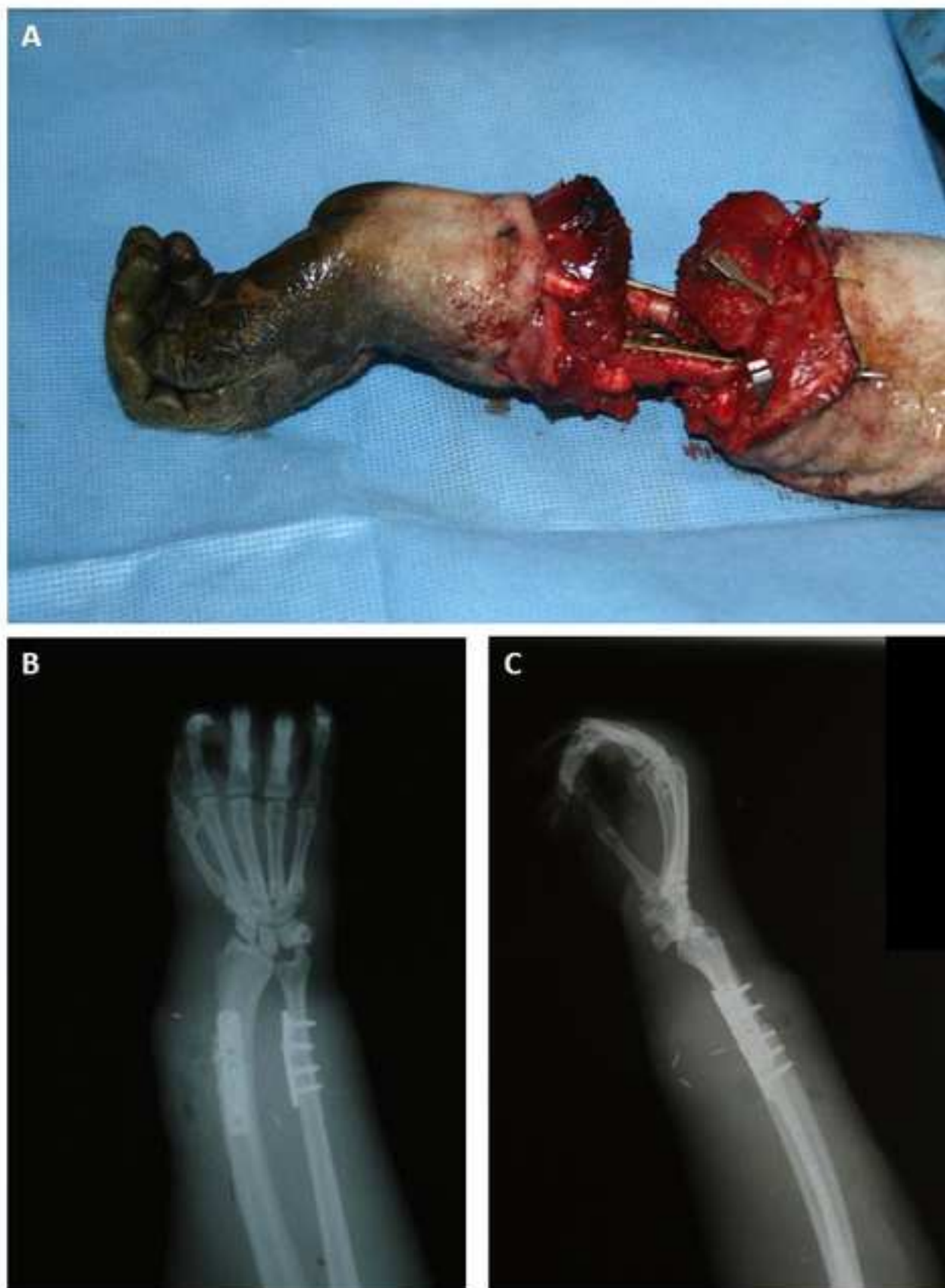

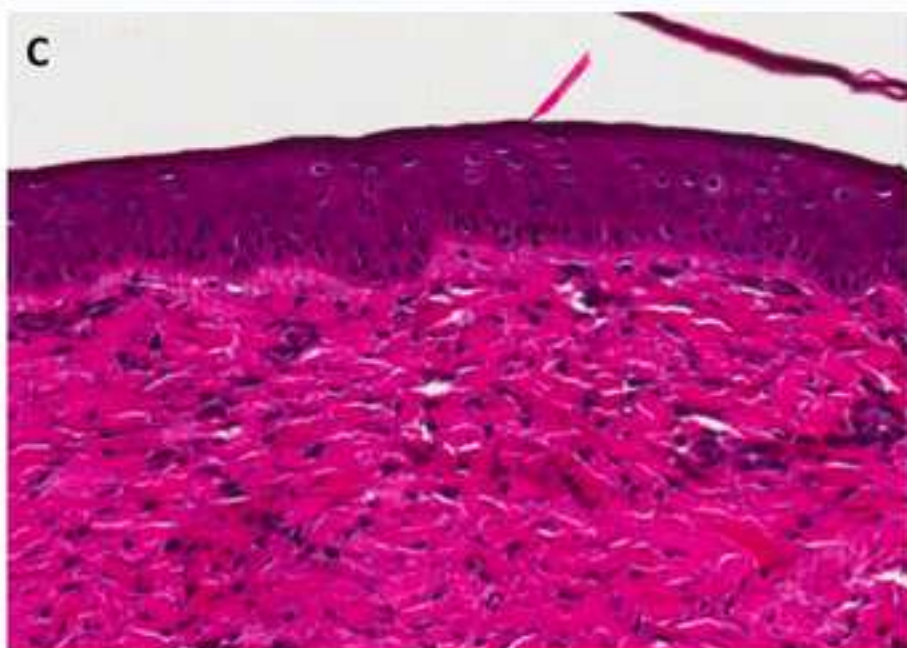
Figure
[Click here to download high resolution image](#)

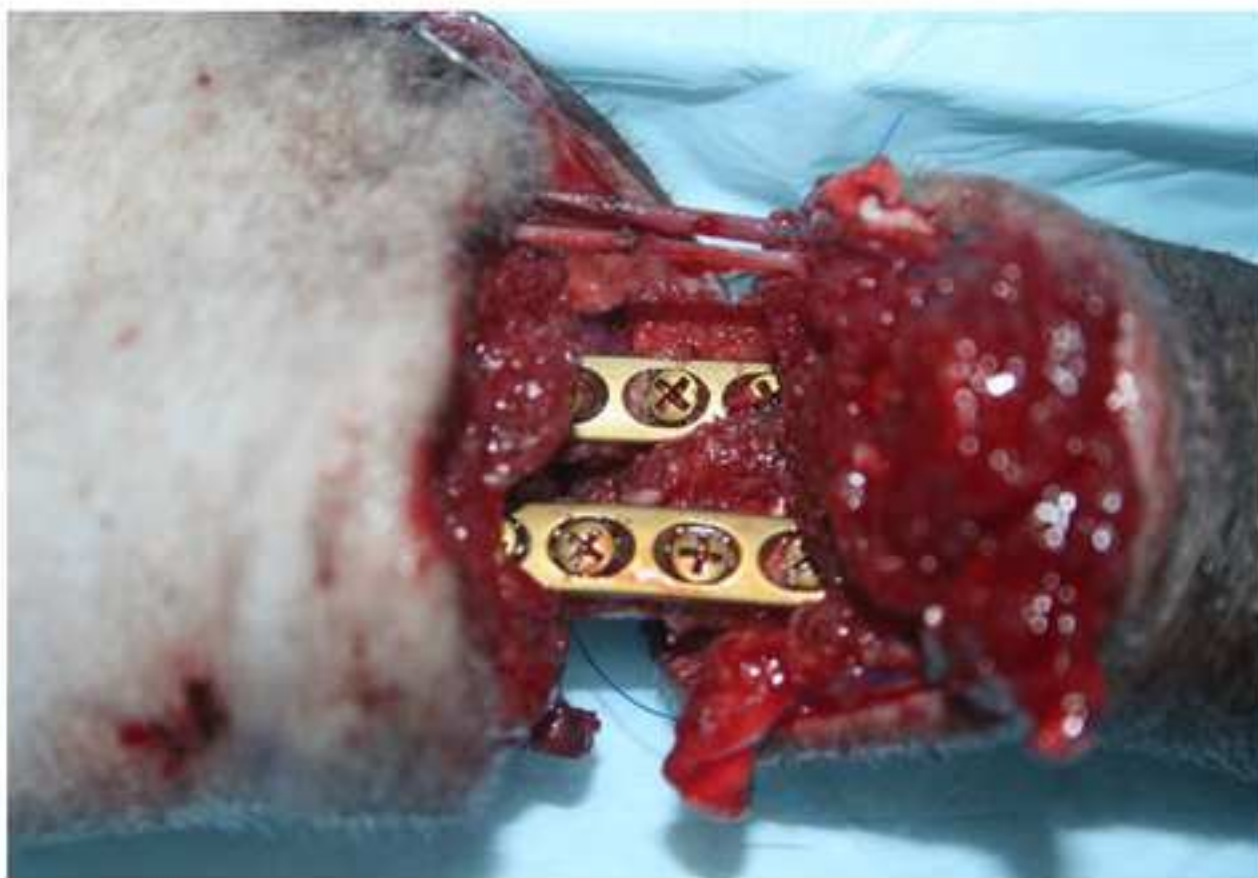

Figure
[Click here to download high resolution image](#)

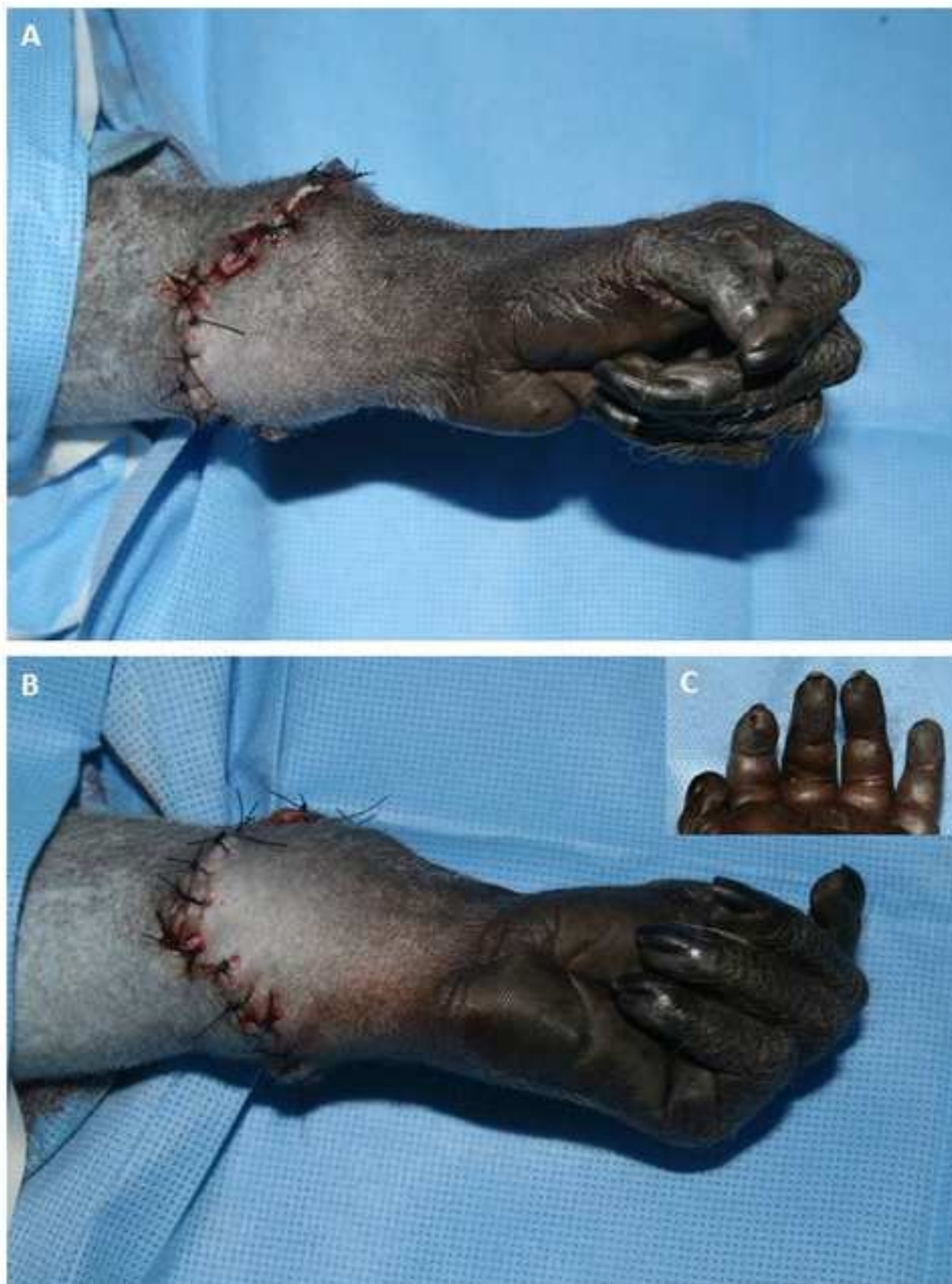

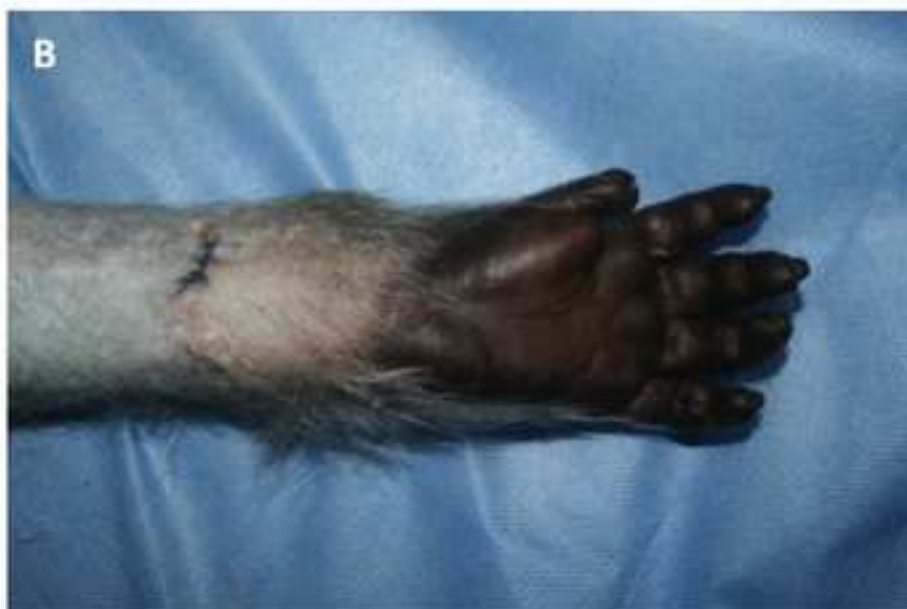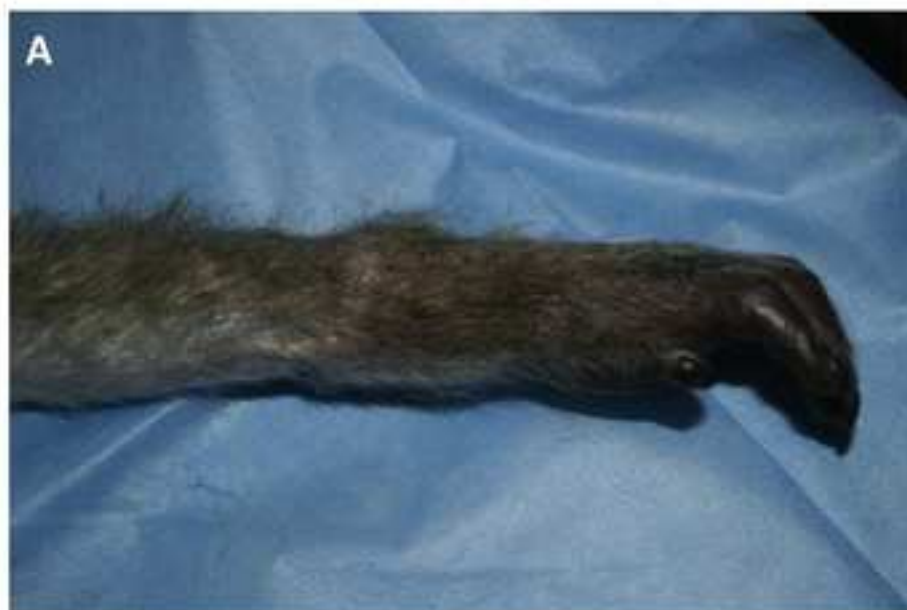Figure
[Click here to download high resolution image](#)



Name

ORTHOPEDIC EQUIPMENT

- Electric Pen Drive
- Low Contact Dynamic Compression Plate, 2mm, 4 hole
- Low Contact Dynamic Compression Plate, 2mm, 6 hole
- Titanium cortex screws, self tapping, 2mm

GENERAL SURGICAL INSTRUMENTS

- Adsons forceps
- Geralds forceps
- Scalpel handle
- Scalpel blades, No. 15
- Tenotomy scissors
- Mayo scissors
- Mosquito clamps
- Needle driver
- Bipolar diathermy forceps
- Micro hemaclip applier

MICROSURGICAL INSTRUMENTS

- Jewlers forceps
- Micro scissors
- Micro needle driver
- Vessel dilator
- Anterior chamber needle
- Ackland clamps (single)
- Ackland clamps (approximator)

MEDICATIONS

- Isoflurane
- Ketamine
- Buprenorphine
- Banamine
- Cefazolin

INTRAVENOUS FLUIDS

- 0.9% Normal Saline
- 5% Dextrose
- Albumin 5%
- Dopamine 40mg/ml

[illegible]

Comments

Reciprocating saw/drill

Ulna plate

Radius plate

1-3% Inhaled in Oxygen

1 mg/ml 5-10ml/hr CRI

0.01mg/kg IV 12 hourly

1mg/kg IM pre-operatively and post operatively

25mg/kg IM pre and post operatively

5 ml/kg/hr intraoperatively

run at 5ml/hr before and after FK infusion

5 ml/kg/hr intraoperatively

as needed intraoperatively



1 Alewife Center #200
Cambridge, MA 02140
tel. 617.945.9051
www.jove.com

ARTICLE AND VIDEO LICENSE AGREEMENT

Title of Article:

UPPER EXTREMITY TRANSPLANTATION IN NON-HUMAN PRIMATES -

Author(s):

LEONARD, POWELL, ALBERTO, SHAN MUGARAJAH, MASTROIANI, LOFGREN,
WINTER, KURTZ, CETRUSO

Item 1 (check one box): The Author elects to have the Materials be made available (as described at <http://www.jove.com/publish>) via: ☒ Standard Access ☐ Open Access

Item 2 (check one box):

- ☒ The Author is NOT a United States government employee.
- ☐ The Author is a United States government employee and the Materials were prepared in the course of his or her duties as a United States government employee.
- ☐ The Author is a United States government employee but the Materials were NOT prepared in the course of his or her duties as a United States government employee.

ARTICLE AND VIDEO LICENSE AGREEMENT

1. **Defined Terms.** As used in this Article and Video License Agreement, the following terms shall have the following meanings: "**Agreement**" means this Article and Video License Agreement; "**Article**" means the article specified on the last page of this Agreement, including any associated materials such as texts, figures, tables, artwork, abstracts, or summaries contained therein; "**Author**" means the author who is a signatory to this Agreement; "**Collective Work**" means a work, such as a periodical issue, anthology or encyclopedia, in which the Materials in their entirety in unmodified form, along with a number of other contributions, constituting separate and independent works in themselves, are assembled into a collective whole; "**CRC License**" means the Creative Commons Attribution-Non Commercial-No Derivs 3.0 Unported Agreement, the terms and conditions of which can be found at: <http://creativecommons.org/licenses/by-nc-nd/3.0/legalcode>; "**Derivative Work**" means a work based upon the Materials or upon the Materials and other pre-existing works, such as a translation, musical arrangement, dramatization, fictionalization, motion picture version, sound recording, art reproduction, abridgment, condensation, or any other form in which the Materials may be recast, transformed, or adapted; "**Institution**" means the institution, listed on the last page of this Agreement, by which the Author was employed at the time of the creation of the Materials; "**JOVE**" means MyJove Corporation, a Massachusetts corporation and the publisher of *The Journal of Visualized Experiments*; "**Materials**" means the Article and / or the Video; "**Parties**" means the Author and JOVE; "**Video**" means any video(s) made by the Author, alone or in conjunction with any other parties, or by JOVE or its affiliates or agents, individually or in collaboration with the Author or any other parties, incorporating all or any portion of the Article, and in which the Author may or may not appear.

2. **Background.** The Author, who is the author of the Article, in order to ensure the dissemination and protection of the Article, desires to have the JOVE publish the Article and create and transmit videos based on the Article. In furtherance of such goals, the Parties desire to memorialize in this Agreement the respective rights of each Party in and to the Article and the Video.

3. **Grant of Rights in Article.** In consideration of JOVE agreeing to publish the Article, the Author hereby grants to JOVE, subject to Sections 4 and 7 below, the exclusive, royalty-free, perpetual (for the full term of copyright in the Article, including any extensions thereto) license (a) to publish, reproduce, distribute, display and store the Article in all forms, formats and media whether now known or hereafter developed (including without limitation in print, digital and electronic form) throughout the world, (b) to translate the Article into other languages, create adaptations, summaries or extracts of the Article or other Derivative Works (including, without limitation, the Video) or Collective Works based on all or any portion of the Article and exercise all of the rights set forth in (a) above in such translations, adaptations, summaries, extracts, Derivative Works or Collective Works and (c) to license others to do any or all of the above. The foregoing rights may be exercised in all media and formats, whether now known or hereafter devised, and include the right to make such modifications as are technically necessary to exercise the rights in other media and formats. If the "Open Access" box has been checked in Item 1 above, JOVE and the Author hereby grant to the public all such rights in the Article as provided in, but subject to all limitations and requirements set forth in, the CRC License.

ARTICLE AND VIDEO LICENSE AGREEMENT

4. Retention of Rights in Article. Notwithstanding the exclusive license granted to JoVE in **Section 3** above, the Author shall, with respect to the Article, retain the non-exclusive right to use all or part of the Article for the non-commercial purpose of giving lectures, presentations or teaching classes, and to post a copy of the Article on the Institution's website or the Author's personal website, in each case provided that a link to the Article on the JoVE website is provided and notice of JoVE's copyright in the Article is included. All non-copyright intellectual property rights in and to the Article, such as patent rights, shall remain with the Author.

5. Grant of Rights in Video – Standard Access. This **Section 5** applies if the "Standard Access" box has been checked in **Item 1** above or if no box has been checked in **Item 1** above. In consideration of JoVE agreeing to produce, display or otherwise assist with the Video, the Author hereby acknowledges and agrees that, Subject to **Section 7** below, JoVE is and shall be the sole and exclusive owner of all rights of any nature, including, without limitation, all copyrights, in and to the Video. To the extent that, by law, the Author is deemed, now or at any time in the future, to have any rights of any nature in or to the Video, the Author hereby disclaims all such rights and transfers all such rights to JoVE.

6. Grant of Rights in Video – Open Access. This **Section 6** applies only if the "Open Access" box has been checked in **Item 1** above. In consideration of JoVE agreeing to produce, display or otherwise assist with the Video, the Author hereby grants to JoVE, subject to **Section 7** below, the exclusive, royalty-free, perpetual (for the full term of copyright in the Article, including any extensions thereto) license (a) to publish, reproduce, distribute, display and store the Video in all forms, formats and media whether now known or hereafter developed (including without limitation in print, digital and electronic form) throughout the world, (b) to translate the Video into other languages, create adaptations, summaries or extracts of the Video or other Derivative Works or Collective Works based on all or any portion of the Video and exercise all of the rights set forth in (a) above in such translations, adaptations, summaries, extracts, Derivative Works or Collective Works and (c) to license others to do any or all of the above. The foregoing rights may be exercised in all media and formats, whether now known or hereafter devised, and include the right to make such modifications as are technically necessary to exercise the rights in other media and formats. For any Video to which this Section 6 is applicable, JoVE and the Author hereby grant to the public all such rights in the Video as provided in, but subject to all limitations and requirements set forth in, the CRC License.

7. Government Employees. If the Author is a United States government employee and the Article was prepared in the course of his or her duties as a United States government employee, as indicated in **Item 2** above, and any of the licenses or grants granted by the Author hereunder exceed the scope of the 17 U.S.C. 403, then the rights granted hereunder shall be limited to the maximum rights permitted under such

statute. In such case, all provisions contained herein that are not in conflict with such statute shall remain in full force and effect, and all provisions contained herein that do so conflict shall be deemed to be amended so as to provide to JoVE the maximum rights permissible within such statute.

8. Likeness, Privacy, Personality. The Author hereby grants JoVE the right to use the Author's name, voice, likeness, picture, photograph, image, biography and performance in any way, commercial or otherwise, in connection with the Materials and the sale, promotion and distribution thereof. The Author hereby waives any and all rights he or she may have, relating to his or her appearance in the Video or otherwise relating to the Materials, under all applicable privacy, likeness, personality or similar laws.

9. Author Warranties. The Author represents and warrants that the Article is original, that it has not been published, that the copyright interest is owned by the Author (or, if more than one author is listed at the beginning of this Agreement, by such authors collectively) and has not been assigned, licensed, or otherwise transferred to any other party. The Author represents and warrants that the author(s) listed at the top of this Agreement are the only authors of the Materials. If more than one author is listed at the top of this Agreement and if any such author has not entered into a separate Article and Video License Agreement with JoVE relating to the Materials, the Author represents and warrants that the Author has been authorized by each of the other such authors to execute this Agreement on his or her behalf and to bind him or her with respect to the terms of this Agreement as if each of them had been a party hereto as an Author. The Author warrants that the use, reproduction, distribution, public or private performance or display, and/or modification of all or any portion of the Materials does not and will not violate, infringe and/or misappropriate the patent, trademark, intellectual property or other rights of any third party. The Author represents and warrants that it has and will continue to comply with all government, institutional and other regulations, including, without limitation all institutional, laboratory, hospital, ethical, human and animal treatment, privacy, and all other rules, regulations, laws, procedures or guidelines, applicable to the Materials, and that all research involving human and animal subjects has been approved by the Author's relevant institutional review board.

10. JoVE Discretion. If the Author requests the assistance of JoVE in producing the Video in the Author's facility, the Author shall ensure that the presence of JoVE employees, agents or independent contractors is in accordance with the relevant regulations of the Author's institution. If more than one author is listed at the beginning of this Agreement, JoVE may, in its sole discretion, elect not take any action with respect to the Article until such time as it has received complete, executed Article and Video License Agreements from each such author. JoVE reserves the right, in its absolute and sole discretion and without giving any reason therefore, to accept or decline any work submitted to JoVE. JoVE and its employees, agents and independent contractors shall have

ARTICLE AND VIDEO LICENSE AGREEMENT

full, unfettered access to the facilities of the Author or of the Author's institution as necessary to make the Video, whether actually published or not. JoVE has sole discretion as to the method of making and publishing the Materials, including, without limitation, to all decisions regarding editing, lighting, filming, timing of publication, if any, length, quality, content and the like.

11. **Indemnification.** The Author agrees to indemnify JoVE and/or its successors and assigns from and against any and all claims, costs, and expenses, including attorney's fees, arising out of any breach of any warranty or other representations contained herein. The Author further agrees to indemnify and hold harmless JoVE from and against any and all claims, costs, and expenses, including attorney's fees, resulting from the breach by the Author of any representation or warranty contained herein or from allegations or instances of violation of intellectual property rights, damage to the Author's or the Author's institution's facilities, fraud, libel, defamation, research, equipment, experiments, property damage, personal injury, violations of institutional, laboratory, hospital, ethical, human and animal treatment, privacy or other rules, regulations, laws, procedures or guidelines, liabilities and other losses or damages related in any way to the submission of work to JoVE, making of videos by JoVE, or publication in JoVE or elsewhere by JoVE. The Author shall be responsible for, and shall hold JoVE harmless from, damages caused by lack of sterilization, lack of cleanliness or by contamination due to the making of a video by JoVE its employees, agents or independent contractors. All sterilization, cleanliness or decontamination procedures shall be solely the responsibility of the Author and shall be undertaken at the Author's

expense. All indemnifications provided herein shall include JoVE's attorney's fees and costs related to said losses or damages. Such indemnification and holding harmless shall include such losses or damages incurred by, or in connection with, acts or omissions of JoVE, its employees, agents or independent contractors.

12. **Fees.** To cover the cost incurred for publication, JoVE must receive payment before production and publication the Materials. Payment is due in 21 days of invoice. Should the Materials not be published due to an editorial or production decision, these funds will be returned to the Author. Withdrawal by the Author of any submitted Materials after final peer review approval will result in a US\$1,200 fee to cover pre-production expenses incurred by JoVE. If payment is not received by the completion of filming, production and publication of the Materials will be suspended until payment is received.

13. **Transfer, Governing Law.** This Agreement may be assigned by JoVE and shall inure to the benefits of any of JoVE's successors and assignees. This Agreement shall be governed and construed by the internal laws of the Commonwealth of Massachusetts without giving effect to any conflict of law provision thereunder. This Agreement may be executed in counterparts, each of which shall be deemed an original, but all of which together shall be deemed to be one and the same agreement. A signed copy of this Agreement delivered by facsimile, e-mail or other means of electronic transmission shall be deemed to have the same legal effect as delivery of an original signed copy of this Agreement.

A signed copy of this document must be sent with all new submissions. Only one Agreement required per submission.

CORRESPONDING AUTHOR:

Name: DAVID A. LEONARD, M.D., M.B.A., M.P.H.
Department: TBRC
Institution: MGH
Article Title: UPPER EXTREMITY TRANSPLANTATION IN NON-HUMAN PRIMATES
Signature: David Leonard Date: 6/5/14

Please submit a signed and dated copy of this license by one of the following three methods:

- 1) Upload a scanned copy of the document as a pdf on the JoVE submission site;
- 2) Fax the document to +1.866.381.2236;
- 3) Mail the document to JoVE / Attn: JoVE Editorial / 1 Alewife Center #200 / Cambridge, MA 02139

For questions, please email submissions@jove.com or call +1.617.945.9051

David Leonard, MBChB, MRCS

*Transplantation Biology Research Center
Massachusetts General Hospital*

June 9th 2014

Dear Editor

Thank you for your review and comments. Please find below a point-by-point response in addition to the requested changes, identified by track-changes, in the revised manuscript. Please accept my apologies that these did not get returned to you by the requested date; this was unfortunately beyond my control, and I have addressed the issue as quickly as possible since it came to my attention. I hope that this delay has not caused undue inconvenience, and that it will not preclude further review of this manuscript.

Editorial comments: *(Responses in italics)*

1. Please add a one line space between each step and sub-steps of your protocol section.

Spaces have been added

2. Please re-write steps of your protocol section in imperative tense, as if you are telling someone how to do the technique (i.e. "Do this", "Measure that" etc.). For example, step 1.1, please begin with "Use cynomolgus macaques..". In step 2.2, "...should be clipped" etc

Protocol steps have been re-written in imperative tense.

3. In step 1.2 please consider rephrasing "Planning meeting" and begin as "Plan surgery..".

Step 1.2 has been rephrased accordingly.

4. Please define all abbreviations upon its first occurrence. For instance "IM" in step 2.1, "OR" in 2.2 etc.

5. In step 2.2, how is sedation confirmed, please specify.

Sedation is confirmed by observation. This step has been clarified.

6. Please write step 2.2 in imperative tense.

Step 2.2 has been revised.

7. In step 2.5 please specify what fluids are being administered. Please specify list of all reagents, materials, tools, equipment's used in the materials and equipment's table.

Intraoperative fluids include 0.9% normal saline and 5% dextrose. Details have been added to point 2.5 and the materials table updated.

8. Please rephrase step 2.6 in imperative tense.

2.6 has been revised.

9. In step 2.10 please replace betadine with povidone-iodine.

2.10 has been revised.

10. Please rephrase step 4.15 in imperative tense and please mention "We routinely..." as a NOTE under this step.

4.15 has been revised, and note added.

11. In step 5.3 please replace "We find.." with "Use 2.0 mm compression plates for..".

5.3 has been addressed.

12. In step 6.1 please place "The elbow should be.." as a NOTE.

6.1 has been revised and note added.

13. Please rephrase step 6.2 in imperative tense.

6.2 has been revised and a note added.

14. Please provide a representative result that shows the immunological and functional outcomes following the surgery.

Further details of the functional outcomes have been added to the representative results section. The immunological outcome has been augmented by addition of representative histology, demonstrating the absence of rejection, to figure 6. We hope that this adequately addresses this critique.

15. Please cite all the figures in the protocol text where applicable.

Figures are cited in text were applicable.

16. Your protocol exceeds the 2.75 page of highlighting. After you have made all of the recommended changes to your protocol (listed above), please re-evaluate the length of your protocol section. There is no page limit for the protocol text, but there is a 3 pages limit for filmable content. If your protocol is longer than 3 pages, please highlight (in yellow) 2.75 pages (or less) of text to identify which portions of the protocol are most important to include in the video; i.e. which steps should be visualized to tell the most cohesive story of your protocol steps. Please see JoVEs instructions for authors for more clarification. Remember that the non-highlighted protocol steps will remain in the manuscript and therefore will still be available to the reader.

Highlighting has been revised to meet 2.75 page limit.

17. Please revise the text to avoid the use of any pronouns (i.e. "our"). Please use the Ctrl+F function to find and replace the pronouns.

The manuscript has been reviewed to replace pronouns.

18. Please print and sign the attached Author License Agreement, then scan and upload it with your manuscript files.

Please find attached author license agreement.

19. Due to the nature of being a video based journal, JoVE authors must be very specific when it comes to the humane treatment of animals. Regarding animal treatment in your protocol, please only add the following information to your text if applicable:

a) Please include an ethics statement before your numbered protocol steps indicating that the protocol follows the animal care guidelines of your institution.

The ethics statement already in place has been expanded.

b) Please specify the euthanasia method.

Two options are available for euthanasia. These have been specified in Note 1 to Point 4.15.

c) Please mention how animals are anesthetized and how proper anesthetization is confirmed.

Anesthetic details are covered in protocol section 2. Point 2.8 has been expanded to clarify assessment of anesthetic depth.

d) Use of vet ointment on eyes to prevent dryness while under anesthesia.

This statement has been added to point 2.4

e)For survival strategies, discuss post-surgical treatment of animal, including recovery conditions and treatment for post-surgical pain.

These topics are covered in detail in protocol section 6.

f)Do not leave an animal unattended until it has regained sufficient consciousness to maintain sternal recumbency.

With due respect, sternal recumbency is not relevant to assessment of recovery in non-human primates. Protocol section 6.5 includes the statement “monitor continually until fully alert and recovered from anesthesia”, we trust this statement will be sufficient.

g)Do not return an animal that has undergone surgery to the company of other animals until fully recovered.

This statement is not applicable to this protocol. Due to the potential for interference with the transplanted hand, and the risk of severe wound infections following otherwise minor injuries while under immunosuppression, animals on this protocol currently remain individually housed and are not returned to group housing. Careful monitoring of psychological well being is conducted by investigators and non-human primate enrichment specialists. This is all in accordance with best practice and all necessary guidelines, but is not easily and concisely described in a few lines of text. For the time being we have not included a specific alternative statement, but if journal policy or editorial/review preference is that some additional statement is required we should appreciate your advice on how best to address this – would, for example, something similar to the second and third sentences of this paragraph be appropriate?

20.Please make sure that the “Discussion” section covers the following points running between 3 – 6 paragraphs.

- a)Critical steps within the protocol
- b)Modifications and troubleshooting
- c)Limitations of the technique
- d)Significance of the technique with respect to existing/alternative methods
- e)Future applications or directions after mastering this technique

The discussion has been reviewed to ensure these points are addressed, and some additional discussion added where necessary.

We hope that these revisions adequately address your editorial concerns. Again, please accept my

sincerely apologies that these revisions are being returned later than the requested date. We hope that this does not cause undue inconvenience and that it will be possible for this paper to continue through the editorial and review process.

Many thanks, and kind regards

David A. Leonard, MBChB, MRCS

*Research Fellow
Vascularized Composite Allotransplantation Laboratory
Transplantation Biology Research Center
Massachusetts General Hospital
MGH-East Building 149-9019
13th Street
Boston
MA, 02129*

Email: david.leonard@tbrc.mgh.harvard.edu

David Leonard, MBChB, MRCS

*Transplantation Biology Research Center
Massachusetts General Hospital*

August 13th 2014

Dear Editor

Thank you for your review and comments. Please find below a point-by-point response in addition to the requested changes, identified by track-changes, in the revised manuscript.

Editorial comments:

1) Please keep the editorial comments from your previous revisions in mind as you revise your manuscript to address peer review comments. For instance, if formatting or other changes were made, commercial language was removed, etc., please maintain these overall manuscript changes.

Previous revisions have been retained.

2) Please take this opportunity to thoroughly proofread your manuscript to ensure that there are no spelling or grammar issues. Your JoVE editor will not copy-edit your manuscript and any errors in your submitted revision may be present in the published version.

A further, thorough proofreading of this manuscript has been performed.

3) If your figures and tables are original and not published previously, please ignore this comment. For figures and tables that have been published before, please include phrases such as “Re-print with permission from (reference#)” or “Modified from..” etc. And please send a copy of the re-print permission for JoVE’s record keeping purposes.

All figures etc presented in this manuscript are original and have not previously been published.

Reviewers' comments:

Reviewer #1:

Manuscript Summary:

This well-written and well-illustrated manuscript described an alternative translational VCA model in the NHP. This model contains vascularized bone marrow and can mimic closely the hand transplant scenario

in humans. All sections of the manuscript have been developed well and I recommend this manuscript for publication without reserves.

Major Concerns:

No major concerns.

Minor Concerns:

No minor concerns.

Additional Comments to Authors:

It would have been appropriate to have a short, additional comment in the introduction section highlighting the importance of the vascularized bone marrow presence in this model.

Thank you for your review and comments. With regard to the presence of vascularized bone marrow, we agree that this is potentially of significant importance in this model. However, we have not as yet performed a quantification of the viable marrow volume in this model, similar to that previously reported by Barth and colleagues for their heterotopic partial facial subunit model, and until such data are available we feel any comment on this issue in the context of our model would lack foundation.

Reviewer #2:

Manuscript Summary:

The manuscript entitled "Upper extremity transplantation in non-human primates: an orthotopic model for translational research" reports an experimental model in Cynomolgus macaques that can be used in VCA.

The originality is based on the surgical procedure which allows to achieve in these non-human primates a model close to human upper extremity transplantation allowing immunological and functional studies.

The Authors explain well its utility and report clearly and in detailed manner the surgical procedure.

Two autologous replantations and four allotransplantations were performed to show the feasibility of the model. Fifty percent of the transplanted animals were lost and the cause was vascular in two of them.

Major Concerns:

N/A

Minor Concerns:

N/A

Additional Comments to Authors:

The very small group of animals included in the study represents its major limit

Thank you for your review and comments. We agree that small group size is a limitation at the present time, but nonetheless believe that current numbers are sufficient to demonstrate the feasibility and utility of the model described. Studies using this model are ongoing, and practical limitations on group sizes in large animal studies notwithstanding, we hope to report experimental findings supported by sufficient numbers to demonstrate statistical significance, or lack thereof, in due course.

We wish to thank the editorial team and reviewers for their comments and critique, and trust that the revisions and responses provided adequately address the issues raised.

Many thanks, and kind regards

David A. Leonard, MBChB, MRCS

*Research Fellow
Vascularized Composite Allotransplantation Laboratory
Transplantation Biology Research Center
Massachusetts General Hospital
MGH-East Building 149-9019
13th Street
Boston
MA, 02129*

Email: david.leonard@tbrc.mgh.harvard.edu