
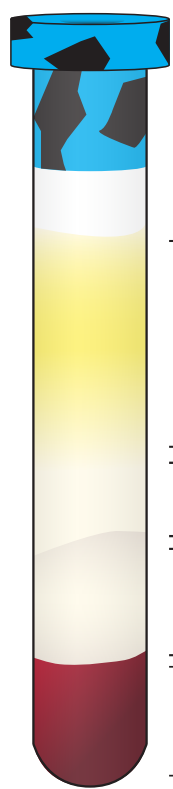


Before



After



Plasma layer

Mononuclear layer

Gel layer

Packed erythrocytes
and granulocytes