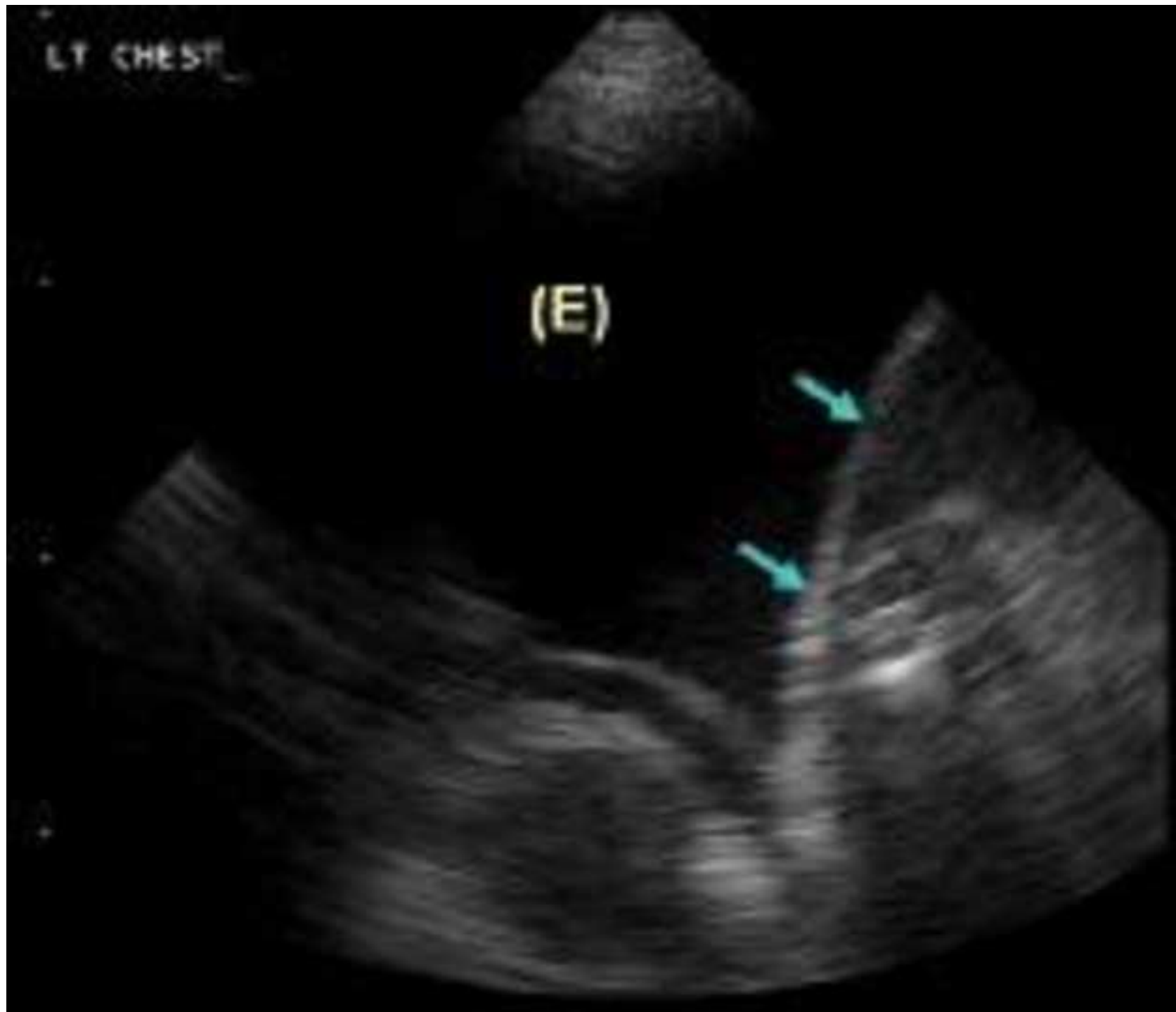

JoVE: Science Education
Thoracentesis with Catheter Insertion
--Manuscript Draft--

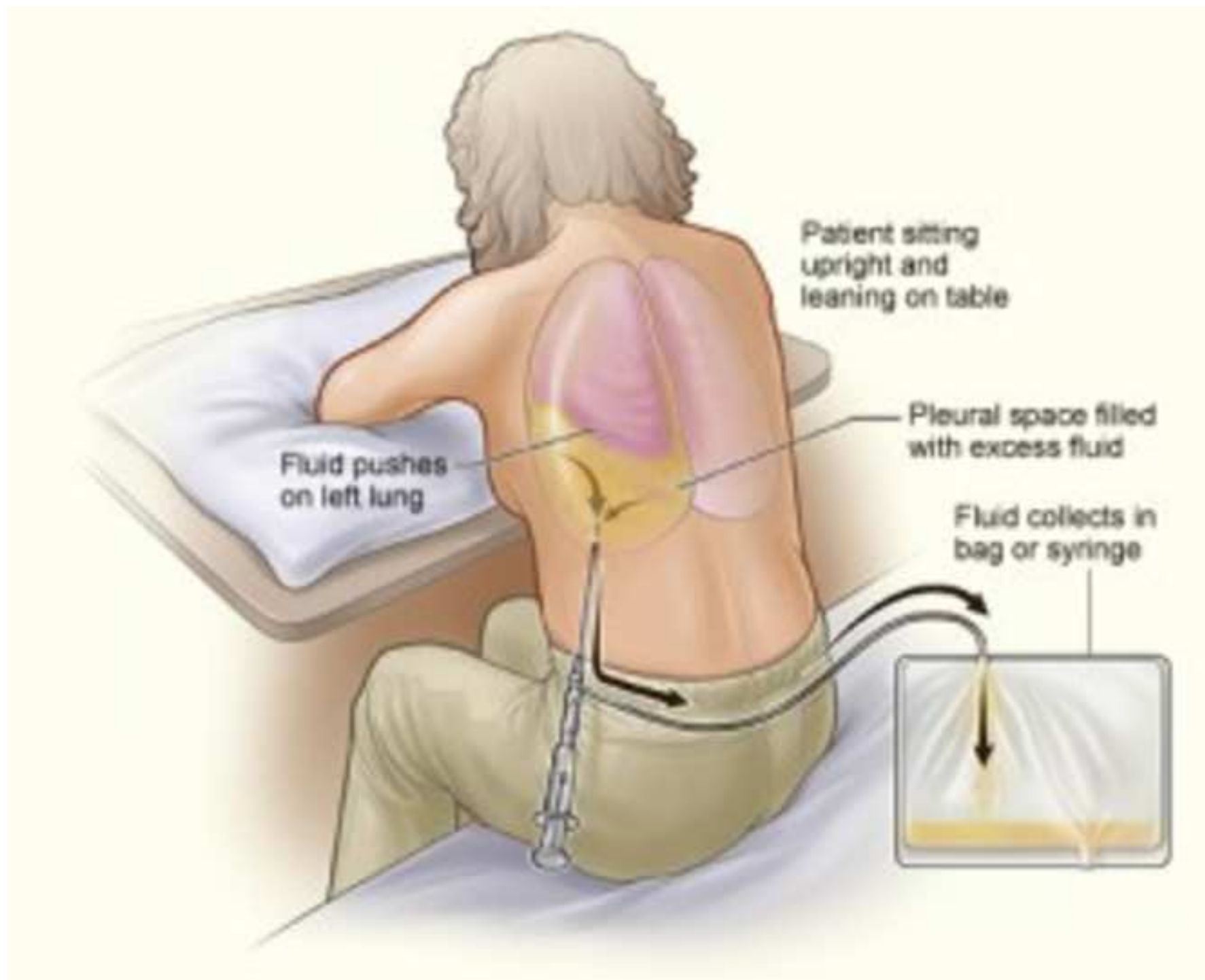
Manuscript Number:	10206
Full Title:	Thoracentesis with Catheter Insertion
Article Type:	Manuscript
Section/Category:	Manuscript Submission
Corresponding Author:	Megan Fashjian UNITED STATES
Corresponding Author Secondary Information:	
Corresponding Author's Institution:	
Corresponding Author's Secondary Institution:	
First Author:	Megan Fashjian
First Author Secondary Information:	
Order of Authors:	Megan Fashjian
Order of Authors Secondary Information:	



Light's criteria for distinguishing pleural transudate from exudate

Pleural fluid is an exudate if one or more of the following criteria are met:

- Pleural fluid protein:serum protein ratio > 0.5
- Pleural fluid LDH:serum LDH ratio > 0.6
- Pleural fluid LDH $>$ two-thirds of the upper limit of normal serum LDH



Author Name: Meghan Fashjian

Clinical Skills Education Title: Thoracentesis with Catheter Insertion

Overview:

Thoracentesis is a puncture through the chest wall into the pleural cavity for the purpose of aspirating pleural fluid. Thoracentesis serves both diagnostic and therapeutic purposes in patients with pleural effusion. Diagnostic thoracentesis removes a small amount of pleural fluid for evaluation of effusion with unknown etiology. Therapeutic thoracentesis is performed to reduce the symptoms related to large pleural effusions (such as dyspnea, cough, chest discomfort, and pleuritic chest pain).

Historically, thoracentesis was performed blindly- the size of effusion was determined by chest x-ray and percussion of the chest. Now ultrasound is available almost universally, allowing thoracentesis to be performed under imaging guidance. This reduces the risk of complication such as pneumothorax or a misplaced catheter. Free-flowing effusions are best suited for thoracentesis. More complex effusions may require chest tube placement.

There are no absolute contraindications, however, if there are multiple coagulopathies these should be weighed against the benefit of immediate procedure. These should be corrected when possible. If there is an urgent need to perform procedure, it is overall safe and the risks are minimal when performed properly.

Procedure:

1. Collect the necessary equipment

The equipment needed is:

- 6F or 8F catheter drainage device
- Universal drainage set
- Fluid collection bag
- 19G Filter needle
- 22G or 25G needle
- Luer-Lock syringe 10mL
- Luer-Lock syringe 60mL
- 1 ABG syringe
- Scalpel
- Chloraprep 10mL
- Three specimen vials
- Two ampules Lidocaine 1% (total 10mL)
- Needle stop
- Fenestrated drape

Commented [AS1]: F or Fr stands for so-called "French scale" for the catheter size. It is a commonly used system.

- Gauze
- Towel
- Bandage

2. Preparation for the procedure

2.1. Have the patient sit on the edge of the bed/stretcher with their legs hanging over, touching the floor. This is ideal positioning (**Figure 1**). If the patient is unable to sit up, perform the procedure in supine or lateral decubitus position.

2.2. Place the patient's arms on the bedside table (make sure the table is at an appropriate height). This position helps to open up the intercostal spaces allowing for easier passage of the catheter.

2.3 Make sure the patient's back is exposed, with no clothing or blankets that can potentially fall into the sterile field.

2.4 Place a fluid protective barrier on the bed/stretcher.

2.5 Have a **available** support personnel available to gather extra supplies once you are sterile.

3. Marking the insertion site

Prior the procedure, mark the site on the chest wall where the catheter will be inserted. Traditionally the level of effusion has been estimated by percussion. Currently the recommended method is to visualize the effusion by the chest ultrasound.

3.1 Estimating the level of effusion by percussion

3.1.1 Percuss posteriorly from the top of the rib cage down each intercostal space listening for dull sound that may indicate pleural effusion. Percussion should be performed posteriorly as dullness in the right anterior lower chest will mark the liver, and in the left anterior lower chest will mark the heart borders.

3.2 Visualizing the fluid by ultrasound (**Figure 2**).

3.2.1 If needed, record the patient identifiers in the machine prior to beginning exam.

3.2.2 Place the US gel on the probe.

3.2.3 Place the probe on the patient's back using proper orientation.

3.2.4 Search first for the diaphragm. If it is difficult to find, search for a kidney on that side.

3.2.5 Once the diaphragm is identified, qualify the ~~type~~ (echogenicity) and volume of effusion.

Commented [DM2]: Production- let us know if you want this cut.

Commented [DN3]: I think this list is important and should not be cut.

Commented [AS4]: This is a drawing that needs to be reproduced at your discretion.

Commented [AS5]: I asked to add this part because not all the institutions have access to chest ultrasound.

Commented [AS6]: Figure 2 is a photograph that can be taken as a still shot during the filming.

Commented [AS7]: I think the word "type" here was used as a synonym to "echogenicity" – which is a term to describe the strength of signal ("echo") and, simply put, reflects the darkness of the pixels on the screen – the more echogenic the structure appears the brighter is the signal. AS 0728

Commented [DN8]: How can one qualify the type using US?

3.2.6 Make note of the depth of effusion. If the depth of the effusion is greater than 2cm it is safe to proceed.

3.2.7 To avoid the damage to the lung and visceral pleura, make sure that there is no evidence of the 3.2.7 Make sure there is no "curtain sign" (the intermittent obscuration of pleural effusion by the lung during respiratory cycle). pleural gliding against each other as the lung descends) present so the damage to the visceral pleura or lung which may create a fistula or air leak is avoided.

Commented [AS9]: Changed. AS 0728

3.3 Once a suitable pocket of fluid is located by ultrasound mark the space with a skin marker. When the patient is in a sitting position the ideal space should be mid-scapular (or at least 10 cm lateral to spine), above the ninth rib (to avoid the diaphragm). If the level of fluid is estimated by percussion, the insertion site should be one or two intercostal spaces below the level of effusion, 10 cm lateral to the spine and above the ninth rib.

Commented [AS10]: As chest sonography and US findings are complex subject and are beyond the scope of the manuscript, perhaps this part can be omitted from the script. However, Ms Fashjian will be performing the ultrasound as a part of the procedure to visualize the pleural effusion to be aspirated.

Commented [DN11]: This seems to be awkwardly phrased.

3.4 Instruct the patient to hold position and not move around.

Commented [AS12]: I think this sentence does not have to be scripted but might stay in the accompanying manuscript. AS

Commented [DN13]: Again, if length permits, in my opinion, this should be incorporated in the video.

4 Thoracentesis

4.1 Perform a "time-out" pre-procedure verification of the patient, the procedure, and the site of the procedure ("time-out") per your institution's policy.

Commented [AS14]: Re-phrased AS 0728

4.2. Put on the hat and mask with shield, as well as the gown and gloves using the sterile technique.

Commented [DN15]: I think the time-out does not refer to just the site of the procedure, it refers to everything. If that's correct, please consider rephrasing the sentence.

4.3. Clean the skin with chlorhexidine or available sterilizing agent. Be sure to clean a wide area around the marked space.

4.3.1. Place sterile drapes on the stretcher/bed.

4.4. Place sterile drapes on the patient to isolate the sterilized area around the marked skin.

4.5. Fill a 10mL syringe using a filter needle with lidocaine to be used as a local anesthetic (most kits contain 10mL of lidocaine (1% or 2%) in glass ampules).

4.6. Introduce the lidocaine and make a small wheal at the predetermined site of insertion.

4.6.1. Using a 25g needle on the syringe, brace the non-dominant hand against the patient gently stabilizing the needle.

4.6.2. With the dominant hand, guide the bevel of the needle under the skin (needle should be perpendicular to the patient) and give 2mL of lidocaine just under the skin to create a wheal.

4.6.3. Advance the needle slightly just over the top of the rib to avoid the intercostal arteries and the nerve bundles, then aspirate the syringe.

4.6.4. If no flow is observed with aspiration, continue to advance, aspirate, and infiltrate the subcutaneous tissues with lidocaine until you aspirate pleural fluid. Do not advance the needle any further.

4.6.5. Once the pleural fluid is aspirated, pull back 1-2 mm and then bolus the remaining lidocaine onto the pleura.

4.6.6. Remove the needle (do not instill lidocaine into the tract while retracting to avoid seeding the space).

4.7. Prepare the remainder of the kit.

4.7.1. Set aside the specimen containers on the sterile field including ABG syringe (for pH measurement).

4.7.2. Thread the blunt tip needle through the catheter.

4.7.3. Set up the preferred drainage method. For this video we will use a series of one-way valves into a drainage bag.

4.8. Using a scalpel, make a small incision in the skin at the site previously marked.

4.9 Insert the catheter. The insertion needle length and gauge will vary kit-to-kit.

4.9.1. Brace the non-dominant hand against the patient.

4.9.2. Using the dominant hand, advance the needle forward, simultaneously creating negative pressure on the end of the syringe until the fluid is aspirated. Presence of the fluid indicates that the catheter is in pleural space.

4.9.3 Advance the catheter over the needle and slowly retract the needle.

4.10. Attach the one way tubing to the end of the catheter.

4.11 Once the tubing is attached to a syringe, aspirate the fluid and collect the samples for laboratory analyses. Pleural pressures ~~are~~ *should be* obtained as each aliquot is removed (250mL-500mL) as well. For the cytological analysis, a minimum of 50mL is required. Additional fluid should be obtained for other tests, such as cell counts, pH, etc.

4.11 Once the samples are obtained, measure the opening pleural pressures. The aspiration should stop when the pleural pressure drops to -20mm H2O.

4.12 When ready to remove the catheter generate negative pressure with the syringe by pulling back on the plunger or have the patient generate negative pressure by continuously humming or saying 'E'.

Commented [AS16]: Measuring pleural pressures is beyond the scope of the manuscript, so I think this sentence can be omitted from the script and left in the manuscript only.

Commented [AS17]: I think this sentence is optional. AS

4.12. After the catheter has been removed, make sure there is no bleeding or oozing (if there is continue to apply pressure until it stops), and place a bandage and a clean dry dressing over the insertion site.

5. Post-procedural care.

Post-procedural care is dependent upon each institution. Often a chest x-ray is obtained to rule out pneumothorax, but is not required. If there is no evidence of pneumothorax the patient is released to home.

Summary:

A thoracentesis is a bedside procedure that can yield valuable diagnostic information as well as offer therapeutic benefit in patients with pleural effusion. It can be done in the clinic or at bedside with minimal risk.

The procedure should be performed under US guidance by an experienced clinician. If US is not available, the extent of the effusion can be determined by chest percussion and chest X-ray. Biochemical, microbiological, and cytological analyses of the aspirated fluid allow one to narrow down the differential diagnosis of the effusion. Cytology and microbiological analysis are performed to determine if malignancy or infection is present. Biochemical analysis of the aspirated pleural fluid allows to distinguish exudates from transudates (Figure 3), which then guides the subsequent diagnostic workup. When thoracentesis is performed properly the risk of complications is very low.

Figures and legends.

Figure 1. Positioning of the patient for optimal catheter placement

Figure 2. Chest Ultrasound

Figure 3. Light's criteria

Commented [AS18]: I think Light's criteria (Figure 3) and the characteristics of exudate vs transudate might be beyond the scope of the manuscript so perhaps this paragraph doesn't need to be scripted.

Commented [DN19]: I agree, this is beyond the scope of this video.

Commented [AS20]: Figure 1 needs to be re-drawn if you decide to use it.

Commented [AS21]: Can be created at your discretion during the filming as a still shot. The image is provided as an example. I think this figure is optional since we don't discuss chest US in detail.

Commented [AS22]: I think this figure is optional.