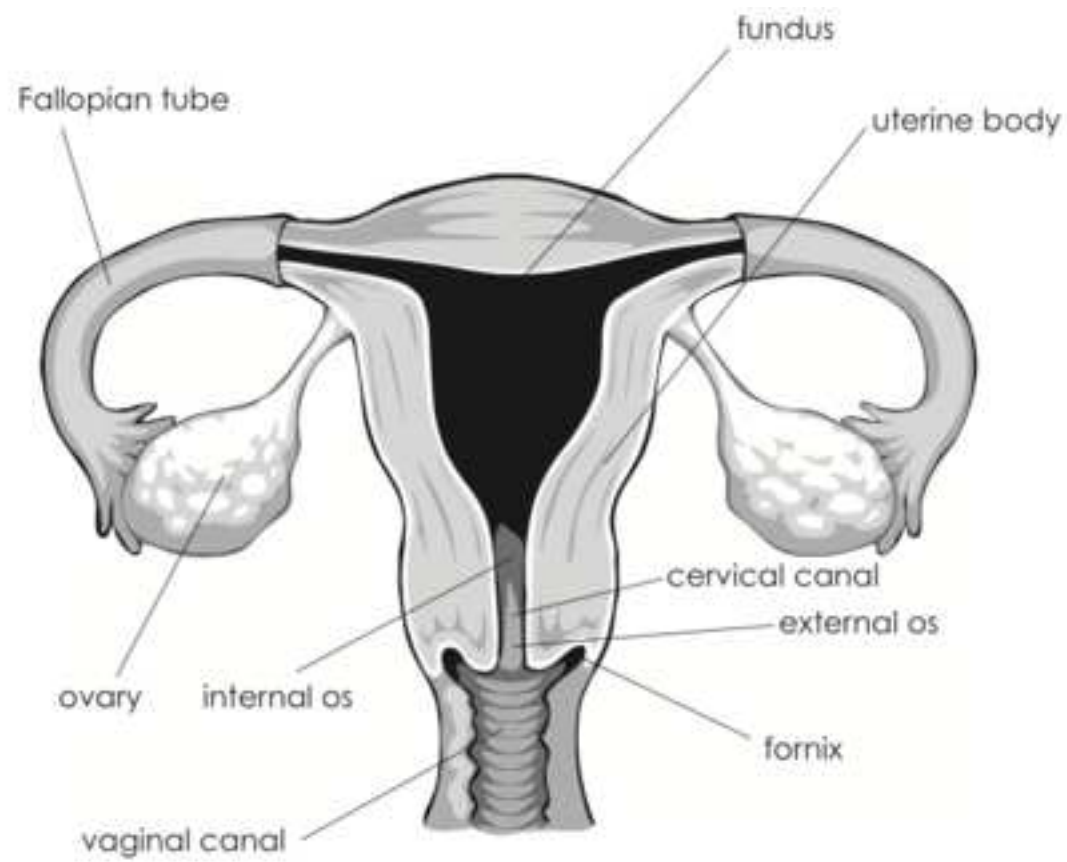
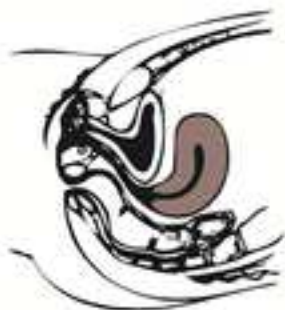

JoVE: Science Education
Bimanual and Rectovaginal Exam of the Non-Pregnant Patient
--Manuscript Draft--

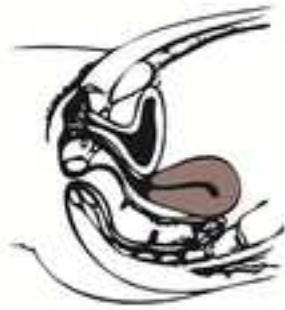Manuscript Number:	10163
Full Title:	Bimanual and Rectovaginal Exam of the Non-Pregnant Patient
Article Type:	Manuscript
Section/Category:	Manuscript Submission
Corresponding Author:	Alexandra Duncan UNITED STATES
Corresponding Author Secondary Information:	
Corresponding Author's Institution:	
Corresponding Author's Secondary Institution:	
First Author:	Alexandra Duncan
First Author Secondary Information:	
Order of Authors:	Alexandra Duncan Tiffany Cook Jaideep Talwalkar
Order of Authors Secondary Information:	



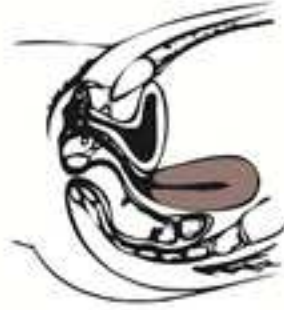Common Uterine Positions



anteverted



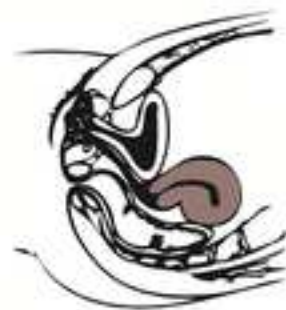retroverted



midline



anteflexed



retroflexed

Author Names: Alexandra Duncan, Tiffany Cook, Jaideep Talwalkar

Clinical Skills Education Title: Bimanual ~~and~~ Rectovaginal Exam ~~and Pelvic Exam~~
~~conclusion~~ of the Non-Pregnant Patient

Overview

A bimanual exam is a thorough check of a patient's cervix, uterus, and ovaries (**Figure 1**). It can tell an experienced provider a great deal, as it may lead to the discovery of abnormalities, such as cysts, fibroids, or malignancies, but it's useful even in the absence of such findings, as it allows the practitioner to establish an understanding of the patient's anatomy for future use.

Performing the bimanual exam before the speculum exam can help relax patients, mentally and physically, before what is often perceived as the "most invasive" part of the exam. A practitioner already familiar with the patient's anatomy can insert a speculum more smoothly and comfortably. However, lubrication used during the bimanual exam may interfere with processing certain samples obtained during the speculum exam. Providers must be familiar with local laboratory processing requirements before committing to a specific order of examination.

This demonstration begins immediately after the end of the speculum exam; therefore, it assumes the patient has provided a history and is in the modified lithotomy position.

A rectovaginal exam is not always necessary, but it may be performed to fully assess a retroverted uterus and ovaries (this may be the only way to accomplish full assessment depending on uterine position) or to assess the rectum.

Procedure

1. Bimanual Exam

1.1. Prepare the patient by saying, "I will now place two gloved fingers in your vagina and use my other hand to press on your abdomen to assess your uterus and ovaries."

1.2. Fully coat the first two fingers of your dominant hand with lubricant.

1.3. Sit and tell the patient you are placing one, then two fingers in their vagina.

1.3.1. Insert the dominant index finger, palm down with the other fingers tucked, 1" into the vaginal introitus. Apply posterior pressure to open the introitus and insert the middle finger.

1.4. Apply posterior pressure (to avoid tugging the labia) and supinate your hand.

1.5. Insert the fingers fully into the patient's vagina, while moving the labia away with your thumb on one side and your fourth and fifth fingers on the other (**Figure 2**).

Commented [DN1]: I think the title of this video can be simplified to Bimanual and Rectovaginal Exam, since the term Pelvic exam is really not used throughout the manuscript.

Commented [AS2]: This is a part of pelvic exam examination that is in a separate video because of the formatting constrains.

Commented [DN3]: Although, it is mentioned below that this image would be acquired during the video shoot, I'm not sure what it means.

Commented [JR4R3]: Instead of having the authors take a low-quality picture of the positioning of the hands themselves, they've suggested a higher-quality photo be taken while filming the demonstration at the video shoot, if possible.

1.6. Release the labia, rest your external fingers in the inguinal groove, and stand up.

1.7. Place your dominant foot on the footstool, tuck your dominant elbow into your side, and soften your wrist. If more pressure is needed to insert the fingers farther, stand straight and use your core to press forward without looming over the patient (**Figure 3**).

1.8.2. Cervical Check and Bimanual Exam

2-1.8.1. Place the fingers palm up on the posterior (bottom) wall of the vagina.

2-1.8.2. Sweep the fingers from side to side, moving upward, until the cervix is located, which should feel moist and firm. Often, it is angled down, which makes it easy to end up in the anterior fornix. If the cervix cannot be located, start again at the posterior vaginal wall.

1.9.2-2. Use a sweeping motion with your internal fingers to assess the face of the cervix for masses. Note the cervical os and the direction the os is pointing.

1.10.2-3. Check cervical tone by gently squeezing the cervix. A nulliparous patient's cervix should feel firm, like cartilage. It may be softer in a patient who has been pregnant.

1.11.2-4. Gently move the cervix up, down, and from side to side, watching the patient's face for any discomfort, which is a positive sign of cervical motion tenderness (CMT).

1.12.2-5. Move your fingers, so they are underneath the cervix, and gently press upward.

2-5.1.12.1. If the patient's uterus is retroverted, it may feel like it's protruding into the posterior fornix. Use your fingers to assess as much of the uterus as can be reached.

1.13.2-6. Starting at the umbilicus, use the pads of the fingers on your non-dominant hand to press down on the patient's abdomen and scoop forward.

1.13.1.2-6-1. Move your external hand an inch lower and repeat. Continue until the abdominal hand moves the uterus, causing the cervix to move lightly (tap) against your internal fingers. As you get nearer to the uterus, the cervix taps more intensely. The most intense tapping indicates your external hand is directly on the uterus.

1.13.2.2-6-2. Note where the most intense movement starts and stops, which indicates, respectively, the upper and lower boundaries of the uterus.

1.13.2-6-3. Move from one side of the patient's abdomen to the other (in line with the uterus), while applying a rocking pressure, to locate the side boundaries of the uterus.

1.13.2-6-4. Use your external hand to pull the uterus toward you, as your internal fingers gently press up on the cervix, until you are palpating the uterus between your hands. Remember that

Commented [DN5]: Similar to my comment above, this image is missing.

Commented [DN6]: I don't think we need a new section here.

the position of the uterus can range from anteflexed to retroflexed (roughly 10-15% of patients), and this can affect other parts of the exam and the patient's reproductive health. The uterus may also be slightly tilted or off-center (**Figure 4**).

[1.14.2.7](#). Assess the uterus for size, shape, and consistency. The uterus of a nulliparous adult is roughly 7 cm long by 4 cm; if the patient has been pregnant, it may be larger. It should feel muscular, not boggy or hard, and smooth; protrusions may indicate fibroids.

[1.15.2.8](#). To assess the right ovary, slide your fingers, palm up, into the right lateral fornix.

[1.16.2.9](#). Drop your wrist and hook the fingertips up to find the internal iliac pulse. It may be necessary to back your fingers out of the vagina 1-2" to find the pulse.

[2.9.1.16.1](#). Once located, hook your fingers upward to press firmly against the pulse (there is more space here than people tend to believe). Do not push your hand in deeper; keep your wrist and arm relaxed, and only press upward with your fingertips (**Figure 5**).

[1.17.2.10](#). Using the pads of the index and middle fingers of your non-dominant hand, begin 1" medial to the right hip point (ASIS), then sweep your external fingers slowly, with light-medium pressure, down to the pubis, parallel to the inguinal groove.

[1.17.2.10.1](#). The ovary should bump gently against the internal fingers and feel very subtle (may feel like a small oval bulge or a wave of muscle). Do not stop or push directly on the ovary — ovaries are roughly equivalent to testes and are very sensitive.

[1.18.2.11](#). Move your fingers into the left lateral fornix to assess the left ovary.

[23](#). Rectovaginal Exam

[23.1](#). Change gloves to avoid cross-contamination from the patient's vagina to the anus.

[23.2](#). Coat the first two fingers of your dominant hand with lubricant, base to tip.

[23.3](#). Stand with your dominant foot on the stool; rest your dominant elbow on your leg.

[23.4](#). Let the patient know what to expect: "You will now feel me placing a finger in your vagina and a finger in your rectum to better assess your uterus and ovaries."

[23.5](#). Ask the patient to bear down, as if they are having a bowel movement.

[23.5.1](#). As they are bearing down, insert your index finger into the vagina and your middle finger into the rectum to the first knuckle of your middle finger, then pause.

[23.5.2](#). Wait a few seconds as the second internal sphincter involuntarily contracts.

[23.5.3](#). When it relaxes (or after a few seconds, if you cannot feel it clearly), insert the rest of the way as the patient continues to bear down.

[23.6](#). Scissor the fingers to assess the septum, checking that it is firm and pliable.

[23.7](#). Sweep your middle finger side to side against the top wall of the rectum to assess the utero-sacral ligaments (should feel like rubber bands), then press your finger deeper into the rectum while sweeping the walls. Expect to feel stool, but no fixed masses.

[23.8](#). With your middle finger, locate the cervix through the septum and examine what you can reach of the uterus. Repeat the bimanual exam with your middle finger.

[34](#). Conclusion of the Exam

[34.1](#). Remove your fingers, re-drape the patient, and remove your gloves out of the patient's sight (as there may be visible discharge or stool). Throw the gloves into the trash unless the rectovaginal exam was just finished, and they are needed for a stool sample.

[34.2](#). Tell the patient they can push back to sit up, and offer them a wipe.

[34.3](#). If there were no pathological findings, tell the patient that everything appears healthy and normal, that you are going to send the samples to the lab, and when they should expect to hear back.

[34.4](#). Let the patient know you are stepping out, so they can get dressed. Afterward, answer any questions they have.

Summary

This video reviewed the techniques for performing a comfortable bimanual and rectovaginal exam.

When first performing the exam, it can be hard to know what both normal structures and abnormalities should feel like, but familiarity develops with practice. Experienced practitioners can determine the structure and location of the patient's anatomy and discover polyps, cysts, and malignancies; the potential of pelvic inflammatory disease; and more. The rectovaginal exam can be a good way to gather information about a retroverted uterus and ovaries, as well as other information about the patient's health.

People new to the exam should be aware that the inside of the vagina feels moist and fairly yielding, while the cervix is moist and firm. Depending on if a patient has had children or not and where they are in their menstrual cycle, the cervix may feel firmer (like the cartilage of the nose) or softer (like pursed lips). A healthy ovary is soft, subtle, roughly 2 cm by 2 cm, and

shaped like an almond. An ovary that is large, hard, and very easily palpable is a concerning finding. Ovaries shrink after menopause and may not be palpable in post-menopausal patients. They may also be challenging to locate in patients who are obese.

Commented [AS7]: I suggest to keep this part in the manuscript but omit from the video script. For your consideration. A.S.

It is important to be aware that different patients' anatomy may vary greatly. When concluding an exam, the clinician should inform the patient that "everything appears healthy and normal" as long as there were no concerning findings that required follow-up; in this case, "normal" does not mean statistically average, but normal for the patient. It is important that the patient understand the baseline for health in their own body, and that, however their anatomy appears, it is healthy and normal for them.

Figures and Legends

Figure 1: Female reproductive system.

A schematic drawing of the organs of the female reproductive system.

Figure 2: Clearing the labia with the fingers.

A photograph showing the correct positioning of the external hand during the internal examination.

Figure 3: Bimanual exam.

Correct positioning of the examiner for the bimanual exam.

Commented [AS8]: The authors suggest to use an image made during the video shoot for the figures 2, 3, and 5.

Figure 4: Common uterine positions.

Schematic drawing of the common uterine position (sagittal view).

Commented [AS9]: Doesn't need to be reproduced-original image

Figure 5: Hand position to locate the ovary, outside of the body.

A photograph showing the correct hand position for ovary examination.