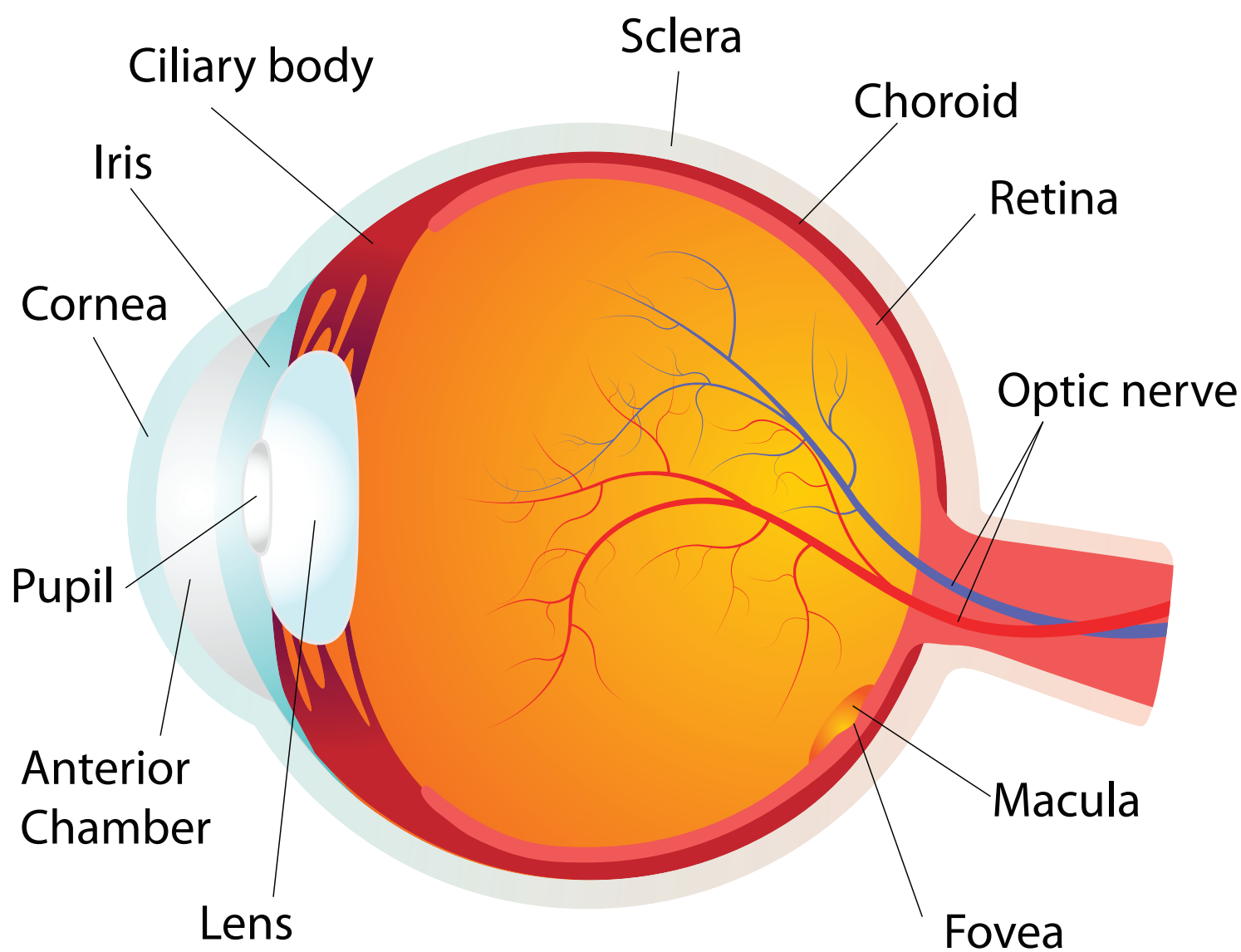
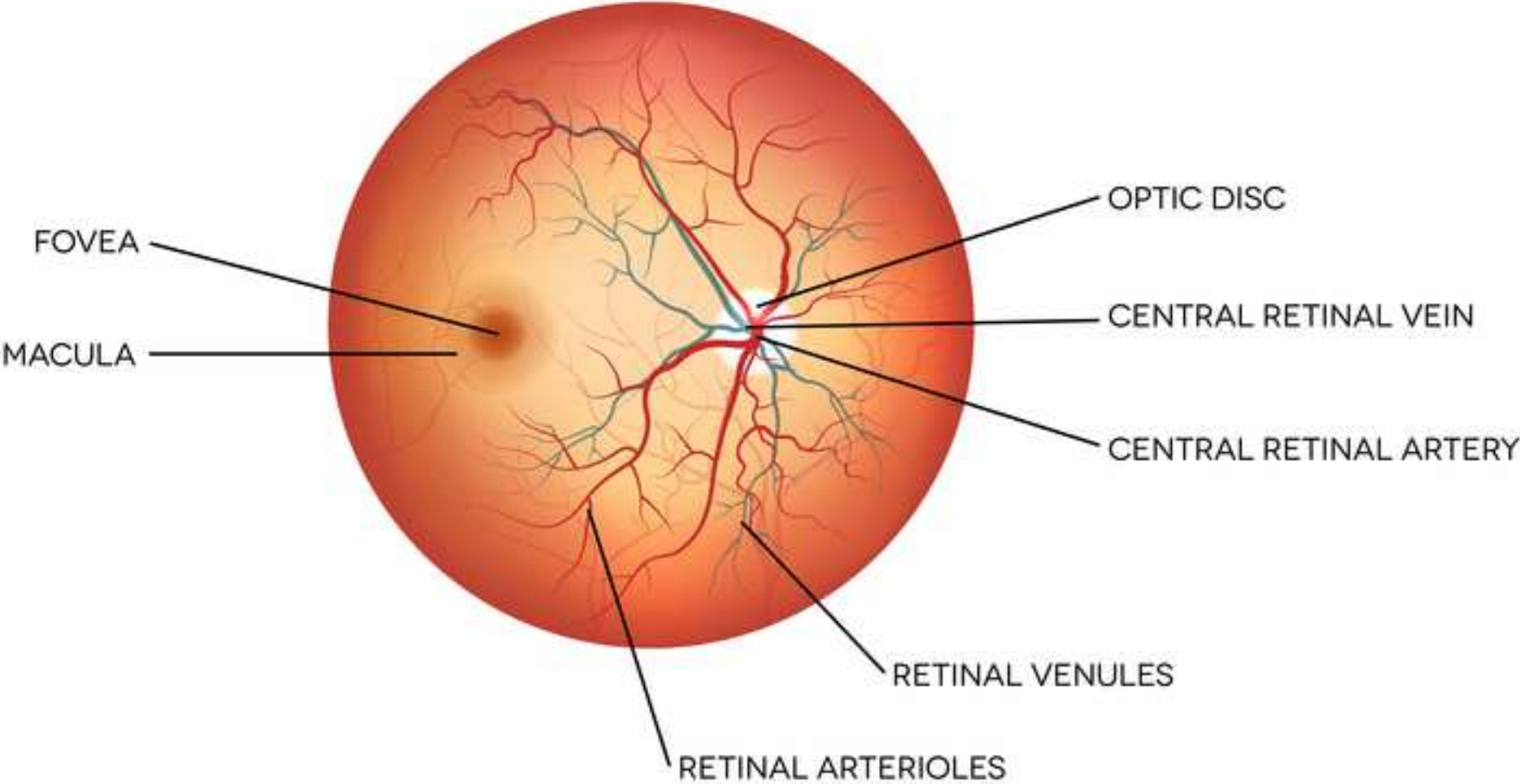


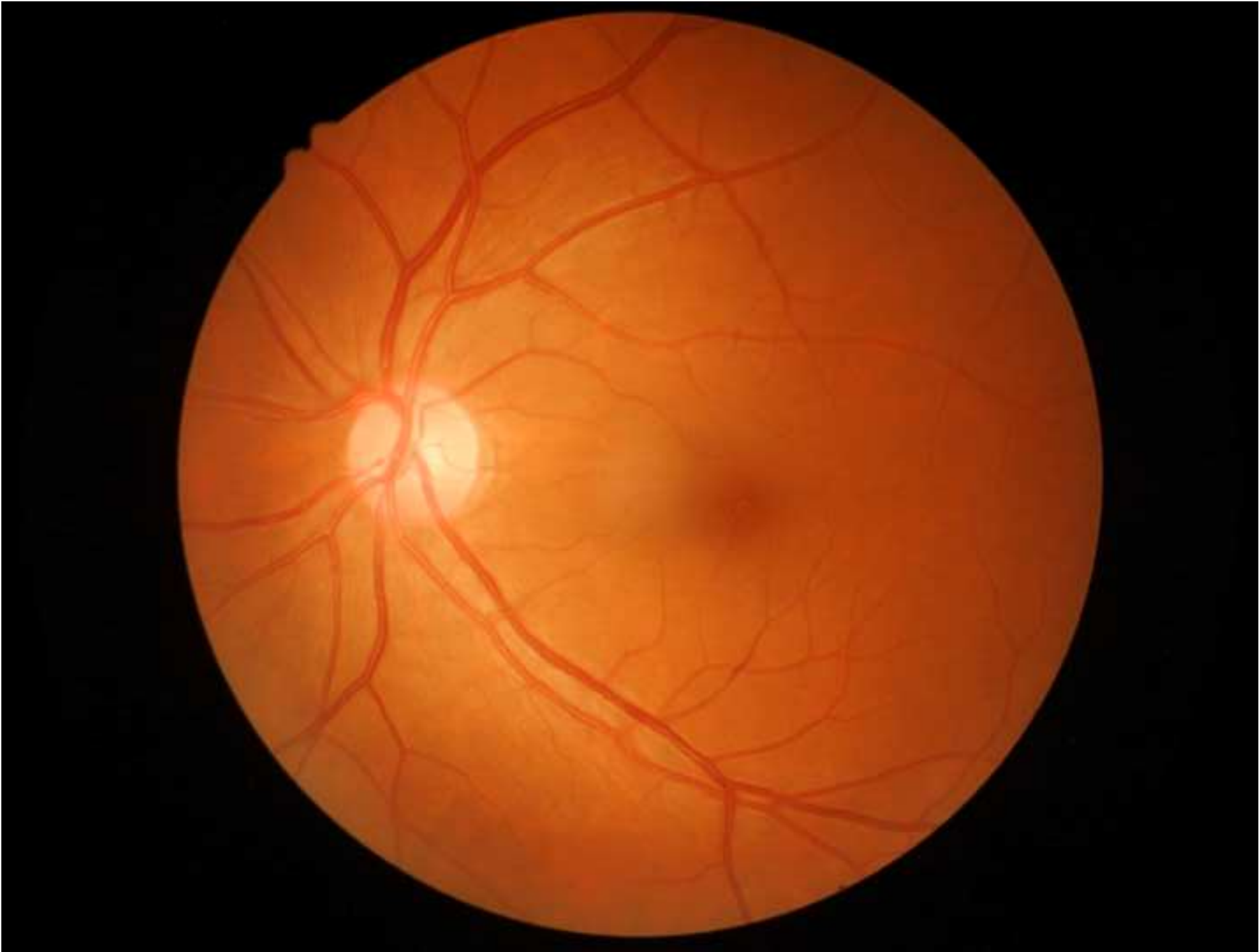
**JoVE: Science Education**  
**Ophthalmoscopic Examination**  
--Manuscript Draft--

<b>Manuscript Number:</b>	10146
<b>Full Title:</b>	Ophthalmoscopic Examination
<b>Article Type:</b>	Manuscript
<b>Section/Category:</b>	Manuscript Submission
<b>Corresponding Author:</b>	Richard Glickman-Simon UNITED STATES
<b>Corresponding Author Secondary Information:</b>	
<b>Corresponding Author's Institution:</b>	
<b>Corresponding Author's Secondary Institution:</b>	
<b>First Author:</b>	Richard Glickman-Simon
<b>First Author Secondary Information:</b>	
<b>Order of Authors:</b>	Richard Glickman-Simon
<b>Order of Authors Secondary Information:</b>	



HUMAN EYE ANATOMY  
**THE RETINA**





**Author Name:** Richard Glickman-Simon, MD  
**Clinical Skills Education Title:** Ophthalmoscopic Examination

**Overview:**

The simplest ophthalmoscopes consist of an aperture to look through, a diopter indicator, and a disc for selecting lenses. The ophthalmoscope is primarily used to examine the fundus, or the inner wall of the posterior eye, which consists of the choroid, retina, fovea, macula, optic disc, and retinal vessels (**Figure 1**). The spherical eyeball collects and focuses light on the neurosensory cells of the retina. Light is refracted as it passes sequentially through the cornea, the lens, and the vitreous body. ~~Images are projected onto the retina upside down and reversed from right to left.~~

The first landmark observed during the funduscopy exam is the optic disc, which is where the optic nerve and retinal vessels enter the back of the eye (**Figure 2**). The disc usually contains a central whitish physiologic cup where the vessels enter; it normally occupies less than half the diameter of the entire disc. Just lateral and slightly inferior is the fovea, a darkened circular area that demarcates the point of central vision. Around this is the macula. A blind spot approximately 15° temporal to the line of gaze results from a lack of retinal cells at the optic disc.

**Procedure:**

Since mydriatic eye drops are not used in general practice, the view of the fundus is limited to only a section of the posterior retina. Be familiar with these features before attempting to examine the patient.

- 1.1 Unless the patient’s refractive errors make it difficult to focus on the retina, it is usually best to remove your own eyeglasses for the exam.
- 1.2 After darkening the room, turn on the ophthalmoscope and shine the light on your hand or on the wall.
- 1.3 Turn the lens disc until the largest white circle of light can be seen, and the diopter indicator reads 0, meaning the ophthalmoscope lens is neither converging nor dispersing the light.
- 1.4 Keep your index finger on the lens disc during the exam, so the diopters can be adjusted as necessary to focus in on the retinal structures.
- 1.5 To examine the patient’s right eye, hold the ophthalmoscope in your right hand and look through the aperture with your right eye; to exam the patient’s left eye, hold the ophthalmoscope in your left hand and look through the aperture with your left eye. This avoids bumping noses with the patient.

**Commented [JS1]:** 1.1.1.1.1.1.This sentence doesn’t seem necessary here and could be removed.

**Commented [AS2]:** 1.1.1.1.1.2.Agreed and deleted.  
AS

- 1.6 Position yourself about a foot from the patient at eye level, and ask them to stare at a spot on the wall just over your shoulder.
- 1.7 As you peer through the aperture, keep both eyes opened, press the ophthalmoscope firmly against your bony orbit, and hold the handle at a slight angle away from the patient's face.
- 1.8 Position the ophthalmoscope about 15° lateral to the patient's line of vision. Direct the light to the pupil and look for an orange-red glow. This is the red reflex. Note any opacities that seem to interfere.
- 1.9 Stay focused on the red reflex and move the ophthalmoscope inward along the 15° line, until you are almost on top of the patient's eye. While doing this, the optic disc and retinal vessels should come into sharp focus. The disc appears as a yellow, orange, or pinkish oval that largely fills the field of view.
- 1.10 If the disc isn't seen right away, identify a blood vessel and follow it toward the disc. It appears to get wider, if going in the right direction. The light may need to be dimmed in order to keep the patient comfortable and to avoid spasmodic constriction of the pupil.
- 1.11 If the disc appears out of focus, try adjusting the diopters by rotating the lens disc one or two settings in the positive or negative direction. The retina only appears perfectly sharp if neither you nor the patient have refractive errors.
- 1.12 Carefully examine the disc for outline clarity, color, relative size of the yellowish-white central cup, and symmetry with the contralateral eye. White or darkly pigmented rings and crescents are often seen around the disc and have no pathologic significance.
- 1.13 Follow the retinal vessels as they extend away from the disc in all four directions. Veins appear redder and wider than arteries.
- 1.14 Look for spontaneous venous pulsations, which appear as subtle variations in the width of the veins with each heartbeat. It's possible to discern subtle pulsations of the veins.
- 1.15 Make special note of arteriovenous crossings. Since the walls of the normal retinal arteries are transparent, only the column of blood is visible within. Veins crossing behind arteries, therefore, are normally seen right up to the column on either side.
- 1.16 Look for any lesions elsewhere in the retina, noting their size.
- 1.17 Examine the fovea and surrounding macula by asking the patient to look directly into the light. The macula often appears to shimmer.
- 1.18 Finally, look for opacities in the lens by adjusting the diopters between 10+ and 12+.

1.19 If the image is lost while searching the retina, it means the light fell out of the pupil as the ophthalmoscope was moved. It takes some practice to keep it inside.

## Summary

The ophthalmologic exam is probably the most challenging for students to master. With time, however, it becomes routine. It is also one of the most productive parts of the physical exam, as it not only offers a window into the condition of the eye, but also provides evidence of disease elsewhere in the body. Elevated intracranial pressure from a variety of causes may lead to swelling of the optic nerve, which appears as papilledema on a funduscopic exam. In papilledema, the optic disc is swollen, its margins are blurred, the central cup is lost, and venous pulsations are absent. Papilledema signals a serious, life-threatening condition. Death of optic nerve fibers, which can occur in optic neuritis, multiple sclerosis, and temporal arteritis, causes the disc to atrophy and lose its smaller blood vessels. Uncontrolled hypertension leads to “copper wiring” of thickened arterial walls in the retina, causing them to appear less transparent. Veins crossing these arteries seem to stop abruptly before reaching either side, a condition called AV nicking. Other signs to look for in hypertensive retinopathy are hard exudates and cotton-wool patches, which result from infarcted nerve fibers. In diabetics, the retina may reveal microaneurysms, hemorrhages, and neovascularization.

Common eye diseases observable on a funduscopic exam include glaucoma and macular degeneration. In glaucoma, increased intraocular pressure may cause the central cup of optic disc to deepen and widen, so it occupies greater than half of the disc diameter. In age-related macular degeneration, patches composed of cellular debris, called drusen, can be seen scattered throughout the retina. In more severe stages, neovascularization is visible. Cataracts can be more thoroughly examined by focusing the ophthalmoscope on opacified lenses.

## Figures and legends.

Figure 1: Anatomy of the eye.

A diagram showing a sagittal view of the human eye with the structures labeled.

Figure 2: Retina landmarks.

A schematic of the human retina and its important landmarks that can be observed on a funduscopic exam. -Optic disc, macula, fovea, and retinal vasculature are labelled.

Figure 3: Normal retina.

A photograph showing an ophthalmoscopic view on the normal left retina.

**Commented [JR3]:** All images downloaded from Shutterstock.

**Commented [JS4]:** 1.1.1.1.1.3. Please expand the captions for Figures 1-3 to include more information than just image titles.