

# JoVE: Science Education

## Comprehensive Breast Exam

--Manuscript Draft--

Manuscript Number:	10118
Full Title:	Comprehensive Breast Exam
Article Type:	Manuscript
Section/Category:	Manuscript Submission
Corresponding Author:	Alexandra Duncan UNITED STATES
Corresponding Author Secondary Information:	
Corresponding Author's Institution:	
Corresponding Author's Secondary Institution:	
First Author:	Alexandra Duncan
First Author Secondary Information:	
Order of Authors:	Alexandra Duncan Tiffany Cook
Order of Authors Secondary Information:	

**Author Names:** Alexandra Duncan and Tiffany Cook

**Clinical Skills Education Title:** Comprehensive Breast Exam

## Overview

Breast exams are a key part of an annual gynecological exam and are important for all patients, no matter their sex or gender expression. 1 in 8 women will be diagnosed with breast cancer; male breast cancer, though less common, has a lifetime incidence of 1 in 1000.

The breast exam can feel invasive to patients, so it is important to do everything possible to make them feel comfortable and empowered, rather than vulnerable. An examiner should be aware of what they are communicating, both verbally and non-verbally, and give their patients control wherever possible (for instance, always allowing them to remove their own gowns). An examiner may choose to utilize a chaperone for the patient's (as well as their own) comfort. Some institutions require the use of a chaperone.

While it is always important to avoid overly clinical language, certain colloquialisms can cross the line from caring to overly intimate in this exam. It is helpful to avoid the words "touch" and "feel" in this exam, as this language can feel sexualized. Instead, use words like "assess," "check," or "examine."

Additionally, best practice dictates avoiding assumptions about patients' gender, as patients with female anatomy may identify as another gender (e.g. transgender, genderqueer, etc.). This video depicts the approach to a patient in whom history has revealed no specific complaints or risk factors related to breast health.

In order to avoid missing potential findings, the breast exam should be performed in a systematic fashion and consist of three main components: visual inspection of the breast tissue, palpation of the lymph nodes, and palpation of the breast tissue.

The breast tissue extends from directly under the clavicle to around the fifth rib (or bra line). Laterally, it extends from the mid-axillary line to the sternal border. The breast is viewed in four quadrants; the upper outer quadrant has the most tissue and is the location of many lymph nodes, and the tail of Spence (or axillary tail) extends to the edge of the axilla, where it attaches to the chest wall (**Figure 1**).

## Procedure

1. Preparation for the exam.

1.1. Before beginning the breast exam, establish an expectation of comfort, and ask the patient to communicate their questions and concerns during the visit. For example, say something like, "Have you had an exam like this before? How was that experience for

you? I expect this to be a comfortable exam. If there is anything I can do to make this more comfortable for you, please let me know and I will make any adjustments I can. You may ask me questions at any time.”

**1.2. Clean your hands.** Some practitioners choose to perform the manual portions of the exam with gloves for the sake of the patient’s (or their own) comfort. If an examiner has any doubts, then it is better to wear gloves, as a patient can pick up on any anxiety, which may make them feel uncomfortable.

## 2. Introduce the exam.

**2.1. Introduce and summarize the three parts of the exam for the patient:** “I’m going to perform a breast exam. First, I will have you do some arm movements so I can check how your breast tissue moves. Then I will check some lymph nodes in your underarm area. Last, I will use the pads of my fingers to assess your breast tissue.”

**2.2. With the patient seated on the exam table, ask them to lower the gown to their waist.**

## 3. Visual exam.

During this exam, visually observe and assess all of the breast tissue, both still and in motion. To establish if something is normal or a recent change (more concerning) for a patient, ask, “Is this normal for you? How long has it been like this?” Document any findings.

**3.1. Visually inspect the breast tissue while the patient remains still. Assess for redness, scaly skin, visible lumps, spontaneous discharge, moles, inverted nipples, and dimpling.** Also assess for potential signs of domestic violence and trauma: bruises, burns, bite marks, scars, etc. Indicate marks and ask, “Can you tell me more about how this happened?”

**3.2. Visually assess the breast tissue in motion. All parts of the breast tissue should move freely, away from the chest wall. Again, no tissue should appear to dimple or retract.**

**3.2.1. Ask the patient to slowly raise their arms above their head, then clasp their hands and push them together, and then slowly lower their arms to their sides.**

**3.2.2. Stand to one side of the patient and offer your arm, palm down, for support. Ask the patient to lean forward, and observe the side of the breast tissue as they do so.**

**3.2.3. When the patient is fully forward, place a hand mirror under their breast, angled to see the skin and tissue on the underside of the breast.**

3.2.4. Ask the patient to sit back, angling the mirror as they move to observe how the lower breast tissue moves.

3.3. If the patient has pendulous breasts and it's difficult to see all the skin underneath, ask them to lift their breasts to assess the skin.

3.4. Ask the patient to place their hands on their hips, then roll their shoulders forward. Observe how the tissue moves; then perform the first step of the lymph node exam.

#### 4. Lymph node exam.

4.1. Assess the supraclavicular lymph nodes while the patient is in the final position from the visual exam. Use your index and middle finger of each hand to hook over the patient's collarbone, and use a circle-slide motion to palpate for the supraclavicular nodes, checking both sides at once (**Figure 2**).

4.2. Assess the axillary lymph nodes (**Figure 2**). Ask the patient to put the gown back on, leaving their right shoulder uncovered for examination, and rest their right forearm on your shoulder.

4.2.1. To assess the central nodes, use the index and middle fingers of your right hand to push up and under the fatty tissue toward the apex of the axilla, and press firmly against the upper thoracic wall (which feels like a large, curved bone). Let the patient know they may feel some pressure.

4.2.2. From there, palpate down the mid-axillary line to the fifth rib. Drag your fingers across the skin between palpations, rather than lifting your hand, to assess the most superficial layer of tissue and ensure no area is skipped.

4.2.3. Ask the patient to make a fist in order to view the line between the biceps and triceps. Ask them to release the fist, and then palpate the brachial chain using two fingers of your right hand.

4.2.4. Place the index, middle, and ring fingers of your left hand behind the pectoralis muscle, and place your right hand on the front of the chest to brace the tissue and assess the pectoral lymph nodes. Apply anterior pressure with your left hand while moving it up and down in a windshield-wiper motion to assess the tissue and nodes.

4.2.5. Place the index, middle, and ring fingers of your right hand in front of the teres major muscle, and place your left hand on the patient's back to brace the tissue and assess the subscapular lymph nodes. Apply posterior pressure with your right hand while moving it up and down in a windshield-wiper motion to assess the tissue and nodes.



4.2.6. Repeat on the patient's left side. Use the opposite hand for each previous step.

## 5. Clinical breast exam.

There are a few well-accepted methods for the breast exam. All of these methods use a systematic approach to ensure all breast tissue is examined: concentric circle or spiral, vertical strip or linear, and radial spoke or wedge. The vertical strip exam (demonstrated in this video) has the most data to support it. Regardless of the method used, the palpation technique is the same.

5.1. Ask the patient to recline on the examination table in the supine position. Pull out the foot shelf.

5.2. Ask the patient to roll away from you and onto their side. Place a pillow behind half of their back before they lie flat again. Ask the patient to lower their gown on the side closest to you, and raise their arm over their head.

5.3. Begin the exam at the top of the mid-axillary line. Using the pads of three fingers in a circle-slide motion, palpate in circles roughly the size of a quarter to assess for masses.

5.3.1. While palpating, spiral down through three levels of pressure: superficial, medium, and deep (reaching the chest wall). Healthy breast tissue may feel lumpy, including fatty tissue, lobules, fibrocystic changes, the inframammary ridge, and lymph nodes. Healthy structures have clearly defined boundaries and move freely under your fingers; they won't feel stuck to the tissue around them, nor matted together (**Figure 3**).

5.3.2. Continue to palpate in a straight line to the bottom of the breast (around the fifth rib). Move an inch over and palpate in a straight line up to the clavicle.

5.3.3. Continue to examine the breast in the vertical strip pattern until finishing at the nipple line (**Figure 4**). Tell the patient, "You'll feel me pass over your nipple."

5.3.4. Ask the patient to roll away from you, then remove the pillow. Place the pillow behind the patient's head, and ask the patient roll back.

5.3.5. Starting at the clavicle, continue the exam by re-assessing the nipple line, continuing the vertical strip pattern until reaching the sternal border.

5.3.6. Ask the patient to lower their arm to their side.

5.4. Assess the infraclavicular nodes and tail of Spence.

5.4.1. From the mid-clavicle, palpate directly below the clavicle to the edge of the shoulder.

5.4.2. Palpate back a quarter of the way across the chest in a zigzag pattern, then to the distal border of the upper outer quadrant to finish checking the superior tail of Spence.

5.4.3. Assess the inferior tail of Spence by placing three fingers under the pectoral muscle, so the tissue is resting on the pads of your fingers, and moving in a sideways windshield-wiper motion, as previously done to assess the axillary lymph nodes.

5.5. Repeat steps 5.1 through 5.4 for the other breast.

6. Optional: Information about the breast self-exam (BSE).

Data are lacking to support routine BSE, and it is not known to affect breast cancer outcomes. While the United States Preventative Services Task Force does not recommend it, the American Cancer Society and the American College of Obstetrics and Gynecology recommend breast self-awareness for all patients.

6.1. While assessing the breast tissue, educate the patient about breast self-awareness and encourage them to check their own natural structures, which have just been assessed as normal. Let the patient know they can do a monthly self-exam, like the clinical exam just performed, on the last day of their period, when there is least tenderness and fewest fibrocystic changes. Post-menopausal women can perform a self-exam on the same date every month.

7. Conclude the exam.

7.1. Ask the patient to sit up and put the gown back on. Exit the room and allow the patient to dress. Return to discuss the findings and next steps.

## Summary

This video covers how to perform the clinical breast exam and how to visually inspect and examine breast tissue and associated lymph nodes.

Before the exam, establish the expectation that the patient can communicate their questions and concerns during the visit. Only ask the patient to remove their gown when necessary, and remind them when they can raise their gown during the exam. This minimizes feelings of vulnerability.

Begin with an overview of the exam and explain every step as you reach it. Start with the visual inspection of the breast tissue, both still and in motion. Make note of any potential signs of domestic or intimate partner violence. Remember that some patients engage in rough sex and bruising may not be indicative of violence.

While proceeding through the exam, document any findings. There is a wide range of healthy anatomy, and what is normal for one patient may be abnormal for another. For

example, inverted nipples are perfectly normal for some patients; however, an inverted nipple may be concerning if it is only on one side or is a recent change.

Move on to the axillary lymph node exam, then assess the breast tissue in a systematic matter.

Include the patient in the exam wherever possible, and educate the patient so they are not alarmed by natural structures. If something concerning is found in one breast, make a note of the location and check the other breast to see if there are similar structures.

Beyond asking clarifying questions, do not discuss concerns or follow-up testing while the exam is ongoing. Wait until the patient is dressed, then reenter the room to discuss concerns and next steps, as having those conversations while the patient is unclothed and vulnerable heightens anxiety.

When an exam with no negative findings is finished, always tell the patient that “everything appears healthy and normal.” This simple statement empowers the patient to equate their body structures as normal.

## Figures and legends

Figure 1: Breast landmarks and quadrants.

Human breast with the quadrants and surface landmarks labelled.

**Comment [AS1]:** The attached figure is a drawing to be reproduced, however it is probably possible to apply graphics to the photograph

Figure 2: Supraclavicular and axillary lymph nodes.

Anatomic location of the lymph nodes evaluated during the breast examination.

**Comment [JR2]:** Can this figure be reproduced, as well?

Figure 3: Normal breast tissue and common breast pathologies.

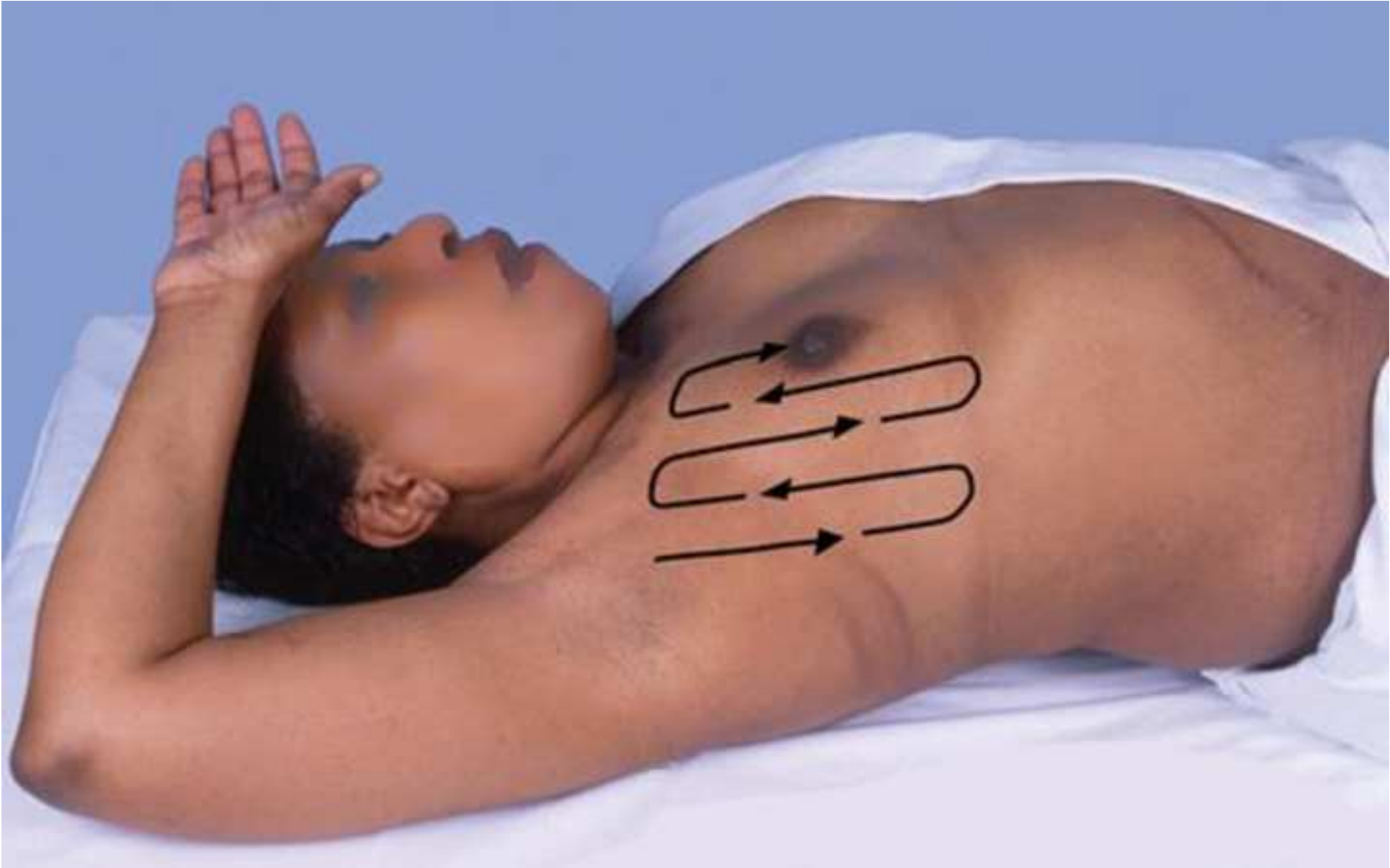Note the diffuse boundaries of a malignant lump.

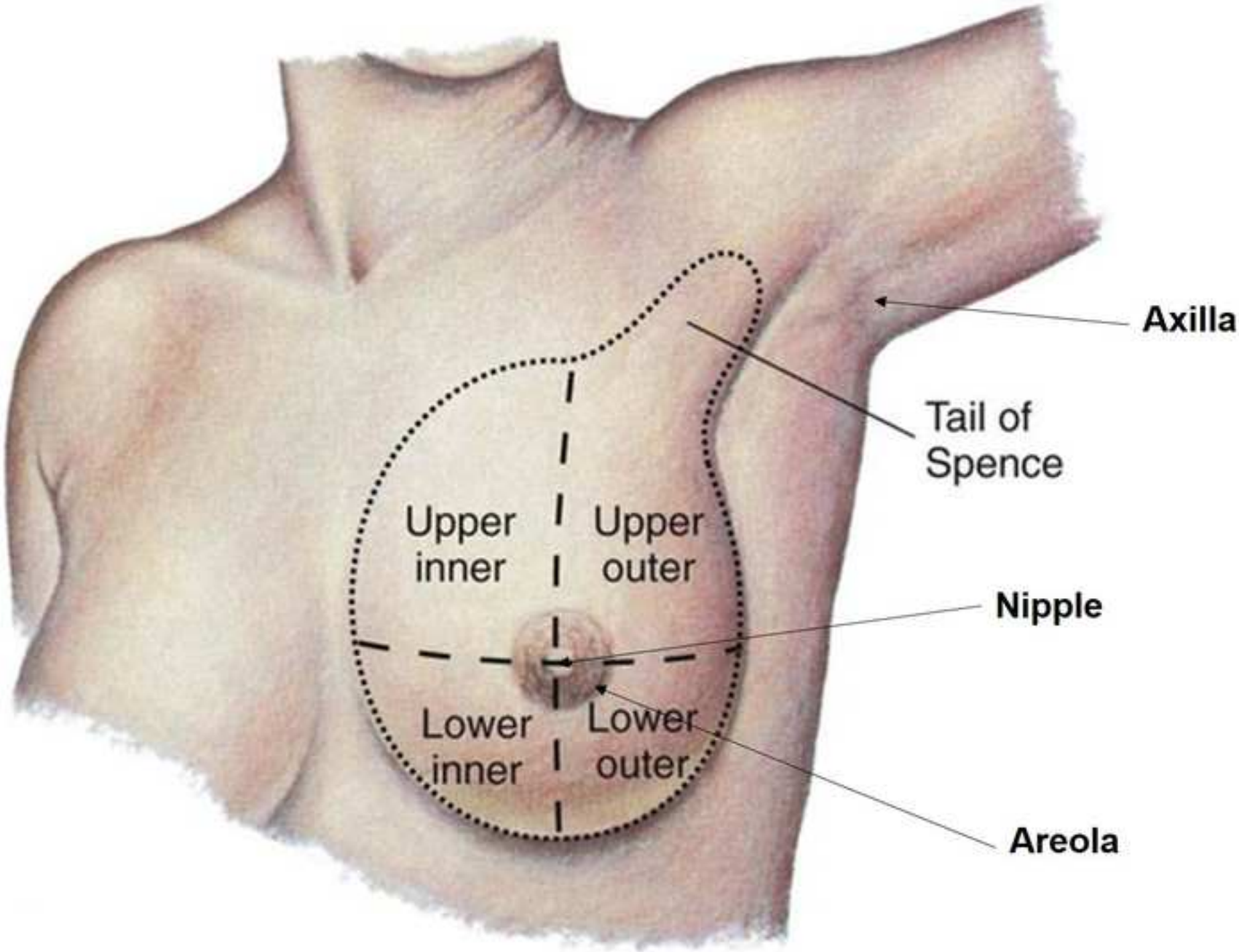
**Comment [JR3]:** Image downloaded from Shutterstock.

Figure 4: Linear strip breast exam pattern.

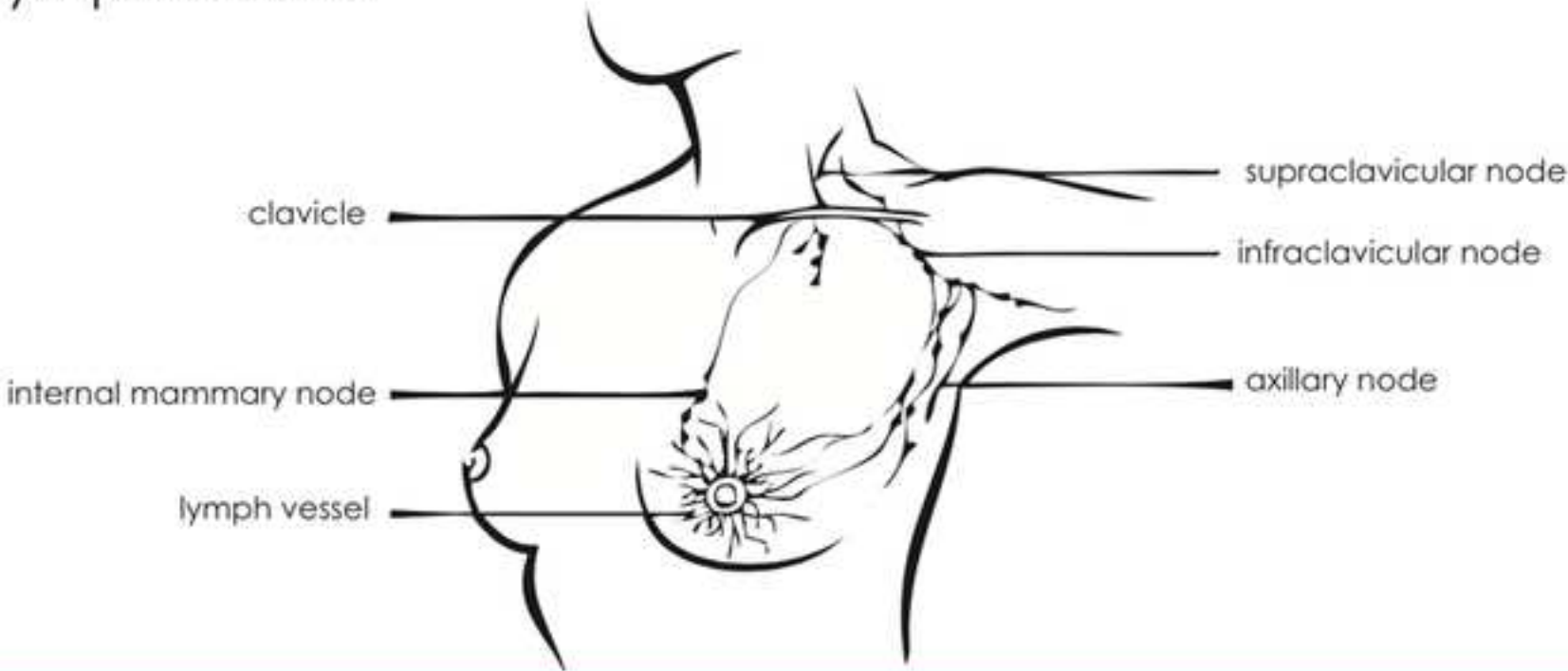
Direction of palpation of breast using linear strip approach (shown by arrows).

**Comment [AS4]:** The authors suggest to consider an animation similar to this one: [http://www.google.com/imgres?imgurl=http://www.wdv.com/Cancer/Breast/images/BSE.gif&imgrefurl=http://www.wdv.com/Cancer/Breast/CBE/&h=241&w=360&tbnid=mHvqMZlPEhr5XM:&zoo:m=1&docid=2HU6HnRAhF8TdM&ei=1e8GVdnbE-zisATvqICoAQ&tbn=isch&ved=0CG4QMyhHM\\_Ec](http://www.google.com/imgres?imgurl=http://www.wdv.com/Cancer/Breast/images/BSE.gif&imgrefurl=http://www.wdv.com/Cancer/Breast/CBE/&h=241&w=360&tbnid=mHvqMZlPEhr5XM:&zoo:m=1&docid=2HU6HnRAhF8TdM&ei=1e8GVdnbE-zisATvqICoAQ&tbn=isch&ved=0CG4QMyhHM_Ec)

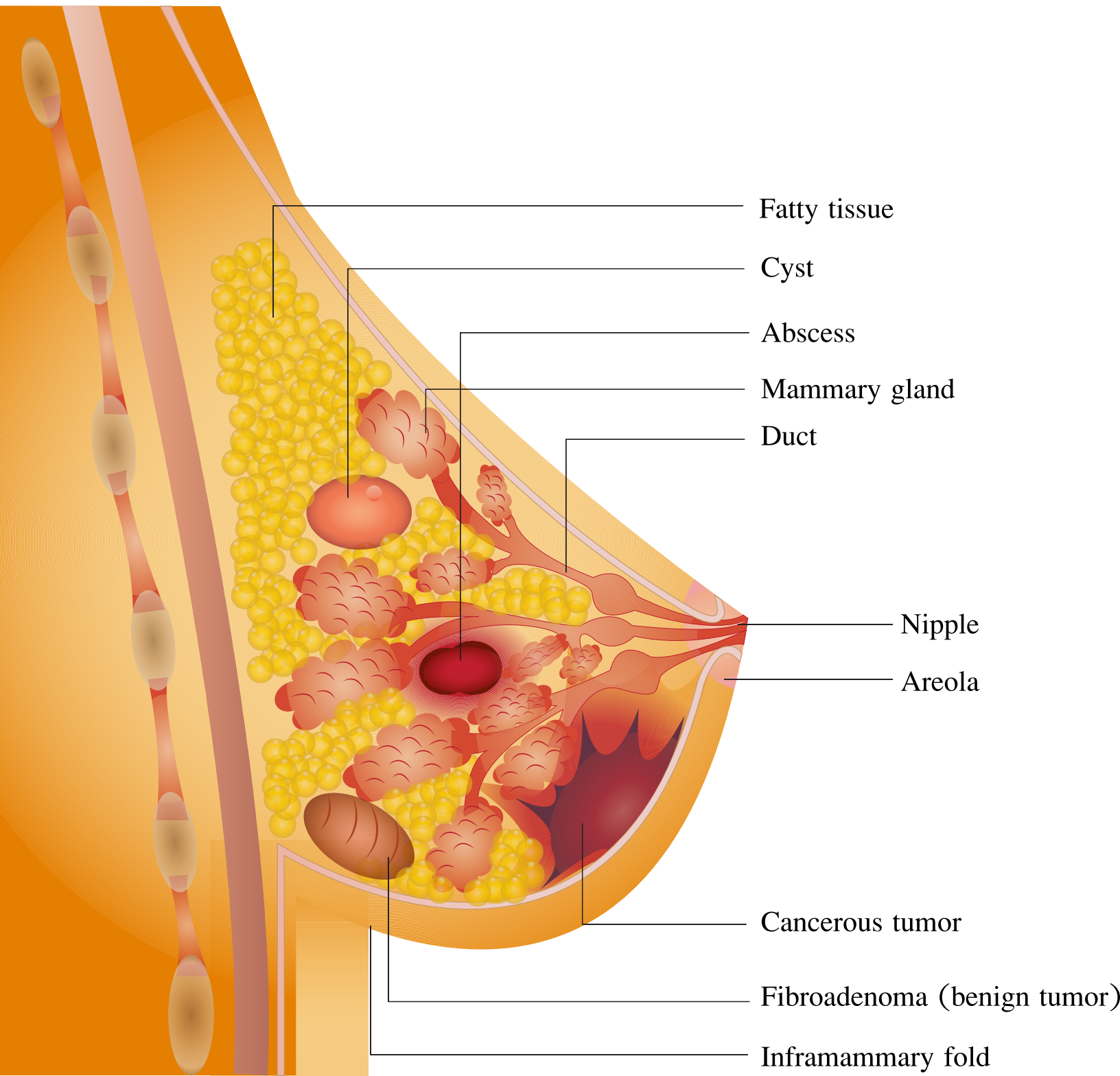




# Lymph Nodes







**Author Names:** Alexandra Duncan and Tiffany Cook

**Clinical Skills Education Title:** Comprehensive Breast Exam

## Overview

Breast exams are a key part of an annual gynecological exam and are important for all patients, no matter their sex or gender expression. 1 in 8 women will be diagnosed with breast cancer; male breast cancer, though less common, has a lifetime incidence of 1 in 1000.

The breast exam can feel invasive to patients, so it is important to do everything possible to make the patients feel comfortable and empowered, rather than vulnerable. An examiner should be aware of what they are communicating, both verbally and non-verbally, and give their patients control wherever possible (for instance, always allowing them to remove their own gowns). An examiner may choose to utilize a chaperone for the patient's (as well as their own) comfort. Some institutions require the use of a chaperone.

While it is always important to avoid overly clinical language, certain colloquial words can cross the line from caring to overly intimate in this exam. It is helpful to avoid the words "touch" and "feel" in this exam, as this language can feel sexualized. Instead, use words like "assess," "check," or "examine."

Additionally, the best practice dictates avoiding assumptions about patients' gender, as patients with female anatomy may identify as another gender (e.g., transgender, genderqueer, etc.). This video depicts the approach to a patient in whom history has revealed no specific complaints or risk factors related to breast health.

In order to avoid missing potential findings, the breast exam should be performed in a systematic approach and consist of three main components: visual inspection of the breast tissue, palpation of the lymph nodes, and palpation of breast tissue.

The breast tissue extends from directly under the clavicle to around the fifth rib (or bra line). Laterally, it extends from the mid-axillary line to the sternal border. The breast is viewed in four quadrants; the upper outer quadrant has the most tissue and is the location of many lymph nodes, and the tail of Spence (or axillary tail) extends to the edge of the axilla, where it attaches to the chest wall (**Figure 1**).

## Procedure

1. Preparation for the exam.

1.1. Before beginning the breast exam, establish an expectation of comfort, and ask the patient to communicate their questions and concerns during the visit. For example, say

**Comment [AS1]:** We removed the highlights as requested. AS

**Comment [AS2]:** Perhaps this sentence can be part of the script?

**Comment [AS3]:** If you feel the intro is too lengthy perhaps this last clause can be included only in the accompanying manuscript

**Comment [AS4]:** We hope that the highlighted parts fits within formatting limits – when non-highlighted parts are deleted, it is exactly 3 pages long. Perhaps you can include it all, as it is all very well written and meets the highest standards. AS



something like, "Have you had an exam like this before? How was that experience for you? I expect this to be a comfortable exam. If there is anything I can do to make this more comfortable for you, please let me know and I will make any adjustments I can. You may ask me questions at any time."

**1.2. Clean your hands.** Some practitioners choose to perform the manual portions of the exam with gloves for the sake of the patient's (or their own) comfort. If an examiner has any doubts, then it is better to wear gloves, as a patient can pick up on any anxiety, which may make them feel uncomfortable.

## 2. Introduce the exam.

**2.1. Introduce and summarize the three parts of the exam for the patient:** "I'm going to perform a breast exam. First, I will have you do some arm movements so I can check how your breast tissue moves. Then I will check some lymph nodes in your underarm area. Last, I will use the pads of my fingers to assess your breast tissue."

**2.2. With the patient seated on the exam table, ask them to lower the gown to their waist.**

## 3. Visual exam.

During this exam, visually observe and assess all of the breast tissue, both still and in motion. To establish if something is normal or a recent change (more concerning) for a patient, ask, "Is this normal for you? How long has it been like this?" Document any findings.

**3.1. Visually inspect the breast tissue while the patient remains still. Assess for redness, scaly skin, visible lumps, spontaneous discharge, moles, inverted nipples, and dimpling. Also assess for potential signs of domestic violence and trauma: bruises, burns, bite marks, scars, etc. Indicate marks and ask, "Can you tell me more about how this happened?"**

**3.2. Visually assess the breast tissue in motion. All parts of the breast tissue should move freely, away from the chest wall. Again, no tissue should appear to dimple or retract.**

**3.2.1. Ask the patient to slowly raise their arms above their head, then clasp their hands and push them together, and then slowly lower their arms to their sides.**

**3.2.2. Stand to one side of the patient and offer your arm, palm down, for support. Ask the patient to lean forward, and observe the side of the breast tissue as they do so.**

**3.2.3. When the patient is fully forward, place a hand mirror under their breast, angled to see the skin and tissue on the underside of the breast.**

3.2.4. Ask the patient to sit back, angling the mirror as they move to observe how the lower breast tissue moves.

3.3. If the patient has pendulous breasts and it's difficult to see all the skin underneath, ask them to lift their breasts to assess the skin.

3.4. Ask the patient to place their hands on their hips, then roll their shoulders forward. Observe how the tissue moves; then perform the first step of the lymph node exam.

#### 4. Lymph node exam.

4.1. Assess the supraclavicular lymph nodes while the patient is in the final position from the visual exam. Use your index and middle finger of each hand to hook over the patient's collarbone, and use a circle-slide motion to palpate for the supraclavicular nodes, checking both sides at once (**Figure 2**).

4.2. Assess the axillary lymph nodes (**Figure 2**). Ask the patient to put the gown back on, leaving their right shoulder uncovered for examination, and rest their right forearm on your shoulder.

4.2.1. To assess the central nodes, use the index and middle fingers of your right hand to push up and under the fatty tissue toward the apex of the axilla, and press firmly against the upper thoracic wall (which feels like a large, curved bone). Let the patient know they may feel some pressure.

4.2.2. From there, palpate down the mid-axillary line to the fifth rib. Drag your fingers across the skin between palpations, rather than lifting your hand, to assess the most superficial layer of tissue and ensure no area is skipped.

4.2.3. Ask the patient to make a fist in order to view the line between the biceps and triceps. Ask them to release the fist, and then palpate the brachial chain using two fingers of your right hand.

4.2.4. Place the index, middle, and ring fingers of your left hand behind the pectoralis muscle, and place your right hand on the front of the chest to brace the tissue and assess the pectoral lymph nodes. Apply anterior pressure with your left hand while moving it up and down in a windshield-wiper motion to assess the tissue and nodes.

4.2.5. Place the index, middle, and ring fingers of your right hand in front of the teres major muscle, and place your left hand on the patient's back to brace the tissue and assess the subscapular lymph nodes. Apply posterior pressure with your right hand while moving it up and down in a windshield-wiper motion to assess the tissue and nodes.

**Comment [AS5]:** Breast exam includes evaluation of regional lymph nodes as those are known sites to which breast cancer is spread, therefore it is always described and shown as a part of breast evaluation (this is good clinical practice).  
We hope we can keep this part as it is written – it is described incredibly well. AS

4.2.6. Repeat on the patient's left side. Use the opposite hand for each previous step.

## 5. Clinical breast exam.

There are a few well-accepted methods for the breast exam. All of these methods use a systematic approach to ensure all breast tissue is examined: concentric circle or spiral, vertical strip or linear, and radial spoke or wedge. The vertical strip exam (demonstrated in this video) has the most data to support it. Regardless of the method used, the palpation technique is the same.

**Comment [AS6]:** I think this is a good paragraph, so please include it, if you think it can fit within the formatting limits.

5.1. Ask the patient to recline on the examination table in the supine position. Pull out the foot shelf.

5.2. Ask the patient to roll away from you and onto their side. Place a pillow behind half of their back before they lie flat again. Ask the patient to lower their gown on the side closest to you, and raise their arm over their head.

5.3. Begin the exam at the top of the mid-axillary line. Using the pads of three fingers in a circle-slide motion, palpate in circles roughly the size of a quarter to assess for masses.

5.3.1. While palpating, spiral down through three levels of pressure: superficial, medium, and deep (reaching the chest wall). Healthy breast tissue may feel lumpy, including fatty tissue, lobules, fibrocystic changes, the inframammary ridge, and lymph nodes. Healthy structures have clearly defined boundaries and move freely under your fingers; they won't feel stuck to the tissue around them, nor matted together (**Figure 3**).

5.3.2. Continue to palpate in a straight line to the bottom of the breast (around the fifth rib). Move an inch over and palpate in a straight line up to the clavicle.

5.3.3. Continue to examine the breast in the vertical strip pattern until finishing at the nipple line (**Figure 4**). Tell the patient, "You'll feel me pass over your nipple."

5.3.4. Ask the patient to roll away from you, then remove the pillow. Place the pillow behind the patient's head, and ask the patient to roll back.

5.3.5. Starting at the clavicle, continue the exam by re-assessing the nipple line, continuing the vertical strip pattern until reaching the sternal border.

5.3.6. Ask the patient to lower their arm to their side.

5.4. Assess the infraclavicular nodes and tail of Spence.

5.4.1. From the mid-clavicle, palpate directly below the clavicle to the edge of the shoulder.

5.4.2. Palpate back a quarter of the way across the chest in a zigzag pattern, then to the distal border of the upper outer quadrant to finish checking the superior tail of Spence.

5.4.3. Assess the inferior tail of Spence by placing three fingers under the pectoral muscle, so the tissue is resting on the pads of your fingers, and moving in a sideways windshield-wiper motion, as previously done to assess the axillary lymph nodes.

5.5. Repeat steps 5.1 through 5.4 for the other breast.

## 6. Optional: Information about the breast self-exam (BSE).

Data are lacking to support routine BSE, and it is not known to affect breast cancer outcomes. While the United States Preventative Services Task Force does not recommend it, the American Cancer Society and the American College of Obstetrics and Gynecology recommend breast self-awareness for all patients.

6.1. While assessing the breast tissue, educate the patient about breast self-awareness and encourage them to check their own natural structures, which have just been assessed as normal. Let the patient know they can do a monthly self-exam, like the clinical exam just performed, on the last day of their period, when there is least tenderness and fewest fibrocystic changes. Post-menopausal women can perform a self-exam on the same date every month.

## 7. Conclude the exam.

7.1. Ask the patient to sit up and put the gown back on. Exit the room and allow the patient to dress. Return to discuss the findings and next steps.

## Summary

This video covers how to perform the clinical breast exam and how to visually inspect and examine breast tissue and associated lymph nodes.

Before the breast exam is started~~exam,~~, the examiner should establish the expectation that the patient can communicate their questions and concerns during the visit. ~~Only ask the~~ The patient should be asked ~~patient~~ to remove their gown only when necessary, and remind ed -when they can raise their gown during the exam. This minimizes feelings of vulnerability.

The clinician ~~B~~egins~~should begin~~ with an overview of the exam ~~that and and~~ -explain s every step of the examination as ~~they reach it. They S~~~~start~~The examination starts -with the visual inspection of the breast tissue, both still and in motion. Any Then, any

**Comment [AS7]:** I think this part can be in the accompanying manuscript only. AS

**Comment [AS8]:** We changed the sentences written in imperative tense. AS

~~notes~~Make note of any potential signs of domestic or intimate partner violence are made. ~~should be noted. It should be remembered~~ that some patients engage in rough sex, so ~~and so~~ bruising may not be indicative of violence.

While proceeding through the exam, any findings must be documented. ~~any findings.~~ There is a wide range of healthy anatomy, and what is normal for one patient may be abnormal for another. For example, inverted nipples are perfectly normal for some patients; however, an inverted nipple may be concerning if it is only on one side or is a recent change.

The next step is the ~~Move on to the~~ axillary lymph node exam, which is followed by systematic assessment of the breast tissue. ~~then assesses the breast tissue in a systematic matter.~~

The clinician should ~~include~~ the patient in the exam wherever possible and educate the patient so they are not alarmed by natural structures. If something concerning is found in one breast, ~~make~~ a note of the location should be made and the other ~~breast~~ assessed to see if there are similar structures.

Beyond asking clarifying questions, the examiner should ~~do~~ not discuss concerns or follow-up testing while the exam is ongoing. It is advised to ~~Wait~~ until the patient is dressed, then reenter the room to discuss concerns and next steps, as having those conversations while the patient is unclothed and vulnerable heightens anxiety.

When an exam with no negative findings is finished, the clinician should always tell the patient that “everything appears healthy and normal.” This simple statement empowers the patient to equate their body structures as normal.

## Figures and legends

Figure 1: Breast landmarks and quadrants.

Human breast with the quadrants and surface landmarks labelled.

**Comment [AS9]:** The attached figure is a drawing to be reproduced, however it is probably possible to apply graphics to the photograph

Figure 2: Supraclavicular and axillary lymph nodes.

Anatomic location of the lymph nodes evaluated during the breast examination.

**Comment [JR10]:** Can this figure be reproduced, as well?

Figure 3: Normal breast tissue and common breast pathologies.

Note the diffuse boundaries of a malignant lump.

**Comment [JR11]:** Image downloaded from Shutterstock.

Figure 4: Linear strip breast exam pattern.

Direction of palpation of breast using linear strip approach (shown by arrows).

**Comment [AS12]:** The authors suggest to consider an animation similar to this one: <http://www.google.com/imgres?imgurl=http://www.wdv.com/Cancer/Breast/images/BSE.gif&imgrefurl=http://www.wdv.com/Cancer/Breast/CBE/&h=241&w=360&tbnid=mHvgMZlPEhr5XM:&zoom=1&docid=2HU6HnRAhF8TdM&ei=1e8GVdnbE-zisATvqICoAQ&tbn=isch&ved=0CG4QMyhHMEc>