

# JoVE: Science Education

## Vital Signs

--Manuscript Draft--

Manuscript Number:	10107
Full Title:	Vital Signs
Article Type:	Manuscript
Section/Category:	Manuscript Submission
Corresponding Author:	Megan Fashjian UNITED STATES
Corresponding Author Secondary Information:	
Corresponding Author's Institution:	
Corresponding Author's Secondary Institution:	
First Author:	Megan Fashjian
First Author Secondary Information:	
Order of Authors:	Megan Fashjian
Order of Authors Secondary Information:	

**Author Name:** Meghan Fashjian, ACNP-BC

**Clinical Skills Education Title:** Vital Signs

## Overview

The vital signs are objective measurements of a patient's clinical status. There are five commonly accepted vital signs: blood pressure, heart rate, temperature, respiratory rate, and oxygen saturation. In many practices, pain is considered the sixth vital sign and should regularly be documented in the same location as the vital signs. However, the pain scale is a subjective measurement and, therefore, has a different value according to each individual patient.

The accepted ranges for vital signs are: heart rate (HR), 60-100 beats per minute (bpm); respiratory rate (RR), 14-20 bpm; oxygen saturation, (SaO<sub>2</sub>) > 92%; and average oral temperature, 98.6 °F (37 °C) (normal average rectal and tympanic temperatures are 1° higher (measuring core temp), and axillary temperature is 1° lower).

Vital signs serve as the first clue that something may be amiss with a patient, especially if the patient is unable to communicate. Although there are quoted normal ranges, each patient should be considered as an individual and not treated without taking into account the entire clinical picture.

## Procedure

Make sure the patient has been seated and resting for at least 5 min prior to obtaining vital signs (VS) to accurately determine the baseline. The vital signs assessment includes estimation of heart rate, blood pressure (demonstrated in a separate video), respiratory rate, temperature, oxygen saturation, and the presence and severity of pain.

### 1. Heart rate.

The radial artery is the most common site used to assess the pulse.

#### 1.1. Explain to the patient that you are going to start by checking their pulse.

1.2. Place your index and middle fingers on the radial pulse (never use the thumb, as you can sometimes feel your own pulse). To prevent occlusion, do not press or apply pressure to the artery.

#### 1.3. Assess the rhythm.

1.3.1. If the rhythm is regular, count the beats for 15 sec, then multiply by 4.

1.3.2. If the rhythm is irregular, count the beats for a full 60 sec. A regularly irregular pulse may signal premature beats, whereas an irregularly irregular rhythm may signal atrial fibrillation. Confirm any abnormalities with an electrocardiogram (ECG).

1.4. Note the amplitude of the pulse (normal, bounding, diminished, or absent). Bounding pulses may be observed at rest with atherosclerosis, congestive heart failure (CHF), kidney disease, aortic insufficiency, or fever. Diminished pulses may be noted with peripheral vascular disease (PVD) or sepsis. If absent, it may be due to occlusion of the artery and should be further investigated.

1.5. If unable to palpate a pulse in the radial area, move to a different site as listed in **Figure 1** or obtain a Doppler machine for assistance. A Doppler machine is a handheld device with an ultrasound transducer that is used to amplify a pulse and produce an audible heart rate.

1.6. Record HR, making a note of rhythm and amplitude on the VS flow sheet.

## 2. Respiratory rate.

Attempt to calculate the respiratory rate without the patient becoming aware. This can be done either by leaving the fingers on the patient's radial pulse or by counting during the cardiovascular portion of the physical exam when they are breathing normally.

2.1. Count the respiratory rate for a full 60 sec. One respiratory cycle includes both one inspiration and one expiration. Note if slow breathing (bradypnea) or rapid shallow breathing (tachypnea) is present.

2.2. Assess the regularity of breathing. Note if an irregularly irregular (ataxic or Biot's) or regularly irregular (Cheyne-Stokes, characterized by long periods of apnea (no breathing)) pattern is present.

2.3. Note the depth of breathing. Is the patient engaged in shallow or very deep breathing? For example, rapid shallow breathing can be labeled as tachypnea, whereas deep rapid breathing may be Kussmaul breathing, which is associated with diabetic ketoacidosis.

2.4. Note the work of breathing. Is the patient utilizing accessory muscles with respiration? These include the trapezius, scalene, sternomastoid, and external intercostal muscles. This often indicates if there is an issue with oxygen delivery or air trapping.

2.5. Record the rate and rhythm on the VS flow sheet. Also include depth and work of breathing, if abnormal.

## 3. Temperature.

An examiner can obtain oral, rectal, axillary, or tympanic membrane temperatures. Be familiar with the differences in the expected normal values. In the office setting, the most common method of checking the temperature is oral. If the patient is non-responsive or unable to cooperate, oral is not the preferred method, and the examiner should use an alternate technique.

3.1. Explain to the patient that you are going to check their temperature.

3.2. Place a disposable plastic sheath on the thermometer.

3.3. If using a digital thermometer, insert under the patient's tongue and hold there until the thermometer alerts you that the temperature has been calculated.

3.4. If using a glass thermometer, make sure it reads less than 96 °F and insert under the patient's tongue. Hold there for 3 min.

3.5. Record the temperature and location obtained on the vital sign flow sheet.

#### 4. Oxygen saturation.

The oxygen saturation (SaO<sub>2</sub>) can be measured by a non-invasive method called pulse oximetry. The oximeter is a small, usually portable, device that consists of a monitor and a probe, which is placed on the patient's finger, toe, or earlobe. The probe allows two wavelengths of light to pass through the body to a photodetector. The changes in absorbance indicate the percentage of saturated hemoglobin in the arterial blood. Most oximeters display the patient's pulse rate, too. Be advised: if a patient's fingertip is cold or if the patient is wearing nail polish, this may interfere with the reading. There are also conditions that falsely elevate the readings including carbon monoxide (CO) poisoning.

4.1. Explain to the patient that you are going to check their oxygen saturation.

4.2. Place the oximeter probe onto the patient's finger. Finger probes are often a single rubber piece that can be hinged and slipped onto the fingertip. There are alternative probes that can be placed on other body parts, if unable to obtain a read from the finger.

4.3. Record the oximeter reading on the vital sign flow sheet.

#### 5. Pain.

This is considered the sixth vital sign, but is subjective and difficult to measure. Most institutions abide by the policy that pain is what the patient says it is. However, there is no objective way to measure from patient to patient. Most often, a numeric scale (1-10, 10 being the worst pain imaginable) is utilized in patients unable to understand or communicate appropriately. In non-verbal patients, children, or those who do not speak English, severity of pain is assessed by using the visual Wong-Baker FACES scale. Always remember to reassess pain after any intervention taken.

5.1. Ask the patient if they are having pain.

5.1.1. If the patient expresses comprehension and does have pain, ask them to quantify it on a scale of 1-10.

**Comment [JR1]:** Awaiting response on license agreement.

**Comment [DM2]:** If permission for that is cost-prohibitive we can just reference the scale and not show it.

5.1.2. If the patient is unable to comprehend, but appears to have pain, show them the FACES scale to determine the severity of pain.

5.2. Record on the vital sign flow sheet.

### Summary

The vital signs – blood pressure, heart rate, respiratory rate, temperature, oxygen saturation, and “the 6th vital sign”, pain – are often the first pieces of objective evidence gathered before formal evaluation of the patient. These simple non-invasive measurements provide essential (i.e. vital) insight into a patient’s clinical status, as they can indicate early objective changes prior to the onset of symptoms.

A medical practitioner should be familiar with accepted variations in normal ranges of measurements based on age, weight, and gender. Abnormality in vital signs can indicate an acute medical problem or a change in chronic disease state. If these have been obtained prior to the examiner’s first encounter with the patient, but are abnormal, it is advised to perform repeated measurement. The vital signs help guide the evaluation of the patient and to formulate the assessment and plan.

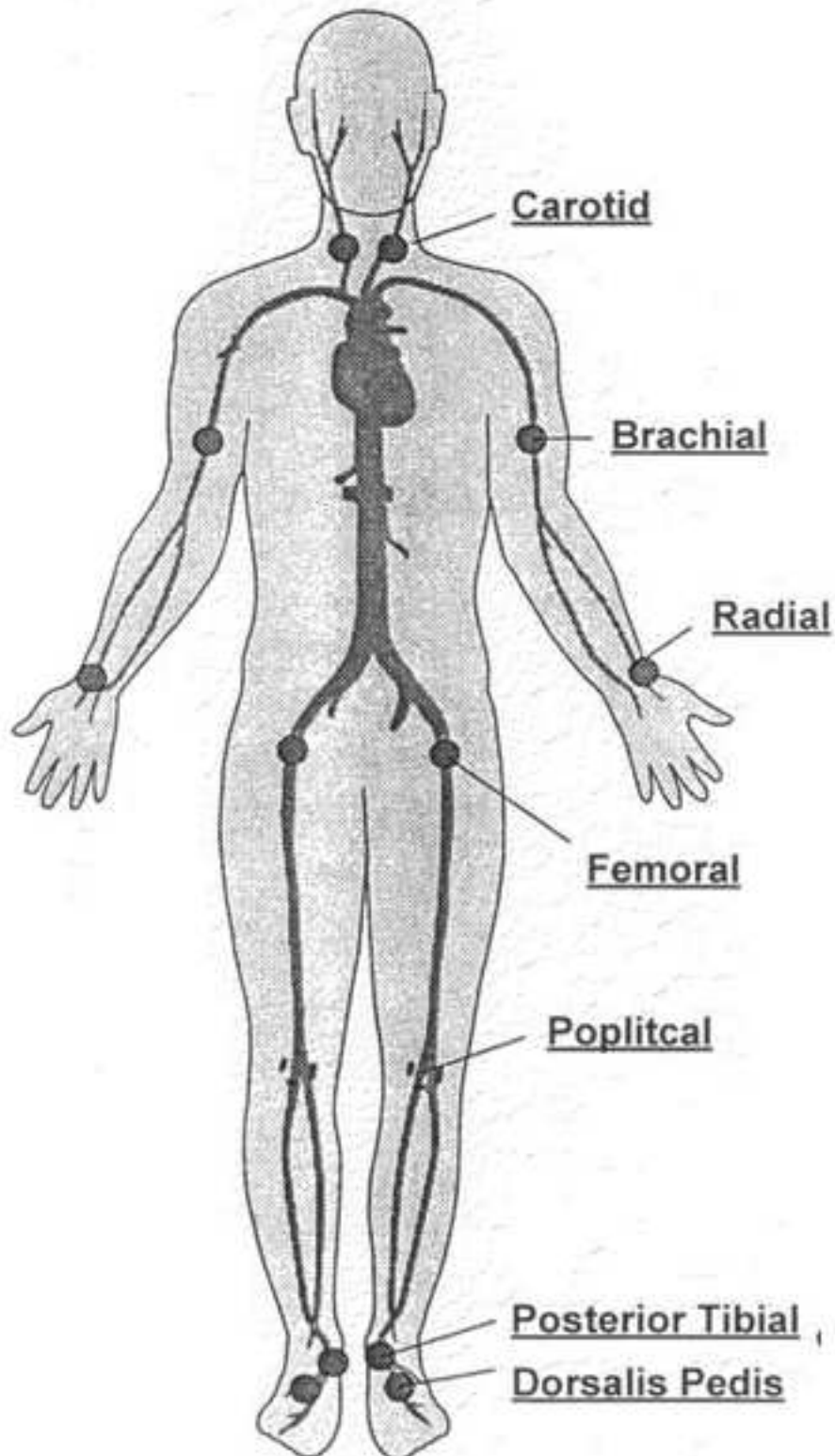
### Figures and legends.

**Figure 1:** Common sites to assess peripheral pulses.  
A schematic of sites for assessment of peripheral arterial pulses.

**Comment [JR3]:** If possible, can this be redrawn?

# Peripheral Pulses

Pulse Rate = pulses/60 sec



**Author Name:** Meghan Fashjian, ACNP-BC

**Clinical Skills Education Title:** Vital Signs

## Overview

The vital signs are objective measurements of a patient's clinical status. There are five commonly accepted vital signs: blood pressure, heart rate, temperature, respiratory rate, and oxygen saturation. In many practices, pain is considered the sixth vital sign and should regularly be documented in the same location as the vital signs. However, the pain scale is a subjective measurement and, therefore, has a different value according to each individual patient.

The vital signs assessment includes estimation of heart rate, blood pressure (demonstrated in a separate video), respiratory rate, temperature, oxygen saturation, and the presence and severity of pain. The accepted ranges for vital signs are: heart rate (HR), 60-100 beats per minute (bpm); respiratory rate (RR), 14-20 bpm; oxygen saturation, (SaO2) > 92%; and average oral temperature, 98.6 °F (37 °C) (normal average rectal and tympanic temperatures are 1° higher (measuring core temp), and axillary temperature is 1° lower).

Vital signs serve as the first clue that something may be amiss with a patient, especially if the patient is unable to communicate. Although there are quoted normal ranges, each patient should be considered as an individual and not treated without taking into account the entire clinical picture.

## Procedure

Make sure the patient has been seated and resting for at least 5 min prior to obtaining vital signs (VS) to accurately determine the baseline. ~~The vital signs assessment includes estimation of heart rate, blood pressure (demonstrated in a separate video), respiratory rate, temperature, oxygen saturation, and the presence and severity of pain.~~

### 1. Heart rate.

The radial artery is the most common site used to assess the pulse.

1.1. Explain to the patient that you are going to start by checking their pulse.

1.2. Place your index and middle fingers on the radial pulse (never use the thumb, as you can sometimes feel your own pulse). To prevent occlusion, do not press or apply pressure to the artery.

1.3. Assess the rhythm.

1.3.1. If the rhythm is regular, count the beats for 15 sec, then multiply by 4.

**Comment [JS1]:** I think this paragraph should include a brief overview of how the estimates will be taken. Right now, that information is currently located in the Procedure section under each vital sign as it's introduced.

**Comment [AS2]:** It might be a good strategy when one maneuver is demonstrated, but as this manuscript covers a few simple techniques, the author and I believe it's best to review each vital sign separately. Also, we try to keep the word count low for the Overview, as it serves as a brief introduction that leads into the in-depth Procedure.

This manuscript is one of many that we have already submitted, and we try to include some theoretical information in the procedure section within formatting limits to facilitate the learning process. It is next to impossible to memorize all these maneuvers without understanding the rationale behind them, and this is what sets our collection apart from other video tutorials on basic clinical skills.

1.3.2. If the rhythm is irregular, count the beats for a full 60 sec. A regularly irregular pulse may signal premature beats, whereas an irregularly irregular rhythm may signal atrial fibrillation. Confirm any abnormalities with an electrocardiogram (ECG).

1.4. Note the amplitude of the pulse (normal, bounding, diminished, or absent). Bounding pulses may be observed at rest with atherosclerosis, congestive heart failure (CHF), kidney disease, aortic insufficiency, or fever. Diminished pulses may be noted with peripheral vascular disease (PVD) or sepsis. If absent, it may be due to occlusion of the artery and should be further investigated.

1.5. If unable to palpate a pulse in the radial area, move to a different site as listed in **Figure 1** or obtain a Doppler machine for assistance. A Doppler machine is a handheld device with an ultrasound transducer that is used to amplify a pulse and produce an audible heart rate.

1.6. Record HR, making a note of rhythm and amplitude on the VS flow sheet.

## 2. Respiratory rate.

Attempt to calculate the respiratory rate without the patient becoming aware. This can be done either by leaving the fingers on the patient's radial pulse or by counting during the cardiovascular portion of the physical exam when they are breathing normally.

2.1. Count the respiratory rate for a full 60 sec. One respiratory cycle includes both one inspiration and one expiration. Note if slow breathing (bradypnea) or rapid shallow breathing (tachypnea) is present.

2.2. Assess the regularity of breathing. Note if an irregularly irregular (ataxic or Biot's) or regularly irregular (Cheyne-Stokes, characterized by long periods of apnea (no breathing)) pattern is present.

2.3. Note the depth of breathing. Is the patient engaged in shallow or very deep breathing? For example, rapid shallow breathing can be labeled as tachypnea, whereas deep rapid breathing may be Kussmaul breathing, which is associated with diabetic ketoacidosis.

2.4. Note the work of breathing. Is the patient utilizing accessory muscles with respiration? These include the trapezius, scalene, sternomastoid, and external intercostal muscles. This often indicates if there is an issue with oxygen delivery or air trapping.

2.5. Record the rate and rhythm on the VS flow sheet. Also include depth and work of breathing, if abnormal.

## 3. Temperature.

An examiner can obtain oral, rectal, axillary, or tympanic membrane temperatures. Be familiar with the differences in the expected normal values. In the office setting, the most common method of checking the temperature is oral. If the patient is non-responsive or unable to



cooperate, oral is not the preferred method, and the examiner should use an alternate technique.

3.1. Explain to the patient that you are going to check their temperature.

3.2. Place a disposable plastic sheath on the thermometer.

3.3. If using a digital thermometer, insert under the patient's tongue and hold there until the thermometer alerts you that the temperature has been calculated.

3.4. If using a glass thermometer, make sure it reads less than 96 °F and insert under the patient's tongue. Hold there for 3 min.

3.5. Record the temperature and location obtained on the vital sign flow sheet.

#### 4. Oxygen saturation.

The oxygen saturation (SaO<sub>2</sub>) can be measured by a non-invasive method called pulse oximetry. The oximeter is a small, usually portable, device that consists of a monitor and a probe, which is placed on the patient's finger, toe, or earlobe. The probe allows two wavelengths of light to pass through the body to a photodetector. The changes in absorbance indicate the percentage of saturated hemoglobin in the arterial blood. Most oximeters display the patient's pulse rate, too. Be advised: if a patient's fingertip is cold or if the patient is wearing nail polish, this may interfere with the reading. There are also conditions that falsely elevate the readings including carbon monoxide (CO) poisoning.

4.1. Explain to the patient that you are going to check their oxygen saturation.

4.2. Place the oximeter probe onto the patient's finger. Finger probes are often a single rubber piece that can be hinged and slipped onto the fingertip. There are alternative probes that can be placed on other body parts, if unable to obtain a read from the finger.

4.3. Record the oximeter reading on the vital sign flow sheet.

#### 5. Pain.

This is considered the sixth vital sign, but is subjective and difficult to measure. Most institutions abide by the policy that pain is what the patient says it is. However, there is no objective way to measure from patient to patient. Most often in most instances, a numeric scale (1-10, 10 being the worst pain imaginable) is utilized to estimate presence and the level of pain in patients unable to understand or communicate appropriately. In non-verbal patients, children, or those who do not speak English, severity of pain is assessed by using the visual Wong-Baker FACES scale. Always remember to reassess pain after any intervention taken.

5.1. Ask the patient if they are having pain.

**Comment [AS3]:** We believe they are. We introduce a device used specifically in this section and briefly describe how it works before going into direct instructions of using said device.

**Comment [JS4]:** Are these details necessary here?

**Comment [JS5]:** This is repetitive from the Overview section.

**Comment [JR6]:** Awaiting response on license agreement.

**Comment [DM7]:** If permission for that is cost-prohibitive we can just reference the scale and not show it.

5.1.1. If the patient expresses comprehension and does have pain, ask them to quantify it on a scale of 1-10.

5.1.2. If the patient is unable to comprehend, but appears to have pain, show them the FACES scale to determine the severity of pain.

5.2. Record on the vital sign flow sheet.

### Summary

The vital signs – blood pressure, heart rate, respiratory rate, temperature, oxygen saturation, and “the 6th vital sign”, pain – are often the first pieces of objective evidence gathered before formal evaluation of the patient. These simple non-invasive measurements provide essential (*i.e.*, vital) insight into a patient’s clinical status, as they can indicate early objective changes prior to the onset of symptoms.

A medical practitioner should be familiar with accepted variations in normal ranges of measurements based on age, weight, and gender. Abnormality in vital signs can indicate an acute medical problem or a change in chronic disease state. If these have been obtained prior to the examiner’s first encounter with the patient, but are abnormal, it is advised to perform repeated measurement. The vital signs help guide the evaluation of the patient and to formulate the assessment and plan.

### Figures and legends.

**Figure 1:** Common sites to assess peripheral pulses.  
A schematic of sites for assessment of peripheral arterial pulses.

**Comment [JR8]:** If possible, can this be redrawn?