

JoVE: Science Education
Electrocardiography (ECG)
--Manuscript Draft--

Manuscript Number:	10106
Full Title:	Electrocardiography (ECG)
Article Type:	Manuscript
Section/Category:	Manuscript Submission
Corresponding Author:	Richard Glickman-Simon UNITED STATES
Corresponding Author Secondary Information:	
Corresponding Author's Institution:	
Corresponding Author's Secondary Institution:	
First Author:	Richard Glickman-Simon
First Author Secondary Information:	
Order of Authors:	Richard Glickman-Simon
Order of Authors Secondary Information:	

Author Name: Richard Glickman-Simon
Clinical Skills Education Title: Electrocardiography (ECG)

Overview

The electrical activity generated by cardiac cells permeates through extracellular fluids to reach the surface of the body. Electrocardiographic (ECG) equipment is used to measure voltage changes between two surface points representing the summation of these impulses from individual cardiac cells. The size of these voltage changes corresponds to the number of cells depolarizing or repolarizing at any given moment. Because the cellular mass of the myocardium far exceeds that of the conduction tissue, peak depolarization corresponds closely with myocardial activity. Since the propagation of electrical impulses through the heart is consistent with each beat, the ECG waveform appears the same with each cardiac cycle (**Figure 1**). Atrial depolarization generates the P wave, and ventricular depolarization generates the QRS complex. These events coincide with atrial and ventricular systole (contraction), respectively. Ventricular repolarization generates the T wave. The PR interval corresponds to the conduction time through the atria and AV node; the ST segment corresponds to the resting phase of ventricular action potentials; and the QT interval corresponds to the total duration of ventricular systole.

Since the spread of electrical energy exhibits a stereotypical pattern as it travels through the heart in three dimensions, it behaves as a vector with both magnitude and direction. This directionality is captured in a 12-lead ECG, in which the wave of excitation is “viewed” from twelve different orientations, or projection vectors, in two planes. As the wave moves toward a positive electrode, an upward deflection is recorded for that lead. As it moves away, a downward deflection is recorded. The limb leads consist of recording electrodes on both wrists and the left leg (either leg is suitable, but by convention, a fourth electrode on the right leg is used as a ground) (**Figure 2**). By assigning polarities to the three electrodes, the ECG equipment creates six independent leads capable of recording the electrical pattern of the heart from six different perspectives in the frontal plane: I, II, III, aVR, aVL, and aVF.

The remaining six precordial (chest) leads are placed in an arc over the anterolateral chest (**Figure 3**). The chest leads measure the electrical pattern from six different perspectives in the transverse plane: V1, V2, V3, V4, V5, and V6. Observing the pattern of ECG changes across twelve leads can help determine the location in the heart affected by a conduction abnormality (**Figure 4**). Note that the 12-lead ECG includes a rhythm strip from one or more leads at the bottom. This longer run of beats makes it easier to quickly assess heart rate and rhythm.

Procedure

Electrocardiograms are routinely recorded in a variety of settings. A resting ECG (demonstrated here) is done while the patient is lying quietly. Cardiac telemetry involves continuous ECG

Comment [AS1]: The overview describes principle and theory behind the ECG. Because the manuscript is very short (less than 3 pages total, the procedure itself is 1.5 pages) and this information is crucial, I think it all has to be included. AS

monitoring in hospitalized patients. A stress ECG is obtained while the patient exercises in a cardiology lab in order to determine the effects of increasing myocardial demand. A Holter monitor is a device worn by the patient for 24 hours that records an ECG tracing during daily normal activity.

1. Prepare for ECG.

1.1. Check to make sure the equipment is turned on and ready for use. Disentangle all 12 leads and load the machine with graph paper, if necessary.

1.2. Have the patient lie supine on a comfortable surface with their clothes removed down to the waist. Appropriately cover women with a gown or bed sheet.

2. Place Leads.

2.1. Most electrocardiograph machines come equipped with adhesive pads designed to adhere to the skin and efficiently conduct electricity to lead electrodes. If available, pull the backing off 4 pads and securely fix a pad to each of the patient's wrists and ankles. If the pads are unavailable, use an alcohol swab or conduction gel as a substitute.

2.2. Connect the 4 limb leads to the adhesive pads according to the label on each lead: RA, LA, RL, and LL.

2.3. Fix the adhesive pads to the 6 locations shown in **Figure 3**: V1 – right sternal border at the fourth intercostal space; V2 – left sternal border at the fourth intercostal space; V3 – one centimeter lateral to the left sternal border at the fifth rib; V4 – mid-clavicular line at the fifth intercostal space; V5 – anterior axillary line at the sixth rib; V6 – mid-axillary line at the sixth rib.

2.4. Connect the 6 precordial leads to the adhesive pads according to the label on each lead: V1–V6.

3. Record the ECG.

3.1. Ask the patient to lie perfectly still. Any muscle activity may loosen the contact points or degrade the electrical signal.

3.2. Run the ECG. Check to see that the tracing is stable and decipherable, and make sure the stereotypical waveform for each lead is recognizable (**Figure 4**). If something is amiss, make sure all 12 leads are in their proper position and firmly in place. Rerun the ECG until the tracing is satisfactory.

3.3. Disconnect the leads and gently remove the pads (or wipe off the gel).

4. Interpret the ECG.

Reading an ECG requires detailed knowledge of cardiac electrophysiology and a great deal of practice. Taking a systematic approach ensures that any clinically significant abnormalities are not missed. Here are a few tips for the initial evaluation of an ECG tracing:

4.1. First, notice the rate and rhythm. A regular rhythm appears as equally spaced QRS complexes. If the rhythm is regular, the ECG device accurately calculates and displays the heart rate by measuring the time intervals between each QRS complex. If irregular, look for a repeated pattern to the irregularity or note if the rhythm is irregularly irregular.

4.2. Check the presence and shape of the P waves, QRS complexes, and T waves. Absent P waves in the presence of an irregularly irregular rhythm, for example, suggest atrial fibrillation; whereas, wide or strangely-shaped QRS complexes suggest ventricular dysrhythmia.

4.3. Check the intervals between waveforms, which the device calculates and displays along with the left ventricular axis.

4.4. Look for signs of myocardial ischemia, which can manifest as changes in the ST segment, or absent Q waves, and ventricular hypertrophy.

4.5. Look for evidence of ventricular hypertrophy, in which precordial Q waves may appear exaggerated in height.

Summary

The electrocardiogram records instantaneous voltage changes sweeping across the heart during each cardiac cycle. It is therefore capable of detecting cardiac disorders that manifest as aberrations in the generation and conduction of electrical activity anywhere in the heart. This makes the ECG the test of first choice for diagnosing cardiac dysrhythmias. It is also indispensable in the evaluation of acute coronary syndrome and certain metabolic disorders affecting the cardiac conduction system. The use of twelve leads allows the ECG to capture information about the magnitude and direction of the wave of excitation as it passes through the heart. The sensitivity of the resting ECG is limited, because many cardiac disorders, including myocardial ischemia, occur only during exercise. Stress ECGs and Holter monitors increase this sensitivity by capturing the heart's electrical activity at times of increased myocardial demand. The ECG cannot directly measure mechanical functioning of the heart's chambers and valves, but it can suggest the presence of functional abnormalities in so far as they produce electrical disturbances.

Figures and legends.

Figure 1: Normal ECG Waveform.

A normal ECG waveform with segments and peaks labelled.

Comment [JR2]: All figures downloaded from Shutterstock.

Figure 2: Limb Leads.

The position of the ECG limb leads. RA – right arm, LA – left arm, LL – left leg.

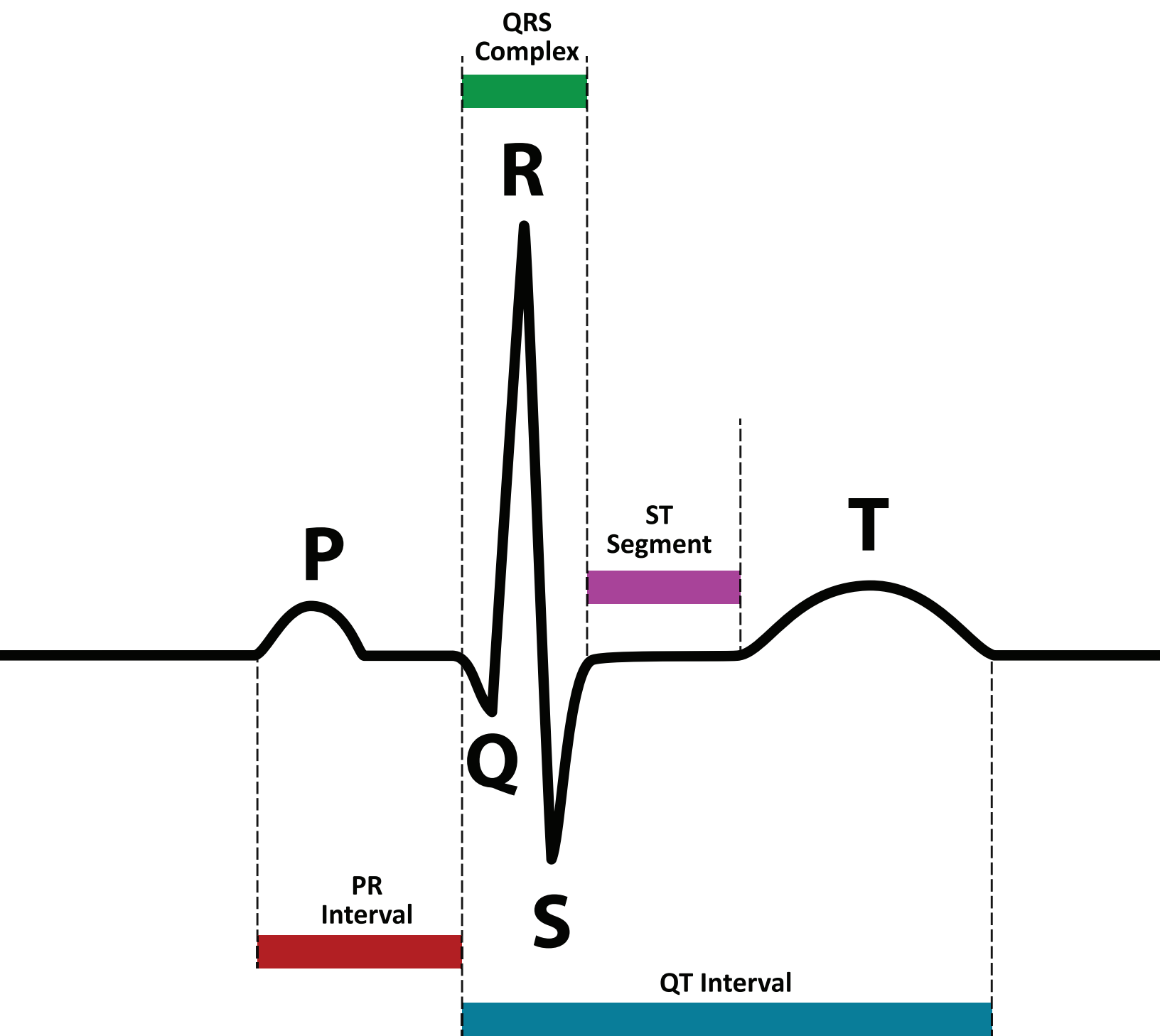
Figure 3: Precordial (Chest) Leads.

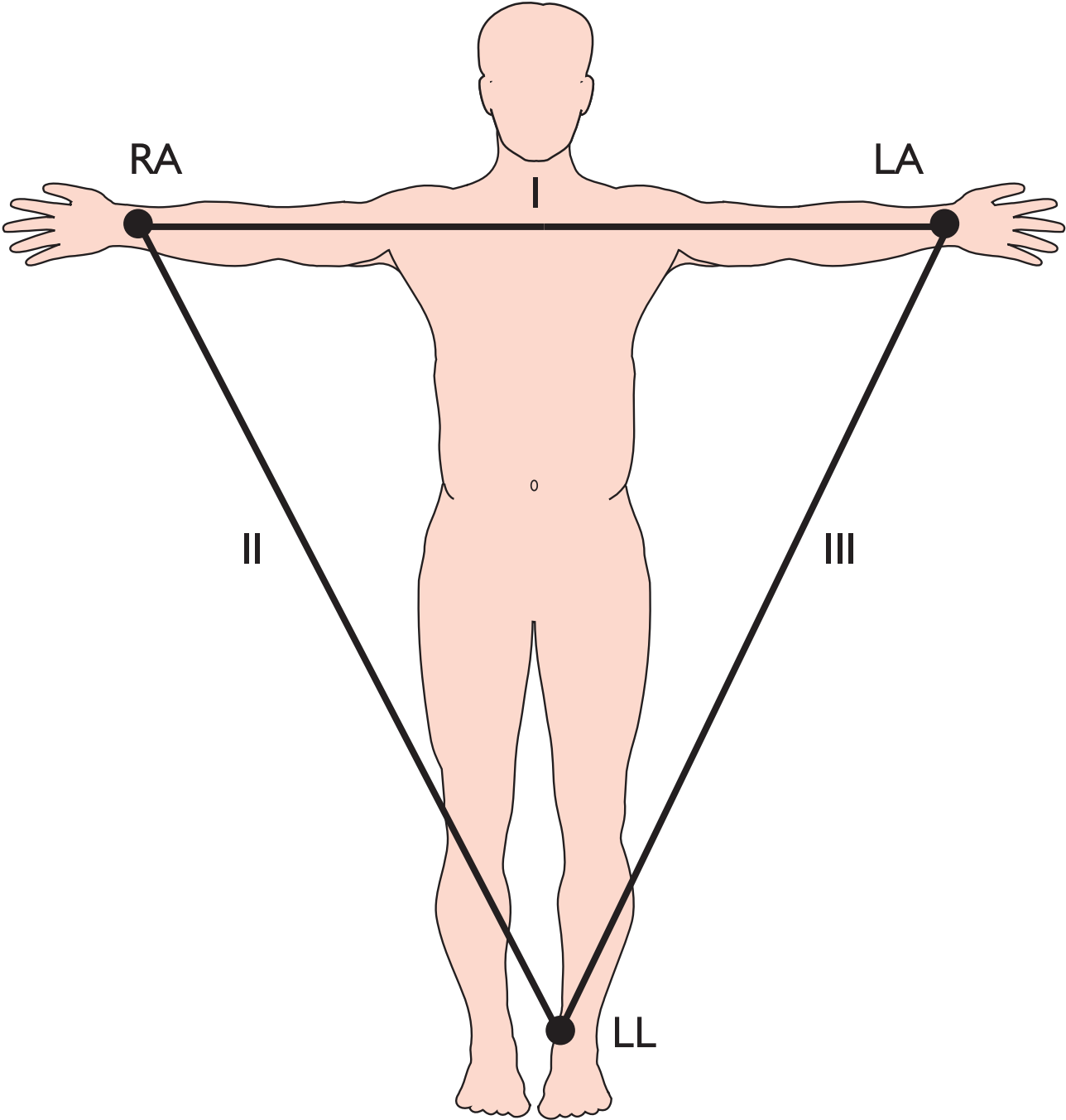
The position of the chest leads, V1-V6.

Figure 4: 12-Lead ECG.

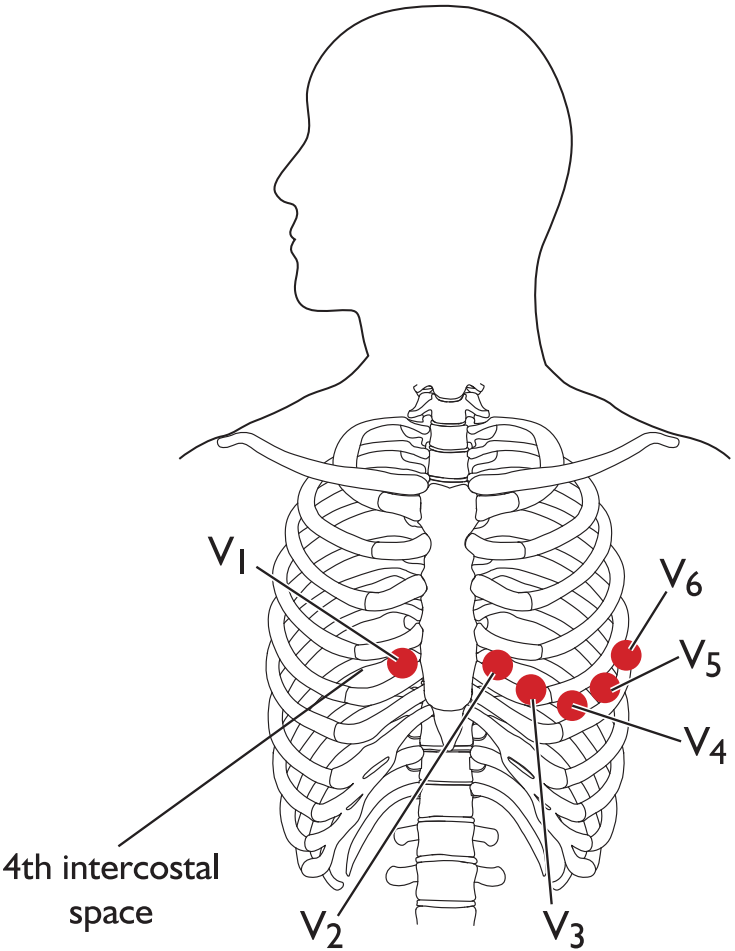
An example of a normal 12-lead sinus rhythm electrocardiogram.

Comment [JR3]: For Figure 3, we only need the left half (Panel A) of the image. If it's not possible to modify the image, we can add something simple to the caption, like "Panel A shows the position of the standard chest lead placement for V1-V6."

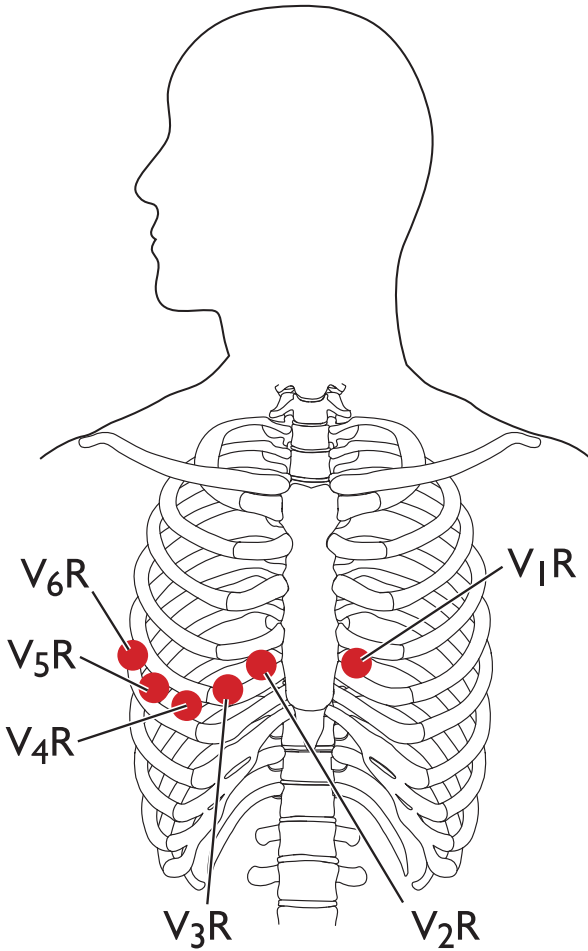




Limb leads



A. Standard chest lead placement



B. Right sided chest lead placement

