

JoVE: Science Education
Motor Exam Part II - Reflex Evaluation
--Manuscript Draft--

Manuscript Number:	10074
Full Title:	Motor Exam Part II - Reflex Evaluation
Article Type:	Manuscript
Section/Category:	Manuscript Submission
Corresponding Author:	Cynthia Brown UNITED STATES
Corresponding Author Secondary Information:	
Corresponding Author's Institution:	
Corresponding Author's Secondary Institution:	
First Author:	Cynthia Brown
First Author Secondary Information:	
Order of Authors:	Cynthia Brown
Order of Authors Secondary Information:	

Author Name: Cynthia Brown M.D.

Clinical Skills Education Title: Motor Exam Part II – Reflex Evaluation

Overview

The deep tendon reflexes are monosynaptic spinal reflexes. In clinical practice, they are elicited by briskly tapping the muscle tendon with a reflex hammer. This causes an involuntary muscle contraction in response to rapid stretching of the muscle tendon (**Figure 1**), and then, the response is evaluated by a clinician in a semi-quantitative way.

There are many types of reflex hammers (**Figure 2**), and the examiner should find one that is well-balanced and can be used with a reproducible stimulus. The best way to use the hammer is to let it drop rather than swinging it to hit the tendon. Letting the hammer fall will result in an equal stimulus each time. Although the hammer can be used to directly tap a partially stretched tendon, which allows the examiner to observe the result, it may be preferable to have the examiner place their fingers over the tendon and then tap their own fingers. This approach allows the examiner to both feel the strength of the tendon contraction as well as to observe the movement of the contracting muscle innervated by the corresponding nerve root.

Testing of deep tendon reflexes provides crucial information about the level at which the nervous system is affected. Decrease in deep tendon reflexes could be associated with the processes affecting the reflex arc: sensory fiber, spinal cord, or the motor fiber (termed the “lower motor neuron” or LMN). The lesion at the level of the descending motor tracts from the cerebral cortex and brain stem (“upper motor neurons” or UMN) can manifest by hyperreflexia; this is thought to be due to decreased tonic inhibition of the spinal reflexes.

The neurological exam also includes testing of the pathological reflexes that can indicate conditions such as frontal lobe disease and upper motor neuron lesions.

Procedure

1. Deep tendon reflexes: general approach.

1.1 Have the patient sit, with their legs hanging down, on the examination table. The testing can also be done with some repositioning of the limbs if the patient is lying in bed.

1.2 Instruct the patient to remain relaxed.

1.3 Elicit the reflexes by letting the reflex hammer drop either directly on the tendon or on your fingers placed on the tendon.

1.4 Test each reflex bilaterally and compare the sides.

1.5 If the reflexes cannot be obtained or are hypoactive, have the patient perform reinforcing maneuvers, which increase the reflexes.

1.5.1 To reinforce the reflexes, first have the patient relax. Then instruct the patient to clench their teeth and pull against their interlocked fingers with their arms elevated in front of them (Jendrassik maneuver).

1.6 For each reflex, grade the response from 0-4 with 2 being normal, 0 being absent, 1 being trace, 3 being increased, and 4 being hyperreflexia with clonus (**Table 1**). There are often "+" signs added to the numbers, allowing for more detailed assessment.

2. Upper extremity reflexes.

2.1 Triceps reflex (C 6, 7, 8).

2.1.1 With the patient seated, have their arm slightly flexed across their body.

2.1.2 Support the patient's forearm, and place your index and middle fingers over the triceps tendon.

2.1.3 Let the hammer fall on your fingers or allow it to fall on the tendon.

2.1.4 Feel the tendon contraction, and observe the extension of the elbow.

2.1.5 Repeat on the other side, and compare the sides.

2.2 Biceps reflex (C 5, 6).

2.2.1 Have the patient's arms resting in their lap, or support their forearm across your own arm.

2.2.2 Let the hammer fall on the biceps tendon in the antecubital fossa.

2.2.3 Alternatively, place your index and middle finger on the tendon, and allow the hammer to fall on your fingers in order to both feel the contraction of the tendon and observe the flexion of the arm.

2.2.4 Repeat on the other side and compare the sides.

2.3 Brachioradialis reflex (C 5, 6).

2.3.1 Have the patient's arms resting in their lap, or support their forearm across your own arm.

2.3.2 Either let the hammer fall on the brachioradialis tendon or place your index and middle finger on the tendon and allow the hammer to fall on your fingers in order to both feel the

contraction of the tendon and observe the contraction of the muscle (flexion of the elbow and supination of the hand).

2.3.3 Repeat on the other side and compare the sides.

3. Lower extremity reflexes.

3.1 Quadriceps reflex (knee-jerk) (L 2, 3, 4).

3.1.1 Have the patient sit with their legs hanging over the examination table.

3.1.2 Use the reflex hammer to either tap on the quadriceps tendon or place your fingers on the tendon and strike your own fingers.

3.1.3 Repeat on the other side and compare the sides. Remember that the patient's leg is likely to kick forward, so do not stand in front of the patient.

3.2 Achilles tendon reflex (ankle-jerk) (S 1).

3.2.1 Dorsiflex the patient's foot, and tap on the Achilles tendon with the hammer. Observe the reflex (the plantar flexion).

3.2.2 Repeat on the other side and compare the sides.

4. Babinski reflex.

4.1 Warn the patient that the testing causes a tickle with an unpleasant sensation.

4.2 Run the handle of the reflex hammer along the lateral portion of the dorsum of the patient's foot, from the heel and across the top of the foot toward the great toe.

4.2.1 The normal response is flexion of the great toe. A positive Babinski response is seen with upper motor neuron lesions and consists of extension of the great toe accompanied by fanning of the other toes (**Figure 3**).

4.3 Repeat on the other side and compare the sides.

5. Other reflexes.

5.1 Jaw jerk (Cranial nerve V).

5.1.1 Tell the patient to relax their jaw and open their mouth slightly.

5.1.2 Place your index finger along the protuberance of the chin and slightly tap it with the reflex hammer. Normally, there is no response. Upper motor neuron lesion can lead to masseter muscle contraction and an upward jaw jerk.

5.2 Hoffman response.

5.2.1 Tell the patient to relax their hand.

5.2.2 Hold the patient's middle finger between your thumb and index finger.

5.2.3 Snap your thumb against the patient's middle fingernail. Normally, there is no response. Upper motor neuron lesion can result in a positive Hoffman's response (when the fingers flex after the snap over the nail of the middle finger).

5.2.4 Repeat on the other side and compare the sides.

5.3 Perform clonus testing if the reflexes appear hyperactive and an upper motor lesion is suspected.

5.3.1 To test for clonus, hold the patient's relaxed lower leg and, with your hand on the dorsum of the foot, quickly dorsiflex the foot. Normally, there should be no response, but if clonus is present, the foot will have multiple oscillations back and forth.

Summary

Evaluation of the deep tendon reflexes is a critical part of a neurological exam and complements motor and sensor examination. The commonly tested deep tendon reflexes include the triceps, biceps, brachioradialis, quadriceps, and the Achilles reflexes. Abnormalities in the deep tendon reflexes can help verify the level of a lesion: hyperreflexia can be seen with upper motor neuron lesions and decreased reflexes may be seen with lesions of the peripheral nervous system. The pattern of the abnormality may help the clinician to reach a clinical diagnosis. For example, unilateral hyperreflexia can be seen in patients with a stroke or multiple sclerosis, but bilateral hyperreflexia may be the sign of a more diffuse upper motor neuron problem, such as amyotrophic lateral sclerosis.

Testing of reflexes is about symmetry, and the proper technique and consistency in eliciting reflexes is essential to determine if difference in reflexes between the sides is present. It may not be immediately apparent which side is abnormal, and the clinical context may help determine whether the reflexes are hyperactive or hypoactive.

Figures and legends:

Figure 1. Knee jerk reflex.

A simplified diagram of one of the commonly tested deep tendon reflexes, a knee jerk reflex. Striking the patellar ligament with a reflex hammer results in activation of the sensory neurons that make direct synapses on alpha motor neurons in the spinal cord, innervating the quadriceps muscle and causing it to contract.

Figure 2. Medical reflex hammers.

Two commonly used medical reflex hammers: Babinsky (top) and Taylor (bottom).

Figure 3. Babinski reflex.

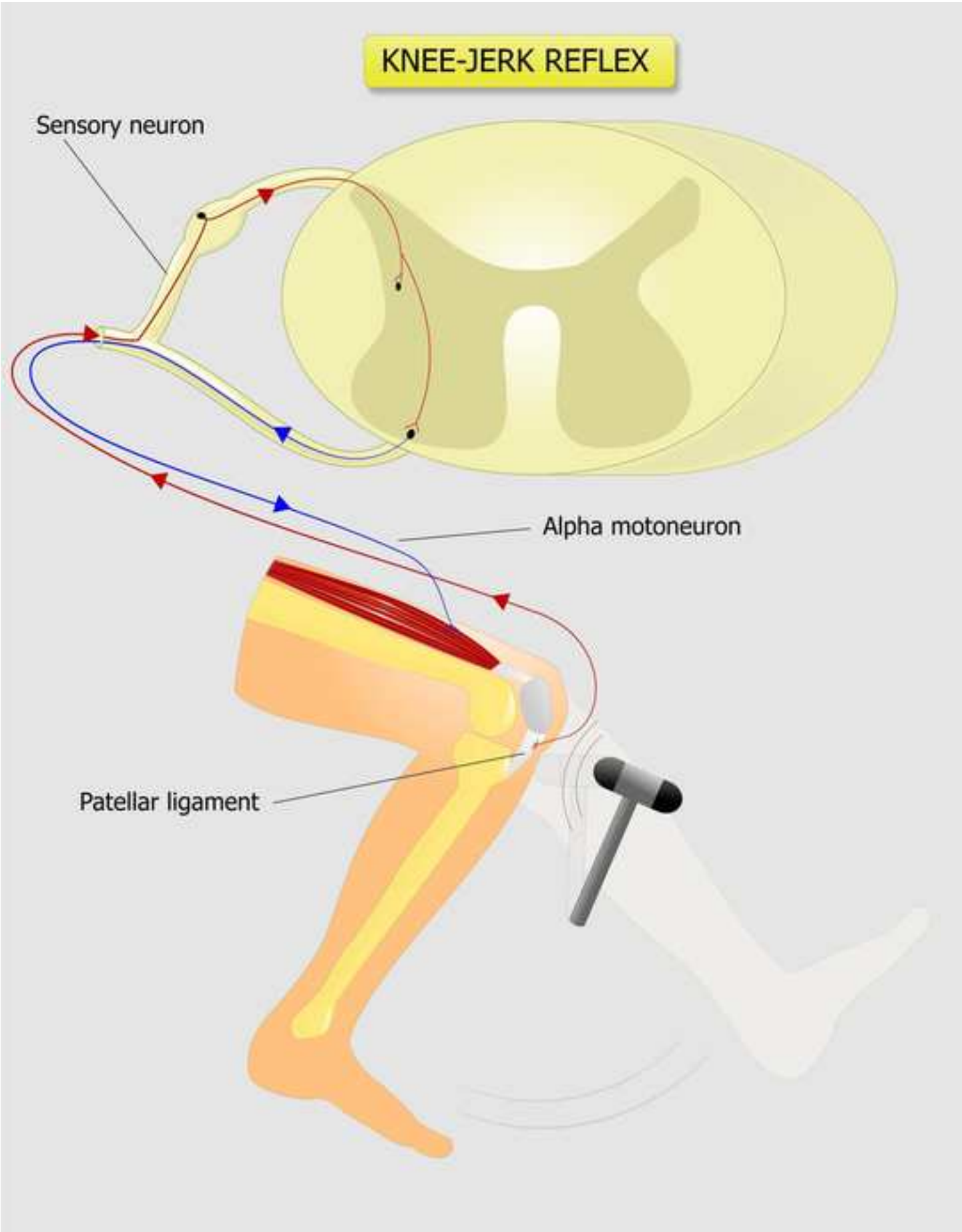
Normal (A) and pathological (positive Babinski sign) (B) plantar response.

Table 1: Scale for rating of deep tendon reflexes.

Comment [JR1]: If possible, can this figure be redrawn?

Table 1. Scale for rating of deep tendon reflexes.

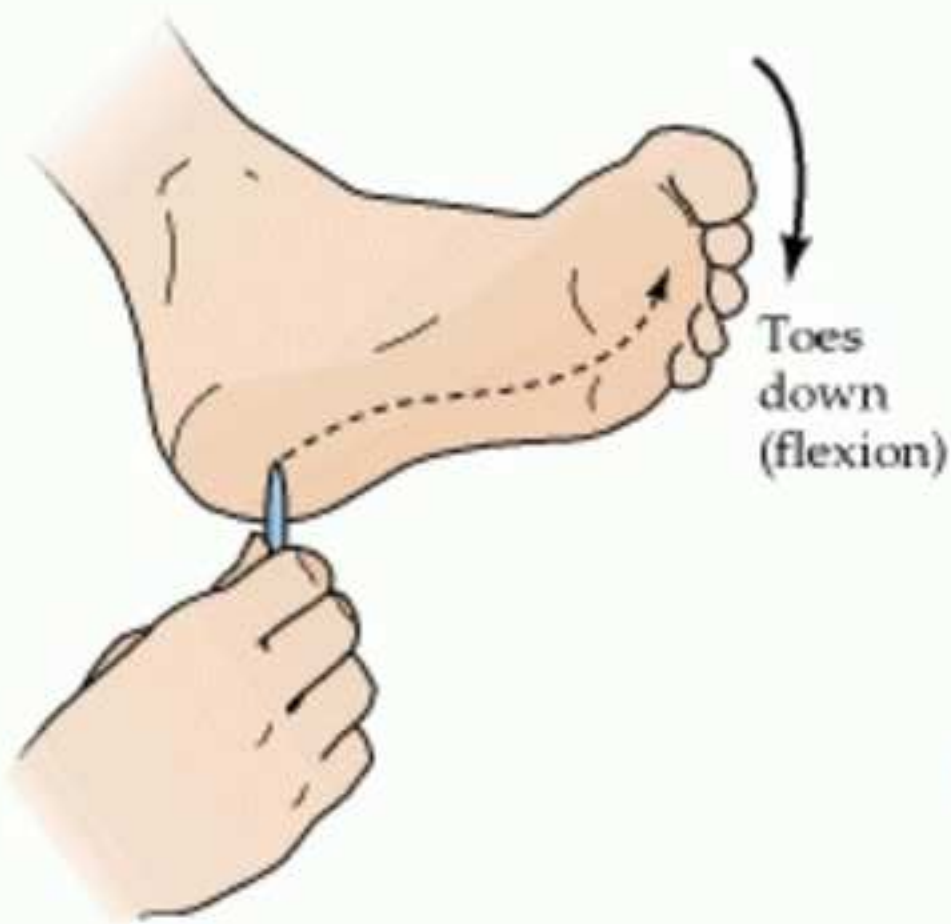
0	No reflex
1	Decreased (trace)
2	Normal
3	Increased
4	Hyperreflexic with clonus (repetitive vibratory movement)



[Click here to download high resolution image](#)



(A) Normal plantar response



(B) Extensor plantar response (Babinski sign)

