

JoVE: Science Education
Physical Examination of the Lungs: Percussion and Auscultation
--Manuscript Draft--

Manuscript Number:	10041
Full Title:	Physical Examination of the Lungs: Percussion and Auscultation
Article Type:	Manuscript
Section/Category:	Manuscript Submission
Corresponding Author:	Suneel Dhand UNITED STATES
Corresponding Author Secondary Information:	
Corresponding Author's Institution:	
Corresponding Author's Secondary Institution:	
First Author:	Suneel Dhand
First Author Secondary Information:	
Order of Authors:	Suneel Dhand
Order of Authors Secondary Information:	

Author Name: Suneel Dhand M.D.

Clinical Skills Education Title:

Physical Examination of the Lungs: Percussion and Auscultation

Overview

Learning the proper technique for percussion and auscultation of the respiratory system is vital and comes with practice on real patients. Percussion is a useful skill that is often skipped during everyday clinical practice, but if performed correctly, it can help the physician to identify underlying lung pathology. Auscultation can provide an almost immediate diagnosis for a number of acute pulmonary conditions, including Chronic Obstructive Pulmonary Disease (COPD), asthma, pneumonia, and pneumothorax.

The areas for auscultating the lungs correspond to the lung zones. Each lung lobe can be pictured underneath the chest wall during percussion and auscultation (Figure 1). The right lung has three lobes; the superior, middle, and inferior lobes. The left lung has two lobes; the superior and inferior lobes. The superior lobe of the left lung also has a separate projection known as the lingual.

Procedure

1. Positioning

- 1.1 Make sure the patient is undressed down to their waist.
- 1.2 Position the patient on the examination table at a 30-45 degree angle and approach them from their right side. Examining the posterior of the lung requires the patient to be leaning forward or sitting on the edge of the bed.

2. Percussion

- 2.1 Percuss both posteriorly and anteriorly, starting on the back.
- 2.2 Place non-dominant hand with middle finger (pleximeter finger) pressed and hyperextended firmly on the patient's right or left mid-back area (lower levels of lungs posteriorly). The firmer the finger is pressed to the chest wall, the louder tends to be the percussion note.
- 2.3 Make sure the other fingers and palm are not pressed against the patient's chest.
- 2.4 Use the tip of the middle finger (plexor finger) of the dominant hand to tap firmly on the top third (middle or distal phalanx) of the pleximeter finger of the non-dominant

hand at least twice (it is advisable to keep fingernails short.) The sound should be hollow, representing an air-filled lung.

2.5 Repeat the percussion at four and five levels, comparing each lung level side-by-side, working up to the chest wall, starting at the inferior lung borders. On expiration, the lower border of the lungs is at the level of the sixth rib at the midclavicular line and the eighth rib at the midaxillary line anteriorly, approximately at the level of the T10 spinous process posteriorly.

2.6 Percuss anteriorly, placing the finger on the chest in the intercostal spaces.

2.7 When percussing the left anterior chest, observe the dull percussion note over the heart.

2.8 The notes normally elicited by percussion of chest:

2.8.1 Resonant percussion note is the sound heard over a normal air-filled lung.

2.8.2 Dull percussion note is heard over solid tissues, such as the heart or liver. When this sound is elicited by percussion of the lungs, it is indicative of consolidation.

2.8.3 Tympanic is a drum-like sound when percussing over hollow organs, such as the stomach. Normally, it is elicited by percussion over the Traube's space, an area overlying the gastric bubble and bordered by the sixth rib, anterior axillary line, and left costal margin. Left pleural effusion produces a dull percussion sound over Traube's space.

Comment [AS1]: All this part is a demonstration

2.8.4 A "Stony dull" or flat percussion note sounds duller than the "standard" dull sound. It resembles the percussion note heard over the thigh and is indicative of a pleural effusion.

2.8.5 A hyper-resonant percussion note is a pathological percussion sound that is indicative of hyper-inflated lungs from advanced COPD, emphysema, or a pneumothorax.

Comment [AS2]: Narrative

3. Auscultation

3.1 Position the patient: ask the patient to lean forward or sit upright in order to examine posteriorly. Asking the patient to fold their arms or place hands on opposing shoulders also helps to get maximal exposure to the lung fields.

3.2 Place the diaphragm of the stethoscope on the patient's chest, and ask them to take deep breaths in and out through their mouth.

3.3 Auscultate at five levels posteriorly and anteriorly, comparing side by side.

3.3.1 Normal breath sounds are called vesicular breath sounds, which are low-pitched sounds louder on inspiration and softer on expiration. They should be symmetrical posteriorly.

3.4 Note the presence and location of abnormal (adventitious) extra breath sounds, such as crackles, wheezing, rhonchi, stridor, or pleural friction rub (Table 1).

3.5 Note the following characteristics of any abnormal breath sounds (if present): loudness, quality, duration, and whether they occur during inspiration or expiration (i.e. timing in the respiratory cycle). Many abnormal breath sounds are best heard after asking the patient to cough.

Comment [AS3]: If we don't get any recording for this part will be just a narrative, all of it.

3.6 Assess for bronchophony, an increased sound transmission over the consolidated lung, when asking the patient to say "99" or "1-2-1". Egophony is when an "E" sound changes to an "A" over consolidated lung.

3.7 Assess for whispering pectoriloquy. While auscultating with the stethoscope, ask the patient to whisper "99" or "1-2-1". In the consolidated lung, the sound will actually be heard better and more clearly with the stethoscope.

Summary

Percussion and auscultation should always be done in sequence whenever performing a full respiratory examination. Learning how to percuss correctly takes time and practice (practice can be done on yourself or other surfaces, such as a table). Note how the percussion note changes naturally over air-filled lung, ribs, and solid organs, such as the heart.

Auscultation must be performed over each lung zone to give the physician the best chance of identifying the focus of any lung pathology. Abnormal breath sounds should be easily recognizable when occurring in a patient. Allow enough time to classify the breath sounds. Listen for several breathing cycles in one area, if necessary, to hear the exact nature of the crackles, wheezes, rhonchi, or other pathological findings. Distinguishing between certain breath sounds can occasionally seem subjective, but will become easier with practice, leading to a "spot diagnosis" for many pulmonary conditions.

Figures and Legends

Figure 1. Anatomy of lungs with respect to the chest wall.

Motion graphics showing approximate projections of lungs and their fissures and lobes to the chest wall anteriorly (A) and posteriorly (B).

Comment [D4]: This is a motion graphics picture that Dr Dhang asked to recreate.

RUL – Right Upper Lobe; RML – Right Middle Lobe; RLL – Right Lower Lobe; LUL – Left Upper Lobe; LLL – Left Lower Lobe.

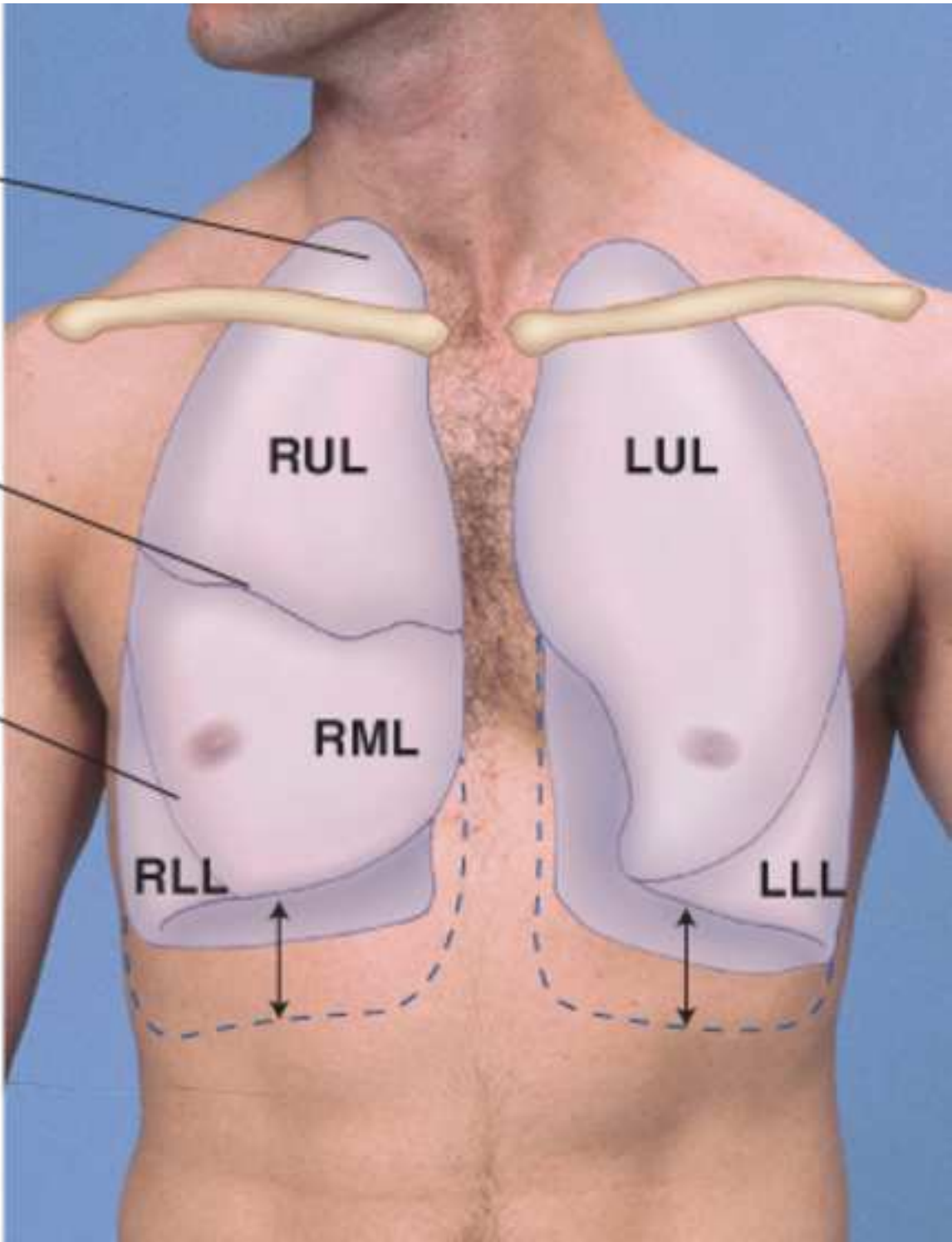
Table 1. Abnormal lung sounds.

A table summarizing potential abnormal findings during auscultation of the lungs.

Apex
of lung

Horizontal
fissure

Oblique
fissure



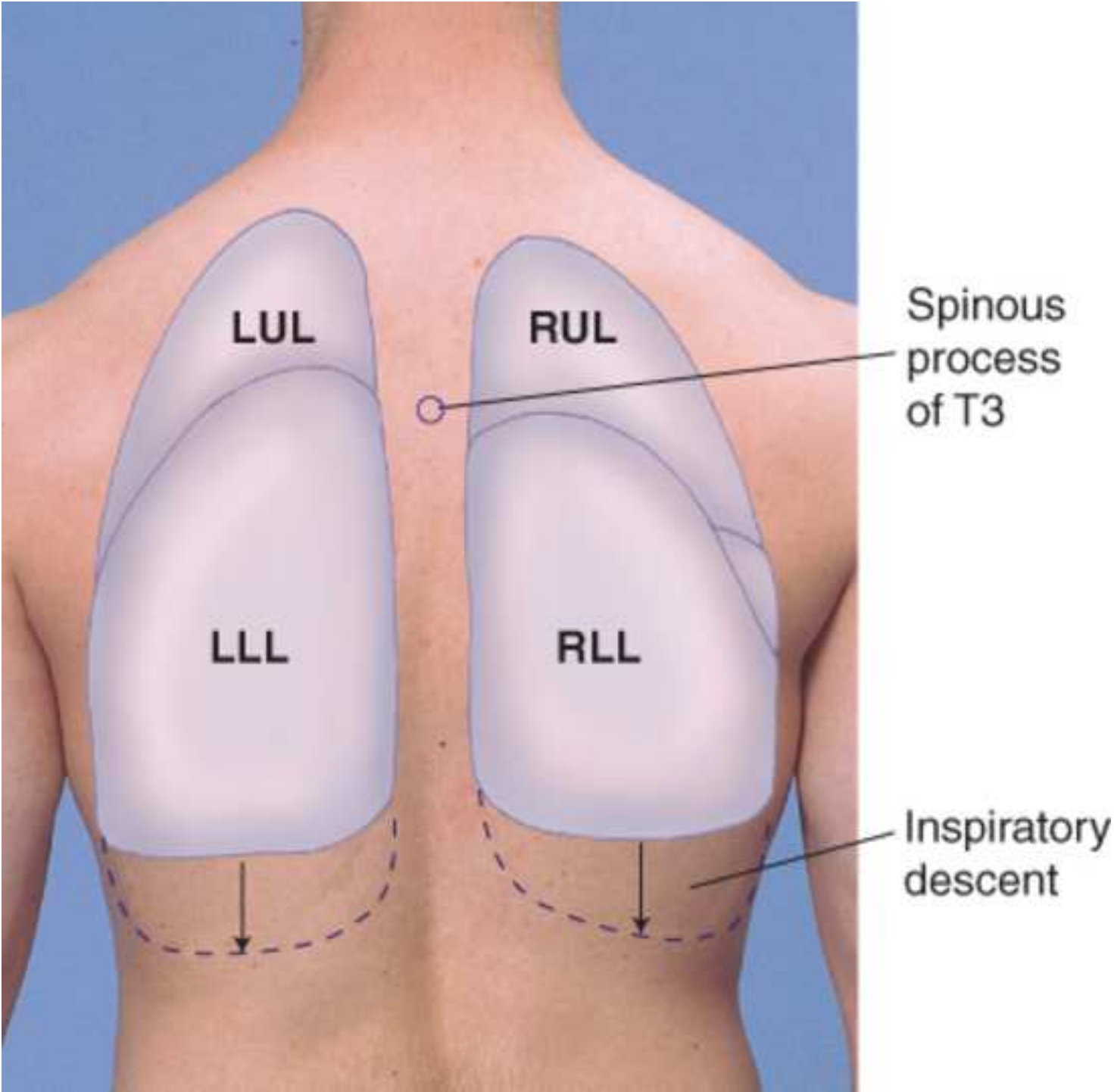


Table 1. Abnormal breath sounds.

Abnormal breath sounds	Description
Bronchial	Harsh or hollow breath sounds, similar to what you would hear if you placed your stethoscope over the trachea or main bronchi. In other areas they can be a sign of underlying consolidation
Bronchovesicular	Normal over the large airways and sternum, abnormal in other areas
Crackles (aka crepitations or rales)	Caused by fluid in the airways and are more commonly heard during inspiration at the bases of the lungs. They can be classified as fine; which are soft, brief high-pitched sounds or “pops”, or coarse; which are louder and lower pitched than fine crackles. Fine crackles can be heard in pulmonary fibrosis and course crackles in COPD and pneumonia. Note the timing of the crackles. Congestive heart failure typically produces late crackles
Wheeze	Distinctive high-pitched continuous sound heard in asthma and COPD
Rhonchi	Low-pitched “snoring” sound that can be auscultated in any condition causing reactive airways disease, including pneumonia, COPD, and CHF
Stridor	An abnormal high-pitched sound generated from the upper airways, usually during inspiration (this is often a medical emergency)
Rub	Caused by pleural surfaces rubbing against each other (pleural friction rub), and heard more in pleurisy as well as other conditions, such as pericarditis

Author Name: Suneel Dhand M.D.

Clinical Skills Education Title: Physical Examination of the Lungs: Percussion and Auscultation

Overview

Learning the proper technique for percussion and auscultation of the respiratory system is vital and comes with practice on real patients. Percussion is a useful skill often skipped during every day clinical practice, but if performed correctly, it can help the physician to identify underlying lung pathology. Auscultation can provide an almost immediate diagnosis for a number of acute pulmonary conditions, including Chronic Obstructive Pulmonary Disease (COPD), asthma, pneumonia, and pneumothorax.

The areas for auscultating the lungs correspond to the lung zones. Each lung lobe can be pictured underneath the chest wall during percussion and auscultation (Figure 1). The right lung has three lobes; the superior, middle, and inferior lobes. The left lung has two lobes; the superior and inferior lobes. The superior lobe of the left lung also has a separate projection known as the lingual.

Procedure

1. Positioning

- 1.1 Make sure the patient is undressed down to their waist.
- 1.2 Position the patient on the examination table at a 30-45 degree angle and approach them from their right side. Examining the posterior of the lung requires the patient to be leaning forward or sitting on the edge of the bed.

2. Percussion

- 2.1 Percuss both posteriorly and anteriorly, starting on the back.
- 2.2 Place non-dominant hand with middle finger (pleximeter finger) pressed and hyperextended firmly on the patient's right or left mid-back area (lower levels of lungs posteriorly). The firmer the finger is pressed to the chest wall, the louder tends to be the percussion note.
- 2.3 Make sure the other fingers and palm are not pressed against the patient's chest.
- 2.4 Use the tip of the middle finger (plexor finger) of the dominant hand to tap firmly on the top third (middle or distal phalanx) of the pleximeter finger of the non-dominant hand at least twice (it is advisable to keep fingernails short.) The sound should be hollow, representing an air-filled lung.

2.5 Repeat the percussion at four and five levels, comparing each lung level side-by-side, working up to the chest wall, starting at the inferior lung borders. On expiration, the lower border of the lungs is at the level of the sixth rib at the midclavicular line and the eighth rib at the midaxillary line anteriorly, approximately at the level of the T10 spinous process posteriorly.

2.6 Percuss anteriorly and posteriorly, placing the finger on the chest in the intercostal spaces.

2.7 Appreciate the quality of percussion sounds. The normal findings on the chest percussion are:

2.7.1 Resonant percussion note: heard over a normal air-filled lung.

2.7.2 Dull percussion note (the sound heard over solid tissues): over the liver in the right lower anterior chest and over the heart in the left anterior chest. When this sound is elicited by percussion of the lungs, it is indicative of consolidation.

2.7.3 Tympanic percussion note (a drum-like sound when percussing over hollow organs): over the Traube's space, an area overlying the gastric bubble and bordered by the sixth rib, anterior axillary line, and left costal margin. Left pleural effusion produces a dull percussion sound over Traube's space.

2.8 Note the presence of pathological percussion sounds. A "Stony dull" or flat percussion note sounds duller than the "standard" dull sound. It resembles the percussion note heard over the thigh and is indicative of a pleural effusion. A hyper-resonant percussion note is a pathological percussion sound indicative of hyper-inflated lungs from advanced COPD, emphysema, or a pneumothorax.

~~2.7 When percussing the left anterior chest, observe the dull percussion note over the heart.~~

2.8 The notes normally elicited by percussion of chest:

2.8.1 Resonant percussion note is the sound heard over a normal air-filled lung.

2.8.2 Dull percussion note is heard over solid tissues, such as the heart or liver. When this sound is elicited by percussion of the lungs, it is indicative of consolidation.

~~2.8.3 Tympanic is a drum-like sound when percussing over hollow organs, such as the stomach. Normally, it is elicited by percussion over the Traube's space, an area overlying the gastric bubble and bordered by the sixth rib, anterior axillary line, and left costal margin. Left pleural effusion produces a dull percussion sound over Traube's space.~~

Formatted: Not Highlight

Formatted: Not Highlight

Comment [AK1]: If this part is meant to be included in the video, then it simply needs to be highlighted like the rest of the text. In short, the highlighting designates the sections of the protocol necessary for scripting and therefore "demonstration". Production notes should clearly specify how this "demonstration" is different from the rest.

Formatted: Not Highlight

2.8.4 A “stony dull” or flat percussion note sounds duller than the “standard” dull sound. It resembles the percussion note heard over the thigh and is indicative of a pleural effusion.

2.8.5 A hyper-resonant percussion note is a pathological percussion sound that is indicative of hyper-inflated lungs from advanced COPD, emphysema, or a pneumothorax.

3. Auscultation

3.1 Position the patient: ask the patient to lean forward or sit upright in order to examine posteriorly. Asking the patient to fold their arms or place hands on opposing shoulders also helps to get maximal exposure to the lung fields.

3.2 Place the diaphragm of the stethoscope on the patient’s chest, and ask them to take deep breaths in and out through their mouth.

3.3 Auscultate at five levels posteriorly and anteriorly, comparing side by side.

3.3.1 Normal breath sounds are called vesicular breath sounds, which are low-pitched sounds louder on inspiration and softer on expiration. They should be symmetrical posteriorly.

3.4 Note the presence and location of abnormal (adventitious) extra breath sounds, such as crackles, wheezing, rhonchi, stridor, or pleural friction rub (Table 1).

3.5 Note the following characteristics of any abnormal breath sounds (if present): loudness, quality, duration, and whether they occur during inspiration or expiration (i.e. timing in the respiratory cycle). Many abnormal breath sounds are best heard after asking the patient to cough.

Comment [AS2]: If we don’t get any recording for this part will be just a narrative, all of it.

3.6 Assess for bronchophony, an increased sound transmission over the consolidated lung, when asking the patient to say “99” or “1-2-1”. Egophony is when an “E” sound changes to an “A” over consolidated lung.

3.7 Assess for whispering pectoriloquy. While auscultating with the stethoscope, ask the patient to whisper “99” or “1-2-1”. In the consolidated lung, the sound will actually be heard better and more clearly with the stethoscope.

Summary

Percussion and auscultation should always be done in sequence whenever performing a full respiratory examination. Learning how to percuss correctly takes time and practice (practice can be done on yourself or other surfaces, such as a table). Note how the

percussion note changes naturally over air-filled lung, ribs, and solid organs, such as the heart.

Auscultation must be performed over each lung zone to give the physician the best chance of identifying the focus of any lung pathology. Abnormal breath sounds should be easily recognizable when occurring in a patient. Allow enough time to classify the breath sounds. Listen for several breathing cycles in one area, if necessary, to hear the exact nature of the crackles, wheezes, rhonchi, or other pathological findings. Distinguishing between certain breath sounds can occasionally seem subjective, but will become easier with practice, leading to a “spot diagnosis” for many pulmonary conditions.

Figures and Legends

Figure 1. Anatomy of lungs with respect to the chest wall.

~~Motion graphics showing An approximate~~ An approximate projections of lungs and their fissures and lobes to the chest wall anteriorly (A) and posteriorly (B).

RUL – Right Upper Lobe; RML – Right Middle Lobe; RLL – Right Lower Lobe; LUL – Left Upper Lobe; LLL – Left Lower Lobe.

Table 1. Abnormal lung sounds.

A table summarizing potential abnormal findings during auscultation of the lungs.

Comment [D3]: This is a motion graphics picture that Dr Dhang asked to recreate.

Comment [AK4]: The submitted text in these manuscripts should not contain terminology pertaining to video production. The legend should describe the figure like any other legend in a manuscript. This text will be displayed on the website. It should sound like the figure legend from a paper.